



### Science Arts & Métiers (SAM)

is an open access repository that collects the work of Arts et Métiers Institute of Technology researchers and makes it freely available over the web where possible.

This is an author-deposited version published in: <https://sam.ensam.eu>  
Handle ID: <http://hdl.handle.net/10985/17441>

#### To cite this version :

Samy BENDAYA, Carolyn ANGLIN, Jean-Yves LAZENNEC, Rachele ALLENA, Philippe THOUMIE, Wafa SKALLI - Good vs Poor Results After Total Hip Arthroplasty: An Analysis Method Using Implant and Anatomic Parameters With the EOS Imaging System - Journal of Arthroplasty p.1-10 - 2016

Any correspondence concerning this service should be sent to the repository

Administrator : [scienceouverte@ensam.eu](mailto:scienceouverte@ensam.eu)



# Good vs Poor Results After Total Hip Arthroplasty: An Analysis Method Using Implant and Anatomic Parameters With the EOS Imaging System

Samy Bendaya, MD, PhD <sup>a, b, \*</sup>, Carolyn Anglin, PhD, PEng <sup>a, c</sup>,  
Jean-Yves Lazennec, MD, PhD <sup>a, d</sup>, Rachele Allena, PhD <sup>a</sup>, Philippe Thoumie, MD, PhD <sup>b</sup>,  
Wafa Skalli, PhD <sup>a</sup>

<sup>a</sup> Institut de Biomécanique Humaine Georges Charpak, Arts et Métiers ParisTech, Paris, France

<sup>b</sup> Hôpital Rothschild AP-HP, Paris, France

<sup>c</sup> Biomedical Engineering Civil Engineering, and McCaig Institute for Bone and Joint Health, University of Calgary, Calgary, Canada

<sup>d</sup> Departments of Orthopaedics and Anatomy, Hôpital Universitaire Pitié-Salpêtrière, UPMC, Paris, France

## ABSTRACT

**Background:** Existing imaging techniques and single-parameter analyses, in nonfunctional positions, fail to detect the differences between patients with good vs poor results after total hip arthroplasty. **Methods:** The present study developed an analysis method using the EOS full-body, low-dose, biplanar, weightbearing imaging system to compare good vs poor patients after total hip arthroplasty and to report on our preliminary experiences (17 good, 18 poor).

**Results:** All revision cases were found to have at least 4 high or low implant or anatomic parameters relative to the good group. These included acetabular cup orientation, sagittal pelvic tilt, sacral slope, femoral offset, and neck–shaft angle. Acetabular cup orientation differed significantly between groups.

**Conclusion:** With the EOS system, a large cohort can be studied relatively quickly and at low dose, which could lead to patient-specific guidelines.

## Keywords:

total hip arthroplasty

THA

EOS system

imaging

functional outcome

Total hip arthroplasty (THA) is one of the most common and successful orthopedic surgeries, with the dual goals of reducing pain and improving function. However, many patients experience postoperative issues, including hip dislocation, leg length discrepancy, pain, and muscle weakness. It is unclear which factors differentiate patients who do well and those who do poorly after surgery. Given the large and increasing number of hip arthroplasties performed each year and the fact that revision surgeries are more expensive [1], result in lower quality of life [2] and have a higher rate of re-revision [3] compared to primary THA, it is important to understand the cause of these mechanical complications and the origin of hip dysfunction. In particular, it is necessary to understand the differences between patients with good vs poor results after surgery.

Component placement, including acetabular cup orientation and depth, and the individual's functional posture, play key roles [4,5]. The challenge is how to measure these. Anteroposterior (AP) X-rays are the current standard for postoperative evaluation, but are inadequate for many clinical measures, including acetabular cup version and pelvic tilt, which require a sagittal view in addition to the AP or frontal view [6]. Furthermore, 2-dimensional measures from AP projection views vary with out-of-plane rotations, including pelvis rotation (whereby 1° of pelvic rotation causes 0.8° change in the measurement of acetabular version [7,8]), as well as femoral rotation or torsion, and flexion or hyper-extension of the femur [9,10]. Note that a large range of pelvic rotations may occur during acquisition [11]. Clinical complications are often investigated with computed tomography (CT) imaging, but this is acquired in the supine position, which does not provide a realistic evaluation of the articular compensation mechanisms during weightbearing. In addition, the resulting radiation dose does not allow CT scanning to be a routine method of review [12,13]. The EOS system acquires simultaneous, perpendicular AP and lateral views while providing a global view of the patient in a functional standing

No author associated with this paper has disclosed any potential or pertinent conflicts which may be perceived to have impending conflict with this work. For full disclosure statements refer to <http://dx.doi.org/10.1016/j.arth.2015.12.036>.

\* Reprint requests: Samy Bendaya, MD, PhD, Hôpital Rothschild AP-HP, 5 rue Santerre, 75012, Paris, France.

<http://dx.doi.org/10.1016/j.arth.2015.12.036>

**Table 1**  
Reasons for Poor Classification.

Primary Reason for Poor Result	Number of Subjects	Secondary Reasons for Poor Result
Leg length discrepancy (patient perception)	8	Hip flexion contracture (3), lateral pelvic tilt, sitting (2), pelvic rotation (1), muscle weakness (1)
Late dislocation (after 12 months)	5	Pelvic rotation (1), leg length discrepancy perception (2)
Hip flexion contracture	2	Lateral pelvic tilt, sitting (2)
High metal ion count + subluxation	2	Impingement (1), pelvic rotation (1)
Impingement	1	Leg length discrepancy perception (1)

or sitting position. This low-dose imaging system then creates a three-dimensional (3D) reconstruction for parameter calculation.

Low-dose, functional imaging with generated 3D models permits a new way to explore and investigate poor functional and clinical results after THA, individually and as a group, and is becoming increasingly common [14]. It is currently used routinely in over 150 medical centers worldwide, with costs lower than CT. EOS imaging results in 4-30 times lower radiation dose compared to CT [15] and 6-9 times lower radiation dose than computed radiography [12] with exact values depending on the imaging parameters, as well as the patient and area being scanned.

**Table 2**  
Subject Details for the Study Groups.

Subject Details	Good Results (n = 17), Mean/Range/SD	Poor Results (n = 18), Mean/Range/SD	P Value, Good vs Poor
Male/female	<b>8 F/9 M</b>	<b>15 F/3 M</b>	<b>.005</b>
Age at review (y)	<b>67.6/48-77/8.4</b>	<b>65.8/35-83/11.9</b>	.89
BMI (kg/m <sup>2</sup> )	<b>26.8/24-30/1.8</b>	<b>27.8/24-31/2.3</b>	.37
Harris Hip Score	<b>91.4/80-96/5.6</b>	<b>81.2/65-93/8.1</b>	<b>.001</b>

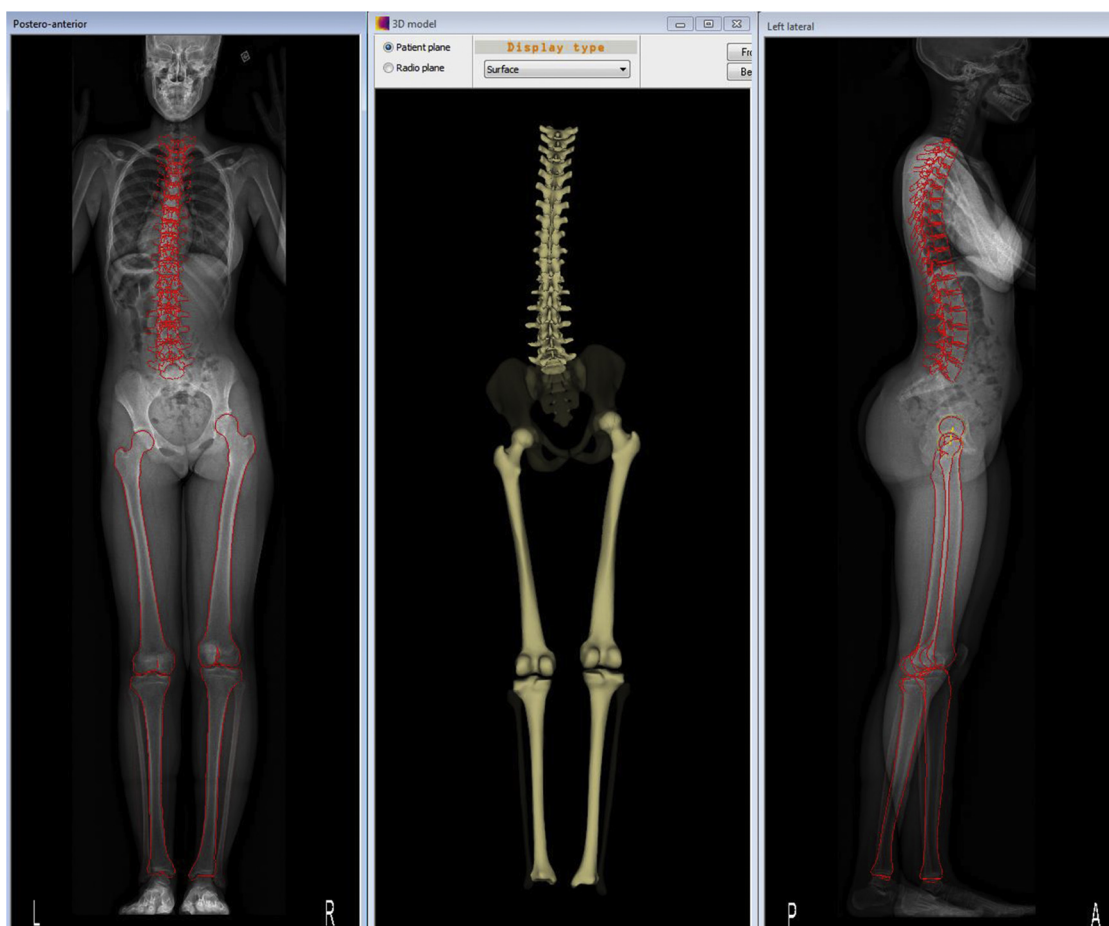
Bolded P-values are statistically significant.  
BMI, body mass index; F, female; M, male; SD, standard deviation.

The purpose of this retrospective study was to develop a method to compare patients with good versus poor results after THA and to report our preliminary experiences in using this technique to compare the groups.

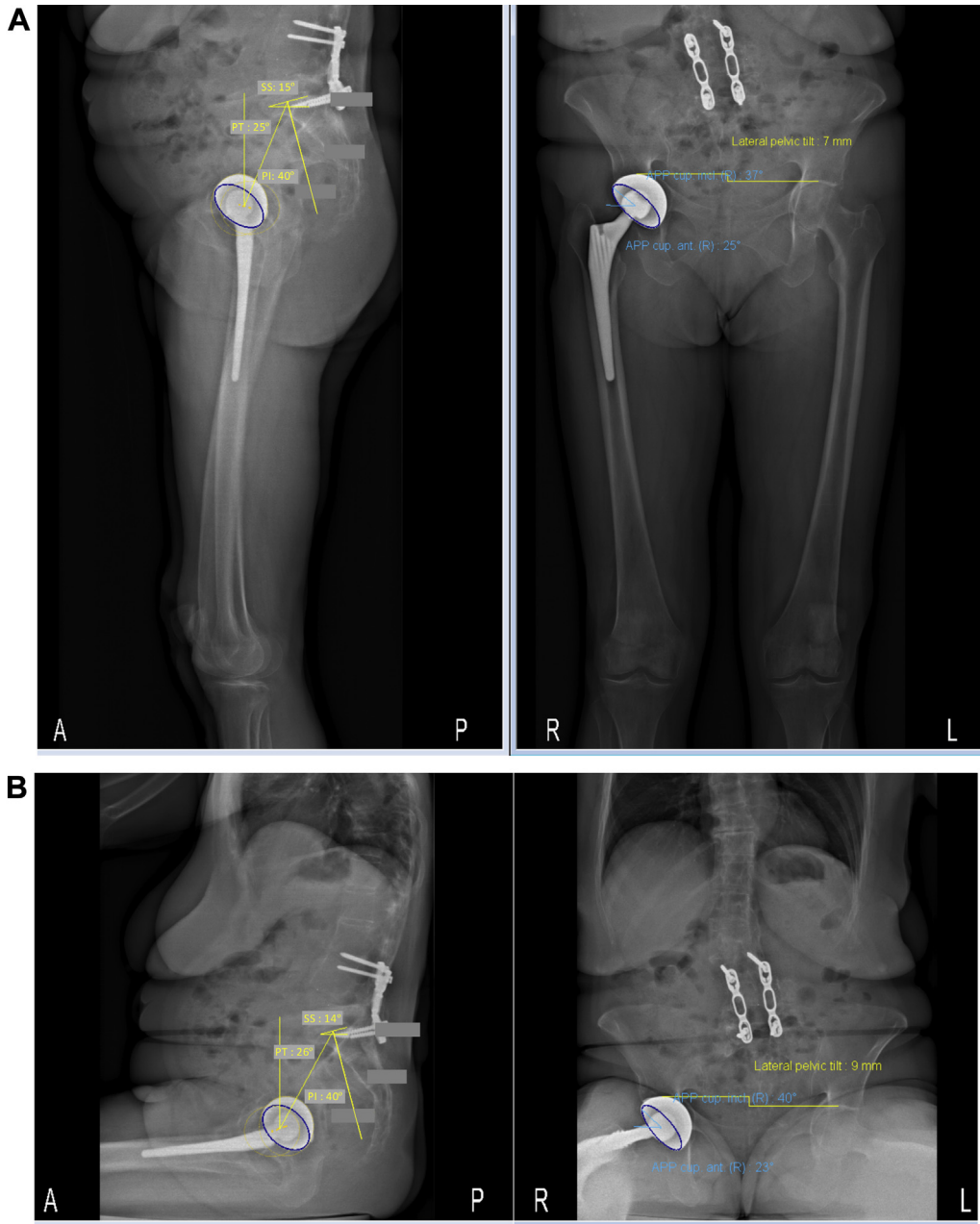
## Material and Methods

### Subject and Implant Details

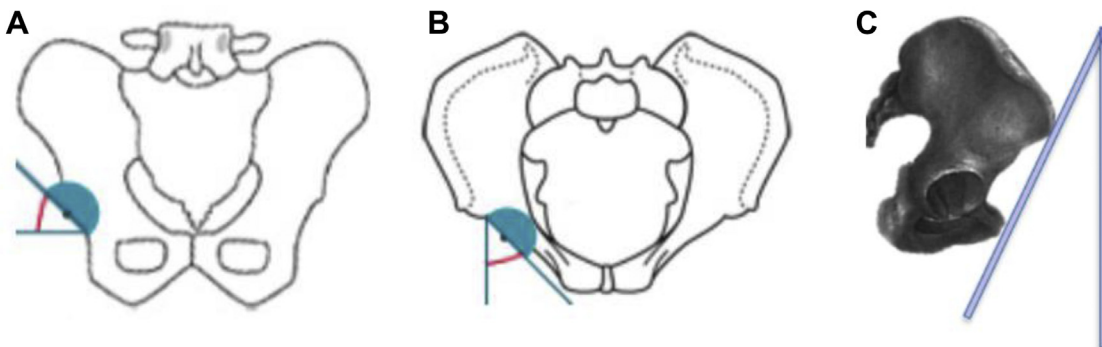
A total of 35 patients were studied: 17 with good results after THA (group G), 18 with poor results (group P). The patients were operated on or referred for follow-up to a single expert surgeon, between 2001 and 2011, with a minimum follow-up of at least 2 years. *Good results* were defined by a Harris Hip Score (HHS) >80 together with the surgeon's evaluation that the patient was satisfied with the surgery, without hip pain, with a good functional result, and without confounding issues such as total knee



**Fig. 1.** Frontal and lateral biplanar X-rays of the same patient in the standing position (left and right) and after skeletal reconstruction (middle).



**Fig. 2.** (A) Acetabular reconstruction and other parameters in the standing position; (B) acetabular reconstruction and other parameters of the same patient in the sitting position.



**Fig. 3.** (A) Acetabular cup inclination, (B) acetabular cup anteversion, and (C) tilt of the anterior pelvic plane (APP). Tilt of the APP does not affect inclination and version relative to the APP, but does change the functional inclination and version relative to the horizontal and vertical.

**Table 3**  
Acetabular Parameters for Good and Poor Groups.

Acetabular Orientation Parameters	Good Results After THA, Mean/Range/SD		Poor Results After THA, Mean/Range/SD		P Value, Good vs Poor, St/Si	P Value, Standing vs Sitting, Good/Poor
	Standing	Sitting	Standing	Sitting		
Acetabular inclination relative to patient transverse plane (°)	<b>37.9</b> /26-57/9	<b>48.8</b> /78-31/11	<b>44.0</b> /28-67/10	<b>53.6</b> (76-28)	.11/.15	<b>.002/.009</b>
Acetabular version relative to patient coronal plane (°)	<b>40.0</b> /21-52/9	<b>46.3</b> /56-39/5	<b>31.8</b> /2-56/12	<b>43.2</b> (58-30)	<b>.02</b> /.17	<b>.01/.002</b>
Acetabular inclination relative to APP (°)		<b>38.6</b> /29-51/7		<b>44.7</b> /28-64/9	.07	—
Acetabular version relative to APP (°)		<b>37.1</b> /11-53/9		<b>33.2</b> /8-48/11	.18	—

Bolded P-values are statistically significant.

APP, anterior pelvic plane; SD, standard deviation; THA, total hip arthroplasty.

arthroplasty or pain at another joint. *Poor results* were defined by HHS <80 or a patient presenting with postoperative pain or hip-related dissatisfaction, which included (primary + secondary reasons): leg length discrepancy perception (8 + 3), late dislocation (5 + 0), hip flexion contracture (2 + 3), high metal ion counts with subluxation (2 + 0), impingement (1 + 1), lateral pelvic tilt when sitting (0 + 4), pelvic rotation (0 + 2), or muscle weakness (0 + 1) (Table 1). No polyethylene wear was evident from the images in this study, and no osteolysis or abnormal centering of the femoral head inside the cup was seen. The *poor* subjects were chosen first, according to the listed criteria, after which a comparably sized cohort of *good* patients was chosen from a similar period. Our intention was to focus on the methodology for comparing groups, rather than on the individuals chosen to belong to each group. These 2 groups represent the 2 main categories of postoperative patient for the surgeon: (1) a good-results group that requires no further follow-up and (2) a poor-results group that needs further investigation to determine whether intervention, possibly revision surgery, is required. Some of the group G patients had isolated functional issues (such as leg length discrepancy or hip flexion contracture), but reported satisfaction and lack of pain. Group P patients had various issues, as listed previously, resulting in dissatisfaction and, in several cases, pain; they were chosen because they had defined functional (mechanical) deficits, rather than biological issues such as infection. Leg length discrepancy ranged from 8-13 mm, averaging 11 mm. In most cases, the dissatisfaction or pain occurred during follow-up rather than immediately after the surgery. None of the dislocations occurred immediately after the surgery.

Group G had a mean age of 68 years (standard deviation [SD], 8); 8 female, 9 male; mean body mass index (BMI) of 27 kg/m<sup>2</sup> (SD, 1.8); 9 right/6 left/2 bilateral THA; and a mean HHS of 91 (SD, 6;

Table 2); all had an anterior surgical approach (8 direct anterior approach and 9 anterolateral approach). Group P had a mean age of 66 years (SD, 12); mean BMI of 28 kg/m<sup>2</sup> (SD, 2.3); 15 female, 3 male; 8R/6L/4B; and mean HHS of 81 (SD, 8; Table 2). Including the bilaterals, 9 had an anterior surgical approach (5 direct anterior approach and 4 anterolateral approach), 7 had a posterior, and 4 had a lateral transgluteal approach, with the posterior and transgluteal approaches coming from referred patients. Prosthesis materials for group G (including the bilaterals) were 14 ceramic–ceramic THA, 3 metal–metal pairings, and 2 metal–polyethylene pairings. For group P, these ratios were 8:7:7 (including the 4 bilaterals). Although the groups were not homogeneous with respect to the implants and approaches, the purpose of the present study was to present an analysis method rather than to generate conclusions regarding the particular implant type or surgical approach.

#### Image Acquisition and Parameters Studied

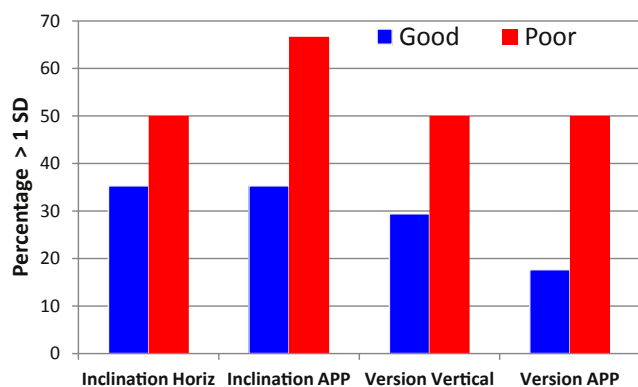
All subjects were imaged after THA in the standing position using the EOS system (Fig. 1) and all but 2 were also imaged in the sitting position.

Once the two 2D (AP and lateral) views were acquired, a 3D parameterized model was created. Clinical parameters were then derived from the 3D model. For the acetabular component, an ellipse was fit to the 2 views simultaneously, defining the cup inclination and version [16] (Fig. 2).

Acetabular cup orientation was the primary variable studied as many studies have shown links to the clinical outcome [17]. The orientation was measured both relative to the functional planes, that is, relative to the patient's (horizontal) transverse plane and (vertical) coronal plane, and relative to the commonly used anterior pelvic plane (APP or "Lewinnek plane"), whereby the APP is defined by the 2 anterior superior iliac spines and the 2 pubic tubercles [18] (Fig. 3). Two measurements of inclination and version were made for all subjects, for both the standing and sitting positions, and then averaged, for greater robustness.

Several pelvic parameters were studied because pelvic orientation has a direct impact on the functional acetabular orientation [19]. These included (see [20] for diagrams of parameters studied): sagittal pelvic tilt, sacral slope, pelvic incidence, axial pelvic rotation, APP relative to the vertical, and right/left height difference as measured by the proximodistal distance between the most proximal point on the acetabular cup and the most proximal point on the contralateral femoral head. Repeatability of the pelvic parameters was confirmed with 2 observers repeating the measurements 3 times on 3 subjects, in standing and sitting, showing an average difference lower than 3°.

The following femoral parameters were studied, as they have been shown to impact clinical outcome [20-23]: femoral offset



**Fig. 4.** Percentage of acetabular cup angles more than 1 SD outside the overall good-results mean, for the good-results and poor-results groups, for cup inclination relative to the horizontal and relative to the perpendicular to the anterior pelvic plane, as well as cup version relative to the vertical and APP. SD, standard deviation.



**Table 4**  
Pelvic Parameters for Good vs Poor Groups.

Pelvic Parameter	Good Results After THA, Mean/Range/SD		Poor Results after THA, Mean/Range/SD		P Value, Good vs Poor, St/Si	P Value, Stand vs Sit, Good/Poor
	Standing	Sitting	Standing	Sitting		
Pelvic tilt in the sagittal plane (PT-s) (°)	<b>17.8</b> /4-30/7	<b>35.5</b> /7	<b>16.1</b> /0-44/12	<b>38.0</b> /59-22/11	0.70/0.40	<.001/<.001
Sacral slope (SS) (°)	<b>34.8</b> /14-54/12	<b>20.4</b> /2-36/11	<b>34.6</b> /16-51/8	<b>19.0</b> /3-50/13	0.87/0.67	<.001/<.001
Pelvic incidence (PI) (°)	<b>52.6</b> /31-74/15	<b>55.8</b> /32-72/12	<b>50.7</b> /37-86/12	<b>55.8</b> /35-85	0.87/0.97	.64/.37
Pelvic rotation in the horizontal plane (PR) (°)	<b>-0.5</b> /-9 to 17/6	<b>-2.3</b> /-9 to 6/5	<b>0.4</b> /-8 to 24/8	<b>-2.9</b> /-9 to 2/3	0.59/0.55	.37/.11
Inclination of anterior pelvic plane (APP) (°)	<b>-2.9</b> /-17 to 31/11	<b>-19.7</b> /-35 to -4/9	<b>1.6</b> /-19 to 26/11	<b>-16.5</b> /-35 to 4/11	0.39/0.75	<.001/<.001
Leg length discrepancy (LLD) <sup>a</sup> (mm)	<b>8.0</b> /1-18/6	<b>6.3</b> /2-12/3	<b>7.7</b> /1-18/5	<b>5.9</b> /0.2-19/5	0.69/0.96	.31/.65

Bolded *P*-values are statistically significant.

SD, standard deviation; THA, total hip arthroplasty.

<sup>a</sup> Based on proximodistal distance between the most proximal point on the acetabular cup and the most proximal point on the contralateral femoral head.

(which can affect muscle weakness or leg length); femoral torsion for the nonoperated side and stem torsion for the operated side (which can affect the combined anteversion); neck length and neck-shaft angle (which can be altered by the surgeon, affecting femoral offset and leg length); and femoral head diameter of the contralateral hip (indicative of the size of the operated hip). Femoral and acetabular parameter repeatability has been validated previously [24,25].

To judge the homogeneity of the 2 groups, subject details (age, BMI, and HSS) were compared using a Student's *t* test, and the male or female proportions compared using a chi-square test, with *P* < .05 defined as significant.

Good vs poor results were compared using a Student's *t* test, with statistically significant results defined as those with *P* < .05. Although this may overpredict significant differences due to the multiple comparisons, the purpose of this pilot study was to identify hypotheses for further study and to provide an initial database of normative values. High/low values were highlighted for those individuals with parameter values more than one standard deviation from the mean of the good-results group. The number of these high/low values was accumulated to judge whether those with poor results had more values outside  $\pm 1$ SD than those with good results. In addition, the proportion of patients with acetabular orientation values outside  $\pm 1$ SD in the poor vs good groups was compared using a chi-square test. Finally, parameter values were compared between standing and sitting using a Student's *t* test.

## Results

Age and BMI were not significantly different between the 2 groups (Table 2). The HHS was significantly higher in group G vs P (averaging 91 and 81, respectively; *P* = .001), as expected due to the group definitions. The proportion of females (15 of 18) in group P was significantly higher than that in group G, which was roughly equally distributed between females and males (8 of 17; Table 2).

**Table 5**  
Femoral Parameters for Good vs Poor Results.

Femoral Parameter	Good Results After THA, Mean/Range/SD	Poor Results After THA, Mean/Range/SD	P Value, Good vs Poor
Femoral offset (mm)	<b>47.8</b> /32-88/13	<b>43.7</b> /32-89/11	.23
Femoral torsion (°)	<b>15.2</b> /-5 to 49/12	<b>14.0</b> /-11 to 36/14	.82
Stem torsion (°)	<b>10.2</b> /-22 to 36/15	<b>10.9</b> /-43 to 60/22	.90
Neck length (mm)	<b>52.0</b> /44-67/7	<b>49.2</b> /24-59/9	.19
Neck-shaft angle (CCD) (°)	<b>127.9</b> /117-143/6	<b>127.7</b> /62-139/13	.68
Femoral head diameter (mm)	<b>46.1</b> /39-55/4	<b>45.0</b> /40-52/4	.37

CCD, Caput-collum-diaphyseal angle.

Acetabular cup orientation differed significantly between groups (Table 3). Acetabular version relative to the coronal (vertical) plane was lower in group P (mean 32°, compared to mean 40° in group G; *P* = .02). Furthermore, there was a strong trend toward acetabular cup inclination relative to the APP being higher in group P (mean 45°, compared to mean 39° in group G; *P* = .07), whereby the proportion of patients with values more than 1 SD higher or lower than the overall mean in the good-results group was substantially and significantly greater in group P (67%) compared to group G (35%; *P* < .001; Fig. 4). The proportion of patients with acetabular inclination values relative to the transverse (horizontal) plane more than 1 SD higher or lower than the overall mean for the good results group was significantly higher in group P (50%) compared to group G (35%; *P* = .03). Likewise, the proportion of patients with acetabular version values relative to the APP more than 1 SD higher or lower than the overall good-results mean was significantly more in group P (50%) compared to group G (18%) (*P* < .001) and the acetabular version relative to the vertical with high or low values was more in group P (50%) compared to group G (29%; *P* = .002).

Interestingly, the means of the 2 groups on any of the remaining individual parameters (pelvic and femoral) were indistinguishable (*P* = .2-.9), with large variations seen in both groups (Tables 4 and 5).

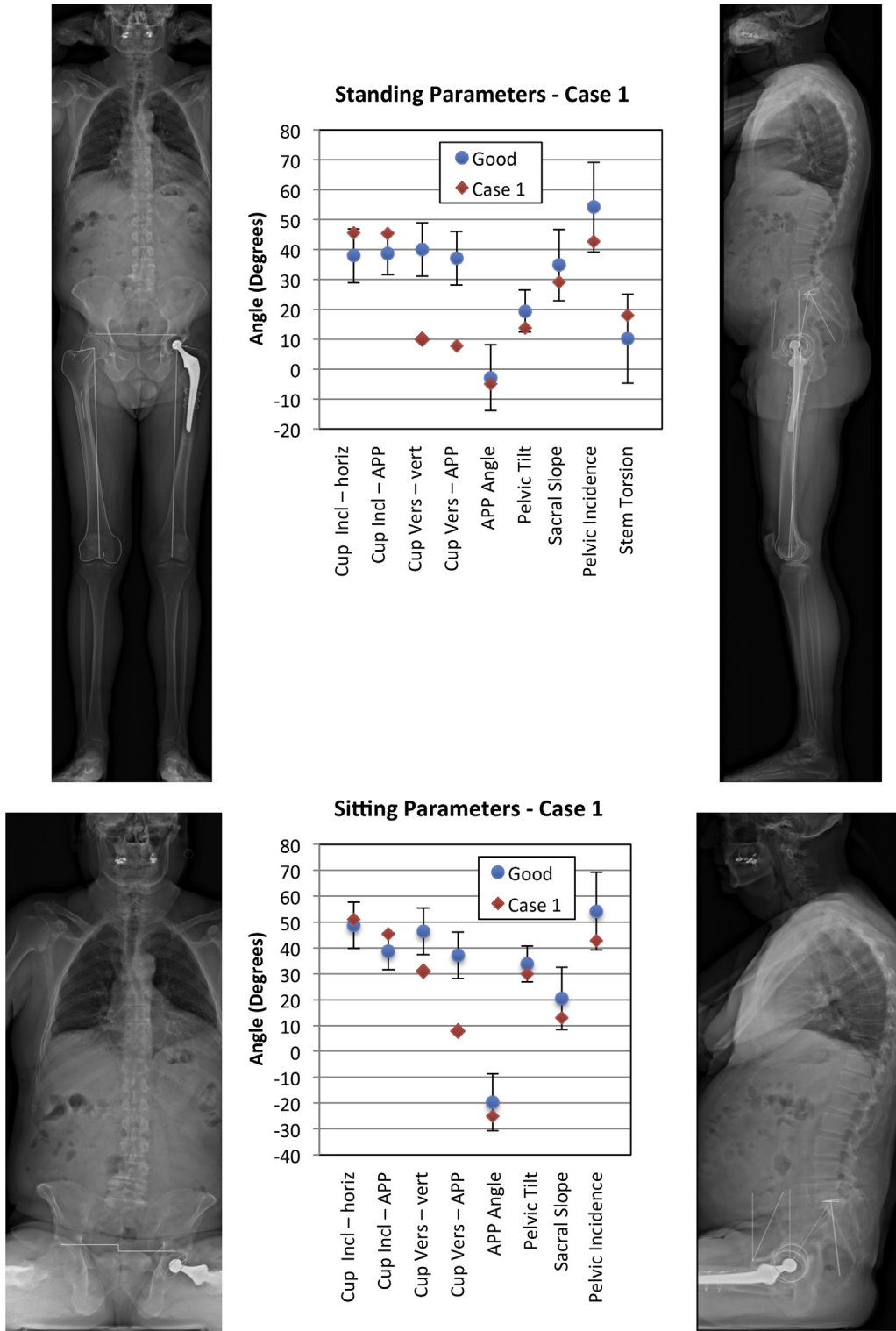
Individuals in the poor-results group demonstrated a greater number of parameters higher or lower than 1 SD from the mean (3.5  $\pm$  1.8, range 0-7) compared to the good-results group (2.3  $\pm$  1.8, range 0-6) in the standing position (*P* = .04). This difference was not seen in the sitting position. All patients who subsequently received revision surgery were found to have at least 4 values outside 1 SD, in the standing position, including acetabular cup orientation, sagittal pelvic tilt, sacral slope, femoral offset, and neck-shaft angle.

Between standing and sitting, sacral slope, sagittal pelvic tilt, APP inclination, and acetabular cup inclination and version relative to the patient plane, all differed significantly in both groups (*P* < .01), as expected (Table 4).

## Discussion

This study investigated patients with good vs poor results after THA. It is the first to provide acetabular, pelvic, and femoral parameters for these 2 groups and the first to provide evidence that a collection of high/low parameters may together contribute to a poor result.

The results show the importance of acetabular component placement, in both inclination and version. The results also show the importance of looking at individuals, not just groups, comparing their parameter values to normative values, to identify potential causes for pain and functional issues.

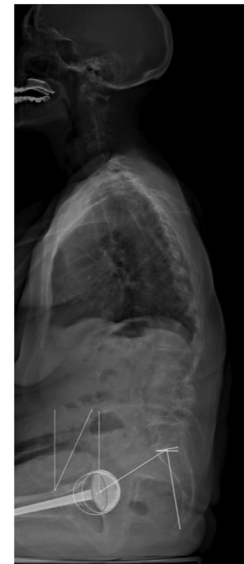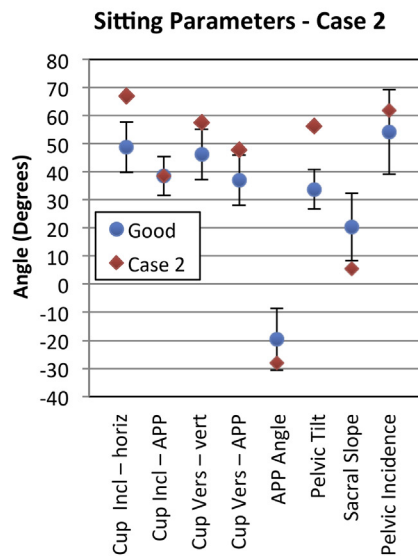
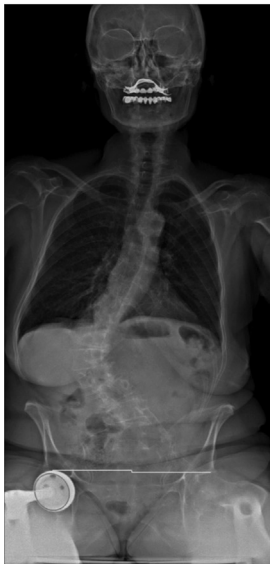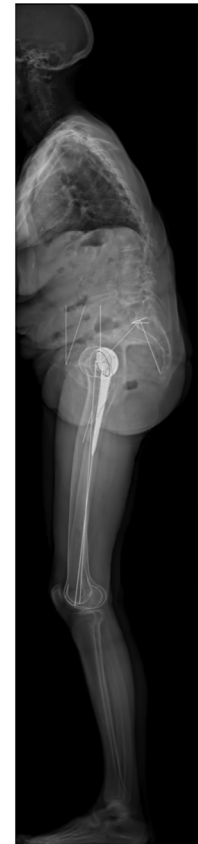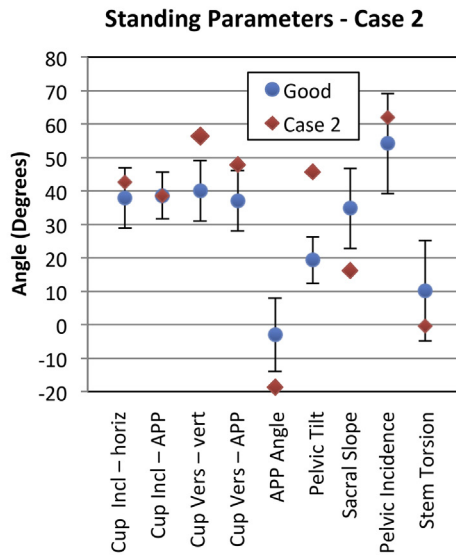


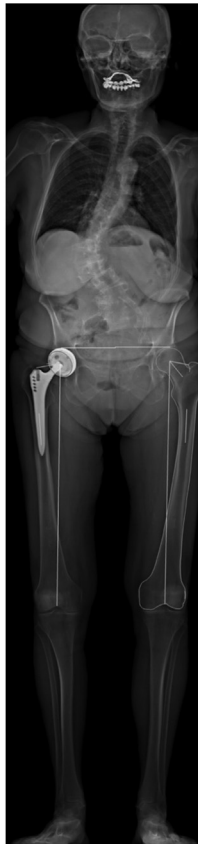**Fig. 5.** Case study 1 with posterior dislocation in the sitting position likely related to the low acetabular anteversion of the cup. The pelvic retroversion from the standing to sitting position (APP angle changed from  $-5^\circ$  in standing to  $-25^\circ$  in sitting) induced an increase in cup anteversion relative to the patient plane ( $10^\circ$  standing and  $31^\circ$  sitting) but was nevertheless insufficient in the sitting position based on the femoral stem anteversion ( $18^\circ$  relative to the patient plane) compared to the opposite side. The orientations also induced occasional posterior subluxation when walking with long strides and when climbing stairs.

An accumulation of high or low values may trigger a poor patient or implant response rather than a single high or low parameter. For example, posterior subluxation in one patient was likely due to the low acetabular cup version (Fig. 5), whereas anterior subluxation in 2 other patients was likely due to the retroverted

pelvis and low sacral slope angle (Fig. 6), and impingement may be related to a combination of acetabular positioning, pelvic tilt, and pelvic axial rotation (Fig. 7).

We recognize the diversity of problems in the “poor” group. Therefore, the goal of this article was not to provide a prescriptive

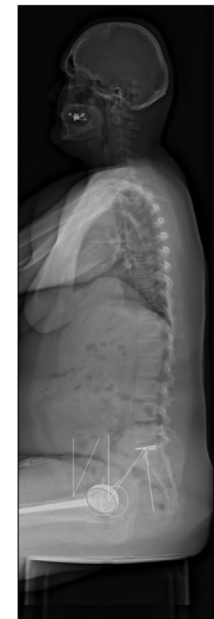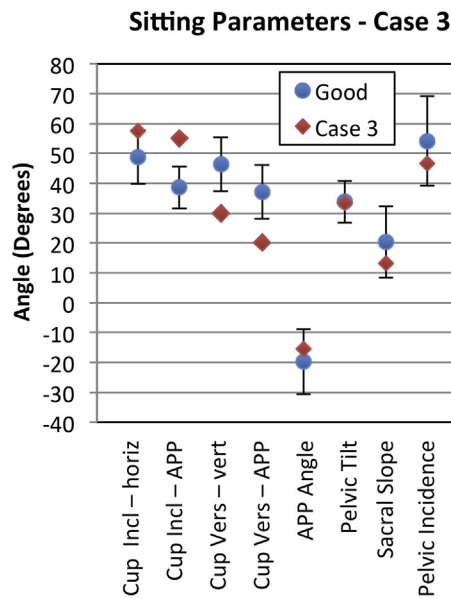
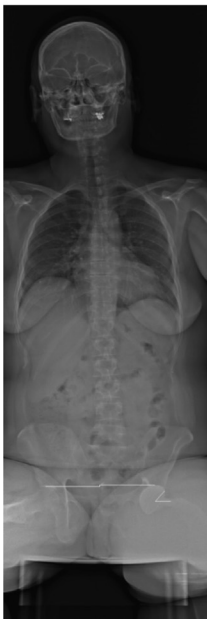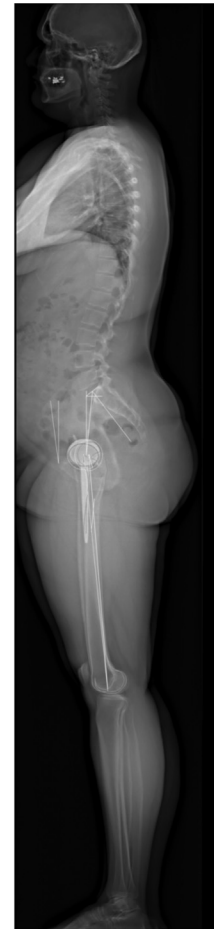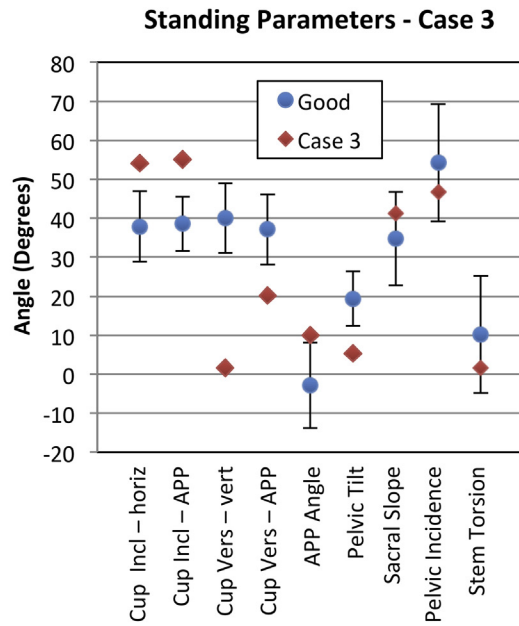


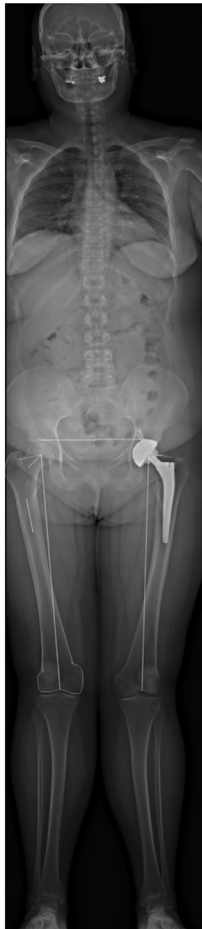**Fig. 6.** Case study 2 with anterior subluxations in the standing position, likely related to a retroverted pelvis (low sacral slope angle of 16°) combined with a high acetabular cup version angle. Because the cup version relative to the APP is almost within the normal range, the problem likely derives from the unusual pelvis position rather than the surgical cup positioning; if this were known in advance, the cup positioning could potentially be changed accordingly. The sitting position is acceptable because of the vertical and anteverted orientation of the cup.

solution to instability. Instead, we have developed a mental and analytical approach, recognizing that poor results are not due to a single parameter, but more often to a collection of unusual parameters. By collecting images preoperatively and postoperatively with the low-dose EOS system, the collection of parameters can be studied together, and unusual values identified.

Given the relatively quick measurement of the clinical parameters, coupled with the low-dose, weightbearing images obtained with the EOS system, patients can be routinely scanned before and after surgery, allowing a continual addition to the normative database presented here, together with the ability to investigate postoperative problems [14].





**Fig. 7.** In case study 3, the patient reported 2 combined problems: (1) anterior iliopsoas impingement in the standing position, likely related to the low anteversion angle of the cup and (2) from the standing to sitting position the patient experienced posterior subluxations—the range of pelvic tilt was substantial, from 5° PT and 10° APP angle in the standing position to 33° PT and -15° APP angle in the sitting position. Nevertheless the cup anteversion was insufficient (30° in the patient plane) to secure the joint in the sitting position because of the low anteversion of the stem (2° relative to the patient plane).

The lack of statistical significance between the good-results and poor-results groups on most parameters confirms the common finding that some patients look-good-feel-bad, whereas some

patients look-bad-feel-good. The fact that there was a significant difference in acetabular orientation agrees with the recognized need to improve the accuracy of component placement [4,26].

A hypothesis for future study is whether a higher acetabular cup inclination may be acceptable in someone with a retroverted (negative APP) pelvis (and anterior surgical approach) because this combination occurred in the 3 cases in the good-results group that had values higher than 1 SD from the mean. Greater numbers of patients with or without this combination are needed.

Surprisingly, version values farther from the widely quoted "safe zone" ( $15^\circ \pm 10^\circ$ ) [27] were associated with the good-results group. This also warrants further investigation. The most likely factor is that the anterior surgical approach used for most of these patients reduced problems with dislocation [28]. It may also be related to the particular surgical technique used by the surgeon. Our findings for desired acetabular cup inclination are closer to the standard safe zone ( $40^\circ \pm 10^\circ$ ) in that 10 of 18 patients with poor results had inclination values  $>45^\circ$ ; however, the large range of values in the poor-results group shows that other factors are also important, including the patient's functional posture [19,29], and femoral torsion [30], which in turn affect the functional cup inclination and version. Previous studies have likewise shown that many prostheses do not fall within the safe zone [25,30,31]. Several different guidelines have been proposed [30,32-34]; however, these typically depend on CT scans, which have a high dose and are supine. Use of the EOS system now offers the opportunity to study a larger cohort of individuals, and to determine which parameters are different from normal, in the functional position, pointing to possible individual causes for pain or functional deficit. The greater proportion of females in the poor-results group warrants further attention.

This preliminary study had several limitations. The number of subjects was low; there was a diversity of clinical problems, implant types, and surgical approaches; the gender mix differed in the 2 groups; and patients were from a single surgeon. Future studies should target a specific clinical issue for a large number of patients from a variety of surgeons. Nevertheless, the potential for using this imaging modality to identify group differences and individual issues was demonstrated. Because of the heterogeneity of the data sets, the implant type, surgical technique, or gender may have played a role in the differences between patients and groups; the analysis framework has now been laid to investigate these questions in a larger data set with more homogeneous or matched parameters between groups. Another limitation is that the number and choice of parameters studied will affect the accumulation of high or low values; a larger study will allow a selection of the most relevant parameters as well as the possibility for cluster-based analysis such as neural networks or principal components analysis. Larger, multisurgeon, multicenter studies are recommended as use of this imaging modality expands.

## Conclusion

In summary, acetabular cup differences do exist between the good- and poor-results groups. By contrast, most other parameters overlap considerably between the 2 groups so that ultimately each patient needs to be studied individually. EOS imaging can be used on all patients, because of the low dose, to analyze cup position and other functional and anatomic parameters, both preoperatively and postoperatively. This will both grow the database of patients with good results and help to diagnose clinical problems in those with poor results, by identifying those parameters that are higher or lower than normal. Importantly, a collection of unusual parameters appears to contribute to a poor result even when a single parameter is not indicative of problems on its own. Given the increasing number of THAs and the technical and economic challenges of revision surgery, it is critical to identify patients at risk of a poor outcome and better diagnosis methods after surgery. An analysis of preoperative and postoperative parameters, correlated with the

clinical results, could lead to patient-specific planning and diagnosis guidelines to improve the outcome of both primary and revision surgery.

## References

1. Bozic KJ, Katz P, Cisternas M, et al. Hospital resource utilization for primary and revision total hip arthroplasty. *J Bone Joint Surg Am* 2005;87:570.
2. Patil S, Garbuz DS, Greidanus NV, et al. Quality of life outcomes in revision vs primary total hip arthroplasty: a prospective cohort study. *J Arthroplasty* 2008;23:550.
3. Ong KL, Lau E, Suggs J, et al. Risk of subsequent revision after primary and revision total joint arthroplasty. *Clin Orthop* 2010;468:3070.
4. Shandiz MA, MacKenzie JR, Hunt S, et al. Accuracy of an adjustable patient-specific guide for acetabular alignment in hip replacement surgery (Optihip). *Proc Inst Mech Eng H* 2014;228:876.
5. Blendea S, Eckman K, Jaramaz B, et al. Measurements of acetabular cup position and pelvic spatial orientation after total hip arthroplasty using computed tomography/radiography matching. *Comput Aided Surg Off J Int Soc Comput Aided Surg* 2005;10:37.
6. Kalteis T, Handel M, Herold T, et al. Position of the acetabular cup—accuracy of radiographic calculation compared to CT-based measurement. *Eur J Radiol* 2006;58:294.
7. Dorr LD, Hishiki Y, Wan Z, et al. Development of imageless computer navigation for acetabular component position in total hip replacement. *Iowa Orthop J* 2005;25:1.
8. Lembeck B, Mueller O, Reize P, et al. Pelvic tilt makes acetabular cup navigation inaccurate. *Acta Orthop* 2005;76:517.
9. Lazennec JY, Brusson A, Dominique F, et al. Offset and anteversion reconstruction after cemented and uncemented total hip arthroplasty: an evaluation with the low-dose EOS system comparing two- and three-dimensional imaging. *Int Orthop* 2015;39:1259.
10. Folinis D, Thelen P, Delin C, et al. Measuring femoral and rotational alignment: EOS system versus computed tomography. *Orthop Traumatol Surg Res* 2013;99:509.
11. Tannast M, Fritsch S, Zheng G, et al. Which radiographic hip parameters do not have to be corrected for pelvic rotation and tilt? *Clin Orthop Relat Res* 2015;473:1255.
12. Deschènes S, Charron G, Beaudoin J, et al. Diagnostic imaging of spinal deformities: reducing patients radiation dose with a new slot-scanning X-ray imager. *Spine* 2010;35:989.
13. Saxler G, Marx A, Vandavelde D, et al. [Cup placement in hip replacement surgery—a comparison of free-hand and computer assisted cup placement in total hip arthroplasty—a multi-center study]. *Z Für Orthop Ihre Grenzgeb* 2004;142:286.
14. Lazennec JY, Rousseau MA, Brusson A, et al. Total hip prostheses in standing, sitting and squatting positions: an overview of our 8 years practice using the EOS imaging technology. *Open Orthop J* 2015;9:26.
15. Delin C, Silvera S, Bassinet C, et al. Ionizing radiation doses during lower limb torsion and anteversion measurements by EOS stereoradiography and computed tomography. *Eur J Radiol* 2014;83:371.
16. Journé A, Sadaka J, Bêlicourt C, et al. New method for measuring acetabular component positioning with EOS imaging: feasibility study on dry bone. *Int Orthop* 2012;36:2205.
17. Barbier O, Skalli W, Mainard L, et al. The reliability of the anterior pelvic plane for computer navigated acetabular component placement during total hip arthroplasty: prospective study with the EOS imaging system. *Orthop Traumatol Surg Res* 2014;100:S287.
18. Lazennec JY, Rousseau MA, Rangel A, et al. Pelvis and total hip arthroplasty acetabular component orientations in sitting and standing positions: measurements reproducibility with EOS imaging system versus conventional radiographies. *Orthop Traumatol Surg Res* 2011;97:373.
19. Lazennec JY, Riwan A, Gravez F, et al. Hip spine relationships: application to total hip arthroplasty. *Hip Int J Clin Exp Res Hip Pathol Ther* 2007;17 Suppl 5:S91.
20. Bendaya S, Lazennec JY, Anglin C, et al. Healthy vs osteoarthritic hips: a comparison of hip, pelvis and femoral parameters and relationships using the EOS system. *Clin Biomech* 2015;30:195.
21. Morrey BF. Instability after total hip arthroplasty. *Orthop Clin North Am* 1992;23:237.
22. Jameson SS, Lees D, James P, et al. Lower rates of dislocation with increased femoral head size after primary total hip replacement: a five-year analysis of NHS patients in England. *J Bone Joint Surg Br* 2011;93:876.
23. Berry DJ, von Knoch M, Schleck CD, et al. Effect of femoral head diameter and operative approach on risk of dislocation after primary total hip arthroplasty. *J Bone Joint Surg Am* 2005;87:2456.
24. Guenoun B, El Hajj F, Biau D, et al. Reliability of a new method for evaluating femoral stem positioning after total hip arthroplasty based on stereoradiographic 3D reconstruction. *J Arthroplasty* 2015;30:141.
25. Humbert L, Carliz H, Baudoin A, et al. 3D Evaluation of the acetabular coverage assessed by biplanar X-rays or single anteroposterior X-ray compared with CT-scan. *Comput Methods Biomech Biomed Engin* 2008;11:257.
26. Callanan MC, Jarrett B, Bragdon CR, et al. The John Charnley Award: risk factors for cup malpositioning: quality improvement through a joint registry at a tertiary hospital. *Clin Orthop* 2011;469:319.

27. Lewinnek GE, Lewis JL, Tarr R, et al. Dislocations after total hip-replacement arthroplasties. *J Bone Joint Surg Am* 1978;60:217.
28. Bouchet R, Mercier N, Saragaglia D. Posterior approach and dislocation rate: a 213 total hip replacements case-control study comparing the dual mobility cup with a conventional 28-mm metal head/polyethylene prosthesis. *Orthop Traumatol Surg Res* 2011;97:2.
29. Lazennec J-Y, Charlot N, Gorin M, et al. Hip-spine relationship: a radio-anatomical study for optimization in acetabular cup positioning. *Surg Radiol Anat* 2004;26:136.
30. Masaoka T, Yamamoto K, Shishido T, et al. Study of hip joint dislocation after total hip arthroplasty. *Int Orthop* 2006;30:26.
31. Saxler G, Marx A, Vandeveld D, et al. The accuracy of free-hand cup positioning—a CT based measurement of cup placement in 105 total hip arthroplasties. *Int Orthop* 2004;28:198.
32. Haaker RGA, Tiedjen K, Ottersbach A, et al. Comparison of conventional versus computer-navigated acetabular component insertion. *J Arthroplasty* 2007;22:151.
33. Nadzadi ME, Pedersen DR, Callaghan JJ, et al. Effects of acetabular component orientation on dislocation propensity for small-head-size total hip arthroplasty. *Clin Biomech Bristol Avon* 2002;17:32.
34. Barrack RL. Dislocation after total hip arthroplasty: implant design and orientation. *J Am Acad Orthop Surg* 2003;11:89.