



Science Arts & Métiers (SAM)

is an open access repository that collects the work of Arts et Métiers Institute of Technology researchers and makes it freely available over the web where possible.

This is an author-deposited version published in: <https://sam.ensam.eu>
Handle ID: [.http://hdl.handle.net/10985/21381](http://hdl.handle.net/10985/21381)

To cite this version :

Nathalie MAUREL, Amadou DIOP, Pauline LALLEMANT-DUDEK, Franck FITOUSSI - Upper limb kinematics after Latissimus Dorsi transfer in children with brachial plexus birth palsy - Clinical Biomechanics - Vol. 87, p.105413 - 2021

Any correspondence concerning this service should be sent to the repository

Administrator : scienceouverte@ensam.eu



Upper limb kinematics after Latissimus Dorsi transfer in children with brachial plexus birth palsy

Nathalie Maurel^{a,*}, Amadou Diop^a, Pauline Lallemand-Dudek^{b,d}, Franck Fitoussi^{c,d}

^a Arts et Metiers Institute of Technology, EPBRO, HESAM Université, 151 Boulevard de l'Hôpital, F-75013 Paris, France

^b Hôpital Trousseau, Service de Médecine Physique et de Réadaptation pédiatrique, 26 Avenue du Dr Arnold Netter, 75012 Paris, France

^c Hôpital Trousseau, Service de chirurgie orthopédique et reconstructrice de l'enfant, 26 Avenue du Dr Arnold Netter, 75012 Paris, France

^d Faculté de Médecine Sorbonne Université, 91 Boulevard de l'Hôpital, 75013 Paris, France

A B S T R A C T

Background: Brachial plexus birth palsy remains a frequent condition and one of its treatments is to transfer the Latissimus Dorsi tendon to the infraspinatus muscle. The aim of this study was to analyse, for the first time, the three-dimensional kinematic effects of this operation on the upper limb joints during the five Mallet tasks and their correlation with clinical parameters.

Methods: Kinematic analysis was performed using an electromagnetic device. An Index of Improvement taking into account the angle in preop and postop, the reproducibility and the angle of a control group was developed. Three groups of patients were analysed: sixteen patients (mean: 10,5 years) for the reproducibility, thirty children (mean: 9,5 years) for the control group and ten patients (mean: 8 years 7 months) who were operated.

Findings: The humerothoracic and glenohumeral external rotations improved during the external rotation, the neck and the abduction tasks and worsened during the spine task. The glenohumeral external rotation worsened during the mouth task. The Humerothoracic abduction improved during the abduction and the neck tasks. The elbow flexion improved for the neck task. Differences were observed between patients and correlations were obtained between the Index of Improvement and clinical parameters.

Interpretation: Using kinematics allows to better analyse the evolution of joint angles after the latissimus dorsi transfer. The Index of Improvement allows to quickly analyse the effect of the operation for each angle and each patient. This effect depends on clinical parameters.

1. Introduction

Brachial plexus birth palsy (BPBP) remains a frequent condition with an estimated incidence of 0.19 to 1.51 cases per 1000 live births (Foad et al., 2008). BPBP is accountable for permanent functional impairments in 8 to 34% of patients (Hale et al., 2010) with a more frequently involvement of the proximal cervical roots (C5, C6 +/- C7) (Waters, 2011). At the shoulder, muscular weakness primarily affects external rotators (ER; infraspinatus and teres minor muscles) whereas internal rotators are usually preserved, resulting in glenohumeral joint axial imbalance (Waters and Bae, 2008). In order to restore the joint axial balance, most authors recommend release of the subscapularis muscle in association with Latissimus Dorsi (LD) muscle transfer to the posterior

aspect of the rotator cuff (El-Gammal et al., 2006; Pearl et al., 2006; Werthel et al., 2018). However, the real kinematic effect of such tendon transfer has not been clearly studied on the glenohumeral (GH), scapulothoracic (ST) and elbow joints.

Clinical measures such as the Mallet scale provide information on general shoulder motion but little on the specific joint contributions to movement (Curtis et al., 2002; Mallet, 1972). To quantify changes after a LD tendon transfer, kinematic analysis may be a valuable adjunct to clinical tools. Upper limbs kinematics has already been studied in children with BPBP during functional movements (Bahm, 2016; Bialo-cerkowski et al., 2006; Duff et al., 2007; Fitoussi et al., 2009; Herisson et al., 2017; Mahon et al., 2018; Mayfield et al., 2017; Mosqueda et al., 2004; Russo et al., 2014; Russo et al., 2019a, 2019b; Wang et al., 2007).

* Corresponding author at: Arts et Metiers Institute of Technology, Equipe Biomécanique et Remodelage Osseux (EPBRO), HESAM Université, 151, Bd de l'Hôpital, F-75013 Paris, France.

E-mail addresses: nathalie.maurel@ensam.eu (N. Maurel), amadou.diop@ensam.eu (A. Diop), pauline.lallemand@aphp.fr (P. Lallemand-Dudek), franck.fitoussi@aphp.fr (F. Fitoussi).

Table 1
Patients' characteristics.

Patient	Sex	Side	Narakas grade	Primary Nerve Surgery	Mallet score preop					Mallet score postop					Follow up	Age at surgery (month)
					Abd	ER	Neck	Spine	Mouth	Total	Abd	ER	Neck	Spine		
S1	M	R	IV	Y	3	2	2	2	3	12	3	3	3	3	4	16
S2	F	R	I	Y	4	2	2	2	2	13	4	4	4	4	3	18
S3	F	R	II	Y	4	2	2	2	3	13	4	3	5	4	3	19
S4	M	R	II	N	5	2	2	2	2	15	4	3	4	4	3	18
S5	M	R	II	N	4	2	3	2	3	15	4	3	4	3	5	19
S6	F	R	II	N	3	2	3	3	3	14	3	4	4	3	4	18
S7	F	L	II	N	4	2	2	2	3	13	5	2	4	5	3	19
S8	M	L	II	N	4	2	2	2	2	14	5	3	5	5	4	22
S9	M	L	III	Y	3	2	2	2	4	13	3	4	4	2	4	17
S10	F	R	I	N	3	2	3	3	4	15	3	4	4	4	4	19

Abd: Abduction; ER: External Rotation.

Table 2
MRI data.

Patient	Glenoid version (N = -6 to +1)	Glenoid shape (normal = 1; flat or convex = 2; bifacet = 3)	PHHA (N = 0,4-0,55)	HHS (normal = 0; flat = 1)
S1	-7	2	0,33	1
S2	-7	2	0,53	0
S3	-7	1	0,42	0
S4	-34	3	0,1	1
S5	-7	1	0,46	0
S6	-13	2	0,46	0
S7	-7	1	0,33	0
S8	-15	3	0,36	0
S9	-1	1	0,55	0
S10	-7	1	0,47	0

PHHA: percentage of humeral head anterior; HHS: Humeral Head Shape; N: non-involved Population.

However, to our knowledge, it has never been studied in children with BPBP before and after Latissimus Dorsi transfer.

The main objective of this study was to evaluate how the LD transfer modified the upper limb kinematics during the Mallet score tasks. These modifications will be analysed, first globally for the whole group of operated patients and secondly for each patient of this group using a specific Index of Improvement (II). In order to reach this objective and to create this index, three groups of patients were studied: one to study the reproducibility of the kinematic parameters, one to obtain a normative database and a last one to assess the kinematic changes before and after the LD transfer.

A secondary objective will be to analyse if the effect of the LD transfer can be correlated to clinical parameters.

2. Methods

2.1. Participants

Three groups of patients were studied.

Children who had received previous shoulder reconstructive surgery, children with bilateral brachial plexus birth injuries or unable to follow directions were excluded. Institutional Review Board approved the study for children. Signed consent from a parent was received prior to participation.

Group 1:

Sixteen BPBP were included in the study of reproducibility. The mean age was 10 years and 6 months (range, 4 years and 10 months-16 years). The two upper limbs were studied. Ten patients had the right side affected. Ten children were managed conservatively whereas six underwent primary repair of the brachial plexus within the first 7 months of life. The global Mallet score was 14.9 (range 11-18).

Group 2:

Thirty BPBP patients participated in the construction of the database using their non-involved arm. The mean age was 9 years and 6 months (range, 4 years and 10 months-16 years).

Group 3:

Ten children with BPBP treated with LD transfer for shoulder ER deficit were included in this study (Table 1), five males and five females. The mean age was 8 years 7 months (range, 5 years 10 months-12 years 7 months). Four children underwent primary repair of the brachial plexus within the first 7 months of life. Right side was involved in 7 cases. Severity of the palsy was classified according to Narakas' classification (Narakas, 1987). Functional evaluation was conducted using the modified Mallet score (Abzug et al., 2010). Shoulder clinical assessment was conducted with a goniometer and focused on measuring ranges of motion, including active abduction, active and passive external rotation with the arm at the side of the body (i.e., ER1) and external rotation with the arm 90° abducted (i.e., ER2). Tendon transfer was performed in

patients with active ER1 $\leq 0^\circ$. LD strength was evaluated using the British Medical Council Research (BMRC) grading system and muscles with a score of 4 or 5 were considered for transfer. All patients benefited from preoperative magnetic resonance imaging (MRI) of the paralyzed shoulder to assess the glenoid version (GV), the percentage of humeral head anterior (PHHA) to the middle of the glenoid and the glenohumeral deformity type (Glenoid Shape and Humeral Head Shape) according to Waters et al., 1998. Eight patients had normal humeral head shape and only one presented a posterior humeral head dislocation (Table 2).

The mean delay between the preop kinematic and the operation was 7 months (range, 0.7 months–21.5 months). Between the operation and the postop kinematic study, it was 8 months (range, 5.9 months–12.1 months).

2.2. Surgical management

Under general anesthesia, the patient was placed in lateral position, contralateral to the paralyzed shoulder. LD was first exposed so that its tendon could be separated from the teres major muscle and detached from its humeral insertion. Release of the subscapularis muscle from the scapula was performed in order to obtain at least 30° of passive ER1 during surgery. Only one patient (S10) had no subscapularis release because the preop passive ER1 was superior to 30° . With the shoulder positioned in maximal ER2, the LD was finally sutured to the infraspinatus tendon and additionally secured to its footprint with one or two non-absorbable suture anchors. Upper limb was immobilized with a thoracobrachial spica cast under general anesthesia, with the shoulder positioned in abduction and external rotation position. After 6 weeks of immobilization, the cast was removed, and rehabilitation was initiated.

2.3. Kinematic analysis

The protocol described by Herisson et al., 2017 was followed. Briefly, kinematic measurements were performed using the Fastrak (Polhemus, Colchester, US) electromagnetic tracking device. Patients were asked to perform five tasks based on the Mallet scale (Hand to mouth (Mouth), Hand to neck (Neck), Hand to Back (Spine), elevating the upper limb in the scapula plane (Abduction), external rotation (ER). Each task was repeated three times consecutively and the mean value obtained from those three trials was studied. Eleven angles were calculated to analyse at the final position, which corresponds to the point of task achievement, the relative positions of anatomical frames, humerus versus thorax (humerothoracic: HT), scapula versus thorax (scapulathoracic: ST), humerus versus scapula (glenohumeral: GH) and forearm versus humerus (elbow). The kinematic calculations followed the descriptions of Herisson et al., 2017 for ST, GH and Maurel et al., 2013 for HT and elbow. For ER, the humeral anatomical frame was calculated at each frame using the positions of the diaphyseal axis of the forearm and the diaphyseal axis of the humerus following the second option in Wu et al., 2005.

2.3.1. Reproducibility study of the protocol

The protocol was followed once by the patient. Then the scapular receiver that was taped on the acromion was removed. Some five minutes later, it was fixed again and all the anatomical points of all the bones were palpated once again. Then, the patient had to repeat the whole protocol (five tasks with three trials per task).

2.3.2. Database

The mean value (M) and the standard deviation (SD) of all the angles were calculated.

2.3.3. Statistical analysis

2.3.3.1. Reproducibility. For the reproducibility study of the protocol

Table 3

Method of creation of the Index of Improvement (II) for each angle: II depends on M (Mean value of the database), SD (standard deviation of the database), MDC95. TN is a test notation: its value is 1 if the angle is inside the corridor $[M - 2SD, M + 2SD]$ and is -1 if the angle is outside this corridor.

Preop test notation (TN)	PostOp test notation (TN)	Difference between Pre and Post op \geq MDC95	$ M - PostOp \leq M - PreOp $	Index of improvement
-1	1	yes	yes	100
-1	1	no	yes	75
-1	-1	yes	yes	50
-1	-1	no	yes	25
-1	-1	no	no	-25
-1	-1	yes	no	-50
1	-1	no	no	-75
1	-1	yes	no	-100
1	1			0

performed on the group 1, the Intraclass Correlation Coefficient (ICC) with an ICC(2,2) model (Pecoraro et al., 2007, Weir, 2005, Maurel et al., 2013), and the Minimum Detectable Change with 95% confidence intervals (MDC95) were calculated as described in Maurel et al., 2013 or Weir, 2005 for the angles at the final position. An angle was considered reproducible if ICC was higher than 0.85. To study the reproducibility of the Test Notation (TN) described below, a Kappa inter-rater agreement test was used. A Kappa value lower than 0.41 was considered poor or fair.

2.3.3.2. *Preop and postop comparison.* To compare preop and postop angles in Group 3, we first analysed if the normality assumption could be accepted using Lilliefors test for the two compared series. When normality existed for the two series, we used a parametric test (paired sample two-tailed *t*-test). Otherwise, we used a non-parametric test (paired Wilcoxon signed rank test). For this comparison, we calculated the effect size and the power.

2.3.3.3. *Correlation with clinical parameters.* To study the correlation of the clinical parameters, with II and INPatientTask (described below), we performed a Spearman rank correlation test.

Statistical significance was set at $P < 0.05$.

2.3.4. Effect of the operation

To formalize the effect of the operation, for each patient and for each of the reproducible angles, we defined an Index of Improvement (II). II used the values of the angle before (PreopAngle) and after (PostopAngle) the operation, the MDC95 and the mean value (M) and the standard deviation (SD) of the database.

First, we calculated a test notation TN in preop and in postop. If the angle is inside the range $[M - 2SD, M + 2SD]$, TN equals 1 otherwise it equals -1 .

Secondly, to define if the difference between PostopAngle and PreopAngle can be considered as sufficient, we compared it to the MDC95. Thirdly, to analyse if PostopAngle is nearer to the M value than PreopAngle, we compared the differences in absolute value of M and PreopAngle and of M and PostopAngle. Depending on what happens for those different calculations, we defined the value of the Index of Improvement (II) between -100 and $+100$ by steps of 25 as explained in Table 3.

Finally, for each patient and each task, the mean value of this index for all the reproducible angles (INPatientTask) was calculated.

3. Results

3.1. Clinical data

Data about clinical and MRI evaluations for group 3 patients are

Table 4

Reproducibility (ICC (95% confidence interval); MDC95) and mean values “M” (standard deviation SD) of angles (°)* for each task in preop, postop analyses and for the database. P value to discriminate the preop and postop results. The index N for the P value indicates when a non-parametric test was performed.

		PreOp		PostOp		P	Effect Size	Power	Database		ICC (95% Conf. Interval)	MDC95
		M	SD	M	SD				M	SD		
Abduction	HTFE	33,0	11,9	31,7	12,6	0,5456	0.2	0.09	23,4	8,4	0,94 (0,89–0,97)	10,8
	HTRot	50,4	20,2	27,3	23,3	0,0020 ^N	1.54	0.99	-0,3	16,1	0,95 (0,89–0,97)	26,0
	HTAbAd	-41,2	10,2	-50,4	8,6	0,0202	0.9	0.84	-64,6	7,7	0,98 (0,96–0,99)	7,5
	ABHFE	37,8	23,2	41,2	19,8	0,1939	0.44	0.24	18,9	8,7	0,95 (0,91–0,98)	18,7
	ABHPS	78,5	29,5	84,9	30,6	0,2910	0.35	0.17	113,7	15,9	0,93 (0,85–0,97)	31,0
	STMed	-4,7	11,1	-9,3	11,1	0,2007	0.44	0.23	-5,7	9,3	0,96 (0,90–0,98)	6,1
	STTilt	-28,6	8,6	-26,8	8,4	0,5855	0.18	0.08	-26,4	7,1	0,94 (0,87–0,97)	8,3
	STPro	43,1	9,2	40,0	8,3	1,0000 ^N	0.23	0.1	38,5	8,9	0,96 (0,92–0,98)	10,1
	GHPE	19,6	8,2	16,3	5,6	0,1310	0.52	0.32	1,5	10,2	0,96 (0,93–0,98)	11,9
	GHRot	-3,6	24,0	-17,7	20,9	0,0456	0.74	0.55	-39,5	17,1	0,92 (0,83–0,96)	25,9
	GHEle	-51,4	15,7	-50,4	14,8	0,6953 ^N	0.11	0.06	-58,6	7,8	0,97 (0,94–0,99)	8,7
ER	HTFE	-5,0	12,5	-8,1	9,4	0,2149	0.42	0.22	-20,8	8,2	0,95 (0,91–0,98)	9,2
	HTRot	33,1	29,9	11,5	25,1	0,0040	1.26	0.94	-56,6	9,1	1,00 (0,99–1,00)	11,0
	HTAbAd	-15,3	12,8	-14,4	6,1	0,7767	0.09	0.06	-5,4	7,0	0,96 (0,90–0,98)	6,9
	ABHFE	61,4	19,3	60,7	11,4	1,0000 ^N	0.05	0.05	79,8	12,5	0,93 (0,83–0,97)	16,4
	ABHPS	72,1	31,0	81,8	26,5	0,0942	0.59	0.39	96,3	13,8	0,95 (0,90–0,98)	19,1
	STMed	14,3	9,1	10,9	10,9	0,1300	0.53	0.32	10,1	8,0	0,96 (0,91–0,98)	8,4
	STTilt	-35,2	10,6	-37,0	9,3	0,1879	0.45	0.25	-35,8	7,8	0,88 (0,74–0,94)	9,7
	STPro	26,4	4,4	22,6	7,7	0,1841	0.45	0.25	16,3	9,1	0,97 (0,94–0,99)	8,8
	GHPE	19,7	6,5	20,9	6,6	0,6653	0.14	0.07	13,5	5,8	0,89 (0,89–0,95)	10,1
	GHRot	-8,1	31,0	-25,4	23,8	0,0069	1.13	0.89	-80,0	10,9	0,99 (0,99–1,00)	11,2
	GHEle	-26,8	12,5	-21,7	10,9	0,2751	0.37	0.18	-8,6	7,5	0,97 (0,95–0,99)	8,9
Neck	HTFE	34,9	13,8	31,2	16,1	0,3308	0.32	0.15	45,2	14,7	0,95 (0,89–0,98)	12,7
	HTRot	35,2	24,1	2,0	22,2	0,0004	1.89	1	-38,6	32,6	0,98 (0,95–0,99)	27,0
	HTAbAd	-61,6	37,6	-72,6	29,5	0,0208	1.16	0.9	-90,1	30,2	0,96 (0,93–0,98)	27,2
	ABHFE	127,7	16,6	143,0	9,2	0,0020 ^N	0.71	0.43	151,9	8,1	0,97 (0,94–0,98)	9,2
	ABHPS	69,7	39,0	86,7	42,0	0,1399	0.51	0.3	103,7	17,2	0,95 (0,90–0,98)	25,4
	STMed	-7,5	18,0	-15,4	13,1	0,0191	0.92	0.73	-18,0	11,0	0,95 (0,89–0,97)	12,3
	STTilt	-31,0	14,4	-30,8	9,0	0,9529	0.02	0.05	-28,6	10,2	0,94 (0,88–0,97)	8,8
	STPro	38,6	15,7	34,8	11,0	0,5521	0.19	0.09	35,2	11,3	0,96 (0,89–0,98)	10,7
	GHPE	18,0	8,0	16,2	8,0	0,5684	0.19	0.08	20,3	15,6	0,98 (0,95–0,99)	9,5
	GHRot	-12,6	22,6	-34,2	16,6	0,0040	1.26	0.94	-67,5	17,5	0,95 (0,91–0,98)	22,5
	GHEle	-65,0	25,0	-62,0	20,6	0,3762	0.29	0.13	-81,5	14,4	0,93 (0,87–0,97)	17,1
Spine	HTFE	-26,3	14,8	-26,6	19,4	0,9320	0.03	0.05	-51,9	12,9	0,94 (0,88–0,97)	19,9
	HTRot	84,7	23,6	66,8	36,0	0,0085	1.09	0.86	104,9	15,5	0,97 (0,95–0,99)	19,3
	HTAbAd	-31,7	16,8	-31,4	15,8	0,9113	0.04	0.05	-52,4	24,3	0,87 (0,73–0,94)	29,0
	ABHFE	76,4	46,2	80,7	43,9	0,2960	0.35	0.17	131,5	7,3	0,99 (0,98–0,99)	15,5
	ABHPS	102,6	29,1	105,9	32,2	0,4922 ^N	0.14	0.07	96,3	27,7	0,88 (0,76–0,94)	34,1
	STMed	15,9	14,4	19,1	9,4	0,3694	0.3	0.13	22,3	8,2	0,94 (0,88–0,97)	10,0
	STTilt	-43,5	10,5	-46,4	11,7	0,3788	0.29	0.13	-44,3	8,8	0,87 (0,72–0,94)	13,6
	STPro	33,0	8,0	30,3	14,4	0,6034	0.17	0.08	25,2	11,3	0,93 (0,85–0,96)	16,1
	GHPE	1,6	9,7	0,5	12,9	0,6023	0.17	0.08	-24,1	12,4	0,94 (0,86–0,97)	17,7
	GHRot	29,1	24,5	8,9	25,5	0,0022	1.41	0.98	30,2	20,1	0,96 (0,93–0,98)	21,0
	GHEle	-20,2	17,5	-23,1	17,4	0,3472	0.31	0.14	-11,4	10,2	0,93 (0,86–0,97)	14,6
Mouth	HTFE	32,6	21,0	30,7	16,4	0,5859	0.18	0.08	8,5	13,4	0,95 (0,91–0,98)	13,7
	HTRot	47,6	18,0	38,7	28,6	0,2972	0.35	0.17	41,1	9,9	0,92 (0,84–0,96)	17,0
	HTAbAd	-40,6	35,6	-29,4	28,3	1,0000 ^N	0.35	0.15	-2,7	7,1	0,94 (0,88–0,97)	19,3
	ABHFE	132,1	7,7	136,7	7,9	0,0098 ^N	1	0.78	135,6	7,3	0,92 (0,84–0,96)	7,8
	ABHPS	63,1	35,8	63,2	28,8	0,9924	0.003	0.05	56,8	17,2	0,91 (0,81–0,96)	24,5
	STMed	2,2	20,0	6,9	18,5	0,4622	0.24	0.11	3,8	9,6	0,97 (0,94–0,99)	8,7
	STTilt	-27,1	10,2	-25,0	8,6	0,3565	0.31	0.14	-33,7	7,3	0,90 (0,77–0,95)	11,6
	STPro	41,0	9,1	42,6	10,9	0,6626	0.14	0.07	34,7	9,1	0,95 (0,89–0,97)	12,6
	GHPE	22,8	6,3	22,5	9,5	1,0000 ^N	0.03	0.05	37,5	11,8	0,97 (0,94–0,99)	9,6
	GHRot	-4,3	17,8	-18,6	20,6	0,0121	1	0.81	-3,6	15,3	0,95 (0,90–0,98)	13,9
	GHEle	-57,6	27,4	-55,5	25,3	0,5181	0.21	0.09	-15,4	10,7	0,97 (0,94–0,99)	15,2

* Scapulothoracic: STPro: Protraction (+)/Retraction (-); STMed: Medial (+)/Lateral (-) rotation; STTilt: Anterior (-)/Posterior (+) tilt; Glenohumeral: GHPE: Plane of elevation, GHEle: Elevation; GHRot: Internal (+)/External Rotation (-); Elbow: ABHFE: flexion (+)/extension (-); ABHPS: Pronation (+)/Supination (-); Humerothoracic: HTRot: Internal (+)/External (-) Rotation; HTFE: Flexion (+)/Extension (-); HTAbAd: Abduction (-)/Adduction (+).

presented in Tables 1 and 2. MRI evaluation showed a moderate GH deformity with a mean GV of -10.5° (range, -34 to -1) and a mean PHHA of 0.40 (range, 0.1 to 0.5). After a mean of 10 months postop, active ER improved from a mean of -25° (range, -40 to 0) preop to 14° (range, -20 to 40) post op (P < 0.05). Active global modified Mallet score improved from a mean of 13.7 (range, 12 to 15) preop to 18.5 (range, 16 to 22) post op (P < 0.05).

3.2. Kinematic analysis

3.2.1. Preliminary observations study

3.2.1.1. *Reproducibility.* During reproducibility analysis, ICC were always higher than 0.87 (Table 4). During the analysis of II, angles (ABHFE/Hand to Mouth; STTilt/Neck, Spine, ER; HTAbAd/Spine; ABHPS/Spine) with poor or fair Kappa values for TN were not studied.

Table 5

Index of Improvement for each angle*: Mean values, standard deviation and repartition of patients by values of II from -100 to +100 by step of 25 (-100 -75 -50 -25 0 25 50 75 100).

		HTFE	HTRot	HTAbAd	ABHFE	ABHPS	STMed	STTilt	STPro	GHPE	GHRot	GHEle
Abduction	Mean	2.5	50	30	-2.5	15	-10	0	10	15	42.5	-2.5
	Standard deviation	14.2	44.1	46.8	18.4	33.7	31.6	47.1	31.6	39.4	61.3	69.2
	Repartition of patients											
ER	Mean	17.5	35	22.5	-2.5	10	-7.5		0	-17.5	27.5	12.5
	Standard deviation	42.6	26.9	44.8	29.9	39.4	23.7		0	51.4	32.2	58
	Repartition of patients											
Neck	Mean	-2.5	50	25	67.5	27.5	15		12.5	0	27.5	-10
	Standard deviation	41.6	45.6	40.8	37.4	57.1	58		27	0	54.6	35.7
	Repartition of patients											
Spine	Mean	12.5	-30		12.5		17.5		-17.5	10	-20	-7.5
	Standard deviation	44.5	32.9		44.5		44.2		37.4	37.6	36.9	35.5
	Repartition of patients											
Mouth	Mean	20	-15	2.5		0	17.5	-5	-15	-20	-20	5
	Standard deviation	38.7	73.8	59.5		51.4	48.7	49.7	31.6	42.2	42.2	25.8
	Repartition of patients											

* Scapulothoracic: STPro: Protraction (+)/Retraction (-); STMed: Medial (+)/Lateral (-) rotation; STTilt: Anterior (-)/Posterior (+) tilt; Glenohumeral: GHPE: Plane of elevation, GHEle: Elevation; GHRot: Internal (+)/External Rotation (-); Elbow: ABHFE: flexion (+)/extension (-); ABHPS: Pronation (+)/Supination (-); Humerothoracic: HTRot: Internal (+)/External (-) Rotation; HTFE: Flexion (+)/Extension (-); HTAbAd: Abduction (-)/Adduction (+).

Table 6

INPatientTask values (the mean of II of all the reproducible angles) for each patient and each task.

Patients	Abduction	Hand to Mouth	Neck	Spine	ER
S1	23	0	28	-28	-10
S2	5	33	5	9	25
S3	34	-20	28	-3	8
S4	14	8	33	-6	0
S5	14	15	10	-6	13
S6	16	-30	53	-3	33
S7	5	-15	25	25	8
S8	30	23	18	-13	23
S9	2	-28	15	-3	-10
S10	-5	-15	0	0	10

3.2.1.2. Prior examination of external rotation. As improvement of external rotation is one of the most important expected effects of the LD transfer, it first can be relevant to focus on this angle and to examine during the different tasks, in which joints it will occur (GH or HT), its direction (internal or external) and its range for non-involved arms.

Database values (Table 4) showed that the external rotation was observed principally for two tasks: ER task (GHRot = -80° (SD 10.9); HTRot = -56.6° (SD 9.1)) and Neck task (GHRot = -67.5° (SD 17.5); HTRot = -38.6° (SD 32.6)). An external rotation of GH was also observed for the Abduction task (GHRot = -39.5° (SD 17.1)). An internal rotation was observed for the Spine task (HTRot = 104.9° (SD 15.5); GHRot = 30.2° (SD 20.1) and the Hand to Mouth task (HTRot = 41.1° (SD 9.9)).

It can be also relevant to examine the Preop angles in regard with the database. For the tasks ER, Neck and Abduction, HTRot and GHRot were always outside the corridor of the database (TN = -1) for five subjects (S1, S3, S4, S6, S7) and always inside the corridor (TN = 1) for one subject (S9). For the other subjects, those angles were always outside the corridor for ER but they were sometimes inside the corridor for the Neck task or/and the Abduction task.

3.2.2. Effect of the LD transfer

Results of global kinematic evaluation are depicted in Table 4. For each angle that have a reproducible TN, the mean values and the repartition of the patient for each value of the Index of Improvement are presented in Table 5. For each task, INPatientTask is presented in Table 6. Finally, for each subject, a synthesis of II is presented in Fig. 1 for each angle and each task. For each task, we first compared the results obtained for the whole group 3 in preop and postop, and we secondly analyse the Index of Improvement and the INPatientTask.

3.2.2.1. ER task. As expected, the LD transfer significantly improved the HT external rotation (HTRot; difference in averages preop/postop = -21.6°) as well as the GH external rotation (GHRot; difference in averages preop/postop = -17.2°). The other kinematic parameters were not significantly influenced by the surgery. Using II, an improvement of HTRot was observed in 8 patients and of GHRot in 7 patients. II never obtained the maximum of 100 ($II \leq 50$). A slightly worsening was observed for HTRot and GHRot in S2 and for GHRot in S5. No change occurred for the other patients.

Considering INPatientTask, an improvement occurred in 7 patients with a worsening in 2.

3.2.2.2. Hand to Neck task. Postop HT external rotation improved during this task (HTRot; difference in average preop/postop = -33.2°) as well as the GH joint (GHRot; difference in average preop/postop = -21.6°). Humerothoracic abduction also improved post-operatively (HTAbAd; difference in averages preop/postop = -11°). The ST joint significantly modified its final position with an increased lateral rotation (STMed; difference in averages preop/postop = -7.9°). Elbow flexion also increased after the LD transfer (ABHFE; difference in

averages preop/postop = 15.4°) even if the power of the test is limited (0.43). Using II, HTRot improved for 6 patients ($II = 100$ for S3, S5, S6) and did not worsen. GHRot improved for 6 patients ($II = 100$ for S3 and S6) and a worsening occurred for S5 and S10. STMed improved for 3 patients (S5 ($II = 100$), S6 and S10 ($II = 100$)) for which STMed was more medial than the database in preop and worsened in one patient (S2) that was more lateral than the database in preop. HTAbAd improved for 3 patients (S1, S6 ($II = 100$) and S9) and did not change for the others. ABHFE improved for 9 patients ($II = 100$ for S2, S6, S4, S7) and did not change for S10.

Considering INPatientTask, an improvement occurred in 9 patients with no worsening.

3.2.2.3. Abduction task. The LD transfer significantly improved the HT external rotation (HTRot; difference in averages preop/postop = -23.1°) and the GH joint external rotation (GHRot; difference in averages preop/postop = -14.1°). The HT abduction was also improved (HTAbAd; difference in averages preop/postop = -9.1°). The power of the test for GHRot was limited (0.55).

Using II, HTRot improved in 8 patients ($II = 100$ for S1, S2, S3, S5) and did not change for the others. GHRot improved in 6 patients ($II = 100$ for S1, S2, S3, S7) and worsened for S8. HTAbAd improved in 5 patients ($II = 100$ for S3, S8) and slightly ($II = -25$) worsened in 2 patients.

Considering INPatientTask, an improvement occurred in 9 patients with a worsening in 1.

3.2.2.4. Hand to Mouth task. GH joint external rotation significantly worsened (GHRot; difference in averages preop/postop = -14.2°) and elbow flexion slightly improved (ABHFE; difference in averages preop/postop = 4.3°).

Using II, GHRot worsened in 2 cases (S3 and S9) and did not change for the other patients.

Considering INPatientTask, a worsening occurred in 5 patients with an improvement in 4.

3.2.2.5. Hand to Spine task. The LD transfer significantly worsened the HT medial rotation (HTRot; difference in averages preop/postop = -20.2°) and the GH joint medial rotation (GHRot; difference in averages preop/postop = -17.9°).

Using II, a worsening was observed for HTRot in 6 patients ($II = -100$ for S1) and for GHRot in 3 patients ($II = -100$ for S6) and did not change for the others.

Considering INPatientTask, a worsening occurred in 7 patients with an improvement in 2.

3.3. Correlation with clinical scores

No correlation was observed between the variation of the Mallet scores and Narakas scores. On the contrary, with an increase of Narakas score, an increase of II was observed for GHELe during the Neck task ($P = 0.01$) and less significantly during the Abduction tasks ($P = 0.06$), and for HTAbAd during the Neck task ($P = 0.06$). A decrease of INPatientTask was observed during ER task with an increase of Narakas score ($P = 0.04$).

An increase of II was observed for ABHPS during the Abduction task with an increase of the anatomical pathology (PHHA ($P = 1e-4$), HHS ($P = 0.04$), Glenoid retroversion ($P = 0.03$)) and during the Neck task with an increase of the retroversion ($P = 9e-4$). The values of ABHPS showed an increase of the pronation.

With an increase of HHS, an increase of II was also observed for HTAbAd during the Hand to Mouth task ($P = 0.02$) and a decreased was observed for STMed during ER task ($P = 0.04$).

When a first surgery was made, II decreased for ABHPS during the Neck task ($P = 0.003$) and ER task ($P = 0.01$), for HTFE during the Spine

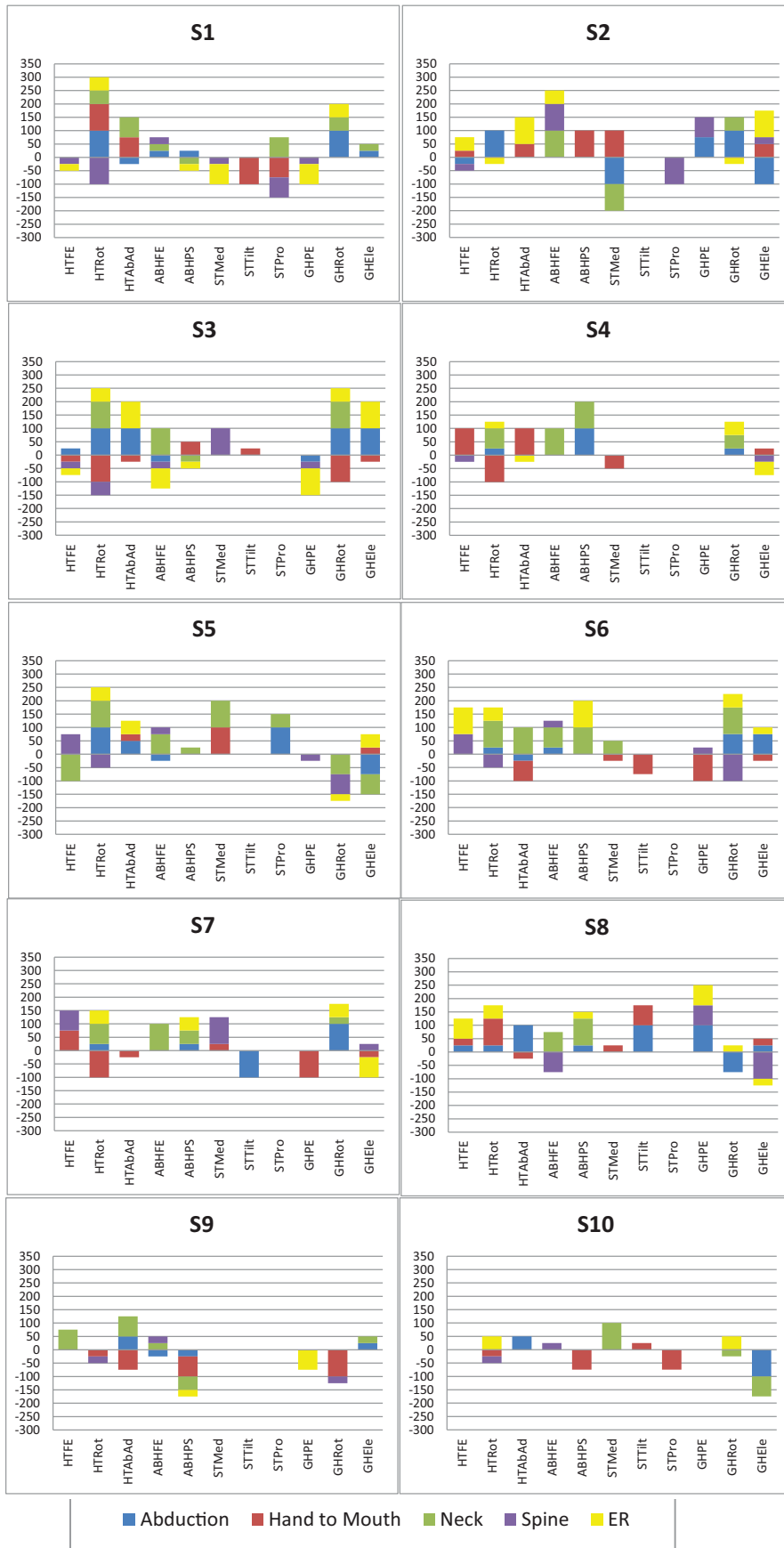


Fig. 1. The Index of Improvement (II) for all the angles and all the tasks for all the subjects.

task ($P=0.05$) and for GHPE during ER ($P=0.01$). There is an increasing of II for GHEle during the Neck Task ($P=0.04$).

A correlation was observed between II and the age of surgery in the ER task for HTAbAd ($P=0.03$).

INPatientTask also increased with the impairment of PHHA during the Neck task ($P=0.05$).

No correlation was observed between the clinical parameters and II for HTRot or GHRot during the different tasks.

4. Discussion

To manage shoulder internal rotation contractures in BPBP, numerous surgical strategies have been proposed with the common goal to restore the axial balance of the GH joint. The goal of treatments is therefore to improve the GH external rotation, and to limit the GH dysplasia and humeral head posterior subluxation occurrence by rebalancing forces around the GH joint. These procedures most commonly involve weakening of the internal rotator muscles and strengthening of the external rotators (Hale et al., 2010). Since the LD muscle transfer to the infraspinatus muscle satisfies both objectives, it was therefore our choice of transfer (Kozin et al., 2010; Pearl et al., 2006; Waters and Bae, 2008; Werthel et al., 2018).

This is the first report to our knowledge about upper limb kinematic assessment after LD transfer to the infraspinatus muscle for BPBP sequelae. We analysed the final angular positions of the bones in the pre- and post-operative situations and compared them to the control group. Significant changes occurred during all the Mallet's tasks, mainly with HT and GH external rotation improvement as expected. However, post op mean kinematic values of those angles never reached the control group values during ER task. Furthermore, HT and GH medial rotation worsened during the "hand to spine task" and GH worsened during the "hand to mouth task" without compensation mechanism in ST joint. The ST Medial-Lateral angle was significantly modified during the "hand to neck" task as the tip of the scapula better rotates outwards over the chest wall leading the glenoid to face more superiorly and, subsequently, improving the range of HT abduction. The LD transfer seems therefore to act not only on the GH joint but also on the ST joint during the "hand to neck" Mallet's task, improving the ST compensation mechanism for the GH joint limitation. Nevertheless, it was not the case for Abduction or Hand to Mouth task.

Elbow flexion was also improved postoperatively during "hand to mouth" and "hand to neck" tasks. The explanation may be that better positioning of the GH joint in external rotation may have improved the lever arm of the long biceps muscle, increasing its strength. Even if the number of studied patients was limited to ten, the power of the test for parameters that were significantly different was higher than 0.8 for the majority of cases (10 cases on 14), and was lower than 0.7 only in two cases.

Analysing only the mean values in preop and postop is not sufficient because it does not take into account the reproducibility of the measure of the angles nor the mean value and the standard deviation of angles of the database. Then, for each patient, each angle and each task we defined an Index of Improvement in order to try to better analyse the improvement of the position of bones taking into account those parameters and also the values of the angles in preop and postop. We did not find any such index in the literature. The reproducibility analysis was performed on a group of 32 arms, including involved arms and non-involved arms, each arm being equally represented. This choice was done to better characterize the reproducibility of our population that could have angles near a non-involved arm or near an involved arm.

Thanks to this index, we can quickly analyse, for a given patient, which angle was improved or worsened and for which task. Nevertheless, to analyse the direction of the modification of the angle it is necessary to come back to the angles values. We observed that the influence of the operation was not equivalent between the patients. To better understand the reason of that, we analysed the correlation

between the clinical parameters and II or INPatientTask. We found that the improvement or worsening of some angles correlated with some clinical parameters. In particular, we observed that an increase of II occurred for ABHPS during the Abduction and the Neck task with an increase of some anatomical pathologies. The interpretation could be that patients with more severe joint deformities used compensatory mechanism with increased forearm supination to act against the shoulder external rotation deficit. With the postop improvement of external rotation, the forearm increases its pronation.

The clinical evaluation showed a significant improvement of the global Mallet's score. The kinematic evaluation was generally less favorable in particular for the hand to mouth and the hand to spine tasks.

When analysing the angles of external rotation in preop, one patient was always inside the corridor of the database and few improvement was observed for this patient. To decide if one patient has to be operated, active ER1 measured clinically was used. It could be certainly interesting to use also the kinematics evaluation before operating a patient in order to better analyse in preop on which angle the operation has to act.

We preferred to analyse in the present study the relative angular position between bones at the final position of the arm and not the angular variation between the initial position and the final position (Herisson et al., 2017), to be more coherent to Mallet scores which are based on final position of arm. Nevertheless, to complete these data, it could be also interesting to analyse the initial position of the bones and the range of motion between initial and final position of bones.

The database has been build using the non-involved arm of BPBP patients instead of healthy population for practical reasons, assuming that the contralateral arm of children with unilateral BPBP can be used as a control (Mayfield et al., 2017; Wang et al., 2007).

We analysed the effect of the operation on a small group of ten patients who were not homogeneous in term of primary nerve surgery, palsy or deformity of the bone. It would be useful to increase the number of studied patients to confirm the results of this study, to better analyse the effect of the LD transfer on BPBP for different groups of patients and to better analyse the correlation between the clinical parameters and the Index of Improvement. It would be also interesting to better analyse the effect of releasing the subscapularis muscle in particular on HTRot and GHRot during the Spine and Mouth tasks. Indeed, the release of the subscapularis muscle involves weakness of the muscle. This release in association with the improving power of the external rotator's muscles due to the LD transfer could explain the worsening of those angles for those two tasks in some patients. Further work should be performed to confirm this assumption. Finally, it would be also interesting to complete this work by a statistical study to analyse a between session repeatability of the Index of Improvement.

5. Conclusion

Thanks to this study, for the first time to our knowledge, quantified information is provided on the upper limb kinematic modifications after a latissimus dorsi tendon transfer during the Mallet tasks in BPBP children. A specific Index of Improvement taking into account the reproducibility of the angle and the database values was also proposed to better analyse, for each patient, the improvement or the worsening of angular positions.

Declaration of Competing Interest

None.

Acknowledgement

Dr. Nataly Quintero of the Physical Medicine and Rehabilitation Department, Hôpitaux de Saint-Maurice, France.

References

- Abzug, J.M., Chafetz, R.S., Gaughan, J.P., Ashworth, S., Kozin, S.H., 2010. Shoulder function after medial approach and derotational humeral osteotomy in patients with brachial plexus birth palsy. *J. Pediatr. Orthop.* 30 (5), 469–474.
- Bahm, J., 2016. Upper limb multifactorial movement analysis in brachial plexus birth injury. *J. Brachial. Plexus Peripher Nerve Inj.* 11 (1), 1–9.
- Bialocerkowski, A.E., Wrigley, T., Galea, M., 2006. Reliability of the V-scope system in the measurement of arm movement in children with obstetric brachial plexus palsy. *Dev. Med. Child Neurol.* 48 (11), 913–917.
- Curtis, C., Stephens, D., Clarke, H.M., Andrews, D., 2002. The active movement scale: an evaluative tool for infants with obstetrical brachial plexus palsy. *J. Hand Surg.* 27 (3), 470–478.
- Duff, S.V., Dayanidhi, S., Kozin, S.H., 2007. Asymmetrical shoulder kinematics in children with brachial plexus birth palsy. *Clin. Biomech.* 22 (6), 630–638.
- El-Gammal, T.A., Saleh, W.R., El-Sayed, A., Kotb, M.M., Imam, H.M., Fathi, N.A., 2006. Tendon transfer around the shoulder in obstetric brachial plexus paralysis: clinical and computed tomographic study. *J. Pediatr. Orthop.* 26 (5), 641–646.
- Fitoussi, F., Maurel, N., Diop, A., Laassel, E.M., Ihharborde, B., Presedo, A., 2009. Upper extremity kinematics analysis in obstetrical brachial plexus palsy. *Orthop. Traumatol. Surg. Res.* 95 (5), 336–342.
- Foad, S.L., Mehlman, C.T., Ying, J., 2008. The epidemiology of neonatal brachial plexus palsy in the United States. *J. Bone Joint Surg. Am.* 90 (6), 1258–1264.
- Hale, H.B., Bae, D.S., Waters, P.M., 2010. Current concepts in the management of brachial plexus birth palsy. *J. Hand. Surg. [Am.]* 35 (2), 322–331.
- Herisson, O., Maurel, N., Diop, A., Le Chatelier, M., Cambon-Binder, A., Fitoussi, F., 2017. Shoulder and elbow kinematics during the Mallet score in obstetrical brachial plexus palsy. *Clin. Biomech.* 43, 1–7.
- Kozin, S.H., Chafetz, R.S., Shaffer, A., Soldado, F., Filipone, L., 2010. Magnetic resonance imaging and clinical findings before and after tendon transfers about the shoulder in children with residual brachial plexus birth palsy: a 3-year follow-up study. *J. Pediatr. Orthop.* 30 (2), 154–160.
- Mahon, J., Malone, A., Kiernan, D., Meldrum, D., 2018. Kinematic differences between children with obstetric brachial plexus palsy and healthy controls while performing activities of daily living. *Clin. Biomech.* 59, 143–151.
- Mallet, J., 1972. Obstetrical paralysis of the brachial plexus. II. Therapeutics. Treatment of sequelae. Results of different therapeutic technics and indications. *Rev. Chir. Orthopédique Réparatrice Appar. Mot.* 1, 192–196.
- Maurel, N., Diop, A., Gouelle, A., Alberti, C., Husson, I., 2013. Assessment of upper limb function in young Friedreich ataxia patients compared to control subjects using a new three-dimensional kinematic protocol. *Clin. Biomech.* 28 (4), 386–394.
- Mayfield, C.H., Kukke, S.N., Brochard, S., Stanley, C.J., Alter, K.E., Damiano, D.L., 2017. Inter-joint coordination analysis of reach-to-grasp kinematics in children and adolescents with obstetrical brachial plexus palsy. *Clin. Biomech.* 46, 15–22.
- Mosqueda, T., James, M.A., Petuskey, K., Bagley, A., Abdala, E., Rab, G., 2004. Kinematic assessment of the upper extremity in brachial plexus birth palsy. *J. Pediatr. Orthop.* 24 (6), 695–699.
- Narakas, A.O., 1987. Injuries of the brachial plexus and neighboring peripheral nerves in vertebral fractures and other trauma of the cervical spine [Article in German]. *Orthopade.* 16 (1), 81–86.
- Pearl, M.L., Edgerton, B.W., Kazimirroff, P.A., Burchette, R.J., Wong, K., 2006. Arthroscopic release and latissimus dorsi transfer for shoulder internal rotation contractures and glenohumeral deformity secondary to brachial plexus birth palsy. *J. Bone Joint Am.* 88 (3), 564–574.
- Pecoraro, F., Mazza, C., Capozzo, A., Thomas, E.E., Macaluso, A., 2007. Reliability of the intrinsic and extrinsic patterns of level walking in older women. *Gait Posture* 26, 386–392.
- Russo, S.A., Kozin, S.H., Zlotolow, D.A., Thomas, K.F., Hulbert, R.L., Mattson, J.M., 2014. Scapulothoracic and glenohumeral contributions to motion in children with brachial plexus birth palsy. *J. Shoulder Elb. Surg.* 23 (3), 327–338.
- Russo, S.A., Killelea, C.M., Zlotolow, D.A., Kozin, S.H., Rodriguez, L.M., Chafetz, R.S., 2019a. scapular stabilization limits glenohumeral stretching in children with brachial plexus injuries. *J. Hand Surg. USA* 44 (1), 63.e1–63.e9.
- Russo, S.A., Kozin, S.H., Zlotolow, D.A., Nicholson, K.F., Richards, J.G., 2019b. Motion necessary to achieve mallet internal rotation positions in children with brachial plexus birth palsy. *J. Pediatr. Orthop.* 39 (1), 14–21.
- Wang, J.S., Petuskey, K., Bagley, A.M., James, M.A., Rab, G., 2007. The contralateral unimpaired arm as a control for upper extremity kinematic analysis in children with brachial plexus birth palsy. *J. Pediatr. Orthop.* 27 (6), 709–711.
- Waters, P.M., 2011. Pediatric brachial plexus palsy. In: Wolfe, S.W. (Ed.), *Green's Operative Hand Surgery*, 6th ed. Elsevier Churchill Livingstone, Philadelphia, pp. 1235–1481.
- Waters, P.M., Bae, D.S., 2008. The early effects of tendon transfers and open capsulorrhaphy on glenohumeral deformity in brachial plexus birth palsy. *J. Bone Jt Surg. Ser. A.* 90 (10), 2171–2179.
- Waters, P.M., Smith, G.R., Jaramillo, D., 1998. Glenohumeral deformity secondary to brachial plexus birth palsy. *J. Bone Joint Am.* 80 (5), 668–677.
- Weir, J.P., 2005. Quantifying test-retest reliability using the intraclass correlation coefficient and the SEM. *J. Strength Cond. Res.* 19 (1), 231–240.
- Werthel, J.D., Wagner, E.R., Elhassan, B.T., 2018. Long-term results of latissimus dorsi transfer for internal rotation contracture of the shoulder in patients with obstetric brachial plexus injury. *JSES Open Access* 2 (3), 159–164.
- Wu, G., Helm, F.C.T., Veeger, H.E.J.D., Makhsous, M., Van Roy, P., Anglin, C., 2005. ISB recommendation on definitions of joint coordinate systems of various joints for the reporting of human joint motion—Part II: shoulder, elbow, wrist and hand. *J. Biomech.* 38 (5), 981–992.