



### **Science Arts & Métiers (SAM)**

is an open access repository that collects the work of Arts et Métiers Institute of Technology researchers and makes it freely available over the web where possible.

This is an author-deposited version published in: <https://sam.ensam.eu>  
Handle ID: <http://hdl.handle.net/10985/21558>

#### **To cite this version :**


Emmanuelle FERRERO, Pierre GUIGUI, Marc KHALIFÉ, Robert CARLIER, Antoine FEYDY, Adrien FELTER, Virginie LAFAGE, Wafa SKALLI - Global alignment taking into account the cervical spine with odontoid hip axis angle (OD-HA) - European Spine Journal - Vol. 30, n°12, p.3647-3655 - 2021

Any correspondence concerning this service should be sent to the repository

Administrator : [scienceouverte@ensam.eu](mailto:scienceouverte@ensam.eu)



# Global alignment taking into account the cervical spine with odontoid hip axis angle (OD-HA)

Emmanuelle Ferrero<sup>1,2</sup>  · Pierre Guigui<sup>1</sup> · Marc Khalife<sup>1</sup> · Robert Carlier<sup>4</sup> · Antoine Feydy<sup>5</sup> · Adrien Felter<sup>4</sup> · Virginie Lafage<sup>3</sup> · Wafa Skalli<sup>2</sup>

## Abstract

**Introduction** Global alignment analysis is of utmost importance in adult spinal deformity patients (ASD). Numerous parameters exist in the literature to measure global alignment based upon C7 or T1. One common limitation of these parameters is that they neglect the cervical segment which is essential in spinal compensatory mechanisms and in horizontal gaze preservation. A recent stereoradiography analysis of asymptomatic subjects introduced a new 3D parameter (ODHA), defined as the angle between the vertical reference line and the line joining the odontoid tip (OD) to hip axis center (HA). Thus, the goal of this study was to analyze 3D global alignment of ASD patients using the new parameter odontoid hip axis angle and its relationship to other spinal parameters.

**Methods** In this prospective study, 90 adult patients with lumbar scoliosis (Cobb > 20°) were included. All subjects underwent low dose biplanar X-rays with 3D spinal reconstructions. Based on published normative values of ODHA, we defined abnormally high value as mean ODHA of asymptomatic subject + 2SD (i.e., ODHA > 6.1°). Values of 3D radiographic parameters and ODI were compared between patients with ODHA > 6.1° and < 6.1°.

**Results** Mean ODHA was 5+/- 3.6° (0.4° to 18.6°). 22 patients had abnormally high ODHA. They were older than the 68 other patients (68+/- 9y vs 53+/- 14y,  $p=0.001$ ), without any significant difference in terms of sex, BMI and rate of rotatory subluxation (54% vs 62%,  $p=0.06$ ). However, coronal and sagittal deformity was more important in patients with abnormal ODHA (larger Cobb angle, coronal malalignment, pelvic tilt and lower lumbar lordosis). Patients with abnormal ODHA had significantly worst ODI (50+/- 23 vs 30+/- 18,  $p=0.0005$ ).

**Conclusion** Extreme values of ODHA are observed in significantly older patients with significant functional impairment. In addition, in these patients with sagittal malalignment with loss of lumbar lordosis, who recruit compensatory mechanisms such as pelvic retroversion, the cervical area is also involved with a posture in cervical hyperlordosis to maintain the head over the pelvis. Thus, ODHA is an interesting parameter allowing a more comprehensive alignment measurement taking into account the mechanisms of compensation of the cervical spine to the pelvis.

**Keywords** Sagittal alignment · Spinal balance · Odontoid · Stereoradiography · Spino-pelvic parameters

---

✉ Emmanuelle Ferrero  
emmanuelle.ferrero@aphp.fr

<sup>1</sup> Department of Orthopaedic Surgery, Hopital Européen Georges Pompidou, APHP, Paris V University, 20 rue Leblanc, 75015 Paris, France

<sup>2</sup> Laboratoire de biomecanique Georges Charpak, Ecole nationale supérieure des arts et métiers, 75013 Paris, France

<sup>3</sup> SpineLab, Department of Orthopaedic Surgery, Hospital for Special Surgery, New York, NY, USA

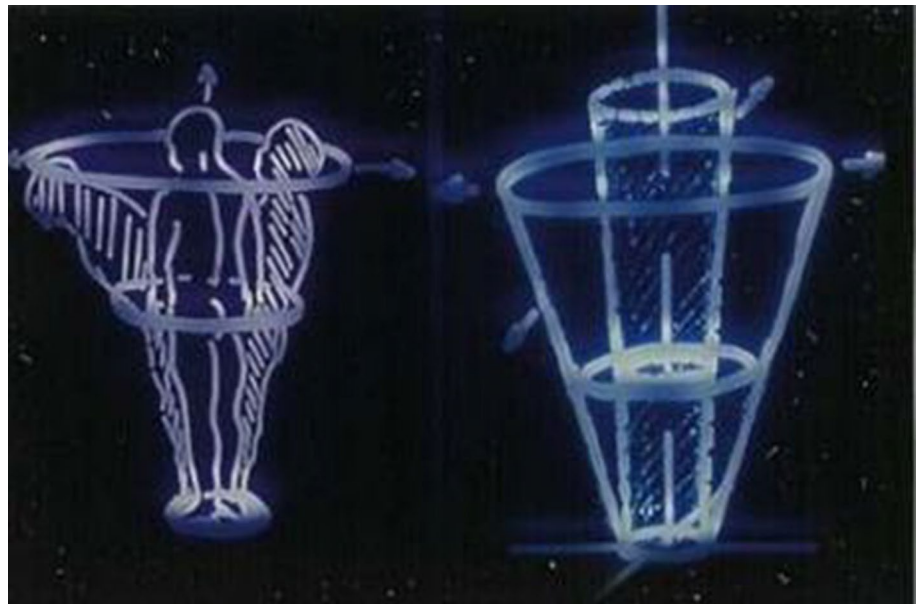
<sup>4</sup> Department of Radiology, Hopital de Garches, APHP, Garches, France

<sup>5</sup> Department of Radiology, Hopital Cochin, APHP, Paris V University, Paris, France

## Introduction

In a balanced posture, head is located above pelvis in both coronal and sagittal planes. Dubousset introduced the concept of “conus of economy” to describe the ideal position of body gravity center (Fig. 1) [1]. When body gravity center is outside of this stability zone, several compensatory mechanisms are recruited in spine, pelvis and lower limbs to correct alignment. Most commonly on radiographs, C7-body center is used as a reference point to analyze global spine alignment, although it is different from body gravity center [2–5]. Several studies highlighted importance of global

**Fig. 1** Conus of economy (J. Dubousset)



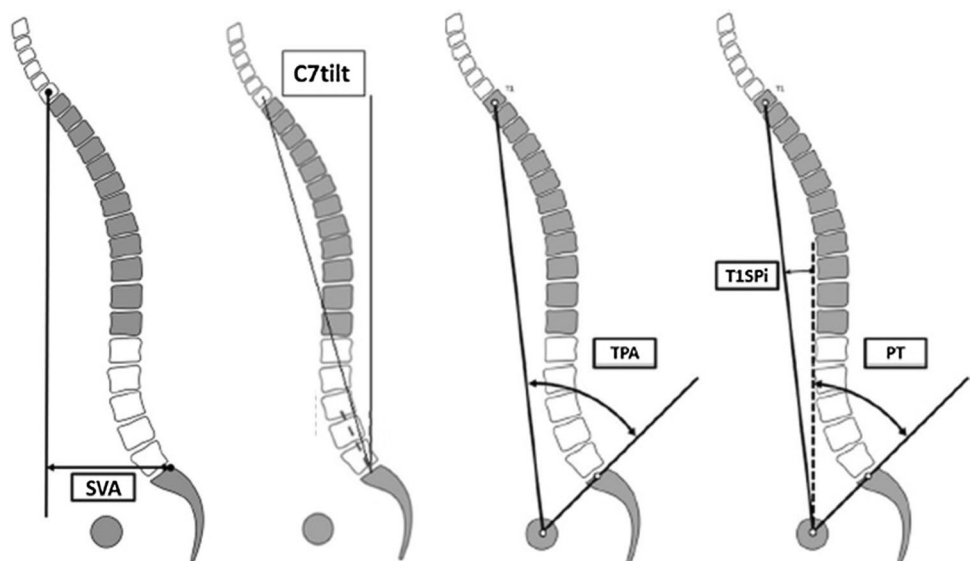
alignment analysis in adult spinal deformity patients (ASD) and the poor outcomes in cases of sagittal malalignment [3–9].

Many studies analyzed global spinal sagittal alignment using different parameters with C7 or T1 vertebra as a reference point: C7 sagittal tilt (C7 tilt), T1 spino-pelvic inclination (T1SpI), sagittal vertical axis (SVA), T1 pelvic angle (TPA) (Fig. 2) [4, 6–9]. Significant correlations were found between these parameters and patients' functional outcomes, highlighting the importance of sagittal analysis in spinal deformity [10–13]. Nevertheless, these parameters have certain limitations. SVA, for example, measuring the offset of C7 relative to the sacral endplate, is influenced by height. Moreover, it is measured in mm and is therefore difficult

to use in multicenter studies with unscaled X-rays. Other parameters, such as TPA, are composite and if they take into account the compensatory mechanisms, they require a more complex analysis.

During the past two decades, several studies have sought to investigate sagittal spino-pelvic alignment from C7 or T1 vertebrae, but only five studies analyzed overall alignment with the position of superior cervical spine or head [4, 14–17]. However, head position is essential to maintain a horizontal gaze, and modification of the cephalic position is made possible by an upper and lower cervical spine alignment change. In addition, none of these five studies included scoliotic patients [17–21]. With the development of full-body X-rays, with low-dose stereoradiography, fullspine

**Fig. 2** Global spinal sagittal alignment parameters: SVA, C7 tilt, TPA, T1SpI



analysis including cervical spine, head and lower limbs is possible. With this system, Amabile et al. recently described a new angle, close to the head center of mass: odontoid hip axis angle (ODHA, angle between the vertical reference line and the line joining the odontoid tip (OD) to the hip axis center (HA)). They demonstrated that ODHA was almost invariant in asymptomatic young and elderly subjects [18, 19, 22]. Similarly, Attali et al. analyzed spinal alignment during inspiration and expiration [17]. They observed variations in cervical alignment and pelvic tilt without significant change in ODHA angle.

Thus, the goal of this study was to analyze 3D global alignment of ASD patients using the new parameter odontoid hip axis angle and its relationship to other spinal parameters.

## Methods

### Studies and patients

Patients with adult lumbar scoliosis were consecutively included between 2014 and 2017 after approval by the local ethics committees of two centers. It was either an old idiopathic scoliosis or a degenerative scoliosis (which appeared on a previously aligned spine), with a minimum Cobb angle of 20°. Patients with history of spinal surgery or with another cause for scoliosis and with cervical pathology were excluded. Patients' outcomes were recorded through Visual Analog Scale (VAS) and Oswestry Disability Index (ODI) [23, 24].

### Radiographic acquisition

All patients had radiographs from skull to femoral heads, with a low dose stereoradiography system (EOS imaging, Paris, France) [25]. The radiographic acquisition was performed according to a standardized protocol: free-standing position, horizontal gaze and hand on clavicles or cheekbones to avoid arms and spine superimposition [26].

From biplanar radiographic acquisitions, a patient-specific 3D model was reconstructed using a validated software, including the spine from C2 to S1, and the pelvis [27]. The two femoral heads were also reconstructed to obtain the bicoxo-femoral axis.

### Parameters

The usual demographic parameters were collected (age, sex and body mass index).

Sagittal radiographic parameters included the three pelvic parameters: pelvic incidence (PI), pelvic tilt (PT) and sacral slope (SS). The following spinal parameters were measured:

lumbar lordosis (L1S1), thoracic kyphosis (T1T12), cervical lordosis (C3C7). Global alignment was evaluated by SVA, T1SpI and ODHA (Fig. 2). ODHA was the angle measured between the vertical reference line and line joining the odontoid tip to the hip axis center in the 3D patients' geometric landmark (Figs. 3 and 4). Main curvature Cobb angle was measured. Rotatory subluxations, which are an axial rotation between two vertebrae associated with a lateral listhesis greater than 5 mm, were recorded [28]. Coronal imbalance was measured in cm between C7 vertical line and the sacral endplate center (CC7PL).

### Statistical analysis

Statistical analysis was performed with Stata 15.0 software (Statacorp LP, Lakeway Drive, College Station, Texas). First, a descriptive analysis of all series parameters was performed. The distribution and range of global alignment parameters were studied. Secondly, global sagittal alignment

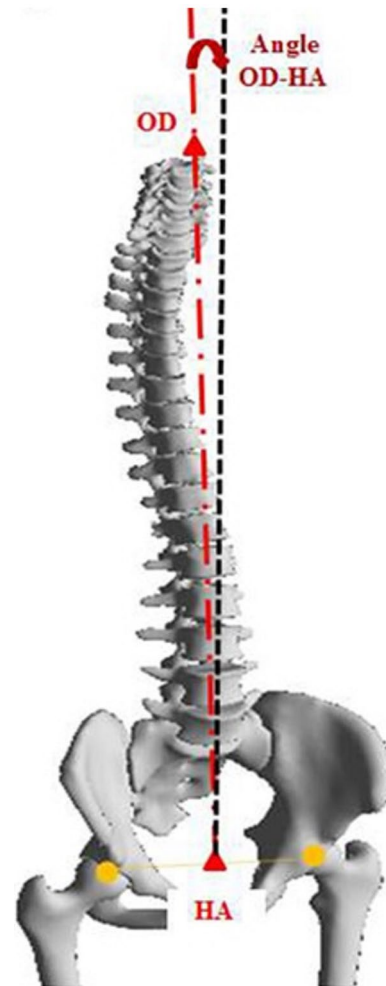
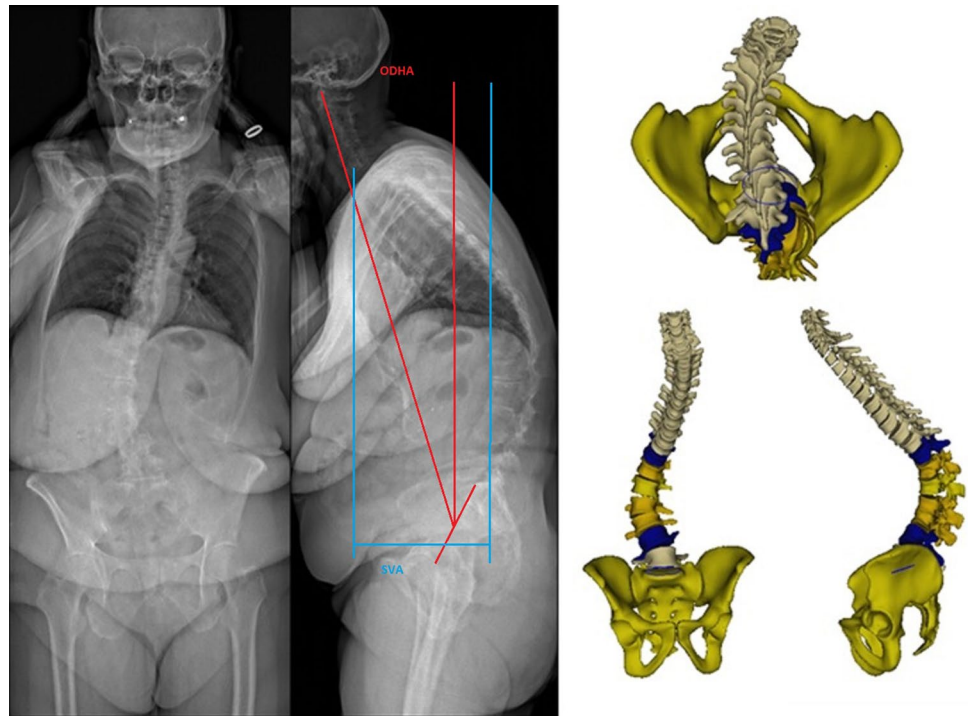


Fig. 3 Odontoid (OD) and the center of the hip axis (HA) angle (ODHA)

**Fig. 4** Coronal and sagittal X-rays and 3D reconstructions of a patient with a large anterior tilt: ODHA 13.7°, T1SpI 9.7°, SVA 146 mm, LL 10°, PT 30°, PI 47°, cervical lordosis 44° and SVA and ODHA measurements



parameters of the patients were compared to those of asymptomatic subjects. The average values used were those of previous studies on non-deformity patients for ODHA ( $2.9 \pm 1.6^\circ$ ) and for T1SpI ( $-1.35 \pm 2.7^\circ$ ) [4, 18]. In order to better characterize the global alignment of our patients, a parameter was defined as “normal” if its value was between plus or minus one standard deviation (SD) from the control subjects means; “Subnormal high” between +1SD and +2SD, “subnormal low” between -1SD and -2SD, “abnormal high” beyond 2SD and “abnormal low” below 2SD. Based on this analysis, we compared patients' radiographic and clinical parameters with an “abnormal high” ODHA value to the rest of the cohort. Finally, correlations between the different parameters were analyzed. P values lower than 0.05 were considered significant.

## Results

### Demographic data

Ninety patients were included with a majority of women ( $n=79$ , 88%). Mean age was  $56 \pm 19$  years, and mean BMI was  $24 \pm 4$  kg/m<sup>2</sup>. Mean VAS was  $4.9 \pm 2.5$  ( $n=65$ ), and mean ODI was  $35 \pm 21$  ( $n=41$ ).

### Radiographic data

Radiographic parameters are reported in Table 1. Rotatory subluxations were present in 54 of the 90 patients (most

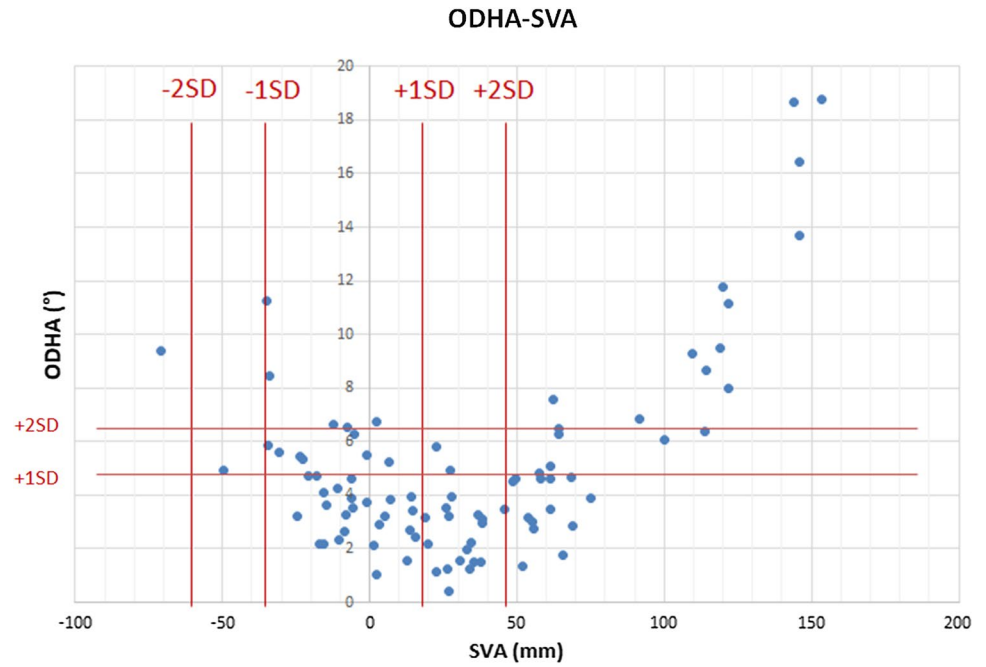
**Table 1** Mean values of radiographic parameters in the cohort ( $n=90$ )

	Mean	SD	Minimum	Maximum
Cobb angle (°)	39	15	20	81
CC7PL (mm)	20	17	0	79
Pelvic incidence (°)	54	13	20	84
Pelvic tilt (°)	20	11	-16	52
Sacral slope (°)	34	11	13	60
L1S1 (°)	48	18	-11	89
T1T12 (°)	41	18	2	115
C3C7 (°)	14	18	-29	69
PI-LL (°)	5	17	-41	52
T1SpI (°)	2.2	5.6	-12.8	18
SVA (mm)	33	48	-71	153
ODHA (°)	5	3.6	0.4	18.8

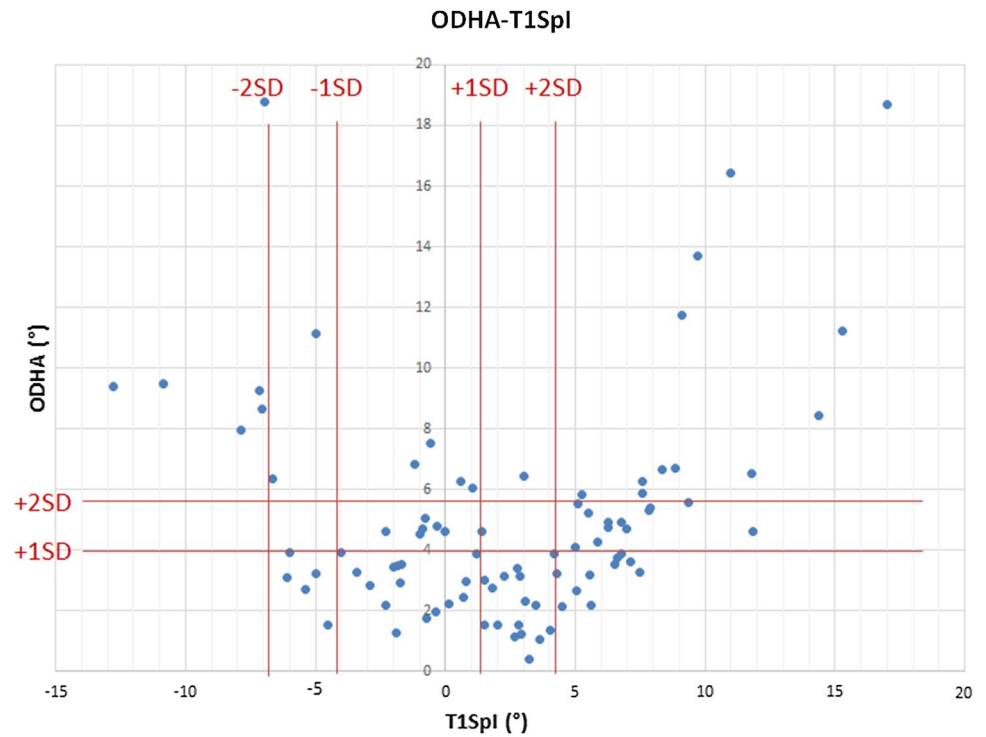
frequently in L3L4, 64%). The range of pelvic and spinal parameters values in the cohort was large (Table 1). Considering global sagittal alignment, dispersion was less important for the angular parameters (T1SpI, ODHA) than for SVA. The range of values was less important for ODHA than T1SpI. T1SpI had a small dispersion with an average value of  $2.2 \pm 5.6^\circ$ , but ODHA with a mean value of  $5 \pm 3.6^\circ$  was therefore the least variable. No patient had negative ODHA value (Figs. 5 and 6).

Mean T1SpI of the controls series was  $-1.35 \pm 2^\circ$ . Therefore, in our series, T1SpI was considered “normal” if its value was within a  $\pm 1$ SD interval from the controls mean,

**Fig. 5** Diagram of SVA and ODHA distribution (patients are represented as dots). Parameters were defined as “normal” if its value was between plus or minus 1 standard deviation (SD) from the controls means; “Subnormal high” between +1SD and +2SD, “subnormal low” between –1SD and –2SD, “abnormal high” beyond 2SD and “abnormal low” below 2SD. (Subnormal low and abnormal low “lines” for ODHA were not represented since it does not bring any additional information)



**Fig. 6** Diagram of T1SpI and ODHA distribution (patients are represented as dots). Parameters were defined as “normal” if its value was between plus or minus 1 standard deviation (SD) from the controls means; “Subnormal high” between +1SD and +2SD, “subnormal low” between –1SD and –2SD, “abnormal high” beyond 2SD and “abnormal low” below 2SD. Subnormal low and abnormal low “lines” for ODHA were not represented since it does not bring any additional information)



i.e., between  $-4.1^\circ$  and  $1.4^\circ$  ( $n=25$ ). Thirty-five patients (39%) had abnormally high T1SpI (superior to 2 standard deviations) (Table 2).

The average SVA in control subjects was  $-8.9 \pm 26$  mm. Consequently, in our cohort, SVA was considered “normal” if its value was within a  $\pm 1$ SD interval from the controls mean, between  $-34.9$  mm and  $17.1$  mm ( $n=36$ ). Thirty-two

patients (36%) had abnormally high SVA (superior to 2 standard deviations), among these patients 16 (50%) had abnormally high ODHA (Table 3).

The average ODHA value in Amabile’s study was  $2.8 \pm 1.6^\circ$ . In our cohort, ODHA was considered “normal” if its value was within a  $\pm 1$ SD interval from the controls mean, i.e., between  $1.3^\circ$  and  $4.5^\circ$  ( $n=43$ ). Twenty-two patients

**Table 2** Distribution of T1SpI ( $n=90$ )

	Inferior limit (°)	Superior limit (°)	<i>n</i>
-1SD < normal T1SpI < +1SD	-4.1	1.35	25
+1SD < subnormal high T1SpI < +2SD	1.35	4.1	17
-2SD < subnormal low T1SpI < -2SD	-6.8	-4.1	7
Abnormal high T1SpI > +2SD	4.1	-	35
Abnormal low T1SpI < -2SD	-	-6.8	6

**Table 3** Distribution of SVA ( $n=90$ )

	Inferior limit (mm)	Superior limit (mm)	<i>n</i>
-1SD < normal SVA < +1SD	-34.9	17.1	36
+1SD < subnormal high SVA < +2SD	17.1	43.1	19
-2SD < subnormal low SVA < -1SD	-60.9	-34.9	2
Abnormal high SVA > +2SD	43.1	-	32
Abnormal low SVA < -2SD	-	-60.9	1

(24%) had abnormally high ODHA (superior to 2 standard deviations), among these patients 16 (73%) had abnormally high SVA (Table 4). These patients with abnormally high ODHA and abnormally high SVA had significantly greater lordosis than patients with high ODHA and normal SVA ( $28^\circ \pm 17$  vs  $11^\circ \pm 15$ ,  $p=0.01$ ). The other 27% of patients had very high PT (>50% of PI), implying great retroversion to compensate for sagittal malalignment. Variance analysis showed a lower dispersion for ODHA than T1SpI and SVA (respectively, variance of ODHA 12.6, T1SpI 32.9 and SVA 2386).

### Comparison between patients with abnormally high ODHA and the rest of the cohort

The 22 patients with abnormally high ODHA value were significantly older than the rest of the cohort ( $68 \pm 9$  years vs  $53 \pm 14$  years,  $p=0.001$ ). There was no difference in terms of sex and BMI between the two groups. Among the 39 patients who had ODI, the 11 patients with abnormally high ODHA had a significantly worse ODI than the other 28 patients of the cohort ( $50 \pm 23$  vs.  $30 \pm 18$ ,  $p=0.005$ ). Rate of rotatory subluxation in each group was not different

**Table 4** Distribution of ODHA ( $n=90$ )

	Inferior limit (°)	Superior limit (°)	<i>n</i>
-1SD < normal ODHA < +1SD	1.3	4.5	43
+1SD < subnormal high ODHA < +2SD	4.5	6.1	20
-2SD < subnormal low ODHA < -1SD	-0.3	1.3	5
Abnormal high ODHA > +2SD	6.1	-	22
Abnormal low ODHA < -2SD	-	-0.3	0

(54%,  $n=12$  vs 62%,  $n=42$ ,  $p=0.06$ ). Patients with abnormally high ODHA had greater deformity, both in the coronal plane (with higher Cobb angle) and in the sagittal plane (with lower lordosis, higher pelvic retroversion, cervical lordosis and SVA) (Table 5).

### Correlation analysis (Table 6)

Regarding the relationships between global alignment parameters, moderate correlations were observed between ODHA and SVA ( $R > 0.450$ ,  $p < 0.05$ ), but no correlation existed with T1SpI. Correlations between ODHA and sagittal parameters were close to those of T1SpI and SVA. They were moderate between ODHA and lumbar lordosis

**Table 5** Comparison of radiographic parameters between patients with abnormally high ODHA ( $>6.1^\circ$ ) and the rest of the cohort

	Abnormally high ODHA ( $n=22$ )		Cohort ( $n=68$ )		<i>p</i>
	Mean	SD	Mean	SD	
Cobb angle (°)	44	17	37	14	0.06
CC7PL (mm)	28	24	18	14	0.03
Pelvic incidence (°)	56	11	54	13	0.41
Pelvic tilt (°)	25	10	18	11	0.004
Sacral slope (°)	31	10	36	10	0.04
L1S1 (°)	39	19	52	17	0.003
T1T12 (°)	45	24	41	16	0.38
C3C7 (°)	23	19	11	16	0.008
PI-LL (°)	16	15	1	17	0.0004
GST1 (°)	2.3	9.3	2.2	4.0	0.96
SVA (mm)	70	71	20	32	0.000
ODHA (°)	9.6	4.0	3.4	1.4	0.000

**Table 6** Correlation analysis between global alignment and spinal parameters

	ODHA 3D	T1SpI	SVA
Pelvic tilt	0.318	–	0.367
Sacral slope	0.207	–	–
PI-LL	0.468	–	0.584
T1T12	–	–	–
L1S1	0.401	–	0.452
C3C7	0.218	0.222	0.482

( $R=0.401$ ,  $p<0.05$ ), and they were low with pelvic tilt ( $R=0.318$ ,  $p<0.05$ ) (Table 6).

There was a significant correlation between ODHA and ODI ( $R=0.401$ ,  $p<0.05$ ). SVA was well correlated with ODI and VAS in this series (respectively,  $R=0.585$  and  $R=0.416$ ,  $p<0.05$ ).

## Discussion

In this study, we described alignment of 90 patients with scoliosis and used a new measurement parameter: the position of odontoid tip with respect to the femoral heads. In this cohort, sagittal pelvic and spinal parameters were similar to the cohorts already described in the literature [10–28]. Nevertheless, results showed that ODHA can be used to assess global alignment along with other global spinal parameters, to assess and estimate cervical compensation for malalignment (scenario where SVA is high but ODHA is normal) and to identify patients who have exhausted this cervical compensation (scenario where SVA is high and ODHA is abnormally high) since they are more likely going to have poor outcomes.

Initially overlooked, cervical spine alignment in ASD has been more explored in the recent years. Nevertheless, few authors have used measures of global alignment from anatomical points of the superior cervical spine or skull, whereas Le Huec et al. described ODHA as the most efficient parameter to analyze global alignment [21, 29]. Amabile et al. have recently shown that ODHA is a global alignment parameter with low dispersion [17–19]. In a cohort of 41 elderly subjects without scoliosis, they observed about 50% of subjects had anterior tilt with abnormally high SVA, while only 12% of these had abnormally high ODHA. The results are similar in our series with 36% of patients with abnormally high SVA, while ODHA was abnormally high for only 24% of patients. The rate of patients with anterior tilt using the T1SpI measurement was close to that of the SVA: 39%. From a methodological point of view, it is important to note that the malalignment threshold value we used

(SVA > 43 mm) was similar to the SRS-Schwab classification one (SVA > 40 mm) [6].

It seems that if the measurement of the anterior malalignment with C7 or T1 as reference vertebra can be of great amplitude, the range of values with the odontoid is reduced, as showed by the variance and the dispersion of the three parameters: ODHA, T1SpI and SVA. SVA major limitation lies in the lack of reproducibility of length measurement on uncalibrated X-rays, whereas angle measurement is more robust to use when comparing subjects with different heights. Nevertheless, the use of SVA is important when assessing sagittal malalignment, although it does not include cervical compensatory mechanisms. ODHA angle is therefore a more robust parameter and takes into account the cervical compensatory mechanisms. In this series, 50% of the abnormally high SVA patients had abnormally high ODHA: They potentially have exhausted their cervical compensatory mechanisms. Indeed, we can observe patients with important anterior tilt (high SVA or T1SpI) who compensate with cervical lordosis and who have a normal ODHA. However, in patients with important anterior tilt (high SVA or T1SpI) with high ODHA, cervical spine recruitment may not be sufficient to correct sagittal alignment, either because cervical compensation in hyperlordosis is insufficient to compensate for other spinal sectors with malalignment, or because they do not have the ability to compensate (cervical ankylosis, muscular weakness...). It is highlighted by the analysis of patients with abnormally high ODHA and abnormally high SVA who had significantly greater lordosis than patients with high ODHA and normal SVA ( $28^\circ \pm 17$  vs  $11^\circ \pm 15$ ,  $p=0,01$ ). It is important to consider this point in the preoperative planning.

Moreover, it should be noted that in this series, no negative values of ODHA were observed; this reinforces the idea of compensation at the cervical spine level to maintain balance. Indeed, in malaligned patients, T1 and C7 may be located behind the femoral heads, but it is unlikely that head is projected behind hips since it is an unsustainable position. To avoid this head position in case of postoperative spine posterior projection, it is common to observe a cervico-thoracic junctional kyphosis [30]. As described by Faundez et al., when ODHA is high, there is an increase in the lever arm, especially above the instrumented spine [31]. Moreover, this suggests the establishment of a compensatory mechanism at the cervical and cervico-thoracic levels, in order to keep the head above the pelvis and the horizontal gaze as much as possible, as shown by the significantly higher value of cervical lordosis in the group of patients with a high ODHA relatively to the rest of the cohort (Fig. 4).

The existing correlations between ODHA, pelvic tilt, L1S1, C3C7 and PI-LL reinforce this idea of a global compensation phenomenon to maintain balance with significant correlations between ODHA and the different spinal



or pelvic parameters. Nevertheless, correlations between functional outcomes and ODHA were smaller than with SVA. It might be due to the under-estimation of the deformity value due to activation of compensations in the cervical spine and to the VAS evaluation according to lumbar pain only. The use of SVA is still important when assessing the sagittal malalignment. Both parameters may be used simultaneously in order to assess cervical compensation in malaligned patients.

## Limitations

One of the limitations of this study was the lack of analysis of lower limbs compensatory mechanisms (hip extension, knee flexion, ankle flexion) to maintain a balanced posture. Another was the absence of gaze analysis [32, 33]. Indeed, full-body analysis could not be performed since most patients only had fullspine radiographs. It would be interesting to study the relationships between C2 position, lower limbs compensatory mechanisms and gravity line. Another limitation is the absence of flexion–extension cervical X-rays. Analysis of cervical range of motion and its consequences on ODHA values might be interesting but was not available for these patients. Finally, it is a mainly radiographic analysis and only 43% of the subjects had clinical scores, thus limiting the analysis of relationships with functional outcomes or quality of life.

We used the tip of C2 rather than the external meati, initially used in reconstructions with the EOS system, because it is more easily visualized on radiographs and its 3D analysis is simpler, especially since the literature has showed that the results were similar between the two parameters [18, 19].

## Conclusion

The results of this study on the alignment of 90 patients with scoliosis made it possible to show that the position of the odontoid with respect to the femoral heads was one of the least variable parameters of global alignment. Extreme values of ODHA were observed in significantly older patients with significant functional impairment. In addition, in these patients with sagittal malalignment and loss of lumbar lordosis, who recruit compensatory mechanisms such as pelvic retroversion, the cervical area is also involved with a posture in cervical hyperlordosis to maintain the head over the pelvis.

Thus, ODHA is an interesting parameter allowing a more comprehensive alignment measurement taking into account the mechanisms of compensation of the cervical spine to the pelvis. It is a useful parameter to assess global alignment and specifically along with other global parameters, to estimate and confirm cervical compensations for malalignment and

to identify patients who have exhausted this cervical compensation and hence are more likely going to have ill-effects of deformity. This global evaluation may be useful to better predict patients at risk of imbalance in case of exhausted compensatory capabilities and to better determine adapted correction in ASD surgery.

## References

1. Dubouset J (2012) L'homme debout: le rachis et son plan horizontal, scolioses. *Mem Acad Natl Chir* 11:66–70
2. Guigui P, Levassor N, Rillardon L, Wodecki P, Cardinne L (2003) Physiological value of pelvic and spinal parameters of sagittal balance: analysis of 250 healthy volunteers. *Rev Chir Orthop Reparatrice Appar Mot* 89(6):496–506
3. Vaz G, Roussouly P, Berthonnaud E, Dimnet J (2002) Sagittal morphology and equilibrium of pelvis and spine. *Eur Spine J Off Publ Eur Spine Soc Eur Spinal Deform Soc Eur Sect Cerv Spine Res Soc* 11(1):80–87
4. Vialle R, Levassor N, Rillardon L, Templier A, Skalli W, Guigui P (2005) Radiographic analysis of the sagittal alignment and balance of the spine in asymptomatic subjects. *J Bone Joint Surg Am* 87(2):260–267
5. Berthonnaud E, Dimnet J, Roussouly P, Labelle H (2005) Analysis of the sagittal balance of the spine and pelvis using shape and orientation parameters. *J Spinal Disord Tech* 18(1):40–47
6. Schwab F, Farcy J-P, Bridwell K, Berven S, Glassman S, Harrast J et al (2006) A clinical impact classification of scoliosis in the adult. *Spine* 31(18):2109–2114
7. Gelb DE, Lenke LG, Bridwell KH, Blanke K, McEneaney KW (1995) An analysis of sagittal spinal alignment in 100 asymptomatic middle and older aged volunteers. *Spine* 20(12):1351–1358
8. Protosaltis T, Schwab F, Bronsard N, Smith JS, Klineberg E, Mundis G et al (2014) The T1 pelvic angle, a novel radiographic measure of global sagittal deformity, accounts for both spinal inclination and pelvic tilt and correlates with health-related quality of life. *J Bone Joint Surg Am* 96(19):1631–1640
9. Roussouly P, Berthonnaud E, Dimnet J (2003) Geometrical and mechanical analysis of lumbar lordosis in an asymptomatic population: proposed classification. *Rev Chir Orthop Reparatrice Appar Mot* 89(7):632–639
10. Schwab FJ, Smith VA, Biserni M, Gamez L, Farcy J-PC, Pagala M (2002) Adult scoliosis: a quantitative radiographic and clinical analysis. *Spine* 27(4):387–392
11. Glassman SD, Berven S, Bridwell K, Horton W, Dimar JR (2005) Correlation of radiographic parameters and clinical symptoms in adult scoliosis. *Spine* 30(6):682–688
12. Lafage V, Schwab F, Patel A, Hawkinson N, Farcy J-P (2009) Pelvic tilt and truncal inclination: two key radiographic parameters in the setting of adults with spinal deformity. *Spine* 34(17):E599–606
13. Glassman SD, Bridwell K, Dimar JR, Horton W, Berven S, Schwab F (2005) The impact of positive sagittal balance in adult spinal deformity. *Spine* 30(18):2024–2029
14. Legaye J, Duval-Beaupère G, Hecquet J, Marty C (1998) Pelvic incidence: a fundamental pelvic parameter for three-dimensional regulation of spinal sagittal curves. *Eur Spine J Off Publ Eur Spine Soc Eur Spinal Deform Soc Eur Sect Cerv Spine Res Soc* 7(2):99–103
15. Diebo BG, Oren JH, Challier V, Lafage R, Ferrero E, Liu S et al (2016) Global sagittal axis: a step toward full-body assessment of sagittal plane deformity in the human body. *J Neurosurg Spine* 25(4):494–499

16. Kim YB, Kim YJ, Ahn Y-J, Kang G-B, Yang J-H, Lim H et al (2014) A comparative analysis of sagittal spinopelvic alignment between young and old men without localized disc degeneration. *Eur Spine J Off Publ Eur Spine Soc Eur Spinal Deform Soc Eur Sect Cerv Spine Res Soc* 23(7):1400–1406
17. Attali V, Clavel L, Rouch P, Rivals I, Rémy-Néris S, Skalli W et al (2019) Compensation of respiratory-related postural perturbation is achieved by maintenance of head-to-pelvis alignment in healthy humans. *Front Physiol* 10:441
18. Amabile C, Pillet H, Lafage V, Barrey C, Vital J-M, Skalli W (2016) A new quasi-invariant parameter characterizing the postural alignment of young asymptomatic adults. *Eur Spine J Off Publ Eur Spine Soc Eur Spinal Deform Soc Eur Sect Cerv Spine Res Soc* 25(11):3666–3674
19. Amabile C, Le Huec J-C, Skalli W (2018) Invariance of head-pelvis alignment and compensatory mechanisms for asymptomatic adults older than 49 years. *Eur Spine J Off Publ Eur Spine Soc Eur Spinal Deform Soc Eur Sect Cerv Spine Res Soc* 27(2):458–466
20. Steffen J-S, Obeid I, Aurouer N, Hauger O, Vital J-M, Dubousset J et al (2010) 3D postural balance with regard to gravity line: an evaluation in the transversal plane on 93 patients and 23 asymptomatic volunteers. *Eur Spine J Off Publ Eur Spine Soc Eur Spinal Deform Soc Eur Sect Cerv Spine Res Soc* 19(5):760–767
21. Sugrue PA, McClendon J, Smith TR, Halpin RJ, Nasr FF, O'Shaughnessy BA et al (2013) Redefining global spinal balance: normative values of cranial center of mass from a prospective cohort of asymptomatic individuals. *Spine* 38(6):484–489
22. Vital JM, Senegas J (1986) Anatomical bases of the study of the constraints to which the cervical spine is subject in the sagittal plane. A study of the center of gravity of the head. *Surg Radiol Anat* 8(3):169–173
23. Vogler D, Paillex R, Norberg M, de Goumoëns P, Cabri J (2008) Cross-cultural validation of the Oswestry disability index in French. *Ann Readapt Med Phys Rev Sci Soc Francaise Reeducat Fonct Readapt Med Phys* 51(5):379–385
24. Grönblad M, Hupli M, Wennerstrand P, Järvinen E, Lukinmaa A, Kouri JP et al (1993) Intercorrelation and test-retest reliability of the Pain Disability Index (PDI) and the Oswestry Disability Questionnaire (ODQ) and their correlation with pain intensity in low back pain patients. *Clin J Pain* 9(3):189–195
25. Dubousset J, Charpak G, Skalli W, Kalifa G, Lazennec J-Y (2007) EOS stereo-radiography system: whole-body simultaneous anteroposterior and lateral radiographs with very low radiation dose. *Rev Chir Orthop Reparatrice Appar Mot* 93(6 Suppl):141–143
26. Faro FD, Marks MC, Pawelek J, Newton PO (2004) Evaluation of a functional position for lateral radiograph acquisition in adolescent idiopathic scoliosis. *Spine* 29(20):2284–2289
27. Humbert L, De Guise JA, Aubert B, Godbout B, Skalli W (2009) 3D reconstruction of the spine from biplanar X-rays using parametric models based on transversal and longitudinal inferences. *Med Eng Phys* 31(6):681–687
28. Ferrero E, Lafage R, Diebo BG, Challier V, Illharborde B, Schwab F et al (2017) Tridimensional analysis of rotatory subluxation and sagittal spinopelvic alignment in the setting of adult spinal deformity. *Spine Deform* 5(4):255–264
29. Aykac B, Ayhan S, Yuksel S, Guler UO, Pellise F, Alanay A et al (2015) Sagittal alignment of cervical spine in adult idiopathic scoliosis. *Eur Spine J Off Publ Eur Spine Soc Eur Spinal Deform Soc Eur Sect Cerv Spine Res Soc* 24(6):1175–1182
30. Ferrero E, Bocahut N, Lefevre Y, Roussouly P, Pesenti S, Lakhali W et al (2018) Proximal junctional kyphosis in thoracic adolescent idiopathic scoliosis: risk factors and compensatory mechanisms in a multicenter national cohort. *Eur Spine J Off Publ Eur Spine Soc Eur Spinal Deform Soc Eur Sect Cerv Spine Res Soc* 27(9):2241–2250
31. Faundez AA, Richards J, Maxy P, Price R, Léglise A, LeHuec JC (2018) The mechanism in junctional failure of thoraco-lumbar fusions. Part II: Analysis of a series of PJK after thoraco-lumbar fusion to determine parameters allowing to predict the risk of junctional breakdown. *Eur Spine J* 1:139–148. <https://doi.org/10.1007/s00586-017-5426-7>
32. Diebo BG, Ferrero E, Lafage R, Challier V, Liabaud B, Liu S et al (2015) Recruitment of compensatory mechanisms in sagittal spinal malalignment is age and regional deformity dependent: a full-standing axis analysis of key radiographical parameters. *Spine* 40(9):642–649
33. Ferrero E, Liabaud B, Challier V, Lafage R, Diebo BG, Vira S et al (2016) Role of pelvic translation and lower-extremity compensation to maintain gravity line position in spinal deformity. *J Neurosurg Spine* 24(3):436–446

**Publisher's Note** Springer Nature remains neutral with regard to jurisdictional claims in published maps and institutional affiliations.