



Science Arts & Métiers (SAM)

is an open access repository that collects the work of Arts et Métiers Institute of Technology researchers and makes it freely available over the web where possible.

This is an author-deposited version published in: <https://sam.ensam.eu>
Handle ID: <http://hdl.handle.net/10985/22555>

To cite this version :

François GIRINON, Wael BAYOUD, Bhrigu LAHKAR, Aurore BONNET-LEBRUN, Jean-Yves LAZENNEC, Wafa SKALLI, Philippe ROUCH, Laurent GAJNY - Fast quasi-automated 3D reconstruction of lower limbs from low dose biplanar radiographs using statistical shape models and contour matching - Medical Engineering & Physics - Vol. 101, p.103769 - 2022

Any correspondence concerning this service should be sent to the repository

Administrator : scienceouverte@ensam.eu



Fast quasi-automated 3D reconstruction of lower limbs from low dose biplanar radiographs using statistical shape models and contour matching

Laurent Gajny PhD¹, François Girinon PhD¹, Wael Bayoud MD, MSc^{1,2}, Bhrigu Lahkar MSc¹, Aurore Bonnet-Lebrun MSc¹, Philippe Rouch PhD¹, Jean-Yves Lazennec MD-PhD², Wafa Skalli PhD¹.

¹Institut de Biomecanique Humaine Georges Charpak, Arts et Metiers, Institute of Technology, Paris, France.

²Department of Orthopedic and Trauma Surgery, La Pitie-Salpetriere Hospital, Assistance Publique – Hopitaux de Paris, UPMC, Paris, France.

Author's email: laurent.gajny@ensam.eu (corresponding author), francois.girinon@gadz.org, wael.bayoud@hotmail.com, bhrigu_kumar.lahkar@ensam.eu, Aurore.bonnet-lebrun@ensam.eu, philippe.rouch@ensam.eu, lazennec.jy@wanadoo.fr, Wafa.skalli@ensam.eu

The edited version of this paper published in Medical Engineering and Physics is available at the following link <https://doi.org/10.1016/j.medengphy.2022.103769>

Abstract

Three-dimensional bone reconstructions from medical imaging are essential for biomechanical modelling and are growing tools in clinics. Several methods of lower limbs reconstruction from biplanar radiographs have been proposed in the literature but with significant operator dependence. A novel reconstruction method based on reduced manual annotation, statistical shape models and fully automatic adjustments was proposed in this study. While significantly reducing operator intervention, the proposed method demonstrated similar or better precision than previous approaches on clinical parameters. Meanwhile, shape accuracy was improved to around 1mm. By quasi-automating the 3D reconstruction without loss of accuracy and precision, the proposed approach is a considerable step towards extensive use of 3D personalized models in clinical routine and large cohort biomechanical studies.

Keywords Biplanar radiographs, 3D reconstruction, lower limb, knee

Introduction

Three-dimensional bones reconstruction from medical imaging is becoming increasingly popular in clinical routine for treatment planning, especially surgical planning [1,2] and clinical outcome assessment [3,4]. These 3D models can be efficiently visualized by clinicians in different planes of interest and surgical strategies can be planned using dedicated software [5]. Moreover, 3D postural and morphological parameters can be computed before and after surgery to assess its success or failure. These parameters are not affected by projection bias such as that obtained with a single coronal radiograph. Another interesting use of these models has been made possible by the emergence of 3D printing technologies that allow surgical strategies to be practiced first on a life-size bone model [6].

3D bone models can be obtained using standard imaging techniques such as Computed Tomography (CT-scan), which results in an expensive, time-consuming examination associated with a significant radiation dose. Magnetic Resonance Imaging (MRI) is non-irradiating but is expensive and time consuming. Moreover, if medical prostheses (hip, knee or

3D reconstruction of lower limbs

other) or spine metallic implant do not constitute a contraindication to the examination, their material usually corrupts the surrounding signal and the anatomical region bearing these materials cannot be analyzed with this modality. It is obviously problematic in the context of a post-operative follow-up. Low dose biplanar radiography is then a relevant alternative since it implies a quick examination, in a functional position. In addition, interactive methods allow the evaluation of bone surfaces in 3D.

In this article, we focus on the reconstruction of lower limbs. The standard reconstruction method of the lower limb used in clinical routine [7] is based on a two-stage process. First, a trained user manually digitizes anatomical landmarks that help preposition a parametric statistical model of the lower limb. Then, the user adjusts the projected contours of the 3D model to the radiographic contours by moving control handles. The entire process typically takes more than 10 minutes for both lower limbs in current practice. In addition to this long reconstruction time, the accuracy of this method is operator dependent and poses the problem of his training. Manual inputs are prone to error and manual adjustments of the model may cause non-physiological local features and different interpretations of the apparent contours. In [8], the authors proposed a method relying only on manual inputs, the same proposed in [7]. While decreasing the operator time, this method does not perform better than the previous one in terms of accuracy and reproducibility.

These two methods [7,8] did not propose patella reconstruction. Yet, the position of the patella is essential to understand, evaluate, and control patellofemoral function in pain. A solution was proposed in [9] to study patellofemoral kinematics. It consisted of manually digitizing the complete patella contour on sagittal and coronal radiographs. This process was time consuming and not suitable for clinical routine.

A novel femur reconstruction method has recently been proposed [10]. It first consisted in a simplified set of manual annotations in which for instance the operator did not have to explicitly identify left and right condyles on the sagittal view. This was a challenge and a source of error in previous methods. Instead, the operator was asked to click on both condyles and the algorithm would automatically identify left and right. Then, the combination of statistical shape model inference and contour matching resulted in a solution without further manual intervention. The accuracy and precision of this method were very promising with average point-to-surface distances to reference CT scans of 1 mm and an uncertainty on femoral torsion of less than 5°. This promising method was only developed for the femur. Therefore, for more clinical relevance, an extension of this method was needed for the entire lower limb, including the patella.

Therefore, the objective of this study was to introduce a new method of reconstructing the entire lower limb from biplanar radiographs that would include the patella, with simple and intuitive manual annotations for all bones and without any manual refinement of the model. We expected this method to outperform previous approaches in terms of shape accuracy and reliability of clinical parameters. The proposed method is therefore based on a reduced and simplified set of manually determined landmarks, on which statistical shape models of each bone are fitted. They are then automatically refined by matching the contours of the projected models with the radiographic contours.

1. Materials and Methods

1.1. Database

A large database has been collected retrospectively for each bone or possibly combinations of bones. A summary of this database is shown in Figure 1. Firstly, we collected a database of biplanar radiographs with associated 3D reconstructions. The radiographs were acquired with

3D reconstruction of lower limbs

the low dose EOS system (EOS imaging, France). The inclusion of asymptomatic volunteers was validated by the ethics committee (C.P.P. Ile de France VI, CPP06036). After obtaining Institutional Review Board approval, preoperative radiographs of patients awaiting total knee or hip arthroplasty, were collected retrospectively at La Pitie-Salpetriere Hospital, Paris, France. For each subject, lower limb reconstructions were performed by expert users [7]. As the proposed approach was based on statistical models, a subsample of this large database was dedicated to model training (176 asymptomatic subjects aged 21-71 years). A database of 22 asymptomatic volunteers (mean age = 36, range = [23-74]) and of 15 patients with knee pathology (mean age = 67, range = [55-74]) were used to evaluate the agreement of the method with [7]. Another set of 10 asymptomatic volunteers (mean age = 29, range = [23-39]) and of 10 pathological subjects (mean age = 69, range = [61-79]) was used to assess its reproducibility.

A second database, consisting of cadaver CT-scans and associated 3D models segmented using the open software MITK-GEM [11], was built and used both for training and accuracy assessment. For model training, we collected open datasets for femur, tibia and fibula [12]. For model evaluation, we collected 16 non-pathologic and 4 pathologic femurs as well and 9 tibiae and fibula.

Biplanar X-ray database		
Training of the statistical shape models 176 asymptomatic subjects Age : 21 to 71	Agreement with [7] 22 asymptomatic / 15 pathologic Age : 23 to 74 / 55 to 75	Reproducibility 10 asymptomatic / 10 pathologic Age : 23 to 39 / 61 to 79

CT-scan database	
Training of the statistical shape models 50 femurs / 70 tibias and fibulas [12] 38 patellas	Agreement with the manual segmentation Femur : 16 asymptomatic / 4 pathologic Tibias and fibulas : 9 asymptomatic

Figure 1 Summary of the different databases and their contribution in this study.

1.2. Manual inputs

For each bone, several manual inputs were required to initialize the 3D models. They are listed in Table 1 and illustrated in Figure 2.

1.3. Automated reconstruction process

The femur and tibia were reconstructed independently. The reconstruction of the fibula was dependent on that of the tibia. Similarly, the patella was linked to the femur in the reconstruction process. The method was similar for each bone and a detailed technical description of the method for the femur was published in [10]. In summary, a database of 3D EOS reconstructions was used to train a statistical shape model. This model was fitted using a Gaussian process regression onto the annotated landmarks [13,14] providing a coarse but well-positioned initial solution. A second statistical shape model built on the 3D CT reconstructions database was then preferred, when available, for the solution refinement. Inspired by [15–17], the model was automatically adjusted in an iterative process via contour matching between the projected model contours and the radiographic contours of the bone. Specifically, after preprocessing consisting of a recursive median filter and adaptive histogram equalization, this iterative method required initial contours of the 3D model on the sagittal and frontal radiographs. These contours were uniformly subsampled, and a ribbon was constructed orthogonally around the subsampled contour. This ribbon was a region of interest for searching corresponding radiographic contours (see Figure 3). By interpolation, a straightened image was

3D reconstruction of lower limbs

constructed to contain only intensity information inside the ribbon. A shortest path was searched in this image.

Table 1 List of necessary manual annotations to initialize the reconstruction algorithm.

Bone	Annotation	Type	Frontal	Sagittal
Femur	Femoral head	1 sphere	✓	✓
	Greater trochanter	1 point	✓	
	Lesser trochanter	1 point	✓	
	Lateral extremities of the condyles	2 points	✓	
	Posterior points of the condyles	2 points		✓
Tibia + Fibula	Centre of spine	1 point	✓	✓
	Centre of distal joint	1 point	✓	✓
	Medial malleolus	1 point	✓	
	Posterior point of condyles	1 point		✓
	Proximal extremity of the fibula	1 point		✓
	External extremity of malleolus	1 point		✓
Patella	Upper and lower extremities	2 points		✓
	Anterior point	1 point		✓
	Right and left extremities	2 points	✓	

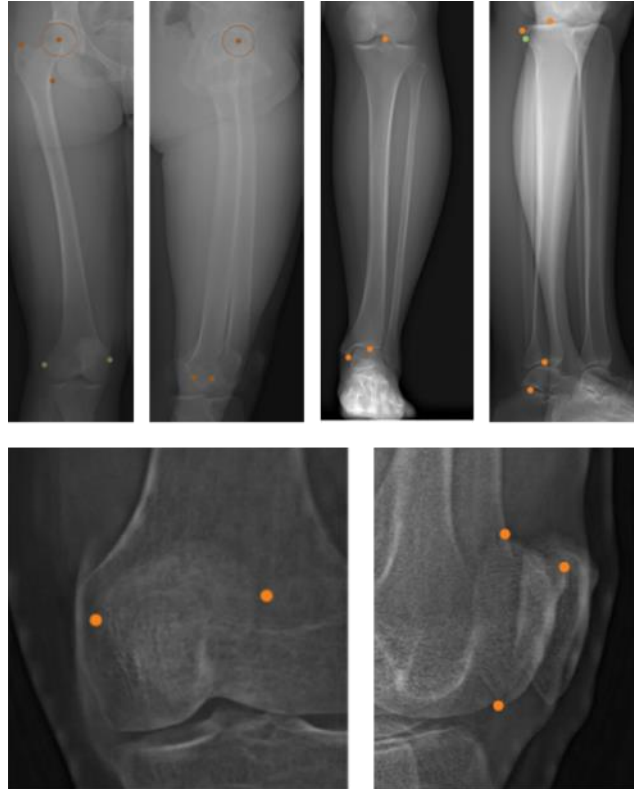


Figure 2 Necessary manual annotations to initialize lower limbs.

3D reconstruction of lower limbs

This process was applied recursively, decreasing the thickness of the ribbon at each iteration, and activating after several iterations some difficult areas that may involve contour matching failures when the shape was coarsely fitted. At each iteration, the 3D model was deformed by dual kriging interpolation [10]. The algorithm had a maximum of 20 iterations and could stop earlier if maximum observed displacement was lower than 0.5 mm.

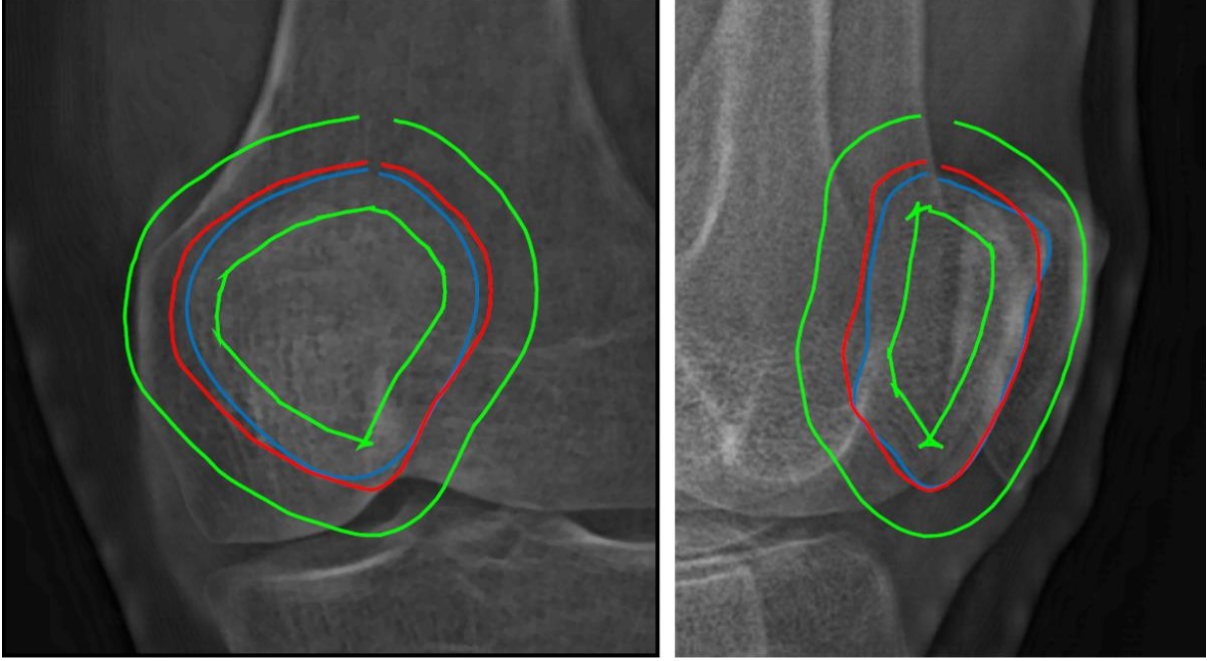


Figure 3 Shortest-path contour matching. Red: Initial contour, Green: Ribbon of interest, Blue: Final contour.

A cost map was to be defined for the determination of the shortest path. The methodology was the same for all bones. In short, for these regions, the overall cost map was a combination of three cost maps. The first penalized a small gradient. The second penalized, in a neighborhood of the manually annotated landmarks, the pixels furthest from those annotations. The third one was a statistical cost map based on the Mahalanobis distance:

$$D_M(p) = \sqrt{(p - \mu_c)^T \Sigma_c^{-1} (p - \mu_c)},$$

where p was the 3D coordinates of a mesh vertex, μ_c the associated vertex on the mean model of the CT scan-based statistical shape model and Σ_c the covariance matrix of this model. Each pixel was associated with a candidate 3D position for the considered mesh vertex. Therefore, candidates with high Mahalanobis distance – i.e. inconsistent with the statistical shape model – were penalized.

1.4. Clinical parameters computation

From the 3D reconstructions of the lower limbs, clinically relevant parameters were calculated. Femoral mechanical angle (FMA), hip-knee-shaft (HKS), femoral torsion (TS), cervico-diaphyseal angle (CDA) and femoral length (FL) were computed. Tibial mechanical angle (TMA), tibial length (TL) and tibial torsion (TT) were also calculated.

1.5. Evaluation

Shape and clinical parameter accuracy when compared to a CT scan reference

The accuracy of the 3D reconstructed models could be evaluated in vitro for each bone, except the patella, by comparing them to 3D segmented bones from our CT database. For each

3D reconstruction of lower limbs

specimen, a pair of digitally reconstructed radiographs [18] – sagittal and frontal in a realistic environment compared to the EOS system – was generated and the 3D reconstruction of the bone was performed by an expert engineer using the proposed method. The CT and EOS models were compared in terms of clinical parameters and point-to-surface distances. Point-to-surface distances were calculated by orthogonally projecting each point of an EOS model onto the nearest triangle of the reference mesh surface model. The mean and standard deviation of these differences were computed for each bone tested.

Shape and clinical parameter accuracy when compared to a previous method

The accuracy of the proposed method was also evaluated *in vivo*. In this evaluation, each bone tested was reconstructed in 3D using a previously validated method [7] and using the proposed method. The two models were compared in terms of clinical parameters. The mean differences and standard deviation were computed. The accuracy of the patella shape was assessed by comparing the solution with the previous manual method [9].

Repeatability and reproducibility of clinical parameters

Three operators have performed the reconstructions on two occasions. Two of them were engineers and regular users of the proposed reconstruction method. The third operator was a clinician who underwent approximately 30 minutes of mandatory training.

Repeatability and reproducibility were quantified on the clinical parameters listed in section 1.4 following the guidelines of ISO 5725-2. Twice the standard deviations of repeatability and reproducibility, as defined in the ISO standard, were then considered as measures for the intra and inter-operator reliability of the proposed method.

2. Results

Difference maps highlighting the point-to-surface distances of the models obtained with the proposed method and the CT references are shown in Figure 4 and 5. On the femur, we observed an average difference of 1.0 mm and a standard deviation of 0.7 mm. The maximum mean differences occurred at the posterior level of the greater trochanter (3 mm), at the anterior part of the greater trochanter (2.5 mm). Similar results were observed on the tibia with an average distance of 1.1 mm a standard deviation equal to 0.8 mm. Here, the maximum mean differences occurred at the anterior rim of the distal joint. The accuracy of the patella shape was evaluated by comparing our solution to a previous approach [9]. The observed mean point-to-surface distance was 1 mm and the standard deviation was 0.8 mm.

The accuracy of the clinical parameters is summarized in Table 2. When comparing with CT references or with [7], the average differences of the femoral parameters were all close to zero. The highest standard deviation was observed for femoral torsion. Limited average differences for tibial parameters were observed when compared to CT (less than 2° or 2 mm). A significant difference in tibial length was observed between our proposed method and [7] (-3.8mm in average).

The repeatability and reproducibility results are summarized in Table 3. The reproducibility of the previous methods [7,8] is also recalled. The proposed method has the best reproducibility for 5 of the 7 parameters for asymptomatic subjects. For pathologic cases, the reproducibility was similar or lower than the former methods for 5 of the 7 parameters. Indeed, femoral and tibial torsions seemed less reproducible than in [7,8].

3D reconstruction of lower limbs

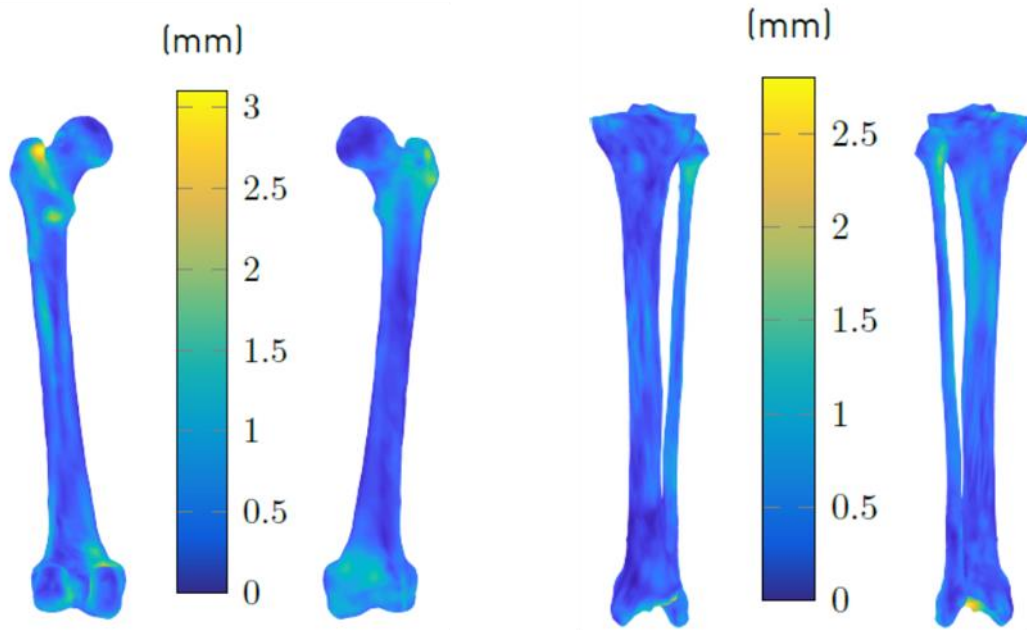


Figure 4 Heat maps representing on each point of the femur and tibia models mean point-to-surface distances to a CT reference.

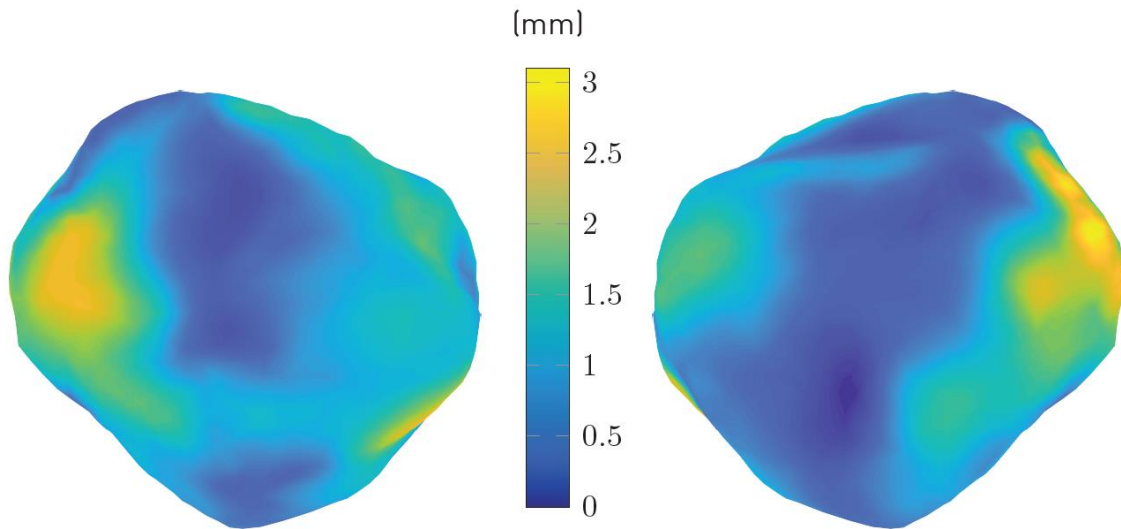


Figure 5 Heat maps representing on each point of the patella model mean point-to-surface distances to a manual segmentation method [9].

3D reconstruction of lower limbs

Table 2 Accuracy of the clinical parameters. Comparison with a CT reference and with a previously validated method.

Bone	Parameters	Comparison with CT	Comparison with [7]
Femur	FMA (°)	0.8 ± 3.3	-0.0 ± 2.9
	HKS (°)	0.3 ± 0.8	-0.1 ± 1.1
	FT (°)	-0.1 ± 4.8	-1.1 ± 5.4
	CDA (°)	0.1 ± 3.3	-0.3 ± 4.8
	FL (mm)	0.3 ± 1.8	0.1 ± 2.0
Tibia	TMA (°)	-2.1 ± 4.8	-1.0 ± 4.3
	TL (mm)	1.7 ± 3.2	-3.8 ± 4.0
	TT (°)	-1.8 ± 5.2	1.0 ± 7.0

Table 3 Repeatability and reproducibility results of the proposed method on clinical parameters and comparison with previous approaches.

Bone	Parameters	Repeatability (2SD)		Reproducibility (2SD)		Reproducibility (2SD) in [7]		Reproducibility (2SD) in [8]	
		A	P	A	P	A	P	A	P
Femur	FMA (°)	0.5	1.0	1.3	1.3	1.3	1.4	2.3	2.9
	HKS (°)	0.2	0.4	0.4	0.9	0.8	0.5	0.7	1.1
	FT (°)	1.3	1.6	4.8	5.1	3.8	4.5	5.0	4.0
	FL (mm)	0.5	0.6	1.4	1.4	1.8	1.7	1.9	1.3
Tibia	TMA (°)	0.5	0.5	1.1	1.3	2.6	2.6	1.3	2.0
	TL (mm)	0.9	1.2	2.5	3.0	2.3	2.4	2.2	2.2
	TT (°)	1.8	3.8	4.0	8.3	4.9	5.2	4.2	5.3

3. Discussion

In this paper, a new reconstruction method of lower limb including the patella from low dose biplanar radiographs has been proposed. It was designed to minimize training time and operator intervention. The number of anatomical landmarks to be annotated manually was reduced comparing to the previous approaches [7,8]. Moreover, their definitions are unambiguous, and they are easy to identify. For instance, the operator is not asked to distinguish the left and right condyles of the femur on the sagittal view. This is often a difficult task that was required several times in the previous methods. The ease of identification is a key ingredient in the reproducibility performance of our method. With only 30 minutes of training, we showed that the proposed method was as or even more reproducible than the previous algorithms for a set of clinically relevant parameters. These promising results can also be explained by the fact that, in contrast to [7], no fine manual registration of the models is needed in a final step. This manual adjustment step is usually an obstacle to the use of 3D reconstruction in clinical routine and there is a real need to replace it by an automatic algorithm.

The automation of this part did not affect shape accuracy. On the contrary, the proposed method outperforms [7]. For the femur reconstruction, we obtained a mean point-to-surface distance from the reference CT scans of 1 mm, which represents around 4% of the diameter of an

3D reconstruction of lower limbs

average femur, and a SD of 0.8 mm. The mean was similar in [7] (1.3mm) but the SD was 1 mm higher. For tibia reconstruction, the same observation regarding the mean point-to-surface distance remains valid (1.1mm vs. 1.3mm) and the SD is twice as low as in [7] (1.6mm vs. 0.8mm).

The proposed method also allows reconstruction of the patella which is important for analyzing patellofemoral function. A previous method enabled to reconstruct it by digitizing its complete contour on the sagittal and coronal view. The proposed method considerably simplified this process by requiring only 3 points on the sagittal view and 2 on the coronal view. The obtained solutions were very close to the previous ones with a mean point-to-surface distance between models of 1 mm (around 3% of the height of an average patella) and a standard deviation of 0.8 mm.

Operator time includes the annotation times for each structure. Annotation of a femur and tibia typically takes less than a minute and a half each, and of a patella 30 seconds. All structures can be reconstructed independently if needed but the average total operator time for a lower limb is around three and a half minutes. In addition, the computation time was above 50 seconds for a lower limb on an regular desktop computer. For comparison, reconstructing a single lower limb with [7] and adding patella reconstruction using [9] took around 10 minutes.

Of course, this study has some limitations. The contour matching algorithm may sometimes fail where the femurs intersect on the sagittal radiograph. This results in a mismatch between the actual radiographic contour and the model contour that may choose to match the other femur. However, using our statistical model, our method prevents this mismatch from persisting across the entire bone. Therefore, the mismatch, when it exists, is limited to a small region of the diaphysis, and does not affect consistency of the clinical parameters. Although the difference is not huge, tibial torsion has demonstrated lower reproducibility on pathological cases than previous approaches. If this specific setting is required, we recommend a local manual adjustment of the model, as in [7]. A last limitation of the presented method is that it cannot efficiently address fractured bones or very local abnormalities such as osteophytes. Nonetheless, it appears to be effective for pathologic patients awaiting total knee or hip arthroplasty.

The proposed method therefore has advantages in terms of operator time and simplicity of required tasks, but also in terms of low radiation dose and potential cost and time savings by replacing a CT-scan segmentation. Although a fully automated reconstruction method is the topic of future research, implementation of the proposed method in the clinic could be a significant advance in the care of patients with lower limb deformities or undergoing arthroplasty.

CRediT author statement

Laurent Gajny: *Conceptualization, Methodology, Formal Analysis, Investigation, Writing - Original Draft, Supervision.* François Girinon: *Methodology, Software, Formal Analysis, Data Curation, Investigation, Writing - Review & Editing, Supervision.* Wael Bayoud: *Validation, Resources, Data Curation, Investigation.* Bhrihu Lahkar: *Validation, Formal Analysis.* Aurore Bonnet-Lebrun: *Validation.* Philippe Rouch: *Conceptualization, Methodology, Supervision.* Jean-Yves Lazennec: *Conceptualization, Resources, Writing - Review & Editing.* Wafa Skalli: *Conceptualization, Methodology, Writing - Review & Editing, Supervision, Funding acquisition.*

Acknowledgments

The authors thank the ParisTech BiomecAM chair program, on subject-specific musculoskeletal modelling and in particular Société Générale and COVEA.

Conflict of interest: Dr. Skalli has a patent related to biplanar X-rays and associated 3D reconstruction methods, with no personal financial benefit (royalties rewarded for research and education) licensed to EOS Imaging. The other authors have nothing to declare.

Ethical Review Committee Statement: Study approval was obtained from La Pitie-Salpetriere Hospital review board. Subject inclusions at Arts et Metiers were validated by the Ethical Committee (C.P.P. Ile de France VI, CPP06036).

Funding: This research was funded by the the ParisTech BiomecAM chair program, on subject-specific musculoskeletal modelling.

References

- [1] Verdier N, Billaud A, Masquefa T, Pallaro J, Fabre T, Tournier C. EOS-based cup navigation: Randomised controlled trial in 78 total hip arthroplasties. *Orthop Traumatol Surg Res* 2016;102:417–21. <https://doi.org/10.1016/j.otsr.2016.02.006>.
- [2] Mainard D, Barbier O, Knafo Y, Belleville R, Mainard-Simard L, Gross J-B. Accuracy and reproducibility of preoperative three-dimensional planning for total hip arthroplasty using biplanar low-dose radiographs : A pilot study. *Orthop Traumatol Surg Res* 2017;103:531–6. <https://doi.org/10.1016/j.otsr.2017.03.001>.
- [3] Lazennec J-Y, Rousseau M-A, Brusson A, Folinais D, Amel M, Clarke I, et al. Total Hip Prostheses in Standing, Sitting and Squatting Positions: An Overview of Our 8 Years Practice Using the EOS Imaging Technology. *Open Orthop J* 2015;9. <https://doi.org/10.2174/1874325001509010026>.
- [4] Lazennec JY, Thauront F, Robbins CB, Pour AE. Acetabular and Femoral Anteversions in Standing Position are Outside the Proposed Safe Zone After Total Hip Arthroplasty. *J Arthroplasty* 2017;32:3550–6. <https://doi.org/10.1016/j.arth.2017.06.023>.
- [5] Milas J, Garayt M, Oriot E, Hobeika J. 31 - EOS Imaging: Low-Dose Imaging and Three-Dimensional Value Along the Entire Patient Care Pathway for Spine and Lower Limb Pathologies. In: Abedin-Nasab MH, editor. *Handb. Robot. Image-Guid. Surg.*, Elsevier; 2020, p. 529–49. <https://doi.org/10.1016/B978-0-12-814245-5.00031-1>.
- [6] Zhang W, Ji Y, Wang X, Liu J, Li D. Can the recovery of lower limb fractures be achieved by use of 3D printing mirror model? *Injury* 2017;48:2485–95. <https://doi.org/10.1016/j.injury.2017.09.003>.
- [7] Chaibi Y, Cresson T, Aubert B, Hausselle J, Neyret P, Hauger O, et al. Fast 3D reconstruction of the lower limb using a parametric model and statistical inferences and clinical measurements calculation from biplanar X-rays. *Comput Methods Biomech Biomed Engin* 2012;15:457–66. <https://doi.org/10.1080/10255842.2010.540758>.
- [8] Quijano S, Serrurier A, Aubert B, Laporte S, Thoreux P, Skalli W. Three-dimensional reconstruction of the lower limb from biplanar calibrated radiographs. *Med Eng Phys* 2013;35:1703–12. <https://doi.org/10.1016/j.medengphy.2013.07.002>.
- [9] Dagneaux L, Thoreux P, Eustache B, Canovas F, Skalli W. Sequential 3D analysis of patellofemoral kinematics from biplanar x-rays: In vitro validation protocol. *Orthop Traumatol Surg Res* 2015;101:811–8. <https://doi.org/10.1016/j.otsr.2015.07.017>.
- [10] Girinon F, Gajny L, Ebrahimi S, Dagneaux L, Rouch P, Skalli W. Quasi-automated reconstruction of the femur from bi-planar X-rays. *Comput Methods Biomech Biomed Eng Imaging Vis* 2020;8:529–37.
- [11] Pauchard Y, Fitze T, Browarnik D, Eskandari A, Pauchard I, Enns-Bray W, et al. Interactive graph-cut segmentation for fast creation of finite element models from clinical ct data for hip fracture prediction. *Comput Methods Biomech Biomed Engin* 2016;19:1693–703. <https://doi.org/10.1080/10255842.2016.1181173>.

3D reconstruction of lower limbs

- [12] Kistler M, Bonaretti S, Pfahrer M, Niklaus R, Büchler P. The Virtual Skeleton Database: An Open Access Repository for Biomedical Research and Collaboration. *J Med Internet Res* 2013;15. <https://doi.org/10.2196/jmir.2930>.
- [13] Albrecht T, Lüthi M, Gerig T, Vetter T. Posterior shape models. *Med Image Anal* 2013;17:959–73. <https://doi.org/10.1016/j.media.2013.05.010>.
- [14] Lüthi M, Gerig T, Jud C, Vetter T. Gaussian Process Morphable Models. *IEEE Trans Pattern Anal Mach Intell* 2018;40:1860–73. <https://doi.org/10.1109/TPAMI.2017.2739743>.
- [15] Trochu F. A contouring program based on dual kriging interpolation. *Eng Comput* 1993;9:160–77. <https://doi.org/10.1007/BF01206346>.
- [16] Ouertani F, Vazquez C, Cresson T, Guise J de. Simultaneous extraction of two adjacent bony structures in x-ray images: Application to hip joint segmentation. 2015 IEEE Int. Conf. Image Process. ICIP, 2015, p. 4555–9. <https://doi.org/10.1109/ICIP.2015.7351669>.
- [17] Huang J, Griffith JF, Wang D, Shi L. Graph-Cut-Based Segmentation of Proximal Femur from Computed Tomography Images with Shape Prior. *J Med Biol Eng* 2015;35:594–607. <https://doi.org/10.1007/s40846-015-0079-7>.
- [18] Roth SD. Ray casting for modeling solids. *Comput Graph Image Process* 1982;18:109–44. [https://doi.org/10.1016/0146-664X\(82\)90169-1](https://doi.org/10.1016/0146-664X(82)90169-1).