



Science Arts & Métiers (SAM)

is an open access repository that collects the work of Arts et Métiers Institute of Technology researchers and makes it freely available over the web where possible.

This is an author-deposited version published in: <https://sam.ensam.eu>
Handle ID: <http://hdl.handle.net/10985/7338>

To cite this version :

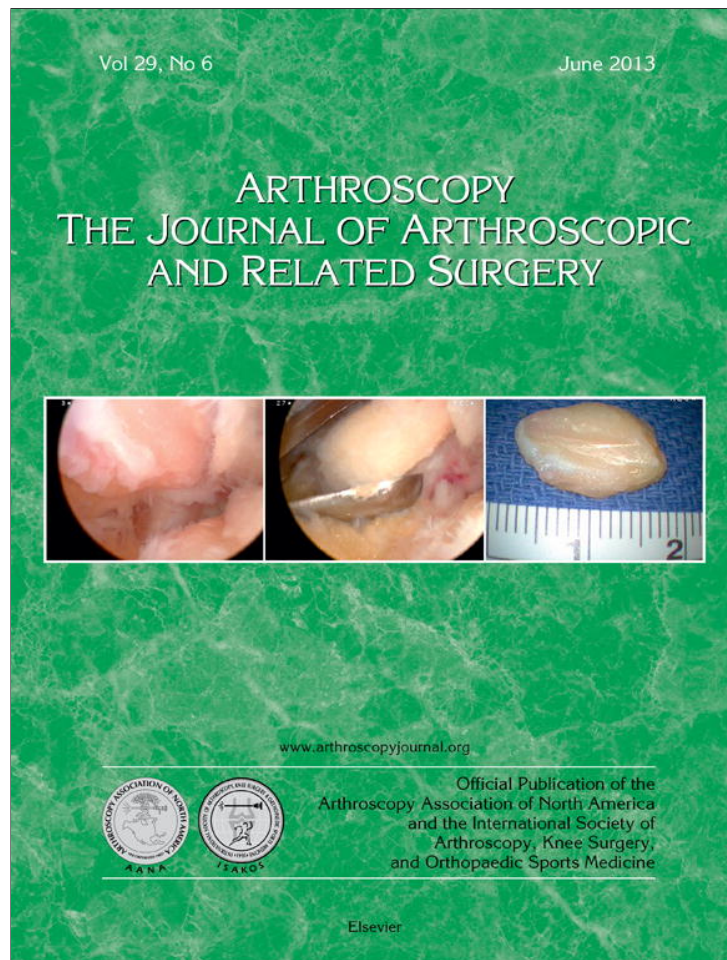
Véronique VIATEAU, Mathieu MANASSERO, Fani ANAGNOSTOU, David MITTON, Véronique MIGONNEY, Sandra GUÉRARD - Biological and Biomechanical Evaluation of the Ligament Advanced Reinforcement System (LARS AC) in a Sheep Model of Anterior Cruciate Ligament Replacement: A 3-Month and 12-Month Study - Arthroscopy: The Journal of Arthroscopy and Related Surgery - Vol. 29, n°6, p.pp 1079-1088 - 2013

Any correspondence concerning this service should be sent to the repository

Administrator : scienceouverte@ensam.eu



Provided for non-commercial research and education use.
Not for reproduction, distribution or commercial use.



This article appeared in a journal published by Elsevier. The attached copy is furnished to the author for internal non-commercial research and education use, including for instruction at the authors institution and sharing with colleagues.

Other uses, including reproduction and distribution, or selling or licensing copies, or posting to personal, institutional or third party websites are prohibited.

In most cases authors are permitted to post their version of the article (e.g. in Word or Tex form) to their personal website or institutional repository. Authors requiring further information regarding Elsevier's archiving and manuscript policies are encouraged to visit:

<http://www.elsevier.com/authorsrights>

Biological and Biomechanical Evaluation of the Ligament Advanced Reinforcement System (LARS AC) in a Sheep Model of Anterior Cruciate Ligament Replacement: A 3-Month and 12-Month Study

Véronique Viateau, D.M.V., Ph.D., Mathieu Manassero, D.M.V., M.Sc., Fani Anagnostou, D.M., Ph.D., Sandra Guérard, Ph.D., David Mitton, Ph.D., and Véronique Migonney, Ph.D.

Purpose: The purposes of this study were to assess tissue ingrowth within the Ligament Advanced Reinforcement System (LARS) artificial ligament (LARS AC; LARS, Arc sur Tille, France) and to study the biomechanical characteristics of the reconstructed knees in a sheep model of anterior cruciate ligament (ACL) replacement. **Methods:** Twenty-five female sheep underwent excision of the proximal third of the left ACL and intra-articular joint stabilization with a 44-strand polyethylene terephthalate ligament (mean ultimate tensile failure load, 2,500 N). Animals were killed either 3 or 12 months after surgery. Explanted knees were processed for histology (n = 10) or mechanical tests including tests of laxity and loading to failure in tension (n = 15). **Results:** Well-vascularized tissue ingrowth within the artificial ligament was only observed in the portions of the ligament in contact with the host's tissues (native ligament and bone tunnels). Ligament wear was observed in 40% of explanted knees. The ultimate tensile failure loads of the operated knees at both time points were inferior to those of the contralateral, intact knees (144 ± 69 N at 3 months and 260 ± 126 N at 12 months versus $1,241 \pm 270$ N and $1,218 \pm 189$ N, respectively) ($P < .01$). In specimens with intact artificial ligaments, failure occurred by slippage from the bone tunnels in all specimens explanted 3 months postoperatively and in half of the specimens explanted 12 months postoperatively. **Conclusions:** This study provides evidence that the LARS AC has a satisfactory biointegration but that it is not suitable for ACL replacement if uniform tissue ingrowth is contemplated. Despite good clinical performance up to 1 year after implantation, none of the reconstructions approached the mechanical performance of the normal ACL in the ovine model. Partial tearing of the artificial ligament, which led to a significant decrease in ultimate tensile strength, was observed in 40% of cases in the ovine model. **Clinical Relevance:** The LARS is not a suitable scaffold for ACL replacement. Further animal studies are needed to evaluate its potential for augmentation of ligament repair.

From Université Paris-Est, Ecole Nationale Vétérinaire d'Alfort (V.V., M.M.), Maisons-Alfort; Laboratoire de Bioingénierie et Biomécanique Ostéo-articulaire, Unité Mixte de Recherche-Centre National de la Recherche Scientifique (UMR-CNRS) 7052 (V.V., M.M., F.A.), and Unité de Formation et de Recherche d'Odontologie, Hôpital la Pitié Salpêtrière, AP-HP, Université Paris 7-Diderot (F.A.), Paris; Arts et Métiers ParisTech, Laboratoire de Biomécanique (S.G., D.M.), Paris; and Université Paris 13, Laboratoire de Biomatériaux et Polymères de Spécialité/Chimie, Structures, Propriétés de Biomatériaux et d'Agents Thérapeutiques, UMR-CNRS 7244 (V.M.), Villeneuve, France.

The authors report the following source of funding in relation to this article: Agence Nationale de la Recherche.

Received July 11, 2012; accepted February 27, 2013.

Address correspondence to Véronique Viateau, D.M.V., Ph.D., Ecole Nationale Vétérinaire d'Alfort, Service de Chirurgie, 7 Avenue du Général de Gaulle, 94704 Maison-Alfort Cedex, France. E-mail: vviateau@vet-alfort.fr

© 2013 by the Arthroscopy Association of North America
0749-8063/12453/\$36.00

<http://dx.doi.org/10.1016/j.arthro.2013.02.025>

Surgical techniques based on autologous tissue grafts are the gold standard for the reconstruction of anterior cruciate ligament (ACL) ruptures. However, there are circumstances in which these techniques have limitations: (1) when early rehabilitation is imperative, (2) in the presence of multiple ligament injuries, and (3) in revision surgeries in which the availability of autologous tissue for reconstruction is limited. In these challenging situations, the use of an artificial ligament is an appealing alternative strategy because it could avoid all the drawbacks and problems arising from the use of autografts and allografts, such as reduced mechanical properties during tissue remodeling, graft harvest morbidity, and the possibility of pathogen transmission.

The use of nondegradable artificial ligaments has not been popular in the past because the devices introduced 30 years ago resulted in unacceptable high failure rates.^{1,2}

Whereas ACL reconstruction with these devices has given excellent short-term results, long-term efficacy results have indeed been poor; ruptures of the prostheses were reported in up to 28% of cases, and a high incidence of clinical synovitis was observed.^{1,2} Analysis of retrieved devices has provided evidence that the abrasion of textile fibers (as a result of yarn-on-yarn and/or yarn-on-bone contact) was the primary cause of artificial ligament failure.³ Moreover, tissue ingrowth inside explanted devices was poorly organized, incomplete, and unpredictable, resulting in the separation of polyester fibers and major structural changes.⁴

Improvements in manufacturing of biomaterials have made available a new generation of artificial ligaments that exhibit better biocompatibility (obtained by removal of potential machining residues and oils that could elicit synovitis) and better design (which increases resistance to torsional fatigue and to wear and tear). The Ligament Advanced Reinforcement System for ACL repair (LARS AC; LARS, Arc sur Tille, France) has been used for ACL reconstruction in humans since 1992.⁵ The main innovation of this polyethylene terephthalate (PET) ligament lies in its ability to mimic the natural ligamentous structure and reduce shearing forces by orientating the multiple parallel fibers of the intra-articular portion of the ligament either clockwise for use in a right knee or counterclockwise for use in a left knee.⁶ Several clinical prospective trials have reported successful functional outcomes after treatment of ruptured ACLs and Achilles tendons with the device, with no adverse inflammatory reactions.⁷⁻¹⁰

Although these preliminary clinical investigations have given encouraging results, the patterns of tissue ingrowth within both the intra-articular and intra-osseous portions of a nondegradable ligament are unknown but are important issues to address because they may impact long-term functional results.¹¹ Despite good short-term results, there is concern that late failure may occur based on the results of other PET grafts.¹¹ With the exception of one case report in which a biopsy of the implanted ligament was performed in a 42-year-old patient (who needed surgical revision for another orthopaedic condition) and of 2 case reports in which a disabling synovitis prompted the removal of the ligament, tissue ingrowth within the LARS AC artificial ligament has not been evaluated yet.¹²⁻¹⁴

The purpose of this study was to assess the nature and pattern of tissue ingrowth within LARS AC ligaments implanted in a sheep model of ACL replacement, as well as the biomechanical behavior of the reconstructed knees at 3 and 12 months postoperatively. Our hypothesis was that short-term implantation of the LARS AC ligament would result in uniform tissue ingrowth within the ligament, resulting in mechanical characteristics of reconstructed knees similar to those of unoperated, contralateral knees at 12 months postoperatively.

Methods

Artificial Ligaments

The LARS AC ligament implanted in this study consists of 44 strands of PET fiber. The 2 segments that are to be positioned in the bone tunnels are composed of longitudinal fibers (25- μ m-diameter circular PET fibers) bound together by a transverse PET knitted structure (25- μ m-diameter polygonal PET fibers); the intra-articular segment is composed of parallel, 25- μ m-diameter circular longitudinal fibers twisted at 90°. The mean value of its ultimate tensile failure load is 2,500 N.

Animals

Twenty-five 2-year-old, female pré-Alpes sheep (each weighing approximately 60 kg on average) free of degenerative joint disease (as evidenced by preoperative radiographs) were obtained from a licensed vendor and raised according to guidelines published for the care and use of laboratory animals.

Surgical Procedure

Sheep were administered a prophylactic intramuscular dose (500,000 IU) of penicillin before surgery. Anesthesia was induced by intravenous administration of thiopental (12 mg/kg) and maintained through inhalation of a mixture of oxygen and isoflurane. Each sheep was then positioned in right lateral recumbency, and its left hind limb was prepared for aseptic surgery and draped by sterile procedures.

A lateral arthrotomy was performed, and the patella was retracted medially. The ACL was cut close to its femoral attachment; its proximal third was resected with a No. 11 Swann Morton blade (Swann-Morton Limited, Sheffield, UK), leaving its distal two-thirds intact. The knee was stabilized with a 44-strand LARS ligament (LARS AC44; ultimate tensile failure load, 2,500 N). In brief, the artificial ligament was placed intra-articularly through two 5-mm-wide femoral and tibial bone tunnels drilled from inside out at the site of the femoral insertion and immediately behind the tibial insertion of the ACL. The ligament was inserted so that its knitted portions remained in the bone tunnels and the parallel longitudinal fibers lay intra-articularly. Before fixation of the ligaments with two 6-mm titanium interference screws, implanted outside-in, the knees were ranged to ensure isometry of the ligaments. Once the screws were secured, the drawer sign was checked and the free ligament extremities were cut flush with the surface of the bone with a Bard-Parker blade. The cruciate ligament stump was not fixed or tensioned with sutures. The joint was copiously lavaged with sterile distilled water plus 0.9% sodium chloride before closure of the capsule with 3-decimal polyglactin 910 (Vicryl; Johnson & Johnson Medical Ltd, Livingston, West Lothian, UK) interrupted sutures. Fascia and skin were closed with a 3-decimal

polyglactin 910 (Vicryl) continuous suture pattern and 2-decimal polyamide (Ethilon; Ethicon) interrupted suture pattern, respectively.

Postoperative Care and Examinations

Postoperative analgesia was provided to all sheep through intravenous injections of meloxicam (0.5 mg/kg) 30 minutes before, at the end of, and 72 hours after the surgical procedure. Standard craniocaudal and mediolateral oblique radiographs were taken at the end of the surgical procedure; the positions of the interference screws were noted. A light protective dressing was applied on the surgical wound and changed as needed until removal of the skin sutures 14 days after surgery. The animals were left free to ambulate without restriction for the whole duration of the study. Orthopaedic examinations were performed at monthly intervals until the animals were killed. The animals were then sedated, and both knees were evaluated for the presence of a positive anterior drawer sign. Synovial fluid samples were subsequently collected under aseptic conditions for cytology evaluation and glucose and protein dosages. The animals were euthanized either 3 months ($n = 12$) or 12 months ($n = 13$) postoperatively with a barbiturate overdose.

Explanted Specimen Analysis

Immediately after euthanasia, the knee joints were examined for evidence of anterior drawer instability and subsequently excised. Both operated and unoperated hind limbs were explanted. Knees were processed for either (1) histology, to assess—under standard and polarized light microscopy—tissue ingrowth, cellularity, and the presence of wear debris in the intra-articular and intraosseous portions of the artificial ligament (5 operated specimens explanted at each time point); or (2) mechanical tests including kinematic analysis and loading to failure in tension (7 operated and 7 unoperated contralateral knees and 8 operated and 8 unoperated contralateral knees explanted at 3 and 12 months postoperatively, respectively). The macroscopic aspect of the internal joint components (articular capsule, artificial ligament, menisci and cartilage surfaces of femoral condyles, and patella) were recorded either before being processed for histology or after kinematic analysis, before load-to-failure tests.

Histologic Analysis

Specimens underwent radiography (Faxitron LX-60; Faxitron Bioptics, Tucson, AZ) and were fixed in 10% neutral buffered formalin for 2 weeks. Intra-articular portions of explanted artificial ligaments, as well as the proximal part of the tibial bone (including the tibial bone tunnel), were excised and embedded in methyl methacrylate. Embedded specimens were subsequently cut in a transverse fashion (either perpendicular to the long

axis of the artificial ligament for the intra-articular portions of the ligament or to the interference screw, as previously determined on the radiographs for the intraosseous portion) with a circular water-cooled diamond saw (Leitz 1600; Leica, Nussloch, Germany). Four sections were selected for analysis: one section located in the tibia, near the tibial plateau (for the intraosseous portion of the ligament), and 3 sections located at the distal, middle, and upper third of the intra-articular portion of the ligament. These sections were ground down to a thickness of 0.1 mm, polished, and surface stained with Stevenel blue and van Gieson picrofuchsin, using standard procedures. Tissue ingrowth within the intra-articular portion of the artificial ligament, as well as the bone-ligament interface, was determined for each sheep specimen from these histologic sections.

Mechanical Tests

The excised joints (including the synovial capsule, the distal part of the femur, the proximal part of the tibia, the patella, and a portion of the quadriceps tendon) were kept frozen at -20°C and were thawed at room temperature for 24 hours before biomechanical experiments. All tests were performed at room temperature; dehydration of the specimens was prevented by spraying 0.9% saline solution during testing. The biomechanical experiments included an anterior drawer test (to assess joint laxity) and a failure test (to assess the bone anchorage of the artificial ligament).

Anterior Drawer Experiments. Knee harvesting was performed, leaving the joint capsule, the collateral ligaments, and the distal fourth of the quadriceps muscles, patella, and tibiopatellar tendon intact. Contralateral, unoperated joints were also prepared and tested and served as controls. Markers (tripods) were positioned on the femur, tibia, and patella. Tests were performed with the specimens mounted on a custom-made device similar to a KT-1000 arthrometer (MEDmetric, San Diego, CA), with the joint in 40° of flexion and neutral rotation. Six cycles of loading were applied to reach a tensile force of 100 N on the proximal third of the tibia, perpendicular to the tibial shaft in the anterior direction. The magnitude of anterior drawer was recorded with an optoelectronic measurement system (Polaris; NDI, Waterloo, Ontario, Canada).

Load-to-Failure Experiments. The joint capsule, collateral and posterior cruciate ligaments, and extensor mechanism were excised, and the free ends of the tibia and femur (cut 10 cm proximal and distal to the joint line) were embedded in steel cylinders by use of a low temperature—melt alloy (MCP70). These specimens were subsequently mounted on the testing machine (Instron 5566; Instron, High Wycombe, England) with a 5-kN load cell and tested at room temperature. The

flexion angle of the joint was set to align the axis of the applied load with the ACL direction and both interference screws. A preload of 50 N was applied, followed by preconditioning (10 cycles between 5 and 50 N), a 120-second relaxation at 100 N, and a pullout test (at a displacement rate of 5 mm/min). Maximum load to failure was calculated from the load-displacement curve, and failure modes were video-recorded for each tested specimen.

Data Analysis

Statistical analyses were performed using XLSTAT software (Addinsoft, Paris, France) to evaluate the effect of implantation time on biomechanical properties. Numerical data were expressed as mean \pm standard deviation. They were analyzed by use of nonparametric Mann-Whitney tests. The significance level was set at $P \leq .05$.

Results

Clinical Results

Permanent weight bearing was observed in all sheep at all strides within 15 to 21 days after surgery until the time of animal death at 3 and 12 months postoperatively. The knees were stable when evaluated for the anterior drawer sign in awake animals at all time points. However, an anterior drawer sign was present in all anesthetized animals as soon as 1 month postoperatively and was observed at the time of death.

Synovial Fluid Analysis

Cellularity and protein contents of collected synovial fluid increased during the first 2 postoperative months and subsequently decreased to remain slightly above the normal physiological levels 3 months postoperatively (Fig 1). Values obtained 12 months postoperatively did not differ from those obtained at 3 months.

Necropsy Findings

Gross examination of explanted joints showed that all artificial ligaments were covered by a connective tissue layer; native ligament fibers could not be distinguished from the fibers of the artificial ligaments. The artificial ligaments were found intact in 13 of 25 explanted knees. Wear, resulting in a partially ruptured artificial ligament, was observed in 10 explanted knees. In all cases artificial ligament tears occurred at the level of the intra-articular portion of the ligament, and in all cases they were confined to the lateral aspect of the ligament, either at the level of the medial aspect of the lateral femoral condyle or just above the tibial tunnel opening. The incidence of wear was similar between specimens explanted 3 months postoperatively and specimens explanted 12 months postoperatively (5 of 12 specimens and 5 of 13

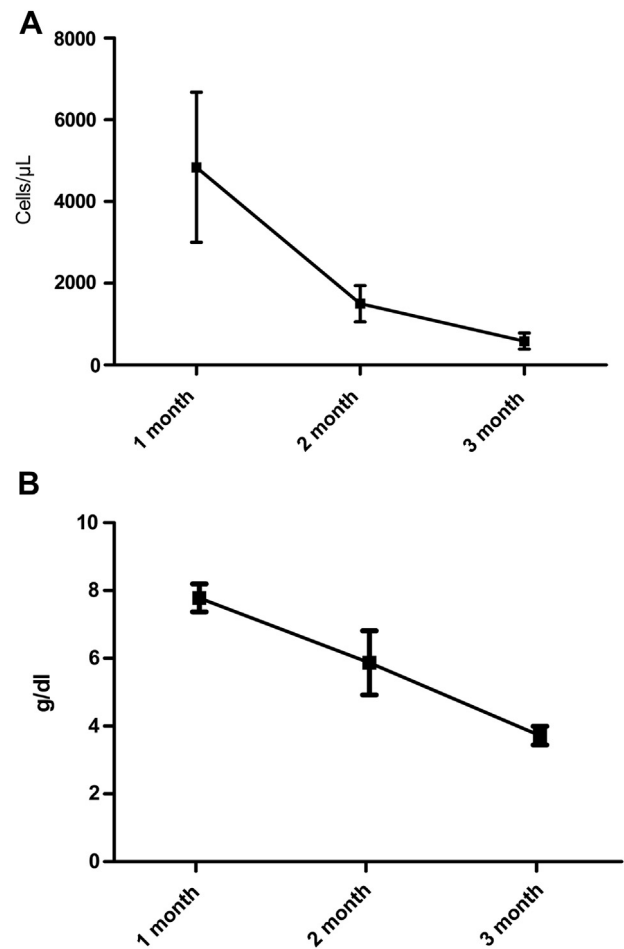


Fig 1. Cellularity (A) and protein contents (B) in synovial fluids collected at monthly intervals during 3 postoperative months. Physiological values for synovial fluid in sheep are as follows: cellularity, 180 cell/mL; protein, 2.3 to 3.0 g/dL.

specimens, respectively). In 2 specimens slippage from either the femoral or the tibial tunnel led to an untensioned intra-articular portion of the artificial ligament.

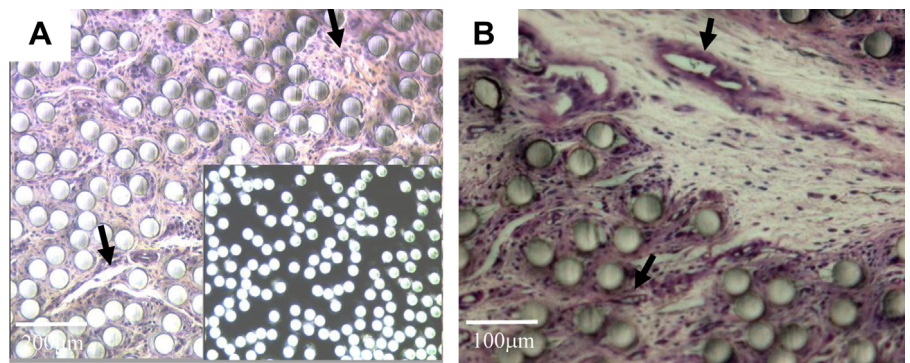
Radiographic Findings

Radiographic examination of explanted specimens at both time points did not show any anomaly.

Histology

Fibrous tissue ingrowth was observed between fascicles and individual PET fibers in the intra-articular portion of explanted artificial ligaments at the 2 explantation time points (Figs 2 and 3). Variations were observed within different sections of the same ligament: dense, well-vascularized fibrous tissue ingrowth was seen within fibers and fascicles located in the close vicinity of the native ligament stump (i.e., the distal third of the artificial ligament) (Figs 2 and 3A and 3B), whereas in the portions located in its central and upper thirds, tissue ingrowth was limited to a scarce, loose, and paucicellular fibrous tissue (Fig 3B). Remnants of the native ACL were observed in 6

Fig 2. Light photomicrographs of representative transversal sections of intra-articular portion of artificial ligament explanted 3 months postoperatively (Stevenel blue stain for visualization of cell nuclei). Fibrous tissue ingrowth between fascicles and circular PET fibers was associated with modifications of the original architecture of the fascicles and individual PET fibers within the fascicles. The inset in A is shown under polarized light. (A, B) Tissue was well vascularized (arrows).



of 10 specimens and at both explantation time points. In the specimens explanted 12 months postoperatively, native and artificial ligament fibers were closely linked. At this time point, fibrocartilaginous tissue was observed within the PET fibers located at the level of the tibial plateau (Fig 3C).

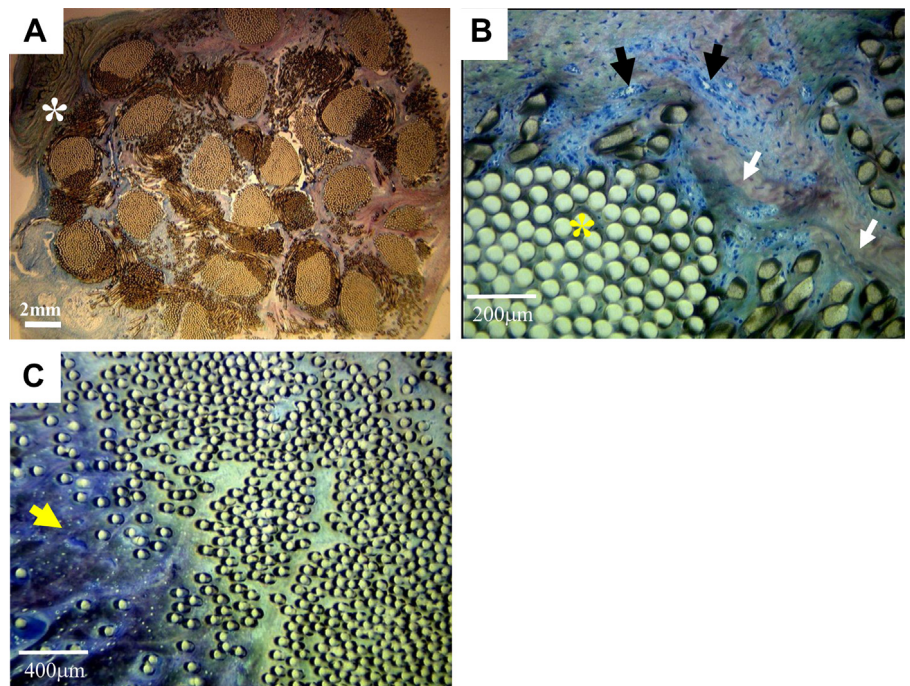
Connective fibrous tissue ingrowth occurred between the fascicles and PET fibers in the intraosseous portion of all explanted artificial ligaments (Fig 4A, 4B, 4C, and 4D). This fibrovascular tissue layer localized at the bone–artificial ligament interface was more dense in specimens explanted 12 months after implantation compared with that observed at 3 months after implantation. Organized, perpendicular Sharpey-like collagen fibers were observed between the artificial ligament and the surrounding bone (Fig 4B and 4D [inset]). Direct device-to-bone contact was observed in

some specimens (3 of 5 specimens and 2 of 5 specimens explanted at 3 and 12 months, respectively) (Fig 4E).

Local foreign-body reaction with numerous giant cells was observed around fibers in the intraosseous part of the artificial ligament at both time points of explantation (Figs 4C and 4F). This reaction was more pronounced than that observed around the circular PET fibers of the unknitted portion of the ligament. In contrast, few giant cells were observed at the level of the intra-articular portion of the artificial ligament.

Wear particles associated with giants cells were few and inconsistently observed (Fig 5). They were seen in 3 of 5 specimens (2 with an intact ligament and one with partial rupture of the device) explanted 3 months postoperatively and in 2 of 5 specimens (one with a partially ruptured ligament and one with an intact ligament) explanted 12 months postoperatively.

Fig 3. Light photomicrographs of representative transversal sections of intra-articular portion of artificial ligament explanted 12 months postoperatively (Stevenel blue stain for cell nuclei visualization). (A) Fibrous tissue ingrowth occurred in continuity with the native ACL (asterisk). (B) Tissue within the fascicles was rich in cells, blood vessels (black arrows), and fibers (white arrows). A loose, paucicellular tissue and occasionally an amorphous protein were observed between PET circular fibers in the central core of the fascicles (yellow asterisk). (C) PET fibers were in areas close to the tibial plateau embedded in fibrocartilage tissue (arrow).



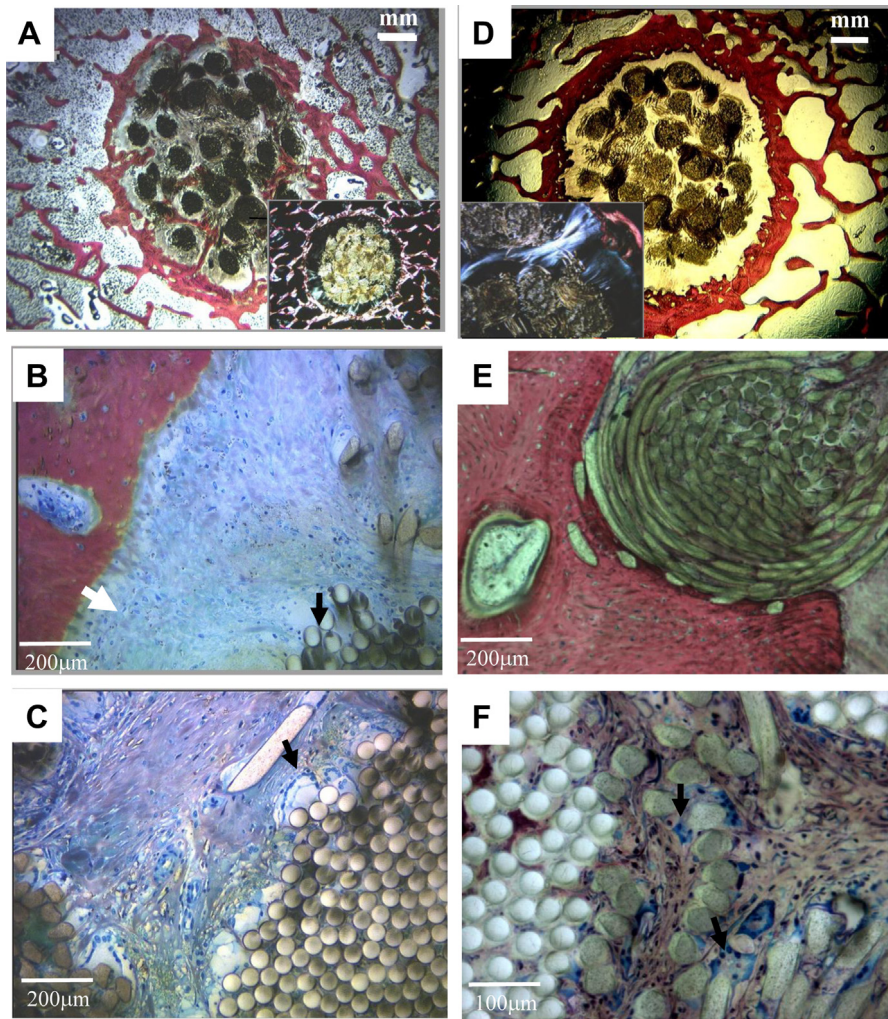


Fig 4. Photomicrographs of representative transversal sections of intraosseous portion of artificial ligament explanted 3 months (A, B, and C) and 12 months (D, E, and F) postoperatively (Stevenel blue stain for visualization of cell nuclei and van Gieson picrofuchsin stain for staining bone tissue). Insert in A and D are shown under polarized light. (A, D) Fibrous tissue ingrowth occurred around the artificial ligament, as well as between its fascicles and individual fibers. (C) Sharpey-like collagen fibers (white arrow) were observed at the ACL-bone interface. (A, E) PET fibers were in direct contact with the surrounding bone in some areas. (C, F) Giants cells (black arrow) were in contact with both circular and polygonal PET fibers at both explantation time points.

Biomechanical Tests

Kinematic Analysis. The anterior drawer sign was present in all explanted specimens at 3 months (2.8 ± 1.7 mm) and at 12 months (2 ± 0.8 mm) after implantation. These values differed significantly ($P < .01$) from those recorded in the contralateral, unoperated knees at 3 months (0.6 ± 0.5 mm) and 12 months (0.2 ± 0.1 mm). The anterior drawer signs measured in explanted specimens with worn and

intact artificial ligaments were similar. The anterior drawer signs measured in explanted knees at 3 and 12 months were similar (Fig 6A), which presents the ratio between the implanted and the unoperated, contralateral knees in terms of anterior tibial translation.

Failure Load. In specimens with intact artificial ligaments, failure in tension occurred by slippage of the ligament from either the femoral or the tibial bone

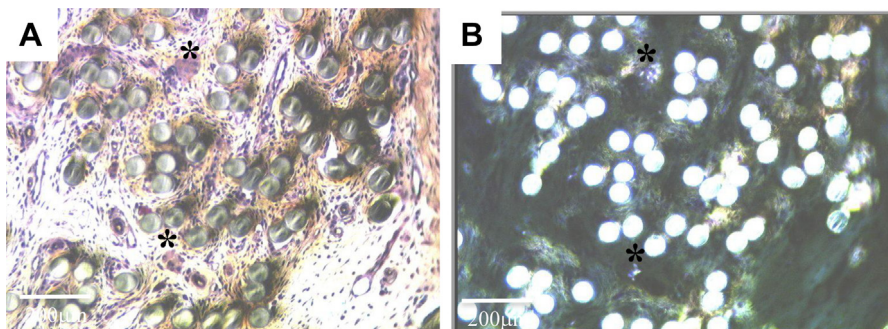


Fig 5. Photomicrographs of representative transversal sections of intra-articular portion of artificial ligament explanted 3 months postoperatively (Stevenel blue stain for visualization of cell nuclei). Wear particles (A, shown under polarized light) were associated with giant cells (B) (asterisks).

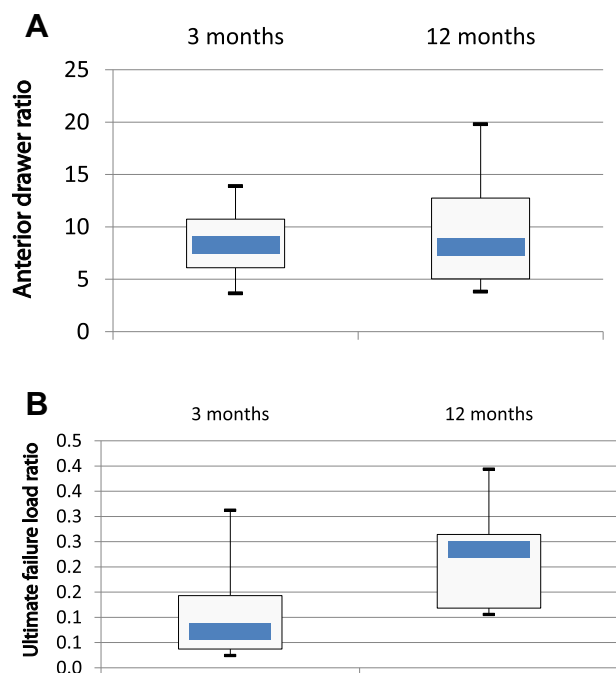


Fig 6. Ratios between artificial and corresponding contralateral native ligament for anterior drawer test (A) and pullout test (B).

tunnels in all specimens explanted 3 months postoperatively and in half of the specimens explanted 12 months postoperatively. In specimens with worn artificial ligaments, failure always occurred by intra-articular rupture at the level at which partial rupture was initially documented, at both explantation time points.

The failure loads in tension of knees explanted 3 and 12 months postoperatively were 144 ± 69 N and 260 ± 126 N, respectively. These values were lower than those obtained from the contralateral intact knees ($1,241 \pm 270$ N and $1,218 \pm 189$ N, respectively) ($P < .01$). Failure loads obtained from knees at 12 months tended to be superior to failure loads at 3 months (Fig 6B); reference to the contralateral knees has been used for comparison facilities between groups. The difference, however, was not statistically significant ($P = .053$). The ultimate tensile failure load differed significantly ($P = .008$) between partially ruptured and intact devices (58 ± 28 N and 186 ± 53 N, respectively).

Discussion

The LARS AC is a third-generation synthetic ligament, designed to overcome the issues of failure and synovitis that led previous generations of synthetic ligaments to fall out of favor. Reported short-term and midterm outcome scores are good for this ligament and comparable to those for autograft techniques.¹⁵ However, the nature and pattern of tissue ingrowth within LARS AC ligaments and subsequent biomechanical behavior have

not yet been studied. In this study a LARS AC ligament was used to replace the native ACL in a sheep model of ACL rupture. We hypothesized that short-term implantation of the LARS AC ligament would result in uniform tissue ingrowth within the ligament, resulting in mechanical characteristics of reconstructed knees similar to those of unoperated, contralateral knees 12 months postoperatively. Well-vascularized dense tissue ingrowth was documented in all the portions of the ligament lying in the close vicinity of the host tissues, providing evidence that it has an adequate biological behavior. However, tissue ingrowth was poor within the intra-articular portions of the ligament not in contact with the native cruciate ligament remnants, and none of the reconstructions approached the mechanical performance of the normal ACL in the ovine model. Twelve months postoperatively, the ultimate failure load was indeed about 25% and in no instance was higher than 40% of the load of the unoperated, contralateral knee.

Replacement of the ACL by the LARS AC artificial ligament was well tolerated in all animals. Although a more pronounced local foreign-body reaction was observed around polygonal fibers located in the intra-osseous portions of the ligament, no adverse inflammatory reaction was observed at either explantation time point. At necropsy, all intra-articular artificial ligaments were entirely covered by a thin connective tissue layer and the native ligament's fibers could not be distinguished from the artificial ligament fibers' remnants. However, histologic examination provided evidence that tissue ingrowth was heterogeneously distributed within the PET fibers. Important variations were indeed observed between histologic sections of the same device, suggesting that local conditions are of utmost importance in the pattern of tissue ingrowth.

Dense, cell-rich, well-vascularized tissue (either fibrous or bone tissue) ingrowth was observed in all portions in which the PET fibers were located within close proximity to the host's tissues (i.e., native cruciate ligament stump and bone lining the tunnels). Interestingly, in regions close to the tibial plateau, highly functionally specialized tissue ingrowth, similar to the natural fibrocartilaginous ligament-to-bone insertion (which is believed to achieve effective, gradual load transfer between ligament and bone), was observed in specimens explanted 12 months postoperatively.^{16,17} All these observations show that the LARS AC ligament allows fine-tissue ingrowth, provided that it is implanted adjacent to the host's tissues. Further animal studies are thus needed to confirm that it is an appropriate scaffold to consider for ligament repair augmentation procedures. However, because loose, paucicellular tissue ingrowth was consistently observed in the upper third of the intra-articular part of the artificial ligament (in which no tissue could indeed be counted on as a source of cells), it may not be adequate for ligament

replacement. In fact, many authors point out the importance of the adjunction of cells to the scaffold to promote cell-mediated tissue regeneration for ligament tissue engineering purposes.⁶

In this study the mechanical properties of reconstructed knees remained inferior to those of intact, unoperated, contralateral knees, which showed better failure loads and inferior anterior drawer laxity.

The loading direction in our study was performed in line with the interference screws, thus simulating a worst-case scenario. Such an experimental design allowed testing of ligament-to-bone fixation and of the intra-articular portion of the ligament, with failure occurring at the level of the weakest part of the reconstruction. At 3 months, all intact ligaments failed by the ligament sliding from one of the bone tunnels, suggesting that—provided that no wear was present—the ligament-to-bone fixation was the weakest link of the reconstruction in the early postoperative period. This is in agreement with reports that, in humans and animals, fixation of autologous grafts is a weak link in the rehabilitation process.^{18,19} Twelve months postoperatively, half of the knees with intact ligaments failed by slippage of the ligament from the bone tunnels. These results show that, although the ligament-to-bone fixation improved over time, it remained the weakest part of the reconstruction 12 months postoperatively in 50% of the specimens. Moreover, failure in tension was highly variable, with most of the failures occurring from 10% to 25% of normal anatomy.

Wear is an important issue to address when evaluating an artificial ligament because it leads to fiber disruption and potentially to ligament failure. In this study worn artificial ligaments indeed exhibited significantly inferior tension failure loads than did intact ligaments, and failure during tension loading always occurred at the level of the disrupted fibers. The intra-articular portion of the LARS AC was designed to facilitate even tensioning of the graft fibers during knee movement and aims to prevent the fiber breakdown that was previously seen in grafts made from woven materials.²⁰ Wear of artificial ligaments was observed in 40% of the knees explanted in this study, which compares favorably with former studies of a similar model in sheep in which either Gore-Tex (Gore Inc, Flagstaff, AZ), Aramid prototype Leeds-Keio (Biomet, South Glamorgan, UK), or composite (Poly(L-lactide) [PLA] and poly(L-lactide-co-glycolide) 90/10 [LG 90/10]) artificial ligaments were implanted and in which wear and rupture were observed in 81% to 100% of cases 12 weeks and 6 months postoperatively.²¹⁻²³ However, the incidence of wear observed in our animal model contrasts with the low incidence reported in the clinical situation. In human subjects, ruptures of implanted artificial LARS AC

ligaments have indeed rarely been reported and seldom occur before 5 years postoperatively. However, it should be noted that second-look arthroscopy was not routinely performed in these studies, and rupture was only documented at the time of revision surgery in symptomatic patients. In our study none of the animals in which wear occurred became lame on a visual scale analysis, indicating that in this animal model, wear was clinically well tolerated. Although walking platform gait analysis is needed to definitively determine lameness in this animal model, this observation suggests that wear of the device may start in the early postoperative period and be present in otherwise clinically sound subjects. In a clinical retrospective study, Gore-Tex ligament damage was indeed present in 38% of cases when routine, second-look arthroscopy was performed 11 months postoperatively.²⁴ Furthermore, in a 19-year clinical outcome study, of the 51 patients followed up, 27.5% were found to have ruptured their PET ligaments.²⁵ However, improved biocompatibility of the new-generation ligaments, preservation of sufficient knee stability, and factors pertaining to the weight-bearing pattern in quadrupeds, as well as the short follow-up period, may have accounted for the good clinical functional results observed in the sheep.

The cause of artificial ligament wear could not be determined with certainty in our study. Many factors such as inappropriate bone tunnel positioning, cyclic bending of the ligament around sharp bony edges, friction between fibers, and loss of fixation of the device can be advocated because this is the case in human subjects.

Regaining knee stability for a positive long-term outcome of ACL reconstruction is a critical issue.¹⁹ Despite initial postoperative stability, anterior laxity was observed in all anesthetized animals in our study as soon as 1 month postoperatively and did not decrease between 3 and 12 months after implantation. This finding was in accordance with a clinical study in humans in which laxity was found postoperatively in 90% of knees stabilized with a LARS ligament.⁵ Whether laxity was linked to postoperative slippage along the interference screws, distension, or partial rupture of the artificial ligament could not be established with certainty in this study. Yet several observations suggested that slippage of the ligament significantly contributed to laxity in the animal model tested: (1) in some specimens, knitted portions of the artificial ligament were found in the joint space 3 months postoperatively; (2) anterior drawer measurements did not differ among specimens with worn and intact ligaments; and (3) lengthening of the LARS AC did not exceed 1.5% after 1,700-N loads were applied in tension in a former mechanical study (unpublished data, 2006).

Limitations

Several limitations of this study need to be discussed. First, although the anatomic design of human and sheep knees is very similar, different anatomic characteristics and weight-bearing conditions in sheep must be taken into account when interpreting our results: (1) Joint loading does not occur in full extension in sheep—the knee remains in over 50° of flexion during the loaded phase of gait, which increases tibial thrust.²⁶ (2) The sheep knee has an increased tibial slope and a narrow intercondylar notch, both of which are recognized as predisposing factors to ACL damage.²⁷ (3) Subchondral cancellous bone lamella is very thin in sheep, which may negatively impact early ligament fixation with interference screws.¹⁹ (4) Bone tunnel positioning and orientations (which were established in this study according to recommendations made for implantations in humans) may not be optimal in sheep.²⁸ To our knowledge, there are indeed no data in the literature establishing the optimal direction and positioning of the bone tunnels in sheep.²⁹ (5) Finally, animals were left free to ambulate, allowing early, unrestricted weight bearing, whereas controlled postoperative rehabilitation is performed in human subjects. The challenging biomechanical environment in which the ligament was tested may thus explain the high incidence of wear observed in this animal study. Second, a 12-month period allows the evaluation of initial inflammatory response and tissue ingrowth but may not be long enough for evaluating the long-term impact of wear. There is indeed real concern that late failure and iatrogenic osteoarthritis may occur based on the results with other PET grafts.¹¹ The presence of wear debris found in some of the explanted joints in our study is a significant concern because these can potentially generate long-term problems. Thus long-term studies need to be performed in the future.

Conclusions

This study provides evidence that the LARS AC has a satisfactory biointegration but that it is not suitable for ACL replacement if uniform tissue ingrowth is contemplated. Despite good clinical performance up to 1 year after implantation, none of the reconstructions approached the mechanical performance of the normal ACL in the ovine model. Partial tearing of the artificial ligament, which led to a significant decrease in ultimate tensile strength, was observed in 40% of cases in the ovine model.

References

- Murray AW, MacNicol MF. 10-16 Year results of Leeds-Keio anterior cruciate ligament reconstruction. *Knee* 2004;11:9-14.
- Jadeja H, Yeoh D, Lal M, Mowbray M. Patterns of failure with time of an artificial scaffold class ligament used for reconstruction of the human anterior cruciate ligament. *Knee* 2007;14:439-442.
- Poddevin N, King MW, Guidoin RG. Failure mechanisms of anterior cruciate ligament prostheses: In vitro wear study. *J Biomed Mater Res* 1997;38:370-381.
- Guidoin MF, Marois Y, Bejui J, Poddevin N, King MW, Guidoin R. Analysis of retrieved polymer fiber based replacements for the ACL. *Biomaterials* 2000;21:2461-2474.
- Lavoie P, Fletcher J, Duval N. Patient satisfaction needs as related to knee stability and objective findings after ACL reconstruction using the LARS artificial ligament. *Knee* 2000;7:157-163.
- Mascarenhas R, MacDonald PB. Anterior cruciate ligament reconstruction: A look at prosthetics—Past, present and possible future. *McGill J Med* 2008;11:29-37.
- Lavoie P, Duval N. A new generation of artificial ligaments in reconstruction of the anterior cruciate ligament: Two-year follow-up of randomized trial. *J Bone Joint Surg Br* 2002;84:356-360.
- Gao K, Chen S, Wang L, et al. Anterior cruciate ligament reconstruction with LARS artificial ligament: A multicenter study with 3- to 5-year follow-up. *Arthroscopy* 2010;26:515-523.
- Liu ZT, Zhang XL, Jiang Y, Zeng BF. Four-strand hamstring tendon autograft versus LARS artificial ligament for anterior cruciate ligament reconstruction. *Int Orthop* 2010;34:45-49.
- Ranger P, Renaud A, Phan P, Dahan P, De Oliveira E Jr, Delisle J. Evaluation of reconstructive surgery using artificial ligaments in 71 acute knee dislocations. *Int Orthop* 2011;35:1477-1482.
- Mulford JS, Chen D. Anterior cruciate ligament reconstruction: A systematic review of polyethylene terephthalate grafts. *ANZ J Surg* 2011;81:785-789.
- Trieb K, Blahovec H, Brand G, Sabeti M, Dominkus M, Kotz R. In vivo and in vitro cellular ingrowth into a new generation of artificial ligaments. *Eur Surg Res* 2004;36:148-151.
- Glezos CM, Waller A, Bourke HE, Salmon LJ, Pinczewski LA. Disabling synovitis associated with LARS artificial ligament use in anterior cruciate ligament reconstruction: A case report. *Am J Sports Med* 2012;40:1167-1171.
- Li H, Yao Z, Jiang J, et al. Biologic failure of a ligament advanced reinforcement system artificial ligament in anterior cruciate ligament reconstruction: A report of serious knee synovitis. *Arthroscopy* 2012;28:583-586.
- Newman SD, Atkinson HD, Willis-Owen CA. Anterior cruciate ligament reconstruction with the ligament augmentation and reconstruction system: A systematic review. *Int Orthop* 2013;37:321-326.
- Smith L, Xia Y, Galatz LM, Genin GM, Thomopoulos S. Tissue engineering strategies for tendon to bone interface. *Connect Tissue Res* 2011;53:95-105.
- Liu Y, Birman V, Chen C, Thomopoulos S, Genin GM. Mechanisms of biomaterial attachment at the interface of tendon to bone. *J Eng Mater Technol* 2011:133.
- Robbe R, Johnson D. Graft fixation alternatives in anterior cruciate ligament reconstruction. *Penn Orthop J* 2002;15:21-27.

19. Hunt P, Scheffler SU, Unterhauser FN, Weiler A. A model of soft-tissue graft anterior cruciate ligament reconstruction in sheep. *Arch Orthop Trauma Surg* 2005;125: 238-248.
20. Machotka Z, Scarborough I, Duncan W, Kumar S, Perraton L. Anterior cruciate ligament repair with LARS (ligament advanced reinforcement system): A systematic review. *Sports Med Arthrosc Rehabil Ther Technol* 2010;2: 29-39.
21. Schindhelm K, Rogers GJ, Milthorpe BK, et al. Auto-graft and Leeds-Keio reconstructions of the ovine anterior cruciate ligament. *Clin Orthop Relat Res* 1991: 278-293.
22. Dürselen L, Häfner M, Ignatius A, et al. Biological response to a new composite polymer augmentation device used for cruciate ligament reconstruction. *J App Mat Res Part B* 2006;76:265-272.
23. Dürselen L, Claes L, Ignatius A, Rübenacker S. Comparative animal study of three ligament prostheses for the replacement of the anterior cruciate and medial collateral ligament. *Biomaterials* 1996;17:977-982.
24. Ferkel RD, Fox JM, Wood D, Del Pizzo W, Friedman MJ, Snyder SJ. Arthroscopic "second look" at the GORE-TEX ligament. *Am J Sports Med* 1989;17:147-152.
25. Ventura A, Terzaghi C, Legnani C, Borgo E, Albisetti W. Synthetic grafts for anterior cruciate ligament rupture: 19-Year outcome study. *Knee* 2010;17:108-113.
26. Taylor WR, Ehrig RM, Heller MO, Schell H, Seebeck P, Duda GN. Tibio-femoral joint contact forces in sheep. *J Biomech* 2006;39:791-798.
27. Osterhoff G, Löffler S, Steinke H, Feja C, Josten C, Hepp P. Comparative anatomical measurements of osseous structures in the ovine and human. *Knee* 2011;18:98-103.
28. Laboureau J, Marnat-Perrichet FP. Isometric reconstruction of the anterior cruciate ligament. Determination of the femoral and tibial tunnels. *Acta Orthop Belg* 1996;62(suppl 1):166-177.
29. Weiler A, Hoffmann RF, Bail HJ, Rehm O, Südkamp NP. Tendon healing in a bone tunnel. Part II: Histologic analysis after biodegradable interference fit fixation in a model of anterior cruciate ligament reconstruction in sheep. *Arthroscopy* 2002;18:124-135.