



Science Arts & Métiers (SAM)

is an open access repository that collects the work of Arts et Métiers Institute of Technology researchers and makes it freely available over the web where possible.

This is an author-deposited version published in: <https://sam.ensam.eu>
Handle ID: <http://hdl.handle.net/10985/21536>

To cite this version :


Mohamad KARAM, Ismat GHANEM, Claudio VERGARI, Nour KHALIL, Maria SAADE, Céline CHAAYA, Ali RTEIL, Elma AYOUB, Eddy SAAD, Khalil KHARRAT, Wafa SKALLI, Ayman ASSI - Global postural malalignment in adolescent idiopathic scoliosis: The axial deformity is the main driver - European Spine Journal - 2022

Any correspondence concerning this service should be sent to the repository

Administrator : scienceouverte@ensam.eu



Global malalignment in adolescent idiopathic scoliosis: the axial deformity is the main driver

Mohamad Karam¹ · Ismat Ghanem¹ · Claudio Vergari² · Nour Khalil¹ · Maria Saadé¹ · Céline Chaaya¹ · Ali Rteil¹ · Elma Ayoub¹ · Eddy Saad¹ · Khalil Kharrat¹ · Wafa Skalli² · Ayman Assi^{1,2} 

Abstract

Purpose To evaluate the global alignment of non-operated subjects with adolescent idiopathic scoliosis.

Method A total of 254 subjects with AIS and 64 controls underwent low dose biplanar X-rays and had their spine, pelvis, and rib cage reconstructed in 3D. Global alignment was measured in the sagittal and frontal planes by calculating the OD-HA angle (between C2 dens to hip axis with the vertical). Subjects with AIS were classified as malaligned if the OD-HA was > 95th percentile relative to controls.

Results The sagittal OD-HA in AIS remained within the normal ranges. In the frontal plane, 182 AIS were normally aligned (Group 1, OD-HA = 0.9°) but 72 were malaligned (Group 2, OD-HA = 2.9°). Group 2 had a more severe spinal deformity in the frontal and horizontal planes compared to Group 1 (Cobb: 42 ± 16° vs. 30 ± 18°; apical vertebral rotation AVR: 19 ± 10° vs. 12 ± 7°, all p < 0.05). Group 2 subjects were mainly classified as Lenke 5 or 6. 19/72 malaligned subjects had a mild deformity (Cobb < 30°) but a progressive scoliosis (severity index ≥ 0.6). The frontal OD-HA angle was found to be mainly determined (adjusted-R² = 0.22) by the apical vertebral rotation and secondarily by the Lenke type.

Conclusions This study showed that frontal malalignment is more common in distal major structural scoliosis and its main driver is the apical vertebral rotation. This highlights the importance of monitoring the axial plane deformity in order to avoid worsening of the frontal global alignment.

Keywords Adolescent idiopathic scoliosis · Posture · Spine · Axial deformity · 3D reconstruction

Introduction

Scoliosis is a three-dimensional complex deformity of the spine. Adolescent idiopathic scoliosis (AIS) is the most common form, with a risk of curve progression at the pubertal growth spurt [1]. Balance control in these subjects was found to be related to the location of the major curve, the severity of the deformity and the pelvic morphology [2–4].

Physiological postural alignment is achieved when the head, spine and pelvis are aligned to minimize energy expenditure inside the “conus of economy” [5]. Failure to

maintain this condition will enable compensating mechanisms to restore a stable posture, by altering the spinal alignment and pelvic orientation [6] and, in some cases, by recruiting the lower limbs in order to maintain balance [7].

The evaluation of the postural alignment in both the frontal and sagittal planes of subjects with AIS is mainly assessed by measuring the offset between the C7 plumbline and the sacral plate in both planes [8]. Frontal trunk alignment in subjects with AIS was shown to be related to curve progression [9, 10]. Sagittal spinal malalignment can also be expressed by hypokyphosis, cervical kyphosis and altered pelvic orientation [11, 12]. However, these measurements do not take into consideration the global position of the head that tends to be of primary importance for postural balance [13]. In addition, distance parameters, known as offset, do not take into account the height of the subject. Thus, it is preferable to use angular parameters instead.

Evaluation of postural alignment in the horizontal plane is usually assessed by evaluating the axial rotation of the apical vertebra, as well as the pelvic rotation [14].

Only a few studies have described the global alignment of subjects (head to pelvis), although non-alignment of the head above the pelvis has been shown to be an indicator of postural alteration [15, 16]. As a result, it is important to assess the global posture of the patient while considering the position of the head. The angle between the vertical and the line joining the dens of the 2nd cervical vertebra (odontoid) to the hip axis, defined as the OD-HA angle, is a global alignment parameter that was recently introduced [17]. This parameter was found to be the most reliable angle that highlighted the vertical alignment of the head over the pelvis, in both frontal and sagittal planes, in young asymptomatic adults and elderly people [18].

The aim of this study was to evaluate the global postural alignment of non-operated subjects with adolescent idiopathic scoliosis, by measuring the OD-HA angle, and to define the radiological determinants behind malalignment.

Methods

This is an IRB approved (CEHDF742) cross-sectional study of non-operated subjects with AIS. Control subjects that were formerly recruited for previous studies were also included. All subjects or their legal guardians signed a written and informed consent form.

Inclusion criteria of subjects with AIS were aged between 10 and 18 years and a Cobb angle $\geq 10^\circ$. Exclusion criteria were structural leg length discrepancy ≥ 1 cm.

Inclusion criteria of control subjects were aged between 10 and 18 years. Exclusion criteria were underlying musculoskeletal or neurological disorders or a Cobb angle $\geq 10^\circ$.

Data acquisition

Demographic data: age (years), weight (kg), height (m) and gender (female/male) were collected. All subjects underwent full-body low-dose biplanar X-rays (EOS Imaging®, Paris, France). Subjects were placed in the free-standing position [19, 20] and 3D reconstructions of their spine (from C3 to L5), rib cage and pelvis were performed by trained operators. The 3D reconstructions and measurements were performed using a specific software (Arts et Métiers ParisTech, Paris, France) and SterEOS® (EOS® Imaging, Paris, France; version 1.6.5.8188). In brief, a semi-automatic method is used where trained operators have to detect specific anatomical landmarks on the 2D radiographs then adjust a first 3D reconstruction based on a statistical model that is retro-projected on both frontal and lateral X-rays [21]. The contours adjustment automatically corrects the 3D

shape of the skeletal reconstruction of each segment. The 3D reconstruction takes approximately 15 min for the spine and 15 min for the rib cage.

Global alignment in both the frontal and sagittal planes was calculated as the angle between the vertical and the line between the most superior point of the dens of C2 (OD) and the middle of the hip axis (HA). The positioning of the OD was shown to be reliable [17].

Subject classification

Subjects with AIS were grouped according to their frontal and sagittal global alignments (OD-HA angle). For the frontal OD-HA, the absolute value was used, thus grouping both left and right malalignment. Subjects with AIS were categorized into two groups: normal frontal alignment (< 95 th percentile of the control values; Group 1), frontal malalignment (> 95 th percentile of the control values; Group 2). For the sagittal OD-HA, subjects were further categorized into two groups: normal sagittal alignment (> 5 th percentile and < 95 th percentile of the control values), sagittal malalignment (< 5 th percentile and > 95 th percentile of the control values).

Subjects with AIS were further classified according to the location of the apex of the major curve (Thoracic: T; Thoracolumbar: TL; and lumbar: L), Lenke classification (L1 to L6) [22] and Abelin-Genevois sagittal classification (AG1; AG2a; AG2b and AG3) [23].

Radiographic parameters

The following radiographic parameters were calculated:

- Postural parameters
 - Frontal plane: coronal plumbline (C7CSL in mm)
 - Sagittal plane: sagittal vertical axis (SVA in mm) [24], T9 tilt (T9t in $^\circ$) [25], pelvic Shift (Psh in cm, negative when the pelvis is posterior to the distal tibia) [26] and knee flexion (in $^\circ$, flexion +/extension -) [27]
- Spino-pelvic parameters
 - Frontal plane: frontal obliquity of the pelvis (mm)
 - Sagittal plane [28]: C0C2 ($^\circ$) [29], CBVA in ($^\circ$) [30], C3C7 ($^\circ$), cervical sagittal vertical axis (cSVA in mm) [29], T1 slope (T1s in $^\circ$) [31, 32], T1T12 ($^\circ$), T4T12 ($^\circ$), T10L2 ($^\circ$) (negative values indicates kyphosis), L1L5 ($^\circ$), L1S1 ($^\circ$), pelvic incidence (PI in $^\circ$), sacral slope (SS in $^\circ$) and pelvic tilt (PT in $^\circ$)
 - Horizontal plane: pelvic axial rotation ($^\circ$)

- Scoliosis parameters were calculated for both major and secondary (structural or non-structural) curves [33]:
 - Frontal plane: Cobb angle ($^{\circ}$)
 - Sagittal plane: hypokyphosis/lordosis index (HI in $^{\circ}$),
 - Horizontal plane: torsion index (TI in $^{\circ}$), apical vertebral rotation (AVR in $^{\circ}$), intervertebral axial rotation at the upper and lower junction (Upper IAR and Lower IAR in $^{\circ}$)
- Rib cage parameters [34, 35]
 - Frontal plane: width (mm)
 - Sagittal plane: thickness (mm) and volumetric spinal penetration index (VSPI in %)
 - Horizontal plane: gibbosity ($^{\circ}$)
 - volume (cm^3)

All parameters are presented in Figs. 1 and 2. The validity of these measures relatively to gold standard (CT-Scan), as well as their reliability (inter and intra operator test-retest), was previously evaluated and reported in the literature. For instance, the overall error on the axial plane measurement is about 6° [36] with an ICC of 0.95 [37].

Statistical analysis

Differences in demographics (age, weight and height) between subjects with AIS and controls were evaluated using either a Mann–Whitney U test or a Student’s *t* test

depending on data normality (Shapiro–Wilk test). The distribution of gender was compared between groups using Fisher’s exact test.

Differences in radiographic parameters were investigated between aligned and malaligned AIS groups (Group 1 and Group 2) and controls using either a Kruskal–Wallis or ANOVA model (depending on the normality of the data) followed by pairwise comparisons and Bonferroni corrections.

Further explorations were done for subjects with global malalignment, classified in Group 2. The distribution of subjects according to Lenke type was compared using Fisher’s exact test. Differences in Cobb, AVR and frontal OD-HA were tested between Lenke types (independent Student’s *t* test or Mann–Whitney U test). Subjects with Lenke types 1 and 3 were grouped together, as well as those with Lenke types 5 and 6, since these types present a major structural curve at the same spinal level.

In order to investigate if postural malalignment is related to the scoliotic frontal deformity, patients with mild and severe deformity were separately grouped (Group 2a: Cobb $< 30^{\circ}$, Group 2b: Cobb $> 30^{\circ}$) and their radiographic parameters were compared. The severity index [33] was calculated only for subjects in Group 2a since its application is possible solely for AIS with mild scoliosis.

The relationships between OD-HA angle in subjects with AIS and the 3D spino-pelvic and scoliosis parameters were investigated using a univariate analysis (Pearson’s correlation) followed by a multivariate analysis (stepwise multiple linear regression) in order to explore the most significant determinants of malalignment.

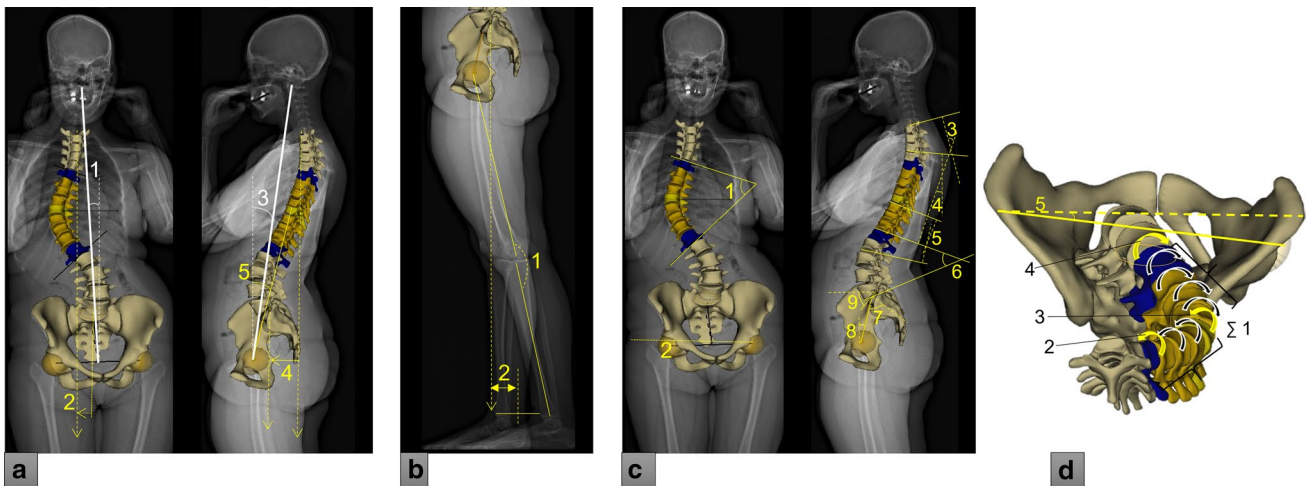


Fig. 1 Global alignment, postural assessment, spino-pelvic and scoliosis parameters. a-1: frontal OD-HA angle, a-2: C7CSL, a-3: sagittal OD-HA angle, a-4: SVA, 5: T9 tilt. b-1: knee flexion, b-2: pelvic shift. c-1: frontal Cobb angle, c-2: lateral pelvic obliquity, c-3: T1T12 kyphosis, c-4: T4T12 kyphosis, c-5: T10L2 thoracolumbar junction,

c-6: L1S1 lordosis, c-7: pelvic incidence, c-8: pelvic tilt, c-9: sacral slope. d-1: torsion index, d-2: upper intervertebral axial rotation, d-3: apical vertebral rotation, d-4: lower intervertebral axial rotation, d-5: pelvic axial rotation

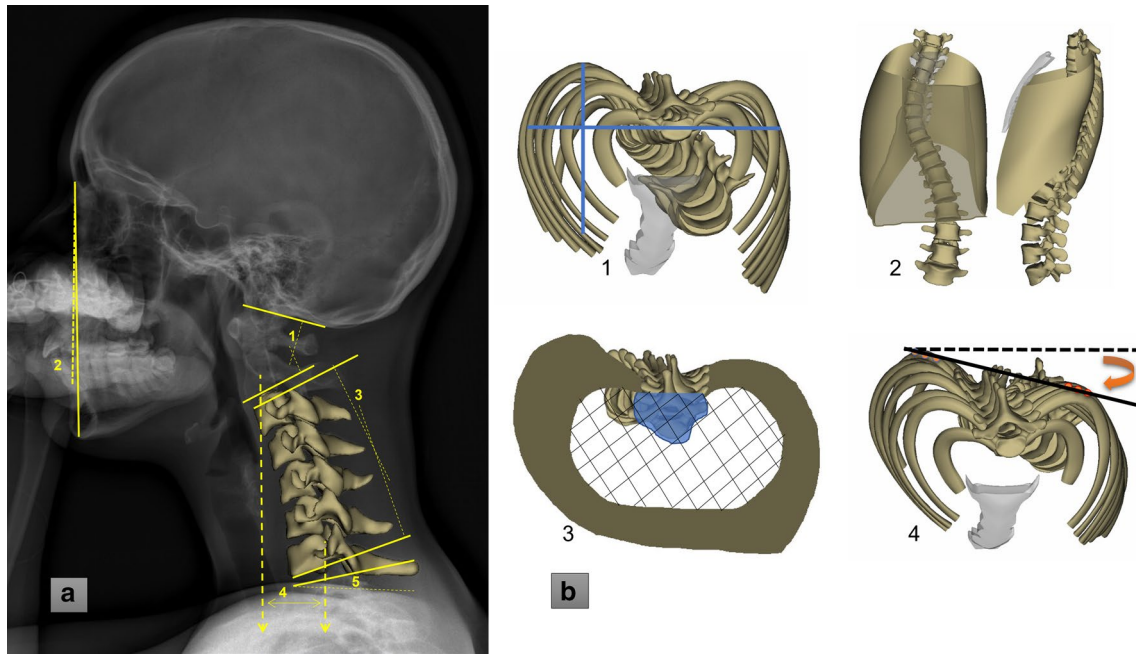


Fig. 2 Cervical spine and rib cage parameters. a-1: COC2 angle, a-2: CBVA, a-3: C3C7 kyphosis, a-4: cSVA, a-5: T1 slope. b-1: width and thickness, 2: volume, 3: volumetric spinal penetration index, 4: gibbosity

The level of significance was set at 0.05 and corrected for in case of multiple comparisons. Statistics were performed using Xlstat® (Addinsoft®, Paris, France; version 2019.1.2).

Results

Sample description

A total of 254 subjects with AIS (216 F/38 M; Cobb: $33 \pm 18^\circ$ [10–107°]) and 64 controls (48 F/16 M) were included. Demographic characteristics did not differ between groups (all $p > 0.05$, Table 1).

The threshold of frontal OD-HA for malalignment was 1.9° (95th percentile in controls). Most AIS patients had normal frontal alignment (Group 1, 72%; $n = 182$ with frontal

OD-HA $\leq 1.9^\circ$), and 28% were frontally malaligned ($n = 72$, Group 2 with frontal OD-HA $> 1.9^\circ$). Sagittal OD-HA angle in AIS patients was similar to controls with no sagittal malalignment ($p = 0.16$) (Fig. 3).

There was a higher rate of major thoracolumbar curves in Group 2 (46%) compared to Group 1 (31%, $p = 0.04$). Similarly, a higher percentage of Lenke 5 curves (46%) was present in Group 2 compared to Group 1 (34%). Abelin-Genevois sagittal classification was similar between groups (Table 2).

As expected, Group 2 had a higher frontal malalignment compared to Group 1 and controls (frontal OD-HA: $2.9 \pm 0.8^\circ$ vs. $0.9 \pm 0.5^\circ$ and $0.8 \pm 0.6^\circ$, respectively, $p < 0.001$) and subjects were similarly aligned in the sagittal plane (Sagittal OD-HA = $-2.5 \pm 2.2^\circ$; $p = 0.24$).

Group 2 had a higher pelvic obliquity compared to controls (6 ± 3 mm vs. 4 ± 3 mm, $p = 0.005$). In addition,

Table 1 Demographics (age, weight, height, gender) for 254 AIS and 64 control subjects

	Control subjects ($n = 64$)		Subjects with Adolescent Idiopathic Scoliosis ($n = 254$)		p -value
	Mean	SD	Mean	SD	
Age (years)	13.7	2.3	14.2	1.9	0.06
Weight (Kg)	52.8	15.1	52.2	11.3	0.50
Height (m)	1.6	0.1	1.6	0.1	0.39
Gender					
Female	48		216		0.055
Male	16		38		

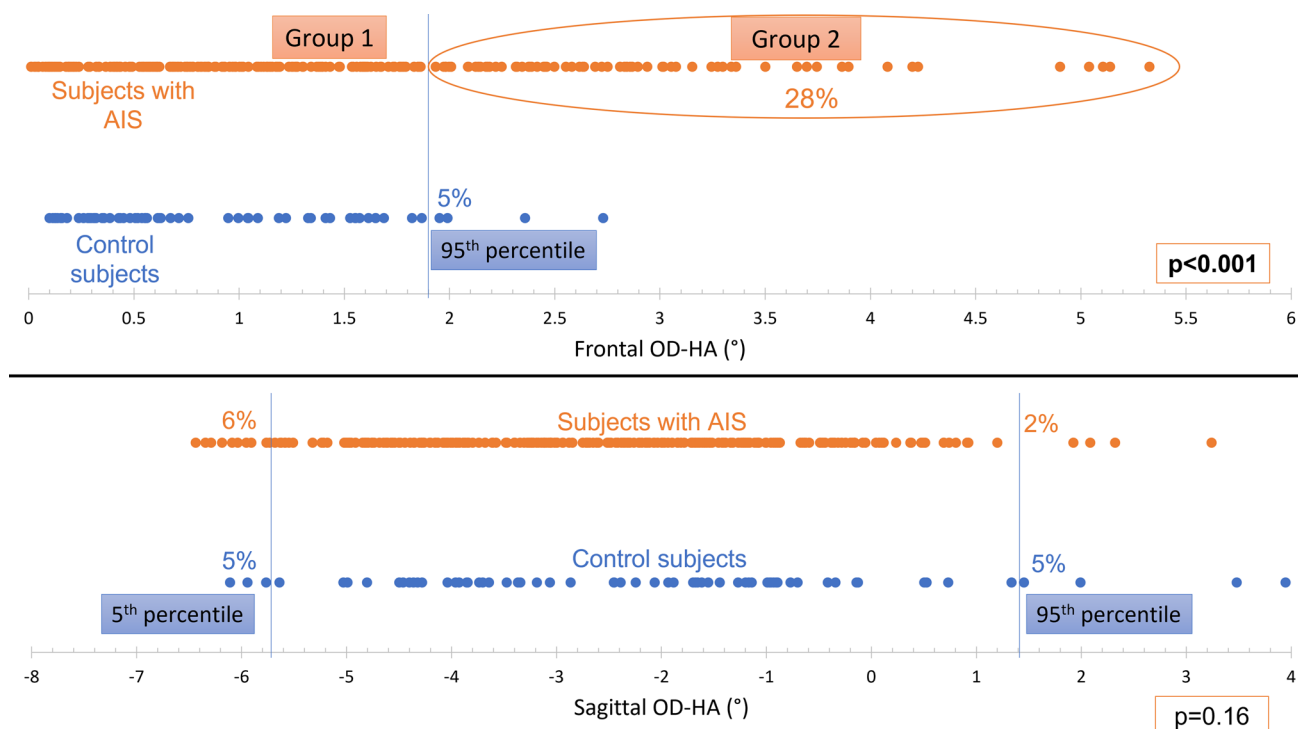


Fig. 3 Distribution of frontal and sagittal OD-HA according to the normative values as defined from the control group

Table 2 Distribution of the AIS sample according to major scoliotic curves, Lenke classification and Abelin-Genevois sagittal classification

	Subjects with AIS; $n = 254$	Group1 (72%; $n = 182$)	Group2 (28%; $n = 72$)	Comparison of distribution between Group 1 & Group 2 (p -value)
Major scoliotic curves	Major thoracic (51%; $n = 129$)	55%; $n = 101$	39%; $n = 28$	0.04
	Major thoracolumbar (35%; $n = 90$)	31%; $n = 57$	46%; $n = 33$	
	Major lumbar (14%; $n = 35$)	13%; $n = 24$	15%; $n = 11$	
Lenke classification	Lenke 1 (38%; $n = 96$)	41%; $n = 75$	29%; $n = 21$	0.12
	Lenke 3 (13%; $n = 33$)	14%; $n = 26$	10%; $n = 7$	
	Lenke 5 (37%; $n = 95$)	34%; $n = 62$	46%; $n = 33$	
	Lenke 6 (12%; $n = 30$)	10%; $n = 19$	15%; $n = 11$	
Abelin-Genevois sagittal classification	AG1 (67%; $n = 170$)	70%; $n = 127$	60%; $n = 43$	0.06
	AG2a (13%; $n = 33$)	12%; $n = 22$	15%; $n = 11$	
	AG2b (4%; $n = 11$)	2%; $n = 4$	10%; $n = 7$	
	AG3 (16%; $n = 40$)	16%; $n = 29$	15%; $n = 11$	

*Bold: Significant p values

patients in Group 2 showed a different pattern of deformity than AIS subjects with normal alignment, as reported in Table 3; for instance, Group 2 presented more severe curves (higher Cobb angle) and showed significantly higher PI and PT, but also TI, upper and lower IAR and AVR ($p < 0.001$).

Features of subjects in Group 2 were further investigated according to the Lenke curve type (Fig. 4). These subjects were mainly classified as Lenke 5 or 6 compared to Lenke 1

or 3 ($n = 44$ vs. 28 , $p = 0.02$). Subjects in Group 2 with Lenke 5 or 6 presented a lower Cobb than those with Lenke 1 or 3 (38 vs. 46° , $p = 0.04$) but a similar AVR (18°).

Sub-groups depending on frontal severity

In the Group 2, 19/72 subjects had a mild frontal deformity (Group 2a: Cobb $< 30^\circ$) and 53/72 subjects had a severe

Table 3 Comparison of radiographic parameters between controls and AIS groups (Group 1: frontally aligned; Group 2: frontally malaligned)

Plane	Parameters	Controls (n=64)		Subjects with AIS (n=254)		p-value	Control vs. Group1	Control vs. Group2	Group1 vs. Group2		
		Mean	SD	Group1 (n=182)						Group2 (n=72)	
				Mean	SD					Mean	SD
<i>Global alignment</i>											
Frontal	Frontal OD-HA angle (°)	0.8	0.6	0.9	0.6	2.9	0.8	<0.001	*		
	Sagittal OD-HA angle (°)	-2.2	2.2	-2.7	1.8	-2.4	2.4	0.24			
<i>Postural assessment</i>											
Frontal	C7-CSL (mm)	7.8	6.2	8.0	5.6	20.2	8.5	<0.001	*		
	Sagittal axis (mm)	-18.5	20.3	-20.1	19.5	-16.4	22.3	0.45			
Sagittal	T9 tilt (°)	10.3	2.7	9.6	3.6	9.9	3.8	0.32			
	Pelvic Shift (cm)	-0.2	2.0	0.4	2.0	0.6	2.2	0.07			
	Knee flexion (+) / extension (-) (°)	-3.0	5.2	-2.6	5.2	-3.0	5.4	0.82			
<i>Spino-pelvic</i>											
Frontal	Pelvic obliquity (mm)	4.1	3.4	4.8	3.3	5.6	3.1	0.005	*		
	COC2 angle (°)	23.7	11.9	25.0	11.6	24.4	12.9	0.64			
Sagittal	Chin brow vertical angle (°)	7.6	6.5	8.0	6.0	7.5	5.8	0.72			
	C3C7 Kyphosis-3D (°)	14.9	11.9	17.2	13.3	17.7	12.1	0.33			
	Cervical sagittal axis (mm)	21.5	8.0	21.5	8.4	21.6	8.8	0.85			
	T1 slope (°)	22.2	6.9	19.6	8.9	18.4	7.7	0.02	*		
	T1T12 Kyphosis (°)	41.6	7.4	34.7	12.7	32.4	11.9	<0.001	*		
	T4T12 Kyphosis (°)	35.5	7.9	28.9	12.0	26.6	12.0	<0.001	*		
	T10L2 (°)	-2.3	9.8	-1.5	9.8	-4.8	11.7	0.14			
	L1L5 Lordosis (°)	46.8	10.1	47.1	12.5	48.0	11.8	0.88			

Table 3 (continued)

Plane	Parameters	Controls (n=64)		Subjects with AIS (n=254)				p-value	Control vs. Group1	Control vs. Group2	Group1 vs. Group2
		Mean	SD	Group1 (n=182)		Group2 (n=72)					
				Mean	SD	Mean	SD				
Horizontal	L1S1 Lordosis (°)	59.6	10.2	58.2	12.0	58.4	10.7	0.63			
	Pelvic Incidence (°)	44.3	9.6	48.1	12.0	49.4	11.5	0.03	*		*
	Sacral Slope (°)	38.7	8.2	39.9	9.3	40.3	8.0	0.67			
	Pelvic Tilt (°)	5.5	6.7	8.2	7.5	9.2	8.9	0.03	*		*
	Pelvic axial rotation (°)	3.3	2.7	3.1	2.5	3.5	3.1	0.77			
Scoliosis Frontal	Major frontal Cobb angle (°)	3.2	2.9	29.7	17.6	41.5	16.1	< 0.001	*	*	*
	Secondary curve- frontal Cobb angle (°)	0.0	0.0	17.6	16.8	26.1	14.5	< 0.001	*	*	*
Sagittal	Major hypokyphosis index (°)	0.1	2.3	-1.6	3.4	-2.6	3.6	< 0.001	*	*	*
	Secondary curve- hypokyphosis index (°)	0.0	0.0	-0.7	2.5	-1.1	2.7	0.005	*	*	*
Horizontal	Major torsion Index (°)	2.3	1.5	9.0	7.1	12.1	7.0	< 0.001	*	*	*
	Secondary curve- torsion Index (°)	0.0	0.0	4.7	5.5	9.9	6.2	< 0.001	*	*	*
	Major apical vertebral rotation (°)	1.6	2.1	11.8	7.4	19.2	9.8	< 0.001	*	*	*
Horizontal	Secondary curve- apical vertebral rotation (°)	0.0	0.0	4.8	6.2	5.8	6.4	< 0.001	*	*	*
	Major Upper IAR (°)	1.4	1.5	5.1	3.4	6.3	3.5	< 0.001	*	*	*

Table 3 (continued)

Plane	Parameters	Controls (n = 64)		Subjects with AIS (n = 254)				p-value	Control vs. Group1	Control vs. Group2	Group1 vs. Group2
				Group1 (n = 182)		Group2 (n = 72)					
		Mean	SD	Mean	SD	Mean	SD				
	Major Lower IAR (°)	1.5	1.5	5.8	4.3	8.1	4.9	<0.001	*	*	*
	Secondary curve- Upper IAR (°)	0.0	0.0	3.5	3.8	5.4	3.8	<0.001	*	*	*
	Secondary curve- Lower IAR (°)	0.0	0.0	2.8	3.4	6.0	4.3	<0.001	*	*	*
<i>Rib cage</i>											
Frontal	Width (mm)	224.7	21.0	225.6	16.0	233.3	17.2	<0.001		*	*
Sagittal	Thickness (mm)	196.9	143.8	172.8	138.8	198.8	143.7	0.10			
	Volumetric SPI (%)	4.1	1.4	5.2	1.6	5.0	1.6	<0.001	*	*	*
Horizontal	Gibbosity (°)	3.5	2.4	5.7	3.4	6.5	4.2	<0.001	*	*	*
	Volume (cm3)	5192.8	1413.3	4928.8	965.7	5213.8	937.1	0.08			

* Bold: significant p values

Frontally malaligned AIS (Group 2)

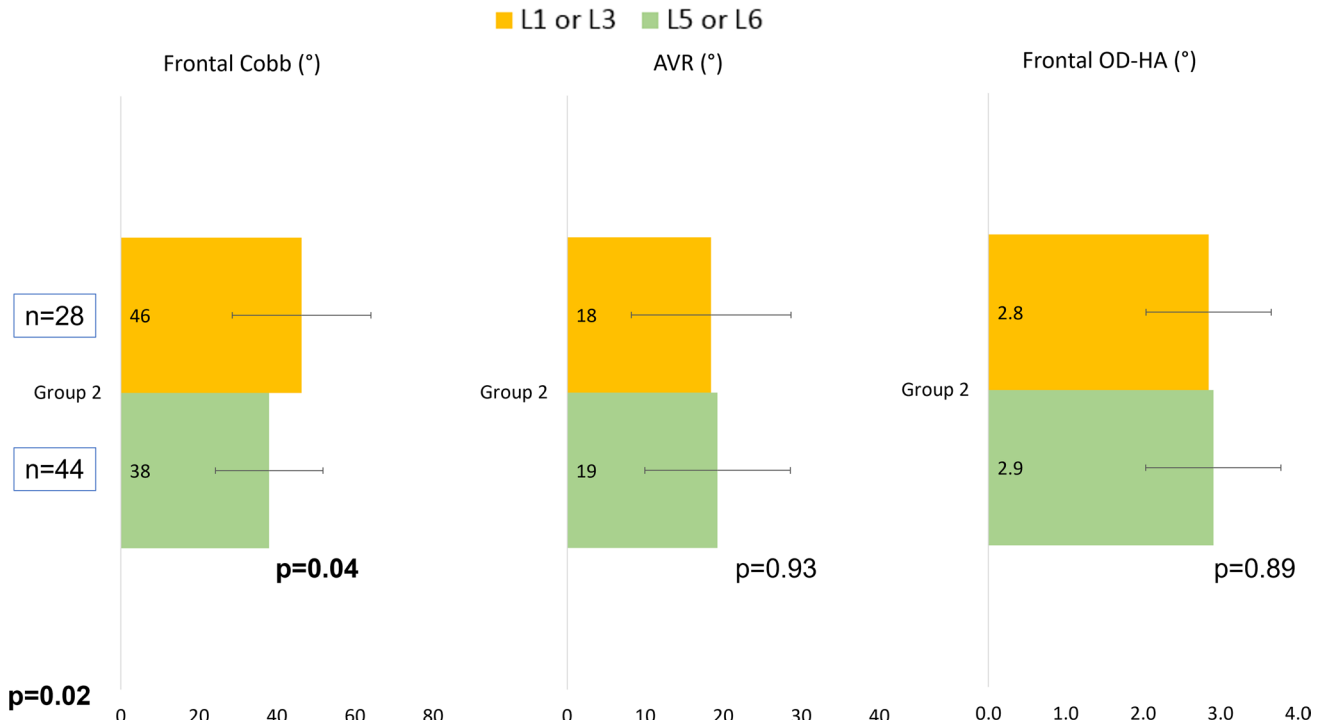


Fig. 4 Subject's distribution and mean comparison of frontal Cobb (°), apical vertebral rotation (°) and frontal OD-HA (°) in Group 2, presented according to Lenke curve type: L1 or L3 and L5 or L6

deformity (Group 2b: Cobb > 30°). In Group 2a, 14 subjects were classified as Lenke 5 or 6, while only five were classified as Lenke 1 or 3; subjects with Lenke 5 or 6 had a higher AVR compared to those with Lenke 1 or 3 ($11 \pm 4^\circ$ vs. $6 \pm 4^\circ$, $p=0.04$) (Fig. 5). Subjects in Group 2a had a positive severity index (≥ 0.6), indicating a risk of progression of the scoliotic deformity.

Relationship between OD-HA angle and spino-pelvic parameters

The frontal OD-HA angle was found to be positively correlated to the Cobb angles of the major ($r=0.31$, $p<0.001$) and secondary curves ($r=0.21$, $p<0.001$), torsion index of the major ($r=0.17$, $p=0.008$) and secondary curves ($r=0.38$, $p<0.001$), AVR ($r=0.44$, $p<0.001$), pelvic obliquity ($r=0.19$, $p=0.003$), pelvic axial rotation ($r=0.14$, $p=0.03$) and was negatively correlated to T10L2 ($r=-0.17$, $p=0.007$; Fig. 6).

The multivariate analysis showed that the frontal OD-HA angle was determined (adjusted $R^2=0.22$) mainly by the AVR ($\beta=0.44$, $p<0.001$) and secondarily by the Lenke type ($\beta=0.20$ L5 as the reference, $p=0.002$).

Discussion

The scoliotic deformity of the spine is known to be related to deformities of the trunk, as well as alterations of the pelvic orientation. This study aimed to evaluate global postural alignment in AIS, while taking into consideration the position of the head. Sagittal alignment remained within normal range, as shown in previous studies [38, 39], suggesting that these young patients can deploy compensatory mechanisms to maintain good sagittal balance, even in case of severe deformity.

However, frontal alignment was shown to be altered in 28% of subjects. Subjects with frontal malalignment were mainly Lenke types 5 or 6. The apical vertebral rotation was found to be the main determinant of frontal malalignment.

Subjects in Group 1 presented a moderate spinal deformity in all three planes compared to controls. Therefore, these subjects presented the classic pattern of spinal deformity of subjects having major thoracic curves [40–45] with a frontally aligned global posture.

Subjects in Group 2 presented severe frontal and axial spinal deformities compared to both Group 1 and controls, although this group was formed according to the frontal OD-HA angle and not curve severity. They also presented

Subgroups in frontally malaligned AIS (Groups 2a & 2b)

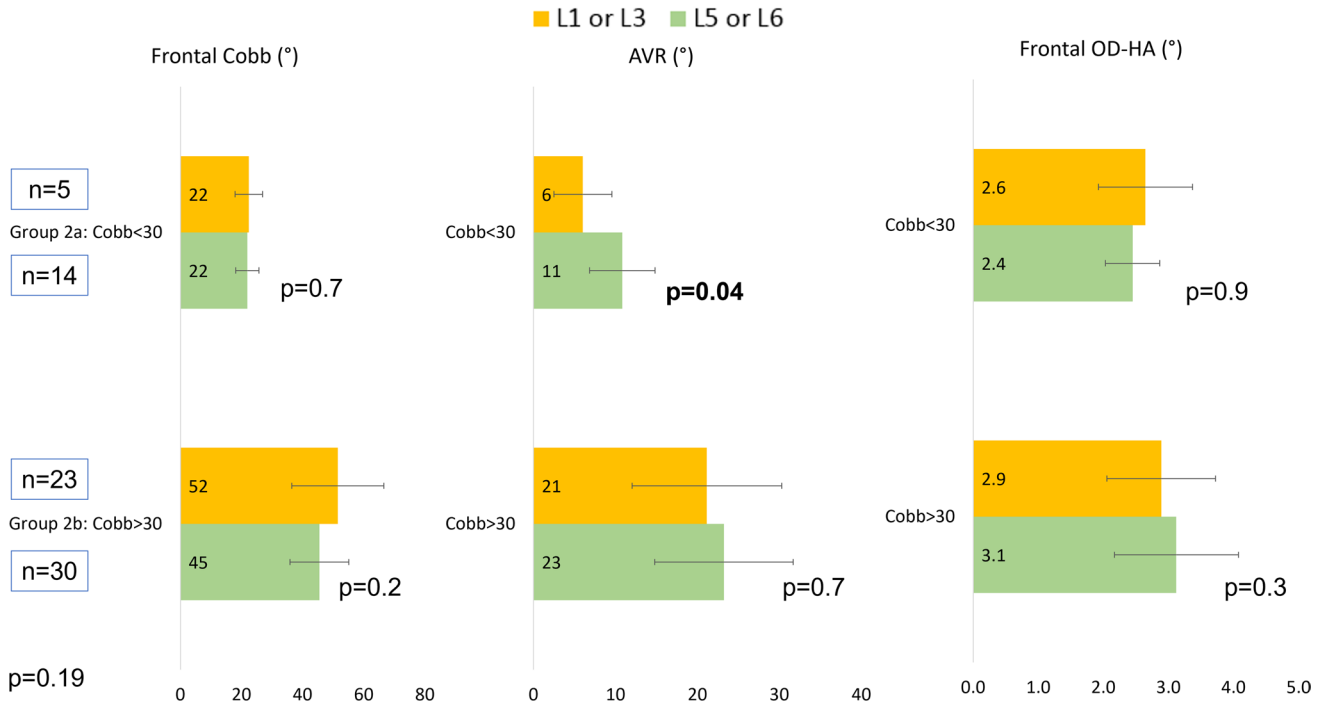


Fig. 5 Subject's distribution and mean comparison of frontal Cobb (°), apical vertebral rotation (°) and frontal OD-HA (°) in Group 2a and 2b, presented according to Lenke curve type: L1 or L3 and L5 or L6

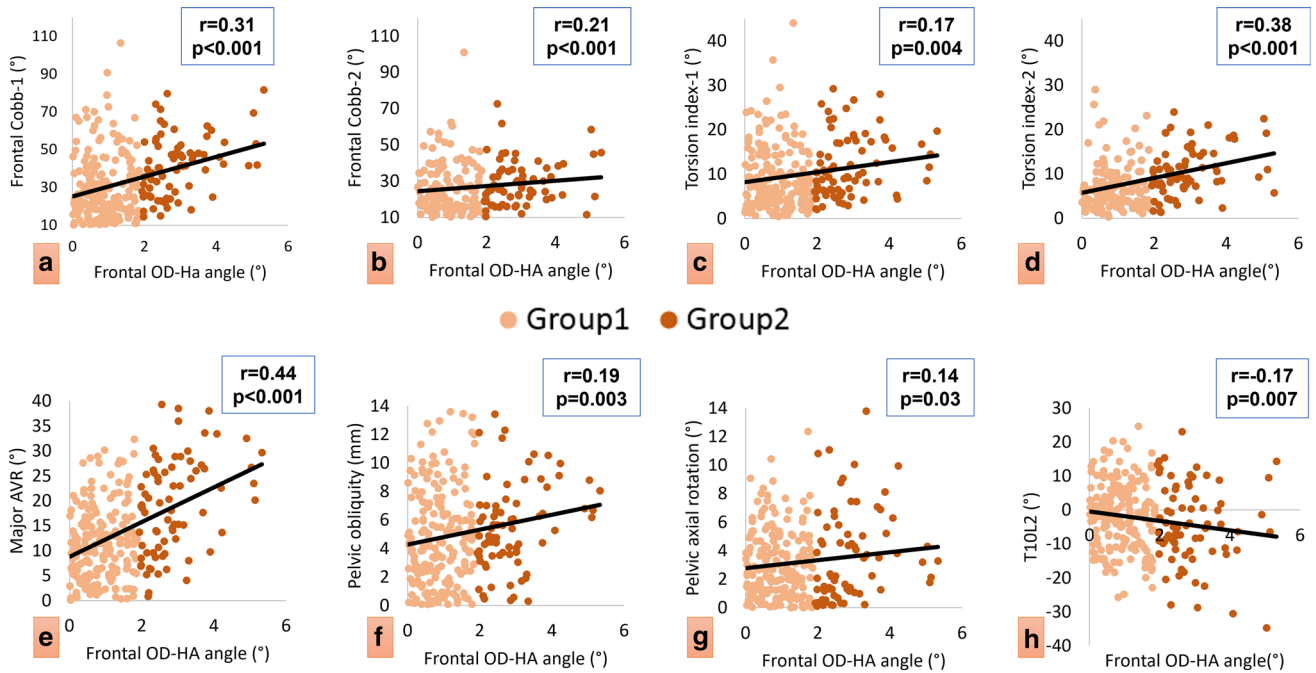


Fig. 6 Correlations between frontal OD-HA angle and the spinopelvic or scoliosis parameters in subjects with AIS. **a** frontal OD-HA versus frontal major Cobb, **b** frontal OD-HA versus secondary frontal Cobb, **c** frontal OD-HA versus major torsion index, **d** frontal OD-HA

versus secondary torsion index, **e** frontal OD-HA versus major apical vertebral rotation, **f** frontal OD-HA versus pelvic obliquity, **g** frontal OD-HA versus pelvic axial rotation, **h** frontal OD-HA versus T10L2 thoracolumbar junction

Parameters	Example 1 (Group 1)	Example 2 (Group 2a)	Example 3 (Group 2b)
Frontal OD-HA (°)	0.3	2.2	4.2
Cobb (°)	30	25	42
AVR (°)	7	21	23
PI (°)	70	36	37
T1T12 (°)	44	38	28

Fig. 7 Three examples of subjects with AIS. Example 1 (Group 1) and examples 2 & 3 (Group 2a & 2b). Example 1 (Group 1) showed a moderate Cobb (30°) and a low AVR (7°). Examples 2 and 3 (Group

2a & 2b) they both presented a high AVR (23° and 21° respectively), while subject in Group 2a had a mild frontal deformity (Cobb=25°), subject in Group 2b presented a severe frontal deformity (Cobb=42°)

a similar loss of thoracic kyphosis and T1 slope to Group 1. Furthermore, their pelvis presented an altered orientation in both frontal (pelvic obliquity) and sagittal planes (pelvic tilt) compared to controls.

It is important to note that both groups did not show alterations in the horizontal gaze, nor alterations of lower limb alignment, showing that subjects in Group 2 do not compensate by changing their horizontal gaze or recruiting compensatory mechanisms at their lower limbs.

Further analysis in Group 2 showed that most of the subjects were classified as Lenke 5 or 6. They presented a lower Cobb compared to subjects with Lenke 1 or 3 from the same group (Lenke 5 or 6: $n=44$, $\text{Cobb}=38 \pm 14^\circ$; Lenke 1 or 3: $n=28$, $\text{Cobb}=46 \pm 18^\circ$, all $p < 0.05$). These findings might suggest that a less severe frontal deformity in thoracolumbar and lumbar scoliosis can induce a frontal global malalignment.

In addition, frontally malaligned subjects with a less severe frontal deformity (Group 2a) were mainly classified as Lenke 5 or 6 ($n=14/19$). These subjects presented a higher AVR compared to subjects with Lenke 1 or 3 ($n=5/19$) with the same curve severity ($11 \pm 4^\circ$ vs. $6 \pm 4^\circ$, $p=0.04$), indicating a higher prevalence of distal

structural scoliosis and a high axial deformity in frontally malaligned AIS, even in those with low Cobb angle. Those with Lenke types 1 or 3 presented either a more distal apical vertebral location (T10) or a high frontal pelvic obliquity; both parameters are known to be correlated to frontal malalignment [46].

Furthermore, subjects in Group 2a had a progressive scoliotic deformity (severity index ≥ 0.6). Examples of subjects from Group 1, 2a and 2b are presented in Fig. 7.

When the determinants of frontal malalignment were investigated, the univariate analysis showed that the frontal OD-HA angle was mainly correlated to the frontal Cobb and AVR. In the multivariate analysis, the main determinant of the frontal OD-HA angle was found to be the AVR and partially the Lenke type.

While this study highlights the importance to assess the axial plane deformity in AIS, this can be limited by the access to biplanar X-ray techniques. Other qualitative method might be used such as the NASH-MOE technique that observes the pedicle orientation on frontal radiographs [47, 48].

In conclusion, frontal global malalignment was more common (28%) in subjects with AIS, especially in subjects

with distal major structural scoliosis, while sagittal alignment remained within normal limits. In this study, subjects with AIS were classified according to their frontal malalignment (frontal OD-HA). As expected, maligned subjects showed the most severe scoliotic deformities. Furthermore, frontal malalignment was found to be mainly determined by the axial rather than the frontal deformity. Therefore, this finding is of utmost importance since it highlights the necessity to monitor the progression in the axial plane, and to intervene at the level of the apical vertebra, in order to avoid the aggravation of the frontal malalignment.

Acknowledgements This research was funded by the University of Saint-Joseph (grant FM300). The funding sources did not intervene in study design; in the collection, analysis and interpretation of data; in the writing of the report; and in the decision to submit the article for publication.

Declarations

Conflict of interest MK, IG, CV, NK, MS, CC, AR, EA, MF, EJ, ES, KK, WS and AA declare that they have no conflict of interest related to this study.

References

- Duval-Beaupere G (1970) Maturation indices in the surveillance of scoliosis. *Rev Chir Orthop Reparatrice Appar Mot* 56:59–76
- Gauchard GC, Lascombes P, Kuhnst M, Perrin PP (2001) Influence of different types of progressive idiopathic scoliosis on static and dynamic postural control. *Spine (Phila Pa 1976)* 26 1052–1058. doi: <https://doi.org/10.1097/00007632-200105010-00014>
- Haumont T, Gauchard GC, Lascombes P, Perrin PP (2011) Postural instability in early-stage idiopathic scoliosis in adolescent girls. *Spine (Phila Pa 1976)*. doi: <https://doi.org/10.1097/BRS.0b013e3181ff5837>
- Stylianides GA, Dalleau G, Begon M et al (2013) Pelvic morphology, body posture and standing balance characteristics of adolescent able-bodied and idiopathic scoliosis girls. *PLoS ONE* 8:1–6. <https://doi.org/10.1371/journal.pone.0070205>
- Dubousset J (2011) Reflections of an orthopaedic surgeon on patient care and research into the condition of scoliosis. *J Pediatr Orthop* 31:1–8. <https://doi.org/10.1097/BPO.0b013e3181f73beb>
- Le Huec JC, Gille O, Fabre T (2018) Sagittal balance and spine-pelvis relation: a French speciality? *Orthop Traumatol Surg Res* 104:551–554. <https://doi.org/10.1016/j.otsr.2018.06.001>
- Barrey C, Roussouly P, Le Huec J-C et al (2013) Compensatory mechanisms contributing to keep the sagittal balance of the spine. *Eur Spine J* 22:834–841. <https://doi.org/10.1007/s00586-013-3030-z>
- Kubat O, Ovadia D (2020) Frontal and sagittal imbalance in patients with adolescent idiopathic deformity. *Ann Transl Med* 8:29–29. <https://doi.org/10.21037/atm.2019.10.49>
- Souder C, Newton PO, Shah SA et al (2017) Factors in surgical decision making for thoracolumbar/lumbar AIS: it's about more than just the curve magnitude. *J Pediatr Orthop* 37:e530–e535. <https://doi.org/10.1097/BPO.0000000000000746>
- Fortin C, Grunstein E, Labelle H et al (2016) Trunk imbalance in adolescent idiopathic scoliosis. *Spine J* 16:687–693. <https://doi.org/10.1016/j.spinee.2016.02.033>
- Pan-pan H, Miao Y, Xiao-guang L et al (2018) How does the sagittal spinal balance of the scoliotic population deviate from the asymptomatic population? *BMC Musculoskelet Disord* 19:36. <https://doi.org/10.1186/s12891-018-1954-5>
- Roussouly P, Labelle H (2013) Pre- and post-operative sagittal balance in idiopathic scoliosis : a comparison over the ages of two cohorts of 132 adolescents and 52 adults. *European Spine J*. <https://doi.org/10.1007/s00586-012-2571-x>
- Vital JM, Senegas J (1986) Anatomical bases of the study of the constraints to which the cervical spine is subject in the sagittal plane A study of the center of gravity of the head. *Surg Radiol Anat* 8:169–173. <https://doi.org/10.1007/BF02427845>
- Illés TS, Burkus M, Somoskeőy S et al (2017) The horizontal plane appearances of scoliosis: what information can be obtained from top-view images? *Int Orthop* 41:2303–2311. <https://doi.org/10.1007/s00264-017-3548-5>
- Steffen JS, Obeid I, Aurouer N et al (2010) 3D postural balance with regard to gravity line: an evaluation in the transversal plane on 93 patients and 23 asymptomatic volunteers. *Eur Spine J* 19:760–767. <https://doi.org/10.1007/s00586-009-1249-5>
- Sugrue PA, Mcclendon J, Smith TR et al (2013) Redefining global spinal balance normative values of cranial center of mass from a prospective cohort of asymptomatic individuals. *Spine* 38:484–489. <https://doi.org/10.1097/BRS.0b013e318273a1c0>
- Amabile C, Pillet H, Lafage V et al (2016) A new quasi-invariant parameter characterizing the postural alignment of young asymptomatic adults. *Eur Spine J*. <https://doi.org/10.1007/s00586-016-4552-y>
- Amabile C, Le Huec J-C, Skalli W (2016) Invariance of head-pelvis alignment and compensatory mechanisms for asymptomatic adults older than 49 years. *Eur Spine J*. <https://doi.org/10.1007/s00586-016-4830-8>
- Faro FD, Marks MC, Pawelek J, Newton PO (2004) Evaluation of a functional position for lateral radiograph acquisition in adolescent idiopathic scoliosis. *Spine (Phila Pa 1976)* 29:2284–2289. doi: 00007632–200410150–00017
- Chaibi Y, Cresson T, Aubert B et al (2012) Fast 3D reconstruction of the lower limb using a parametric model and statistical inferences and clinical measurements calculation from biplanar X-rays. *Comput Methods Biomech Biomed Engin* 15:457–466. <https://doi.org/10.1080/10255842.2010.540758>
- Humbert L, De Guise JA, Godbout B et al (2009) Fast 3D reconstruction of the spine from biplanar radiography: a diagnosis tool for routine scoliosis diagnosis and research in biomechanics. *Comput Methods Biomech Biomed Engin* 12:151–163. <https://doi.org/10.1080/10255840903081222>
- Lenke LG, Betz RR, Harms J et al (2001) Adolescent idiopathic scoliosis: a new classification to determine extent of spinal arthrodesis. *J Bone Joint Surg Am* 83:1169–81. <https://doi.org/10.1097/00007632-200101010-00009>
- Abelin-Genevois K, Sassi D, Verdun S, Roussouly P (2018) Sagittal classification in adolescent idiopathic scoliosis: original description and therapeutic implications. *Eur Spine J* 27:2192–2202. <https://doi.org/10.1007/s00586-018-5613-1>
- Jackson RP, McManus AC (1994) Radiographic analysis of sagittal plane alignment and balance in standing volunteers and patients with low back pain matched for age, sex, and size: a prospective controlled clinical study. *Spine (Phila Pa 1976)* 19 1611–1618
- Vialle R, Levassor N, Rillardon L et al (2005) Radiographic analysis of the sagittal alignment and balance of the Spine. *Methods*. <https://doi.org/10.2106/JBJS.D.02043>

26. Lafage V, Schwab F, Patel A, et al (2009) Pelvic tilt and trunca l inclination: two key radiographic parameters in the setting of adults with spinal deformity. *Spine (Phila Pa 1976)* 34 E599–E606. doi: <https://doi.org/10.1097/BRS.0b013e3181aad219>
27. Le Huec J-C, Aunoble S, Leijssen P, Pellet N (2011) Pelvic parameters: origin and significance. *Eur Spine J* 20:564–571. <https://doi.org/10.1007/s00586-011-1940-1>
28. Salameh M, Bizdikian AJ, Saad E et al (2021) Reliability assessment of cervical spine parameters measured on full-body radiographs in asymptomatic subjects and patients with spinal deformity. *Orthop Traumatol Surg Res.* <https://doi.org/10.1016/J.OTSR.2021.103026>
29. Justin K. scheer, B.s. 1, Jessica a. tang, B.s. 1, Justin s. smith, m.D., Ph.D. 2, et al (2013) Cervical spine alignment, sagittal deformity, and clinical implications : A review. *J Neurosurg Spine* 19:141–159. doi: <https://doi.org/10.3171/2013.4.SPINE12838>
30. Diebo BG, Challier V, Henry JK, et al (2016) Predicting cervical alignment required to maintain horizontal gaze based on global spinal alignment. *Spine (Phila Pa 1976)* 41 1795–1800. doi: <https://doi.org/10.1097/BRS.0000000000001698>
31. Yu M, Zhao WK, Li M et al (2015) Analysis of cervical and global spine alignment under roussouly sagittal classification in Chinese cervical spondylotic patients and asymptomatic subjects. *Eur Spine J* 24:1265–1273. <https://doi.org/10.1007/s00586-015-3832-2>
32. Lee S, Kim K, Seo E et al (2012) The influence of thoracic inlet alignment on the craniocervical sagittal balance in asymptomatic adults. *J spinal Disord Tech* 25:E41–E47. <https://doi.org/10.1097/BSD.0b013e3182396301>
33. Skalli W, Vergari C, Ebermeyer E et al (2017) Early detection of progressive adolescent idiopathic scoliosis: a severity index. *Spine (Phila Pa 1976)* 42 823–830. doi: <https://doi.org/10.1097/BRS.0000000000001961>
34. Pietton R, Bouloussa H, Vergari C et al (2020) Rib cage measurement reproducibility using biplanar stereoradiographic 3D reconstructions in adolescent idiopathic scoliosis. *J Pediatr Orthop* 40:36–41. <https://doi.org/10.1097/BPO.0000000000001095>
35. Assi A, Karam M, Skalli W, Vergari C (2021) P RIMARY R ESEARCH A Novel Classification of 3D Rib Cage Deformity in Subjects With Adolescent Idiopathic Scoliosis. 00:1–11
36. Al-Aubaidi Z, Lebel D, Oudjhane K, Zeller R (2013) Three-dimensional imaging of the spine using the EOS system: is it reliable? A comparative study using computed tomography imaging. *J Pediatr Orthop B* 22:409–412. <https://doi.org/10.1097/BPB.0b013e328361ae5b>
37. Kato S, Debaud C, Zeller RD (2017) Three-dimensional EOS analysis of apical vertebral rotation in adolescent idiopathic scoliosis. *J Pediatr Orthop* 37:e543–e547. <https://doi.org/10.1097/BPO.0000000000000776>
38. Vergari C, Courtois I, Ebermeyer E et al (2019) Head to pelvis alignment of adolescent idiopathic scoliosis patients both in and out of brace. *Eur Spine J* 28:1286–1295. <https://doi.org/10.1007/s00586-019-05981-8>
39. Alzakri A, Vergari C, Van den Abbeele M et al (2019) Global sagittal alignment and proximal junctional kyphosis in adolescent idiopathic scoliosis. *Spine Deform* 7:236–244. <https://doi.org/10.1016/j.jspd.2018.06.014>
40. Mac-Thiong J-M, Labelle H, Charlebois M, et al (2003) Sagittal plane analysis of the spine and pelvis in adolescent idiopathic scoliosis according to the coronal curve type. *Spine (Phila Pa 1976)* 28 1404–9. doi: <https://doi.org/10.1097/01.BRS.0000067118.60199.D1>
41. Akbar M, Almansour H, Lafage R et al (2018) Sagittal alignment of the cervical spine in the setting of adolescent idiopathic scoliosis. *J Neurosurg Spine* 29:506–514. <https://doi.org/10.3171/2018.3.SPINE171263>
42. Hiyama A, Sakai D, Watanabe M et al (2016) Sagittal alignment of the cervical spine in adolescent idiopathic scoliosis: a comparative study of 42 adolescents with idiopathic scoliosis and 24 normal adolescents. *Eur Spine J* 25:3226–3233. <https://doi.org/10.1007/s00586-016-4701-3>
43. Hu J, Qian B, ping, Qiu Y, et al (2017) Can acetabular orientation be restored by lumbar pedicle subtraction osteotomy in ankylosing spondylitis patients with thoracolumbar kyphosis? *Eur Spine J* 26:1826–1832. <https://doi.org/10.1007/s00586-016-4709-8>
44. Wang L, Liu X (2017) Cervical sagittal alignment in adolescent idiopathic scoliosis patients (Lenke type 1–6). *J Orthop Sci* 22:254–259. <https://doi.org/10.1016/j.jos.2016.12.006>
45. Pesenti S, Blondel B, Peltier E et al (2016) Interest of T1 parameters for sagittal alignment evaluation of adolescent idiopathic scoliosis patients. *Eur Spine J* 25:424–429. <https://doi.org/10.1007/s00586-015-4244-z>
46. Chen RQ, Watanabe K, Hosogane N et al (2013) Spinal coronal profiles and proximal femur bone mineral density in adolescent idiopathic scoliosis. *Eur Spine J* 22:2433–2437. <https://doi.org/10.1007/s00586-013-2872-8>
47. Labaki C, Otayek J, Massaad A et al (2019) Is the apical vertebra the most rotated vertebra in the scoliotic curve? *J Neurosurg Spine.* <https://doi.org/10.3171/2019.6.SPINE19203>
48. STOKES IAF, BIGALOW LC, MORELAND MS (1986) Measurement of Axial Rotation of Vertebrae in Scoliosis. *Spine (Phila Pa 1976)* 11 213–218. doi: <https://doi.org/10.1097/00007632-198604000-00006>

Publisher's Note Springer Nature remains neutral with regard to jurisdictional claims in published maps and institutional affiliations.