



Science Arts & Métiers (SAM)

is an open access repository that collects the work of Arts et Métiers Institute of Technology researchers and makes it freely available over the web where possible.

This is an author-deposited version published in: <https://sam.ensam.eu>
Handle ID: <http://hdl.handle.net/10985/10814>

To cite this version :

Aliasghar BEHNAMGHADER, Davood SHARIFI, Sarang SOROORI, Narjes BAGHERI, Ranna TOULOUEI, Roghieh NEMATI, Denis NAJJAR, Alain IOST - Bone Tissue Response to Plasma Sprayed Hydroxyapatite Coatings: An In Vivo Study on Rabbit Femoral Condyles - IRANIAN JOURNAL OF PHARMACEUTICAL SCIENCES - Vol. 4, n°1, p.57-62 - 2008

Any correspondence concerning this service should be sent to the repository

Administrator : scienceouverte@ensam.eu





Bone Tissue Response to Plasma Sprayed Hydroxyapatite Coatings: An *In Vivo* Study on Rabbit Femoral Condyles

Aliasghar Behnamghader^{a,*}, Davood Sharifi^b, Sarang Soroori^b, Narjes Bagheri^a, Ranna Tolouei^c,
Roghieh Nemat^a, Denis Najjar^d, Alain Iost^d

^aMaterials and Energy Research Center, Tehran, Iran,

^bDepartment of Clinical Sciences, Surgery and Radiology Section, Faculty of Veterinary Medicine, University of Tehran, Tehran-Iran,

^cDepartment of Biomedical Engineering, Science and Research Campus, Islamic Azad University, Tehran, Iran,

^dLaboratoire de Métallurgie Physique et Génie des Matériaux, Université des Sciences et Technologies de Lille, UMR CNRS 8517, Lille, France

Abstract

In this study, hydroxyapatite was coated on titanium substrates by plasma spraying process. A well-known porous and lamellar microstructure was found in the lateral and outer surface of coating. The phase composition was studied by XRD and the morphological and the microstructural aspects were investigated by scanning electron and optical microscopy. The hardness of coatings and substrates was measured by Vickers indentation method. For *in vivo* study, rabbit condyles were exposed to two groups of coated and uncoated samples. Radiographically, different parameters such as bone lysis, sclerosis, displacement of samples and bone resorption were taken into consideration and no statistically differences between the two groups, with no sign of infection on the edges of each hole were found. Histopathological interpretation of all coated samples indicated that the extent of callus and thickness of speculae were quite distinct from that of uncoated group. In this group, the space between implant and canal was filled up with matured connective tissues and plenty of bone speculae of woven bone in nature. However, these speculae were thinner and immature as compared to coated samples.

Keywords: Hydroxyapatite coating, Implants; Plasma spraying.

Received: December 4, 2007 **Accepted:** June 10, 2008

1. Introduction

Titanium has been widely used in orthopedic and dental materials applications because of their superior mechanical properties

and high corrosion resistance. However, the results in term of osseointegration has not always been satisfactory under altered metabolic bone conditions [1, 2]. The bone formation around an implant is a complex process and it is not fully understood. The surface morphology, roughness, chemical composition and coating of implant with

*Corresponding author: Aliasghar Behnamghader, Materials and Energy Research Center, Tehran, Iran.
Tel (+98)261-6204131-3
E-mail: a-behnamghader@merc.ac.ir

selected materials, have been commonly investigated to increase the likelihood of osseointegration [3-8]. Among the methods used for the coating of biomaterials, the hydroxyapatite-coated prostheses have been generally fabricated by plasma spraying process [9].

In vivo evaluation constitutes a crucially important phase in the development of new implant materials. A wide variety of animal models have been used to evaluate the HA-coated samples, such as rats, rabbits and etc. For samples with potential load-bearing applications, a common practice is to place a number of small devices into animal at the intramedullary canals, or through cortical bone (transcortical) or subcutaneous site, and to evaluate the tissue adaptation to the material by both mechanical and histological techniques. Although it has been generally accepted that plasma-sprayed HA and CaP coatings improve bone strength and initial osseointegration rate, optimal coating properties, required to achieve maximal bone response are yet to be investigated [10, 11]. The aim of the present study was to investigate the materials characteristics and *in vivo* behavior of HA coatings prepared via plasma spraying process in our laboratories.

2. Materials and methods

2.1. Implant preparation and characterization

HA coatings with thickness varying from 25 to 75 μm were deposited by air plasma spraying on the Ti6Al4V bars with a diameter of 25 mm. Before thermal spraying, the Ti6Al4V samples were sand blasted in order to obtain a favorable surface for mechanical bonding in the coating/substrate interface. The roughness of substrate has an important role in the coating/substrate attachment [12]. The arithmetic average roughness parameter (R_a) of substrate surface used in this study was 2.3 μm . The phase characterization was performed by the X-ray diffraction method (Siemens D-500). After the surface preparation of the samples with 3 μm grade polishing, microstructural studies were conducted by scanning electron microscopy (Cambridge Stereoscan 360).

2.2. Experimental design for *in vivo* experiments

This study was performed in accordance with the University of Tehran Law on animal experiments. Fifteen adult male New Zealand rabbits 3.2 ± 0.15 Kg body weight were submitted to dental bit drilling for unilateral implantation after exposure of the right medial femoral condyle. Acepromazine maleate (2% Karon Co. Iran) used 1 mg/kg.bw intramuscularly as premedication and anesthesia was

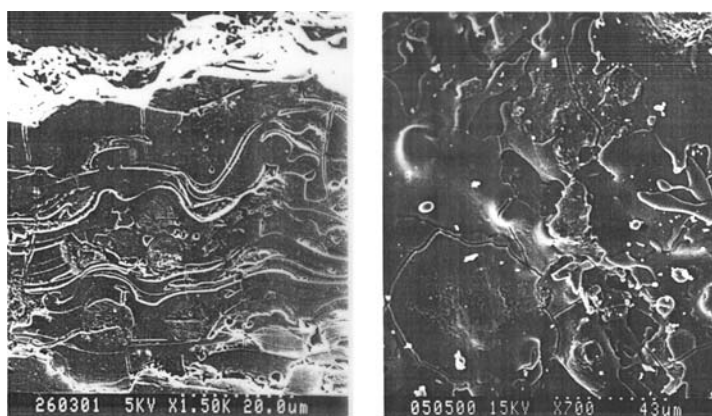
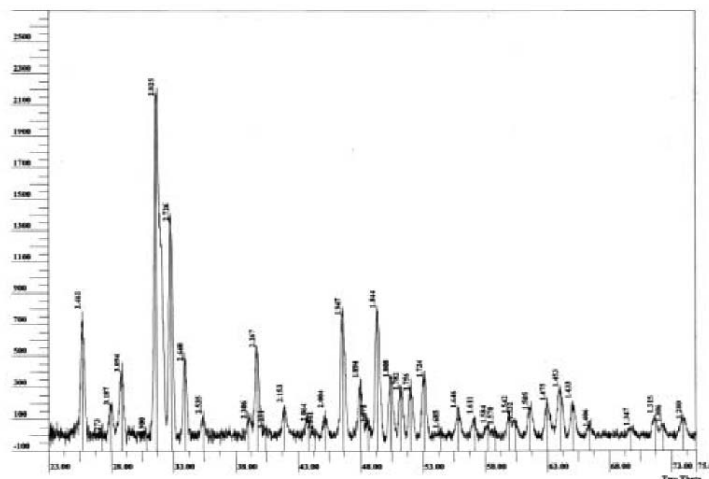


Figure 1. Cross sectional (left) and outer surface images (right) of plasma-sprayed HA coating taken by SEM.

The rabbits were subsequently divided into 3 groups of 5 animals per group. One piece of coated samples was inserted into each hole in group I. Group II contained the uncoated samples and no samples were used in the group III. Antibiotics (penicillin G procaine 40000 IU/kg IM every 12 h) dexamethasone 0.6 mg/Kg.b.w vitamin B₁₂ complex 0.2 mg/Kg.b.w and analgesic such as Tramadol hydrochloride (5 mg/Kg.b.w IM every 12 h) were administered for 3 post-operative days. The lateral and cranio-caudal radiographs were taken before and after implantation and on 15, 30, 45 and 60 days.

The bone segments, previously fixed in 10% neutral buffered formaldehyde solution were decalcified, embedded in paraffin and sectioned at 6 microns. The sections were obtained parallel (serial sections) and transverse to the long axis of the bar samples. These sections were stained with hematoxylin and Eosin (H and E) and Masson's trichrome methods for histopathology [13].

The SEM images of lateral and outer surface of coating are shown in Figure 1. A double-featured, well-known porous and lamellar microstructure due to the plasma spraying parameters [14-16] was found in



59

this work. However, the traces of discontinuity, microcracking and intact particles can be identified. The XRD analysis revealed that the principal crystalline phase of coating is hydroxypapatite (Figure 2). The presence of HA as the principal phase of plasma-sprayed HA coatings is reported elsewhere [14, 17]. The hardness of coatings and substrates was measured by Vickers indentation method. Absolute hardness values were 233 VHN for the substrate and 209 VHN for a 120 μm -thick coating. The difference between coating and substrate hardness values can be due to the material characteristics and the presence of porosity in the coating [18].

The initial attachment and subsequent proliferation of osteogenic cells, as well as their ability to form bone are the most important factors affecting the success of a bone implant [19]. Coating the implant with selected materials has been widely studied to improve tissue interaction [14, 15]. Concerning the *in vivo* behavior of our samples, no operative or postoperative complications were encountered. There were no visible signs of infection or other complications in these animals; all animals recovered from surgery and walked normally.

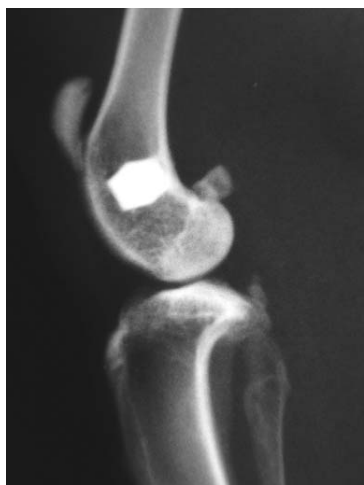

Figure 3. A HA-coated sample, indicating no local reaction and dislocation.

After sacrifice, the macroscopic evaluation revealed all coated (groups II) and uncoated (groups III) samples were well incorporated into the bone. The radiographic interpretation did not indicate any specific changes in the groups II and III (Figure 3). The histological examination of sections of all three groups revealed no evidence of infection, inflammation, foreign body reaction or necrosis of the tissue surrounding the samples. In control group, the holes were completely filled with dense connective tissue containing relatively parallel collagen bundles and immature bone trabecular fragments and unmineralized osteoid tissue. The bone trabecular structure was immature with many remodeling marks.

In uncoated group, around the samples there was not any macrophage or giant cell

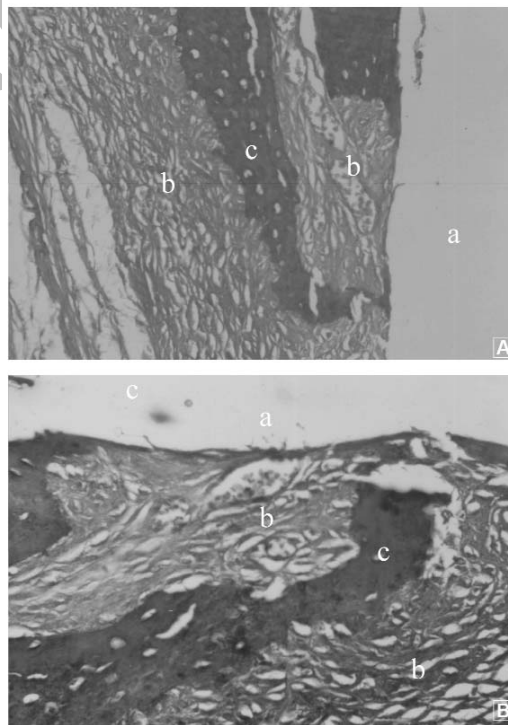


Figure 4. Light micrographs of tissue responses around sample at 60 days after implantation of uncoated titanium in femur of rabbit. Grafted material (a), dense connective tissue with irregular collagen fibers (b), immature woven bone trabeculae (c) were seen. The material was removed from the section. A: H&E \times 247; B: H&E \times 395.

(Figure 4). The gap between bone and implant was filled with connective tissue containing immature bone trabeculae. Only at some places, a direct contact between bone and implant were occurred. In this group, the samples were covered by dense collagen fibers (Figure 4). Thin newly formed immature woven bone trabeculae were present parallelly to the implant surface. These trabeculae were lined with active osteoblasts. The new bone trabeculae were thinner and immature as compared to the group of coated samples. In coated group, the gap between the implant surface and drill wall was filled with mature connective tissue that extensively replaced with bone trabeculae and bridged the gap completely (Figures 5 and 6). However, a thin layer of HA remnants was present between the implant and connective tissue in some sites (Figures 5 and 6). The bone trabeculae structure was relatively mature with high density (mature lamellar bone). Bone formation was more significant where a well direct contact between coated implant and drill wall existed.

The bone-like apatite can be formed on the surface of titanium substrates in SBF environment [5-8] but for the *in vivo* conditions, the findings are controversial. It

seems the uncoated titanium does not show any considerable bone-bonding properties for almost the same time after explantation used in this study [20, 21].

4. Conclusion

In this work, HA coatings were prepared by plasma spraying process and microstructural properties of coatings and bone tissue response were investigated. The microstructure of coatings was porous and lamellar. Radiographic interpretation did not show osteolysis and inflammation or infection around samples in any groups. Histologic results revealed a higher level of osseointegration for the HA-coated samples compared to the uncoated ones. Bone maturation was more significant at the bone-implant interface. Coating of titanium with hydroxyapatite led also to improve the maturation of new formed bone tissue. These results can be attributed to the presence of porous hydroxyapatite in the coated samples. Due to the high biocompatibility and osteoconduction of calcium phosphate materials, they have been widely used for different hard tissue applications such as HA-coated metallic implants and bone substitute materials [10, 11].

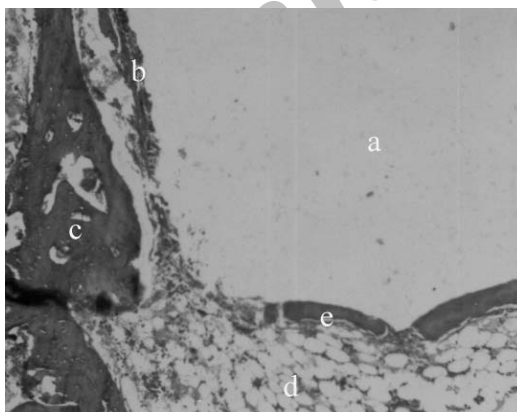


Figure 5. Light micrographs of tissue responses around material at 60 days after implantation of HA coated titanium in femur of rabbit. Grafted material (a), thin collagen fibers and HA remnant (b), trabeculae of lamellar bone (c), immature woven bone trabeculae (e). Bone marrow cavity (d) under the trabeculae was seen (H&E×110).

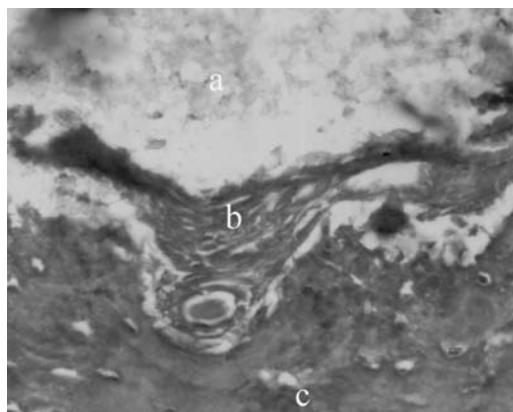


Figure 6. Light micrographs of tissue responses around material at 60 days after implantation of HA coated titanium in femur of rabbit. HA coated surface of implant (a), dense connective tissue with irregular collagen fibers (b), immature woven bone trabeculae (c) (H&E×282).

Acknowledgements

The authors wish to acknowledge the ENSAM (France), Materials and Energy Research Center (Iran) and Faculty of Veterinary Medicine and University of Tehran Research Council (Iran) for approval, financial and technical support of this research work.

References

- [1] Burser D, Schenk RK, Steinmann S, Fiorelini JP, Fox C, Stich H. Influence of surface characteristics on bone integration of Titanium implants: A histomorphometric study in miniature pigs. *J Biomed Mater Res* 1991; 25: 889-90.
- [2] Rimondini L, Rondelli G, Quirici N. *In vitro* corrosion characterization and cell proliferation on surface modified titanium. *Material Wiss* 2002; 33: 716-9.
- [3] Ducheyne P, Cuckler JM. Bioactive ceramic prosthetic coatings. *Clin Orthop Rel Res* 1992; 276: 102-14.
- [4] Wennerberg A, Albrektsson T, Johansson C, Andersson B. Experimental study of turned and grit-blasted screw-shaped implants with special emphasis on effects of blasting material and surface topography. *Biomaterials* 1996; 17: 15-21.
- [5] Park JH, Lee YK. Bioactive calcium phosphate coating prepared on H_2O_2 -treated titanium substrate by electro deposition. *Surf Coat Tech* 2005; 195: 252-7.
- [6] Wen HB, Liu Q. Preparation of bioactive microporous titanium surface by a new two-step chemical treatment. *J Mater Sci* 1998; 9: 121-8.
- [7] Liang F. Apatite formation on titanium by alkali and heat treatment. *Surf Technol* 2003; 165: 133-9.
- [8] Vanzillotta PS, Sader MS. Improvement of *in vitro* titanium bioactivity by three different surface treatments. *Dent Mater* 2006; 22: 275-82.
- [9] Jaffe WL, Scott DF. Current concepts review: Total hip arthroplasty with hydroxyapatite-coated prostheses. *J Bone Jt Surg* 1996; 78A: 1918-34.
- [10] Yang Y, Kim KH, Ong JL. A review on calcium phosphate coatings produced using a sputtering process-an alternative to plasma spraying. *Biomaterials* 2005; 26: 327-37.
- [11] Sun L. Materials fundamental and clinical performance of plasma-sprayed hydroxyapatite coatings. *J Biomed Mater Res* 2001; 58: 570-92.
- [12] Herman H. Plasma spray deposition processes. *MRS Bull* 1988; 12: 60-7.
- [13] Luna LG. Manual of histologic staining method of the Armed Forces Institute of Pathology. 3rd ed., Mc Graw- Hill Company. 1968; pp. 32-46, pp. 94-5.
- [14] Thomas KA. Hydroxyapatite coatings. *Orthopedics* 1994; 17: 267-78.
- [15] D'Antonio JA, Capello WN, Manley MT, Feinberg J. Hydroxyapatite coated implants. *Clin Orthop Relat Res* 1997; 344:124-38.
- [16] Filiaggi MJ, Coombs NA, Pilliar RM. Characterization of the interface in the plasma-sprayed HA coating/Ti-6Al-4V implant system. *J Biomed Mater Res* 1991; 25: 1211-29.
- [17] Chen J, Wolke JGC, deGroot K. Microstructure and crystallinity in hydroxyapatite coatings. *Biomaterials* 1994; 15: 396-9.
- [18] Bull SJ, Rickerby DS. New development in the modeling of the hardness and scratch adhesion of thin films. *Br Ceram Trans* 1989; 88: 177-83.
- [19] Fawcett DW. *Bloom and Fawcett: A textbook of histology*. 12th ed. New York: Chpman and Hall, 1994.
- [20] Lee JH, Ryu HS, Lee DS, Hong KS, Chang BS, Lee CK. Biomechanical and histomorphometric study on the bone-screw interface of bioactive ceramic-coated titanium screws. *Biomaterials* 2005; 26: 3249-57.
- [21] Moroni A, Toksvig-Larsen S, Maltarello MC. A comparison of hydroxyapatite-coated, titanium-coated, and uncoated tapered external-fixation pins. *J Bone Joint Surg* 1998; 80: 547-54.