



Science Arts & Métiers (SAM)

is an open access repository that collects the work of Arts et Métiers Institute of Technology researchers and makes it freely available over the web where possible.

This is an author-deposited version published in: <https://sam.ensam.eu>
Handle ID: <http://hdl.handle.net/10985/14935>

To cite this version :

Abdulmajeed ALZAKRI, Claudio VERGARI, M. VAN DEN ABEELE, Olivier GILLE, Wafa SKALLI, Ibrahim OBEID - Global Sagittal Alignment and Proximal Junctional Kyphosis in Adolescent Idiopathic Scoliosis - Spine Deformity - Vol. 7, n°2, p.236-244 - 2019

Any correspondence concerning this service should be sent to the repository

Administrator : scienceouverte@ensam.eu



Global Sagittal Alignment and Proximal Junctional Kyphosis in Adolescent Idiopathic Scoliosis

Abdulmajeed Alzakri ^{a,b,c}, Claudio Vergari ^a, Maxim Van den Abbeele ^a,
Olivier Gille ^b, Wafa Skalli ^a, Ibrahim Obeid ^b

Abstract

Study design: Case-Control Study

Objectives: To analyse global sagittal alignment including the cranial center of mass (CCOM) and proximal junctional kyphosis (PJK) in Adolescent Idiopathic Scoliosis (AIS) patients treated with posterior instrumentation.

Summary of background data: PJK plays an important role in the global sagittal alignment in AIS patients. Maintaining the head above the pelvis allows for a minimization of energy expense in ambulation and upright posture. Numerous studies have been performed to understand PJK phenomena in AIS patients. However, to our knowledge, no study performed on AIS patients included the head in the analysis of global sagittal alignment and PJK.

Methods: This study included 85 AIS patients and 51 asymptomatic adolescents. Low-dose bi-planar X-rays were acquired for each subject preoperatively and at two years follow up. Two global sagittal alignment parameters were calculated, i.e. the angle between the vertical and the line joining the center of the bi-coxofemoral axis (HA) and either the most superior point of the dentiform apophysis of C2 (OD) or the cranial center of mass (CCOM).

Results: Among normal adolescents, the average OD-HA and CCOM-HA angles were $-2.3^{\circ} \pm 2^{\circ}$ and $-1.5^{\circ} \pm 1.8^{\circ}$, respectively. Among AIS patients the average OD-HA and CCOM-HA angles were respectively $-2.3^{\circ} \pm 1.9^{\circ}$ and $-1.3^{\circ} \pm 1.8^{\circ}$ preoperatively and $-2.8^{\circ} \pm 1.7^{\circ}$ and $-1.9^{\circ} \pm 1.7^{\circ}$ at the last follow up. 13% of the patients developed PJK postoperatively. Case-by-case analysis showed that adjusting the thoracic kyphosis and the compensations required to maintain this constant could provide explanatory elements.

Conclusions: OD-HA and CCOM-HA angles remain almost constant among normal group and patients, pre- and post-operatively, whether PJK or non-PJK. Five patients without PJK and only one patient with PJK produced abnormal values relative to the asymptomatic subjects. Therefore, PJK could be a compensation mechanism, which allows for CCOM-HA and, to a lesser extent, OD-HA to remain invariant.

Level of Evidence: III

Key words: AIS, 3D reconstruction, PJK, global balance, patient-specific.

^a Arts et Metiers ParisTech, LBM/Institut de Biomecanique Humaine Georges Charpak, 151 bd de l'Hopital, 75013 Paris, France

^b Bordeaux University Hospital, Department of Spinal Surgery, Unit 1, C.H.U Tripode Pellegrin, Place Amélie Raba Léon, 33076 Bordeaux, France

^c Orthopedic Department, College of Medicine, King Saud University, Riyadh, Saudi Arabia

Introduction

It is well known that adolescent idiopathic scoliosis (AIS) is a three-dimensional deformity of the trunk and spine; characterized by a spinal curve or curves in the patient's coronal plane. Nevertheless, the sagittal plane represents an important aspect of the patient's balance [1]. Proximal junctional kyphosis is a recently recognized phenomenon in adolescents after AIS surgery. As it has been reported by Yan et al. the incidence of the proximal junctional kyphosis in the adolescent patients was estimated at 11% with a range of 0–55% depending on the study; revision surgery was needed in 10% of these cases [2]. Etiology of PJK is likely multifactorial, with risk factors including thoracoplasty, hybrid instrumentation (proximal hooks and distal pedicle screws, pelvic fixation), integrity of the posterior ligaments, and a preoperative large sagittal thoracic Cobb angle ($T5-T12 > 40^\circ$) [3]. Kim et al. reported that a greater immediate postoperative thoracic kyphosis angle decrease and male sex correlated significantly with PJK [4].

The head's center of gravity passes in front of the cervical spine, thus inducing a non-negligible torque on the spine, considering that the head represents about 7% of total body-weight [5]. Therefore, the global spine alignment including the head should be considered during the surgical planning of posterior instrumentation.

Type 1 and type 2 Lenke curves are associated with abnormal thoracic sagittal alignment, but it has been shown that thoracic hypokyphosis and cervical hypolordosis, often observed in AIS, can be improved postoperatively [6][7][8]. Patients with thoracic hypokyphosis usually compensate with cervical hypolordosis. Hayashi et al. reported that a preoperative cervical lordosis angle (CLA) lower than -5° and a preoperative thoracic kyphosis (TK) lower than 10° were significantly associated with postoperative cervical hyperkyphosis [9]. Wang et al. reported that the cervical sagittal alignment in AIS patients was related with lumbar lordosis and particularly with thoracic kyphosis [7], . It has been reported in many studies that the cervical sagittal alignment correlate with health-related quality of life (HRQOL) in AIS patients [10][11], and that suboptimal sagittal alignment after corrective surgery, such as decreased thoracic kyphosis (TK), is a possible cause of lumbar or cervical spinal degeneration and junctional malalignment [1].

Cotrel-Dubousset instrumentation with concave derotation technique by rod precontouring was able to restore thoracic kyphosis for patients with hypokyphotic spines, preserving or re-establishing normal lumbar lordosis in a considerable percentage of patients [12]–[14]. The

purpose of this series was to analyze global sagittal alignment including the cranial center of mass (CCOM) and proximal junctional kyphosis in AIS patients treated with this technique.

Materials and Methods

Subjects:

After Ethics Committee approval, the data collection of 85 patients with a minimum of two years follow up was carried out retrospectively. The age range was 12 to 18 years old at the time of surgery. All surgeries were performed at the same center by the same surgeon between 2008 and 2014. Only AIS patients treated with posterior fusion with all pedicle screws constructs were considered. No revision cases were included in this study. Proximal fixations ended at the T2–T4 vertebral level. The spine was exposed proximally with care. No violation of facets superior to the UIV occurred, and no resection of interspinous ligament. The radiobiological data of fifty-one asymptomatic adolescents with age ranged from 12 to 18 years old were also retrospectively collected to evaluate normality corridors of clinical parameters.

Protocol:

Bi-planar radiographies were acquired with a low-dose x-ray device (EOS Imaging, Paris, France), [15]. Images were acquired with the patients standing upright with the hands resting on the clavicles and keeping forward eye gaze as described by Faro et al. [16]. Patients with inadequate position were excluded.

Radiological examinations were performed preoperative and at the last follow up for all patients, while radiographies were also acquired immediately after surgery and three months after surgery for eight of the eleven patients who developed proximal junctional kyphosis (PJK).

EOS system was validated to provide reliable 3D reconstruction of spine deformity [17] [18]. 3D reconstructions of pelvis, spine [from C3 to L5] and the most superior point of dentiform apophyse of C2 (OD) was performed (Figure 1). In addition, as described by Vital et al. [5] two stereo-corresponding points localizing the nasion and inion were digitized on the sagittal and coronal views in each reconstructed model to compute the cranial center of mass (CCOM) (Figure 2). 3D reconstructions were also performed for fifty-one healthy adolescents to determine the normality corridor of CCOM position.

The parameters analyzed in this study were described in (Table 1); all parameters were calculated in the patient's sagittal plane.

Proximal Junctional Kyphosis (PJK):

Abnormal PJK was defined as the post-operative proximal junctional sagittal angle between the lower endplate of the uppermost instrumented vertebra and the upper endplate of two supra-adjacent superior to 10° and increased by at least 10° relative to the preoperative measurement [3].

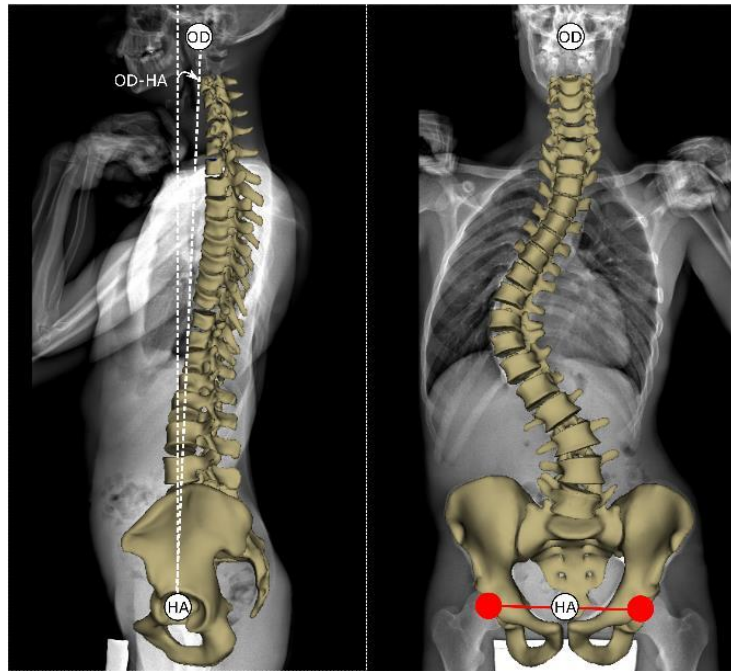


Fig. 1. 3D reconstruction of pelvis and spine (from C3 to Sacrum). OD is the most superior point of dentiform apophyse of C2, HA is the center of the bi-coxofemoral segment. OD-HA is the angle between the vertical line from HA and the line joining OD and HA.

UIV-OD and UIV-CCOM Offsets:

The lever arm between the body's center of the upper instrumented vertebra (UIV) and the vertical line that passes through either the most superior point of dentiform apophyse of C2 (UIV-OD offset) or the cranial center of mass (UIV-CCOM offset).

Statistical analysis:

Clinical parameters were compared for all patients before and after surgery (paired Wilcoxon tests). A Mann-Whitney U test was performed to analyze differences between preoperative parameters among the PJK and no PJK groups, while Kruskal-Wallis tests were used to compare healthy population with preop PJK and preop non-PJK patients.

Correlations were quantified using pairwise Spearman correlations. Non-parametric tests were used to account for the non-normal distribution of several variables (Lilliefors normality test). Significance level was set at 0.05.

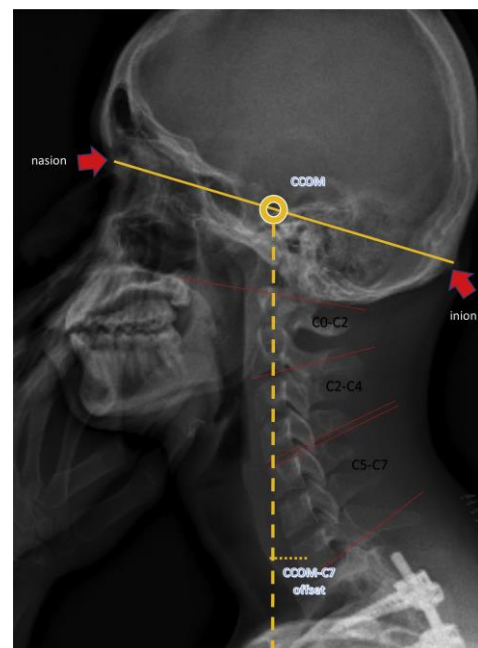


Fig. 2. CCOM, Cranial Center Of Mass is midway on the nation-inion line. CCOM-C7 offset is the distance between the vertical line from CCOM and center of C7 body.

Results

Demographic Data:

The mean age was 15.6 years old (standard deviation SD = 1.99 years old) for AIS patients and 16.3 years (standard deviation SD = 1.7 years old) for asymptomatic adolescents subjects. 88.2 % female (75 patients), 11.8 % male (10 patients) of AIS patients and 67 % female, 33 % male of asymptomatic subjects. The mean weight of AIS patients was 51.3 kg (SD = 9.5 kg) with mean BMI of 20 (SD = 3.7). Full set of radiographies (pre-op, immediate post-op, 3-months post-op and last follow-up) were only available for eight PJK patients; for all other patients only a pre-op and last follow up exams were available. No differences of surgical intervention were detected to explain PJK.

Results on all parameter before surgery and at last follow-up are reported in Table 1.

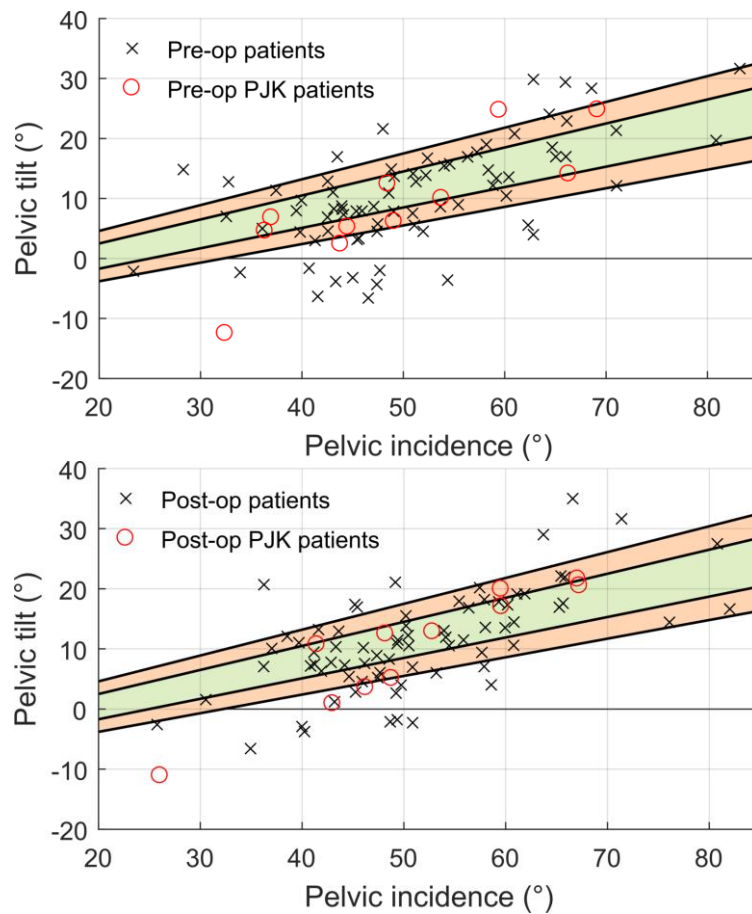


Fig. 3. Normality corridor for the [pelvic](#) tilt (PT) based on its relation with pelvic incidence (PI) provided by Vialle et al. ($PT = -7 + 0.37 PI$). The green band (mean + SD) and orange band ($2*SD$) is the corridor of normality among 51 asymptomatic adolescents.

Table 1. Computed Parameters of control group and AIS patients before surgery and at two years follow up. OD: the most superior point of dentiform apophyse of C2, CCOM: Cranial Center Of Mass, HA: the center of the bi-coxofemoral segment, UIV: Upper Instrumented Vertebra

Abbreviation	Parameter	Mean \pm SD (Healthy subjects)	Mean \pm SD (AIS Pre OP)	Mean \pm SD (AIS Last follow up)	P value (AIS Pre-Op vs Last FU)
CL C3-C7	Cervical lordosis C3-C7 ($^{\circ}$)	-3.7 \pm 0.1	16.6 \pm 6.5	11.7 \pm 7.9	0.00007
OD-HA	Angle between the vertical and the line that connects OD to HA ($^{\circ}$)	-2.3 \pm 2	-2.3 \pm 1.9	-2.8 \pm 1.7	0.009
CCOM-HA	Angle between the vertical and the line that connects CCOM to HA ($^{\circ}$)	-1.5 \pm 1.8	-1.3 \pm 1.8	-1.9 \pm 1.7	0.003
C7-HA	Angle between the vertical and the line that connects C7 to HA ($^{\circ}$)	-4 \pm 2.1	-4.5 \pm 2.2	-5.5 \pm 1.9	0.0003
OD-HA offset	Distance between two vertical lines that fit the OD and HA (mm)	-26.1 \pm 15.3	-24.1 \pm 19.3	-30.9 \pm 19	0.003
CCOM- HA offset	Distance between two vertical lines that fit CCOM and HA (mm)	-16.8 \pm 19.6	-13.9 \pm 20.3	-21.8 \pm 19.6	0.002
CCOM-Sacrum offset	Distance between CCOM and S1 plateau's center (mm)	-0.7 \pm 17.7	2.6 \pm 18.9	-3.4 \pm 18.5	0.01
C7-HA offset	Distance between two vertical lines that fit the C7 body's center and HA (mm)	-18.9 \pm 20.6	-39.3 \pm 19.2	-50.5 \pm 17.2	0.002

C7 SVA	Sagittal vertical axis (Distance between C7 body's center and S1 plateau's center) (mm)	-8.9 ± 21.6	-22.8 ± 18	-32.1 ± 16.3	0.0001
T1S	T1 Slope (°)	20.1 ± 5	12.7 ± 7.9	14.1 ± 7	0.1
Inclination	Angle between the vertical and the line that best fits: OD, all the vertebral bodys' centers from C3 to L5, and S1 (°)	-2.8 ± 2.7	0.7 ± 20.6	11.4 ± 24	0.007
CA	Cobb angle (°)	-	64.1 ± 12.4	25.4 ± 8.8	1.2*10-15
T1–T12 Ky	T1–T12 kyphosis (°)	42.4 ± 12.6	32.2 ± 10.6	38.4 ± 9.8	0.0001
T4–T12 Ky	T4–T12 kyphosis (°)	30.2 ± 10.6	23.2 ± 11.9	24.9 ± 9.2	0.3
L1–S1 LL	L1–S1 lumbar lordosis (°)	-52.1 ± 12	-55.3 ± 9.8	-55.7 ± 8.4	0.8
PI	pelvic incidence (°)	49.7 ± 11.4	50.7 ± 9.1	51.1 ± 8.5	0.7
PT	pelvic tilt (°)	9.6 ± 7.6	10.3 ± 6.9	11.1 ± 6.4	0.2
SS	sacral slope (°)	40 ± 9.4	40.4 ± 6.4	38.2 ± 7.6	0.3
PJK angle	Angle between the inferior plate of UIV and the superior plate of two vertebrae above (°)	-	8.2 ± 6.2	12.9 ± 6.6	0.0000003

Thoracolumbar and Spinopelvic Sagittal Alignment:

The average L1-S1 lordosis and pelvic tilt remained constant from preoperative to last follow-up at -55° and 10.3° preop values, respectively. However, this unchanged average mask significant inter-individual differences: nineteen (22.4%) patients had their pelvic incidence modified by more than 5° at the follow-up of two years, while 23 patients (27%) modified their pelvic tilt. Twenty-seven patients (32%) preoperatively versus twenty-four patients (28%) postoperatively were outside the normality corridor for pelvic tilt provided by Vialle's et al [19] (Figure 3). The average T1-T12 kyphosis significantly increased by 6.2° postoperatively ($P = 0.0001$), thus getting closer to the values of the healthy population ($42.4 \pm 12.6^\circ$). Lordosis was similar in AIS patients and healthy control, and it did not significantly change postop.

Head and Cervical Sagittal Alignment:

In AIS patients, cervical C3–C7 lordosis was significantly higher than in the healthy population (Table 1), and it significantly decreased after surgery by 4.9° ($p < 0.0001$), towards normal values. Among AIS patients the average OD-HA and CCOM-HA angles were respectively $-2.3^\circ \pm 1.9^\circ$ and $-1.3^\circ \pm 1.8^\circ$ preoperatively and $-2.8^\circ \pm 1.7^\circ$ and $-1.9^\circ \pm 1.7^\circ$ at two years follow up. Among normal adolescents the average OD-HA angle and CCOM-HA angle were $-2.3^\circ \pm 2^\circ$ and $-1.5^\circ \pm 1.8^\circ$ respectively. (Figure 4).

Proximal Junctional Kyphosis subgroup:

The average PJK angle for the whole population increased between preoperative and at the last follow up by 4.7° ($p < 0.0001$). 13% (11 patients; 9 Female/ 2 Male) had abnormal PJK at the last follow up, 36 % (4 patients) of them developed PJK during the first three months following the surgery. The average age at time of surgery was 15 years ($SD = 1.9$). Evolution of the proximal junctional angle among the patients with PJK at three times interval after surgery (preoperative, immediately after surgery, three months after surgery and at the last follow up) is shown in Figure 5.

Preoperatively, PJK and non PJK patients did not show particular differences preoperatively. The average preoperative C3-C7 lordosis was similar between PJK group ($12.1^\circ \pm 8.3^\circ$) and non PJK group ($17.3^\circ \pm 6.2^\circ$, $p = 0.2$), but they were different from the control group ($p < 0.05$, Table 2). Postoperatively, the cervical lordosis increased by 6.1° in PJK group and 4.7° in non PJK group, while thoracic T1-T12 kyphosis increased by $8.8 \pm 6.1^\circ$ and $9.8 \pm 7.2^\circ$ in the two groups, respectively. The average preoperative T4-T12 kyphosis in PJK group was

Table 2. Pre-operative radiological parameters of PJK and non PJK group comparing with normal subjects. The preoperative thoracic kyphosis (T4-T12) was almost the same among the control and PJK group; 30.2° and 30.6° respectively but was less in non PJK group; 22.1°.

	Mean ± SD (Control Group)	Mean ± SD (AIS Non-PJK Group)	Mean ± SD (AIS PJK Group)	P value (Control, PJK, Non-PJK) Kruskal-Wallis test
Pelvic incidence	49.7° (± 11.4°)	51° (± 9.0°)	49.1° (+-9.5)	>0 .05
Sacral Slope	40° (± 9.4°)	40.3° (± 6.5°)	40.7° (± 5.3°)	>0 .05
Pelvic Tilt	9.6° (± 7.6°)	10.5° (± 6.8°)	9° (± 7.5°)	>0 .05
C7 SVA	-8.9mm (± 21.6mm)	-23.2mm (± 17.3mm)	-20.3mm (± 22.7mm)	<0 .05
C3-C7 Lordosis	-3.7° (± 0.1°)	17.3° (± 6.2°)	12.1° (± 8.3°)	<0 .05
T1-T12 Kyphosis	42.4° (± 12.6°)	31.3° (± 10.7°)	38° (± 9.6°)	<0 .05
T4-T12 Kyphosis	30.2° (± 10.6°)	22.1° (± 11.6°)	30.6° (± 12.6°)	<0 .05
L1-L5 Lordosis	-52.1° (± 12°)	-54.9° (± 9.9°)	-57.8° (± 8.9°)	>0 .05
Inclination Angle	-2.8° (± 2.7°)	-0.6° (± 21.3°)	10° (± 9.9°)	<0 .05
OD-HA	-2.3° (±2.0°)	-2.3° (± 1.9°)	-2° (± 1.7°)	>0 .05
CCOM-HA	-1.5 (± 1.8°)	-1.3° (± 1.8°)	-0.8° (± 1.8°)	>0 .05

30.6° ± 12.6° and 22.1° ± 11.6° in non PJK group (P = 0.4), but again, AIS differed from the control group (p < 0.05, Table 2). The average preoperative L1-S1 lordosis in PJK group was -57.8° ± 8.9° and -54.9° ± 9.9° in non PJK group (p = 0.4). The average preoperative body inclination in PJK group was 10° ± 9.9° and -0.6° ± 21.3° in non PJK group (p = 0.5). There was no statistical difference between the mean of UIV-OD, UIV-CCOM Offsets among the PJK and non PJK groups pre- or postoperatively.

Figure 6 shows an example of a patient who developed a pathological PJK. She had 10° PJK increase from preop to postop, with an increase of almost 20° in T1-T12 kyphosis (from 26° to 45°). Her inclination also increased from 18° to 44°; still, her OD-HA angle only changed from 0.5° preop to -0.3° postop.

Discussion

The "cone of economy" is a concept described by Dubousset; maintaining the head over the pelvis allows for an energy economic status for ambulation and upright posture [20]. In which minimum muscular energy is required to maintain balance between the heavy cephalic vertebrae (the head) and the polygon of support (both feet). The predominant role of the pelvis

(pelvic vertebrae) is to adapt this posture. Vital et al. conducted an experimental study in six cadavers to determine the center of gravity of the head. Radiologically, this center lies above and slightly in front of the external auditory meatus at the middle of the nasion-inion line. In profile, the axis of gravity passes in front of the cervical spine [5]. El Fegoun et al.

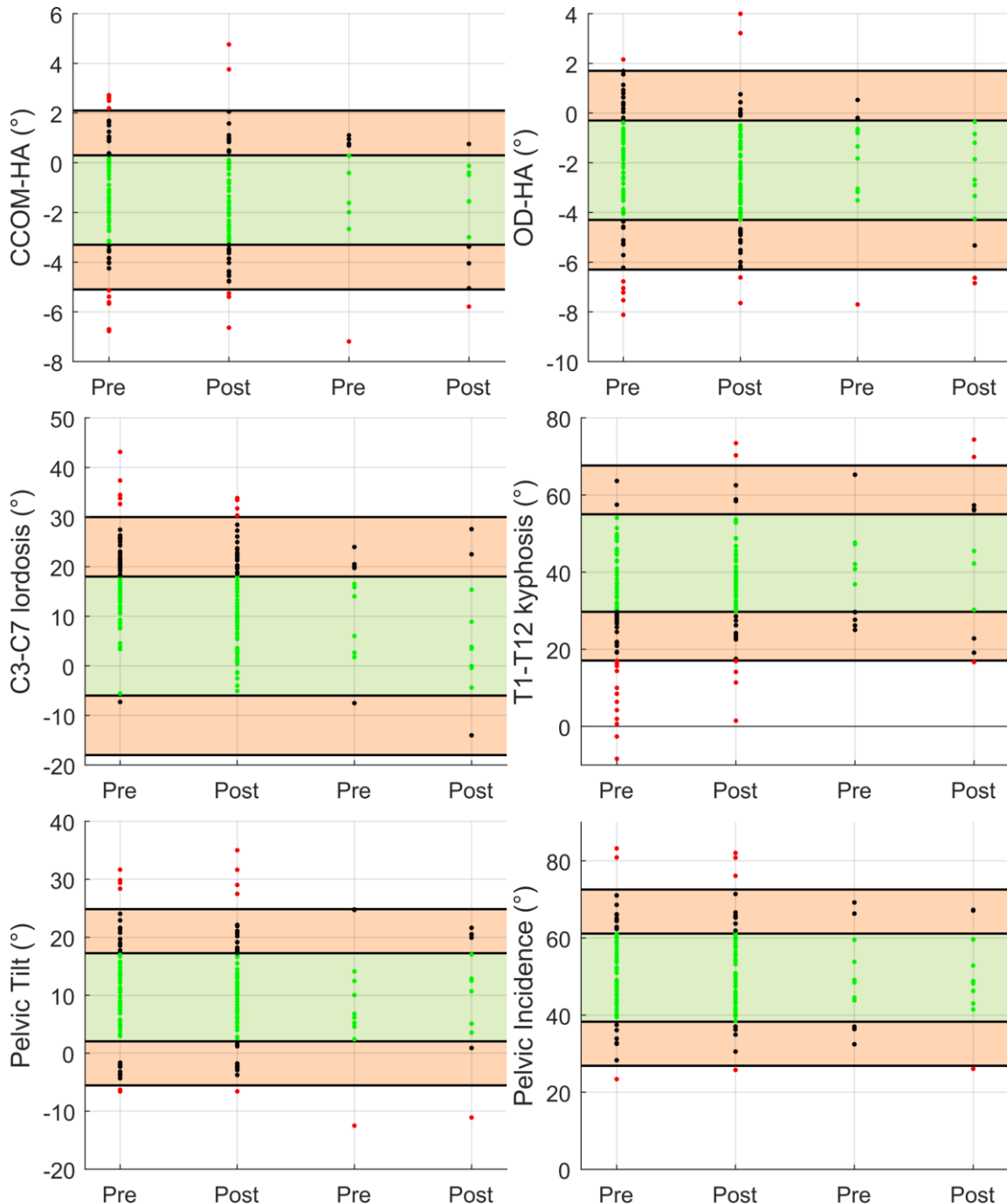


Fig. 4. Pre- and postoperative parameters in the two groups (Group 1: Non-PJK group, and Group 2: PJK group). (A) CCOM-HA (°) and OD-HA (°). CCOM-HA angle: from -3.3° to 0.3° , normal; from 0.3° to 2.1° , subnormal high; from -3.3° to -5.1° , subnormal low. (B) C3–C7 [lordosis](#), T1–T12 [kyphosis](#), [pelvic](#) tilt, and pelvic incidence. The green band (mean \pm SD) and the orange band ($2 \times$ SD) represent the corridor of normality among 51 asymptomatic adolescents. CCOM, cranial center of mass; OD, odontoid; HA, center of the bi-coxofemoral segment.

conducted an experimental study among normal and scoliotic patients by doing radiographic and force plate analysis. The mean sagittal plane alignment of the gravity in relation to the C7 plumb line revealed an offset anteriorly [21]. To improve surgical treatment, a complete understanding of the deformity and its influence on cervical sagittal alignment seems necessary to optimize correction strategies. Few studies have analysed sagittal cervical profile in AIS patients [6]–[9], [22], [23]. Most authors do not take in consideration the center of gravity of the head. Studying the postural alignment from head to feet allows for a complete view of the possible compensatory mechanisms. Few studies include in their analysis a point at the head level (cranial center of mass) or C2 in normal individuals [24], [25]. To our knowledge no study performed in patients with adolescent idiopathic scoliosis include a point at the head to analyse the global sagittal alignment.

Rousseau et al. reported that the reproducibility EOS stereoradiography system is favorably compared with other imaging methods [26]. Also, Ilharreborde et al. has reported that the 3D postoperative reconstructions are as reproducible as preoperative ones and the reproducibility is not influenced by the type of implant used for correction [27]. The small sample size of patients with proximal junctional kyphosis limits the statistical analysis. Furthermore, it is challenging to achieve a satisfactory posture of the patient while acquiring biplanar X-ray data. This could have influenced the results particularly at the cervical spine level. To limit the effect, every patient was asked to look in a mirror fixed at eye’s level during acquisition.

Comparing with normal asymptomatic adolescents. we noticed that OD-HA angle was almost constant (-2.3°) among control, non PJK and PJK groups with a standard deviation at 2° , 1.9° and 1.7°

respectively. Six patients had abnormal OD-HA angle postoperatively. Two of them had OD-HA angle $> 1.7^\circ$ and four had OD-HA angle $< -6.3^\circ$. The average CCOM-HA angle

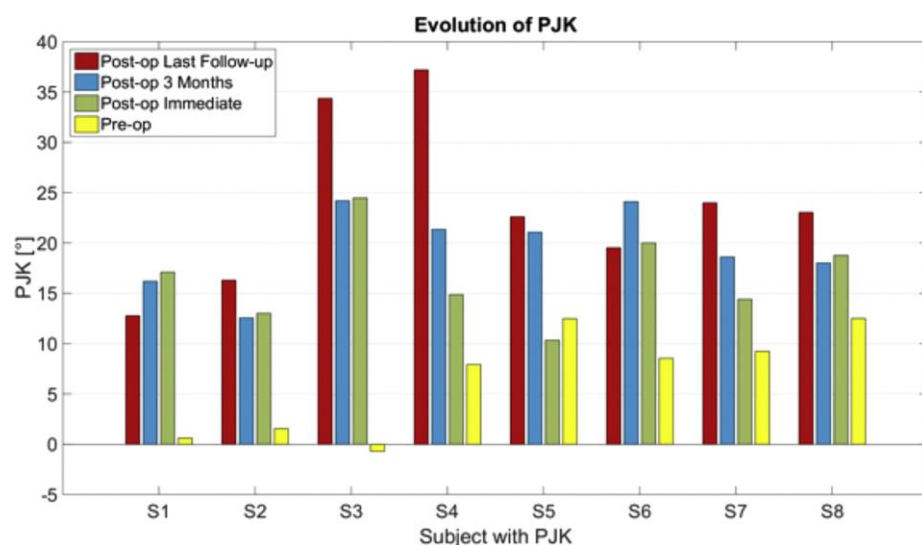


Fig. 5. Evolution of the change in proximal junctional angle among the eight patients with proximal junctional [kyphosis](#) (PJK) at three time intervals after surgery.

among non PJK and PJK group were respectively -1.3° (SD = 1.8°), -0.8° (SD = 1.8°) preoperatively and -1.8° (SD = 1.7°), -2.2° (SD = 1.8°) at two years follow up. The CCOM-HA angle is more relevant to global alignment with less mean and slightly lower standard deviation. It remains almost constant among all patients before and after surgery. The average C7 SVA in normal subjects, non PJK and PJK group was -8.9° (SD = 21.6°), -23.2° (SD = 15.7°) and -20.3° (22.7°) respectively which reveals a posterior shift of plumb line among the patients with AIS (table 2).

Sugrue et al. studied 78 asymptomatic 20 to 40 years old adult and reported the average CCOM-Sacrum offset at 9.0 mm (SD, 31.5 mm) [25]. In our series, we noticed the normal value of CCOM-Sacrum offset among 51 asymptomatic adolescents at -0.74 mm (SD= 17.7 mm). McClendon et al. conducted a study in patients with adult spine deformity with mean age of 60.5 years. The average preoperative CCOM-Sacrum offset was 10.0 cm (SD = 6.58 cm) and the average CCOM-Sacrum offset at two years follow up was 4.19 cm (SD = 4.65 cm). They reported that SRS-22 appearance worsened as preoperative CCOM-Sacrum offset increased ($P < 0.05$), 2-year SRS-22 appearance and mental health was worsened as 2-year CCOM-Sacrum offset increased ($P < 0.05$) [28].

Patients tended to keep the head above the pelvis, thus maintaining OD-HA and CCOM-HA within the normal range. Post-surgery compensation mechanism could be an increase or decrease of pelvic incidence, PJK angle or cervical lordosis, but not at the free spine segment

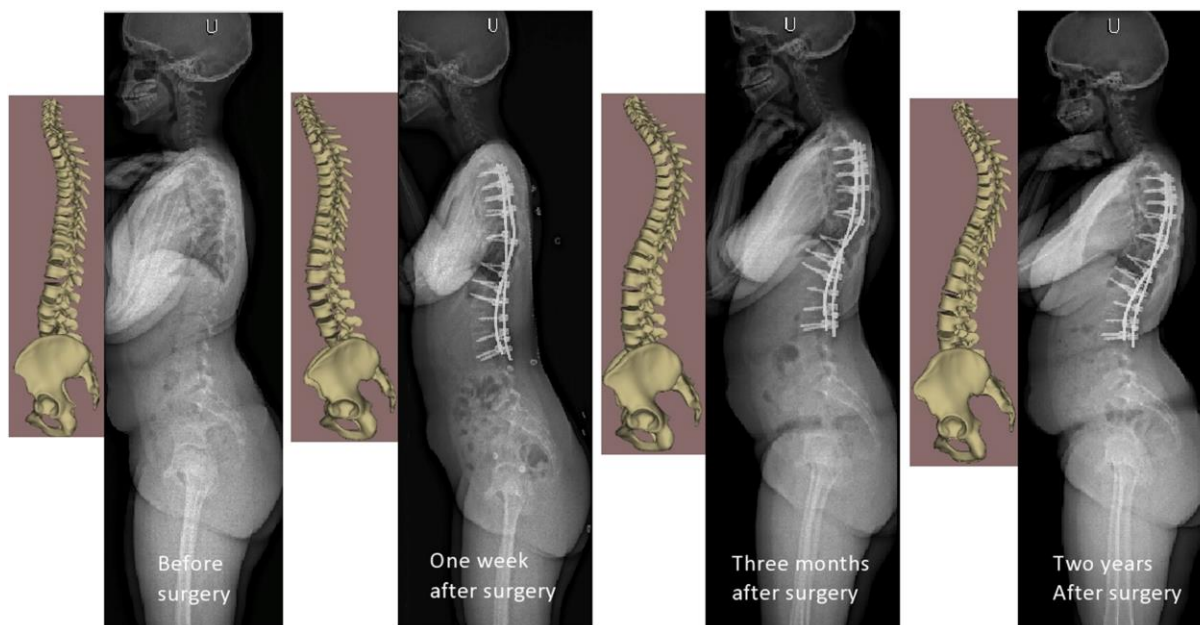


Fig. 6. The evolution of a patient with adolescent idiopathic scoliosis before and after surgery. To keep the head above the pelvis, the patient changes his cervical sagittal alignment and his pelvis shape by increasing the pelvic incidence.

below the instrumentation. Nineteen (22.4%) patients had changed their pelvic incidence more than 5° at the two years follow up; 11 patients had increased their pelvic incidence by 8.8° (SD = 2.4°) and eight patients had decreased their pelvic incidence by 9.6° (SD = 3.7°). Skalli et al. reported the importance of pelvic compensation in posture and motion after posterior spinal fusion and instrumentation for idiopathic scoliosis [29]. Nevertheless, changes in pelvic tilt remain important postoperatively, with 27% of patients showing changes of more than 5° .

At two years follow up nine patients had the PJK angle between 10° and 15° and two patients had a PJK angle between 30° and 35° . These patients had a clear tendency to decrease their thoracic kyphosis with time at the instrumented level. Comparing with non PJK group the average preoperative thoracic kyphosis (T4-T12) increased by 8.5° . Lonner et al. studied with multivariate analysis the preoperative predisposing factors to maintain the thoracic kyphosis at two years follow up. They reported that greater number of levels fused ($r = -0.33$, $P < 0.001$), preoperative kyphosis ($r = -0.39$, $P < 0.001$), percentage of screws in the construct ($r = -0.18$, $P = 0.03$), using standard stainless-steel rods ($r = -0.47$, $P = 0.011$), and percent decrease in thoracic curve ($r = -0.23$, $P < 0.001$) all were correlated with hypokyphosis at follow-up. In one patient, the CCOM-HA angle remain abnormal ($< -4.8^\circ$) after surgery. The CCOM-UIV increased with time after surgery.

C7-HA significantly changed post-operatively, indicating a variation of cervical alignment. However, the head alignment (OD-HA, CCOM-HA) remained quasi-unchanged, as the head was kept above the pelvis, and this irrespectively of other global sagittal alignment. In particular, thoracic kyphosis was changed on purpose by surgery for all patients, thus also modifying global inclination, so it stands to reason that some other aspects of the alignment must have changed to keep OD-HA and CCOM-HA constant. This is what was called a “compensation mechanism” in the present work. While PJK remains a multifactorial problem, these results suggest that global sagittal alignment could play a role in its development, and therefore analysis of sagittal balance, including the head, should be included in preoperative planning and in the assessment of postoperative results.

Conflict of interest: There is no conflict of interest to declare.

References

- [1] B. S. Lonner et al., "Multivariate analysis of factors associated with kyphosis maintenance in adolescent idiopathic scoliosis," *Spine*, vol. 37, no. 15, pp. 1297–1302, Jul. 2012.
- [2] C. Yan, Y. Li, and Z. Yu, "Prevalence and Consequences of the Proximal Junctional Kyphosis After Spinal Deformity Surgery: A Meta-Analysis," *Medicine (Baltimore)*, vol. 95, no. 20, p. e3471, May 2016.
- [3] Y. J. Kim, K. H. Bridwell, L. G. Lenke, J. Kim, and S. K. Cho, "Proximal junctional kyphosis in adolescent idiopathic scoliosis following segmental posterior spinal instrumentation and fusion: minimum 5-year follow-up," *Spine*, vol. 30, no. 18, pp. 2045–2050, Sep. 2005.
- [4] Y. J. Kim et al., "Proximal junctional kyphosis in adolescent idiopathic scoliosis after 3 different types of posterior segmental spinal instrumentation and fusions: incidence and risk factor analysis of 410 cases," *Spine*, vol. 32, no. 24, pp. 2731–2738, Nov. 2007.
- [5] J. M. Vital and J. Senegas, "Anatomical bases of the study of the constraints to which the cervical spine is subject in the sagittal plane A study of the center of gravity of the head," *Surg. Radiol. Anat.*, vol. 8, no. 3, pp. 169–173, Sep. 1986.
- [6] B. Ilharreborde, C. Vidal, W. Skalli, and K. Mazda, "Sagittal alignment of the cervical spine in adolescent idiopathic scoliosis treated by posteromedial translation," *Eur. Spine J. Off. Publ. Eur. Spine Soc. Eur. Spinal Deform. Soc. Eur. Sect. Cerv. Spine Res. Soc.*, vol. 22, no. 2, pp. 330–337, Feb. 2013.
- [7] L. Wang and X. Liu, "Cervical sagittal alignment in adolescent idiopathic scoliosis patients (Lenke type 1-6)," *J. Orthop. Sci. Off. J. Jpn. Orthop. Assoc.*, vol. 22, no. 2, pp. 254–259, Mar. 2017.
- [8] E. P. Norheim, L. Y. Carreon, D. J. Sucato, L. G. Lenke, and S. D. Glassman, "Cervical Spine Compensation in Adolescent Idiopathic Scoliosis," *Spine Deform.*, vol. 3, no. 4, pp. 327–331, Jul. 2015.
- [9] K. Hayashi et al., "Cervical lordotic alignment following posterior spinal fusion for adolescent idiopathic scoliosis: reciprocal changes and risk factors for malalignment," *J. Neurosurg. Pediatr.*, vol. 19, no. 4, pp. 440–447, Apr. 2017.
- [10] M. S. Youn, J. K. Shin, T. S. Goh, S. S. Kang, W. K. Jeon, and J. S. Lee, "Relationship between cervical sagittal alignment and health-related quality of life in adolescent idiopathic scoliosis," *Eur. Spine J. Off. Publ. Eur. Spine Soc. Eur. Spinal Deform. Soc. Eur. Sect. Cerv. Spine Res. Soc.*, vol. 25, no. 10, pp. 3114–3119, Oct. 2016.
- [11] T. S. Protopsaltis et al., "How the neck affects the back: changes in regional cervical sagittal alignment correlate to HRQOL improvement in adult thoracolumbar deformity patients at 2-year follow-up," *J. Neurosurg. Spine*, vol. 23, no. 2, pp. 153–158, Aug. 2015.
- [12] K. H. Bridwell, R. Betz, A. M. Capelli, G. Huss, and C. Harvey, "Sagittal plane analysis in idiopathic scoliosis patients treated with Cotrel-Dubousset instrumentation," *Spine*, vol. 15, no. 7, pp. 644–649, Jul. 1990.
- [13] H. Labelle et al., "Comparison between preoperative and postoperative three-dimensional reconstructions of idiopathic scoliosis with the Cotrel-Dubousset procedure," *Spine*, vol. 20, no. 23, pp. 2487–2492, Dec. 1995.
- [14] Y. Qiu et al., "Comparison of surgical outcomes of lenke type 1 idiopathic scoliosis: vertebral coplanar alignment versus derotation technique," *J. Spinal Disord. Tech.*, vol. 24, no. 8, pp. 492–499, Dec. 2011.

- [15] J. Dubousset, G. Charpak, W. Skalli, G. Kalifa, and J.-Y. Lazenec, "[EOS stereoradiography system: whole-body simultaneous anteroposterior and lateral radiographs with very low radiation dose]," *Rev. Chir. Orthop. Reparatrice Appar. Mot.*, vol. 93, no. 6 Suppl, pp. 141–143, Oct. 2007.
- [16] F. D. Faro, M. C. Marks, J. Pawelek, and P. O. Newton, "Evaluation of a Functional Position for Lateral Radiograph Acquisition in Adolescent Idiopathic Scoliosis:," *Spine*, vol. 29, no. 20, pp. 2284–2289, Oct. 2004.
- [17] J. Dubousset et al., "[A new 2D and 3D imaging approach to musculoskeletal physiology and pathology with low-dose radiation and the standing position: the EOS system]," *Bull. Acad. Natl. Med.*, vol. 189, no. 2, pp. 287-297; discussion 297-300, Feb. 2005.
- [18] L. Humbert, J. A. De Guise, B. Aubert, B. Godbout, and W. Skalli, "3D reconstruction of the spine from biplanar X-rays using parametric models based on transversal and longitudinal inferences," *Med. Eng. Phys.*, vol. 31, no. 6, pp. 681–687, Jul. 2009.
- [19] R. Vialle, N. Levassor, L. Rillardon, A. Templier, W. Skalli, and P. Guigui, "Radiographic Analysis of the Sagittal Alignment and Balance of the Spine in Asymptomatic Subjects:," *J. Bone Jt. Surg.*, vol. 87, no. 2, pp. 260–267, Feb. 2005.
- [20] J. Dubousset, "Reflections of an orthopaedic surgeon on patient care and research into the condition of scoliosis," *J. Pediatr. Orthop.*, vol. 31, no. 1 Suppl, pp. S1-8, Feb. 2011.
- [21] A. B. El Fegoun, F. Schwab, L. Gamez, N. Champain, W. Skalli, and J.-P. Farcy, "Center of gravity and radiographic posture analysis: a preliminary review of adult volunteers and adult patients affected by scoliosis," *Spine*, vol. 30, no. 13, pp. 1535–1540, Jul. 2005.
- [22] M. Yu, C. Silvestre, T. Mouton, R. Rachkidi, L. Zeng, and P. Roussouly, "Analysis of the cervical spine sagittal alignment in young idiopathic scoliosis: a morphological classification of 120 cases," *Eur. Spine J. Off. Publ. Eur. Spine Soc. Eur. Spinal Deform. Soc. Eur. Sect. Cerv. Spine Res. Soc.*, vol. 22, no. 11, pp. 2372–2381, Nov. 2013.
- [23] Y. P. Charles, G. Sfeir, V. Matter-Parrat, E. A. Sauleau, and J.-P. Steib, "Cervical sagittal alignment in idiopathic scoliosis treated by posterior instrumentation and in situ bending," *Spine*, vol. 40, no. 7, pp. E419-427, Apr. 2015.
- [24] C. Amabile, H. Pillet, V. Lafage, C. Barrey, J.-M. Vital, and W. Skalli, "A new quasi-invariant parameter characterizing the postural alignment of young asymptomatic adults," *Eur. Spine J.*, vol. 25, no. 11, pp. 3666–3674, Nov. 2016.
- [25] P. A. Sugrue et al., "Redefining Global Spinal Balance: Normative Values of Cranial Center of Mass From a Prospective Cohort of Asymptomatic Individuals," *Spine*, vol. 38, no. 6, pp. 484–489, Mar. 2013.
- [26] M.-A. Rousseau, S. Laporte, E. Chavary-Bernier, J.-Y. Lazenec, and W. Skalli, "Reproducibility of measuring the shape and three-dimensional position of cervical vertebrae in upright position using the EOS stereoradiography system," *Spine*, vol. 32, no. 23, pp. 2569–2572, Nov. 2007.
- [27] B. Ilharberde et al., "Angle Measurement Reproducibility Using EOS Three-Dimensional Reconstructions in Adolescent Idiopathic Scoliosis Treated by Posterior Instrumentation:," *Spine*, vol. 36, no. 20, pp. E1306–E1313, Sep. 2011.
- [28] J. McClendon, R. B. Graham, P. A. Sugrue, T. R. Smith, S. E. Thompson, and T. R. Koski, "Cranial Center of Mass Compared to C7 Plumb Line Alignment in Adult Spinal Deformity," *World Neurosurg.*, vol. 91, pp. 199–204, Jul. 2016.
- [29] W. Skalli et al., "Importance of pelvic compensation in posture and motion after posterior spinal fusion using CD instrumentation for idiopathic scoliosis," *Spine*, vol. 31, no. 12, pp. E359-366, May 2006.