



Science Arts & Métiers (SAM)

is an open access repository that collects the work of Arts et Métiers Institute of Technology researchers and makes it freely available over the web where possible.

This is an author-deposited version published in: <https://sam.ensam.eu>
Handle ID: <http://hdl.handle.net/10985/15878>

To cite this version :

Abir MASSAAD, Ayman ASSI, Ziad BAKOUNY, Christophe SAURET, Nour KHALIL, Wafa SKALLI, Ismat GHANEM - Three-dimensional evaluation of skeletal deformities of the pelvis and lower limbs in ambulant children with cerebral palsy - Gait and Posture - Vol. 49, p.102-107 - 2016

Any correspondence concerning this service should be sent to the repository

Administrator : scienceouverte@ensam.eu



Three-dimensional evaluation of skeletal deformities of the pelvis and lower limbs in ambulant children with cerebral palsy

Abir Massaad^{a,b,1}, Ayman Assi^{a,b,c,*}, Ziad Bakouny^a, Christophe Sauret^{c,2}, Nour Khalil^{a,1}, Wafa Skalli^{c,2}, Ismat Ghanem^{a,b,d,3}

^a Laboratory of Biomechanics and Medical Imaging, Faculty of Medicine, University of Saint-Joseph, Beirut, Lebanon

^b Gait Analysis Laboratory, SESOBEL, Zouk Mikael, Lebanon

^c Institut de Biomécanique Humaine Georges Charpak, Arts et Métiers ParisTech, Paris, France

^d Htel-Dieu de France Hospital, University of Saint-Joseph, Beirut, Lebanon

ABSTRACT

Article history:

Received 29 December 2015

Received in revised form 21 June 2016

Accepted 22 June 2016

Keywords:

Lower limbs
Cerebral palsy
3D reconstructions
Children
Pelvis
Posture

Skeletal abnormalities, affecting posture and walking pattern, increase with motor impairment in children with cerebral palsy (CP). However, it is not known whether these skeletal malalignments occur in children with slight motor impairment. Our aim was to evaluate skeletal malalignment at the level of the pelvis and lower limbs in ambulant children with CP, with slight motor impairment, using a low dose biplanar X-ray technique.

Twenty-seven children with spastic CP (mean age: 10.9 ± 4 years, 7 Hemiplegia, 20 Diplegia, GMFCS levels I:17, II:10), with no previous treatments at the hips and knees, underwent EOS[®] biplanar X-rays. A control group consisting of 22 typically developing children was also included. Three-dimensional reconstructions of the pelvis and lower limbs were performed in order to calculate 11 radiological parameters related to the pelvis, acetabulum and lower limbs.

Pelvic incidence and sacral slope were significantly increased in children with CP compared to TD children ($48^\circ \pm 7^\circ$ vs. $43^\circ \pm 8^\circ$, $42^\circ \pm 7^\circ$ vs. $38^\circ \pm 5^\circ$, respectively, $p=0.003$). Acetabular parameters did not significantly differ between the two groups. Femoral anteversion and neck shaft angle were significantly increased in children with CP ($25^\circ \pm 12^\circ$ vs. $14^\circ \pm 7^\circ$, $p < 0.001$; $134^\circ \pm 5^\circ$ vs. $131^\circ \pm 5^\circ$, $p=0.005$ respectively). No difference was found for tibial torsion.

This study showed that even slightly impaired children with CP have an anteverted and abducted femur and present positional and morphological changes of the pelvis in the sagittal plane. The orientation of the acetabulum in 3D seems to not be affected when children with CP present slight motor impairment.

© 2016 Elsevier B.V. All rights reserved.

1. Introduction

Cerebral Palsy (CP) is a neurological disorder that can cause muscle spasticity. The increased muscle tone of patients with CP is known to affect their posture and walking pattern [1]. Skeletal

malalignments of the lower limbs are often encountered in children with CP in the three planes [2–4] and are mainly caused by spasticity, abnormal posture, delays in gaining independent walking as well as gait alterations [5].

Previous studies have reported that skeletal malalignments of the lower limbs increase with motor impairment [2,6]. These studies have described only a few femoral parameters (neck shaft angle and femoral parameters) in different groups of CP that differed by their motor impairment but did not compare their results to those of control groups [2,7]. Moreover, it is not known whether these skeletal malalignments occur even in children with slight motor impairment.

Other studies have reported skeletal abnormalities of the hip and acetabulum in children with CP, such as hip dysplasia or acetabular deficiencies [8,9]. It was suggested that these abnormalities, which had been reported in severely affected children

* Corresponding author at: Laboratory of Biomechanics and Medical Imaging, Campus of Innovation and Sport, University of Saint-Joseph, Damascus Street, P.O. Box 1104-2020 Beirut, Lebanon.

E-mail address: ayman.assi@gmail.com (A. Assi).

¹ Laboratory of Biomechanics and Medical Imaging, Campus of Innovation and Sport, University of Saint-Joseph, Damascus Street, P.O. Box 1104-2020 Beirut, Lebanon.

² Institut de Biomécanique Humaine Georges Charpak, Arts et Métiers ParisTech, 151 Boulevard de l'Hôpital, 75013 Paris, France.

³ Department of Orthopaedic Surgery, Htel-Dieu de France Hospital, Alfred Naccache Avenue, Achrafiyeh, Beirut, Lebanon.

with CP, were mainly due to abnormal weight-bearing on the lower limbs. Since slightly impaired children with CP also present abnormal weight-bearing, it would be interesting to elucidate whether their acetabular parameters are affected as well.

The assessment of skeletal malalignments is important in surgical decision-making for children with CP [10], and is usually based on physical examination [11], two-dimensional X-Ray imaging [12] and three-dimensional (3D) gait analysis [13]. However, torsional abnormalities, such as abnormal femoral anteversion (FA) or tibial torsion (TT), require measurements in 3D.

Three-dimensional computed tomography (CT) is a reliable tool to measure FA and TT [10]. This technique has been used to measure these parameters in children with CP [6]. However, the use of this technique is limited by the high exposure to radiation [14] and the fact that its accuracy is affected by positional variables [10], which are difficult to control in children with CP. For these reasons, 3D CT scan is not routinely used to assess lower limb skeletal abnormalities in children with CP.

Low dose biplanar X-rays have been previously found to be a fast and reliable tool for the measurement of skeletal malalignments in the standing position [15–17]. This technique allows quantification of subject-specific skeletal parameters based on 3D reconstruction of the pelvis and lower limbs [16,18] and could be a viable alternative to CT in daily practice.

The aim of this study was to investigate whether ambulant children with CP, with slight motor impairment, present skeletal deformities at the pelvis and lower limbs, using the low dose biplanar X-ray technique.

2. Methods

2.1. Population

This is an IRB approved cross-sectional case-control review of a consecutive series of children with CP who underwent full body low dose biplanar radiographs using EOS[®] system (EOS Imaging, Paris France), in the setting of their pre-treatment evaluation.

Twenty-seven children with spastic CP (17 boys, 10 girls) were included. Motor impairment was defined according to GMFCS E&R levels [19]. Children with a history of previous orthopedic interventions (botulinum toxin, casting, surgery), other than those directed to treat equinus (botulinum toxin in gastrocnemius, lengthening) at least one year prior to the enrollment in the study, were excluded.

Twenty-two typically developing (TD) children (11 boys, 11 girls), for whom biplanar radiographs of their lower extremities had been prescribed for atypical pain and had not shown any abnormality, were included in the study (Table 1). The parents of the children in the CP and TD groups were informed of the possible use of their child's radiographs for research purposes and they approved and signed a written consent form.

2.2. Acquisition and 3D reconstruction

EOS[®] biplanar X-ray acquisition was performed in the standing position. The lower limbs were slightly shifted in the sagittal plane,

in order to avoid knee overlap on the lateral view therefore facilitating 3D reconstruction [15]. Typically developing children and children with CP were asked to stand in the free standing position, with hands on cheeks and flexed elbows [20]. This position is known to reproduce the natural posture of the subject. Children with CP were allowed, when necessary, to put their hands on the embedded bar in the EOS[®] cabin for better stability, without it affecting their natural posture.

One trained operator performed all 3D reconstructions of both lower limbs using SterEOS[®] (version 1.6.4.7977) based on a previously described method [15]: a few geometrical primitives and axes are first digitalized, in order to obtain a simplified personalized parametrical model. Then, a 3D morpho-realistic parametric model, based on a database of CT-Scan reconstructions, is deformed. This deformation is based on statistical shape modeling. Pelvic reconstruction is based on the same technique used for the lower limbs and is performed using a dedicated software developed at Arts et Métiers ParisTech [21] (Fig. 1).

2.3. Radiological parameters

Pelvic, acetabular, femoral and tibial parameters were automatically calculated from the 3D reconstructions of the pelvis and lower limbs of each subject. Eleven radiological parameters were chosen according to their clinical relevance in the diagnosis and decision-making for children with CP. Some of these parameters are routinely used: pelvic incidence (PI), sacral slope (SS), pelvic tilt (PT), femoral anteversion (FA), neck shaft angle (NSA) and tibial torsion (TT). Acetabular parameters are less used in the management of CP: 1) acetabular anteversion (AAnt) reflects the rotation of the acetabulum around the vertical axis [22]. In order to render this angle morphological, the vertical axis was defined as the perpendicular to the sacral plate; 2) acetabular inclination (Alnc) reflects the rotation of the acetabulum around the postero-anterior axis, defined as a parallel to the sacral plate [22,23]; 3) acetabular tilt reflects the rotation of the acetabulum around the medio-lateral axis of the pelvis [24]. The list and the description of each of these parameters are detailed in Table 2 and displayed in Fig. 2. These parameters were calculated for both limbs of the children in the CP and TD groups. The unaffected limbs of children with hemiplegia were excluded from further analysis. The mean values of the pelvic, acetabular and lower limb parameters were also separately calculated for children with GMFCS levels I (N = 17) and II (N = 10).

2.4. Statistics

Comparisons between demographic and radiological parameters of CP and TD children were performed using Student's *t*-test, Mann-Whitney's test or Welch's unequal variances *t*-test. Significance level was set at 0.05.

Means comparison between TD children and CP sub-groups (GMFCS levels I and II) were performed using one-way analysis of variance (ANOVA) with Hochberg's GT2 post-hoc test. Variances of parameters between CP and TD groups were compared using Levene's test.

Table 1

Demographic characteristics of the typically developing children (TD) and children with cerebral palsy (CP). Distribution of the children with CP according to the Gross Motor Classification System (GMFCS).

Groups	Age (years)	Weight (kg)	Height (cm)	N	Spastic Hemiplegia/Diplegia (N)	GMFCS Levels: I/II (N)
	Mean ± SD (min-max)	Mean ± SD	Mean ± SD			
TD children	12 ± 3 (6.5–19)	44.4 ± 13.8	149.9 ± 15	22		
CP children	10.9 ± 4 (6–19.6)	42.2 ± 20	140.1 ± 20	27	7/20	17/10

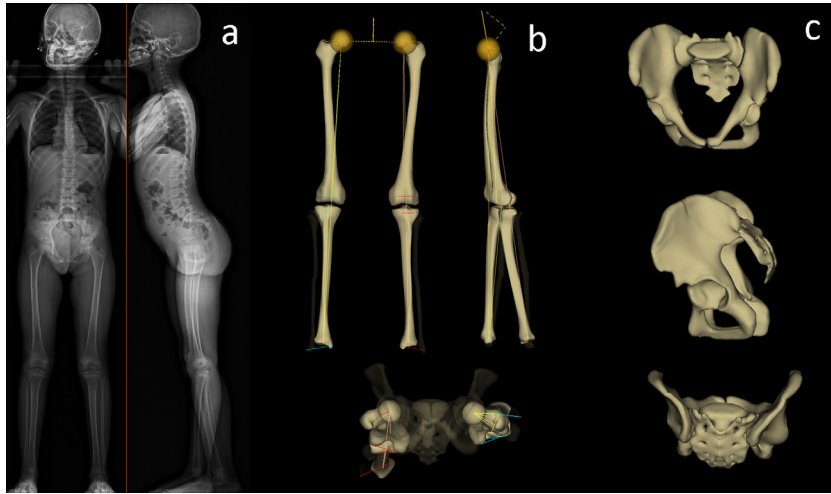


Fig 1. Example of (a) frontal and lateral EOS[®] radiography of a child with cerebral palsy (F, 8 years old) with 3D reconstructions of the lower limbs (b) and the pelvis (c) in coronal, lateral and transverse views.

Table 2
The definition of the acetabular parameters.

Pelvic parameters		Line 1	Line 2
Pelvic Incidence (°)	PI	Sacro-acetabular line (1)	Normal sacral line (2)
Sacral Slope (°)	SS	Horizontal line	The line tangent to the sacral plate
Pelvic Tilt (°)	PT	Vertical line	Sacro-acetabular line
Acetabular parameters		Line 1	Line 2
Acetabular coverage (%) [*]	ACov	Surface of the sphere modeling the acetabulum	Surface of the projection of the acetabulum on the sphere defined in "Line 1"
Sacro-acetabular angle (°)	SA	The line defined by the intersection between the acetabular edge plane (3) and EOS_S plane (4)	The tangent to the sacral plate projected in EOS_S plane
Acetabular tilt (°)	AT	The line defined by the intersection between the acetabular edge plane (3) and EOS_S plane (4)	The postero-anterior axis of the EOS [®] system, passing through the center of the acetabulum
Acetabular inclination (°)	AInc	The line normal to the acetabular edge plane (3) and passing through the center of the acetabulum	The normal to the S plane (5)
Acetabular anteversion (°)	AAnt	The line defined by the intersection between the acetabular edge plane (3) and S plane (5)	The line defined by the intersection between the pelvic sagittal plane (6) and S plane (5)
Lower limb parameters		Line 1	Line 2
Femoral Anteversion (°)	FA	Femoral neck axis	Posterior condylar line
Neck Shaft Angle (°)	NSA	Femoral neck axis	Proximal diaphysis axis
Tibial Torsion (°)	TT	Posterior tibial plates line	Bi-malleolar axis

- (1) Sacro-acetabular line: line joining the center of the acetabulum and the center of the sacral plate.
 - (2) Normal sacral line: the perpendicular to the sacral plate.
 - (3) Acetabular edge plane: is the plane passing through the edge of the acetabulum.
 - (4) EOS_S plane: EOS sagittal plane passing through the acetabular center.
 - (5) S Plane: is the plane parallel to the sacral plate passing through the acetabular center.
 - (6) Pelvic sagittal plane: is a perpendicular plane to the acetabular axis, passing through the centers of both acetabulae.
- ^{*} ACov is a ratio between "line 1" and "line".

A post-hoc power analysis was performed by calculating the effect size of each significant result. Cohen's *d* was calculated when the *t*-test is applied for comparisons between CP and TD populations. Cohen's *f* was applied when the ANOVA test was performed between TD and CP with GMFCS levels I and II [25]. Matlab[®] (The Mathworks, Inc, Natick, MA, USA) and Xlstat[®] (Addinsoft, Paris, France) were used for statistical analysis.

3. Results

3.1. Comparison between TD and CP children

Comparison of age, weight and height (Table 1) between the two groups showed no significant differences ($p=0.355$, $p=0.441$

and $p=0.129$ respectively). Mean values of the radiological parameters for the TD and CP children are reported in Table 3.

The mean value of the pelvic incidence (PI) was significantly increased in the CP population compared to TD ($48^\circ \pm 7^\circ$ vs. $43^\circ \pm 8^\circ$ respectively, $p=0.003$, $d=0.66$). A significantly more vertical sacral plate was found in children with CP compared to the control group ($42^\circ \pm 7^\circ$ vs. $38^\circ \pm 5^\circ$ respectively, $p=0.003$, $d=0.65$). A more anteverted and abducted femoral neck was found in the CP group compared to controls (FA: $25^\circ \pm 12^\circ$ vs. $14^\circ \pm 7^\circ$ respectively, $p<0.001$, $d=1.11$ and NSA: $134^\circ \pm 5^\circ$ vs $131^\circ \pm 5^\circ$ respectively, $p=0.005$, $d=0.6$).

Significantly higher variability was found for the following parameters in children with CP compared to TD children: FA ($p=0.007$), PT ($p=0.002$), and the acetabular tilt angle ($p=0.012$).

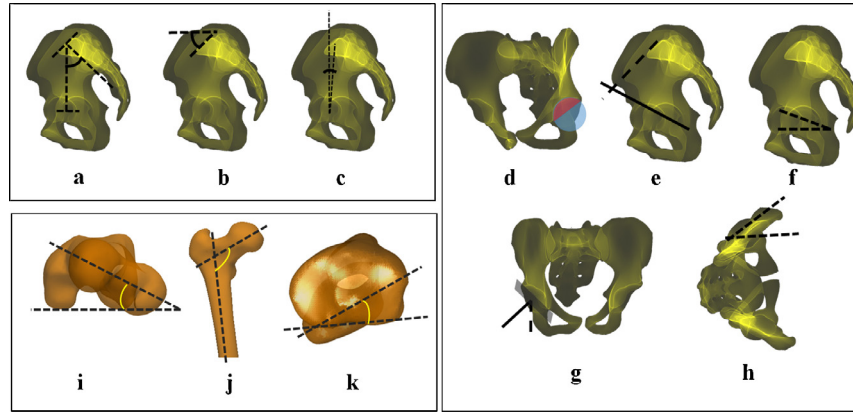


Fig. 2. Illustration of the lower limbs and acetabular parameters.

Pelvic parameters: a) pelvic incidence (PI), b) sacral slope (SS), c) pelvic tilt (PT). Acetabular parameters: d) acetabular coverage (ACov), e) sacro-acetabular angle (SA), f) acetabular tilt (AT), g) acetabular inclination (Alnc), h) Acetabular anteversion (AAnt). Femoral and tibial parameters: i) femoral anteversion (FA), j) neck shaft angle (NSA), k) tibial torsion (TT).

Table 3

3D subject-specific radiological parameters related to the pelvis and lower limbs for the CP and TD children: Pelvic incidence (PI), sacral slope (SS), pelvic tilt (PT), acetabular coverage (ACov), sacro-acetabular angle (SA), acetabular tilt (AT), acetabular inclination (Alnc), acetabular anteversion (AAnt), femoral anteversion (FA), neck shaft angle (NSA), tibial torsion (TT).

	TD children Mean (SD)	CP children Mean (SD)	CP vs TD p value	GMFCS I Mean (SD) p value (GMFCS I vs TD)	GMFCS II Mean (SD) p value (GMFCS II vs TD)
Pelvic parameters					
PI (°)*	43(8)	48(7)	0.003	47(6) 0.020	48(8) 0.033
SS(°)*	38(5)	42(7)	0.003	44(6) 0.001	39(8) 0.983
PT(°)	6(5)	7(10)	0.502	3(8) 0.299	11(10) 0.070
Acetabular parameters					
ACov(%)	42(4)	41(4)	0.177	40(4) 0.153	42(4) 0.999
SA(°)	58(11)	62(12)	0.144	62(11) 0.370	61(14) 0.644
AT(°)	20(9)	21(12)	0.700	17(11) 0.743	26(12) 0.115
Alnc(°)*	72(6)	74(9)	0.062	75(5) 0.092	73(12) 0.175
AAnt (°)	31(4)	32(5)	0.205	33(4) 0.325	31(6) 0.965
Femoral and tibial parameters					
FA(°)*	14(7)	25(12)	p < 0.001	24(13) 0.001	27(11) p < 0.001
NSA(°)*	131(5)	134(5)	0.005	134(6) 0.052	134(5) 0.074
TT(°)	28(6)	28(8)	0.854	27(7) 0.941	29(8) 0.997

3.2. Comparison between TD children and CP children with GMFCS levels I and II

While no differences were noted between the two sub-groups of children with CP and TD children for the acetabular parameters, femoral anteversion was significantly increased in both groups of children with GMFCS levels I and II compared to TD children ($p=0.001$ and $p<0.001$ respectively, $f=0.58$; Table 3). Pelvic incidence was significantly increased in children with GMFCS levels I and II compared to TD children ($p=0.020$ and $p=0.033$ respectively, $f=0.23$). The sacral slope was significantly increased

in children with GMFCS level I compared to the TD group ($p=0.001$, $f=0.26$).

4. Discussion

In this study, a comparison of 3D postural and morphological skeletal parameters of both pelvis and lower limbs, between TD and ambulant children with CP presenting GMFCS levels I and II, was performed using the EOS[®] biplanar X-ray system. The children with CP included in this study had neither medical nor surgical history. This is the first study that calculated the acetabular parameters in CP and TD groups. While no differences were found for the acetabular parameters and tibial torsion, the

pelvic and femoral parameters were significantly different in children with CP.

4.1. TD children

The calculation of lower limb and pelvic parameters in 3D for TD children was recently reported in the literature [18,26,27]; in this study, we had additionally reported acetabular parameters. The presently reported acetabular parameters in TD children could be valuable for better understanding of normal 3D morphology of the acetabulum and hip in the standing position.

The comparison of pelvic parameters with the results found by Szuper et al. [27] is difficult since the authors only reported the mean values for a male population. Our results for PT, SS and PI were comparable to those of Rampal and Gaumetou [18,26], who performed a 3D reconstruction of the pelvis in TD children, using the EOS[®] system. Furthermore, our results were consistent with those of Jacquemier et al. [28], who had established a large database of male and female children, on whom FA and TT were measured clinically.

4.2. CP children

In this study, 3D subject-specific skeletal parameters of the pelvis, acetabulum and lower limbs were calculated in ambulant children with CP (GMFCS levels I and II), presenting no orthopedic history affecting the pelvis, hips or knees. The femoral anteversion (FA) and neck shaft angle (NSA) had been previously evaluated in ambulant children with CP using physical examination and fluoroscopy [2,7]. The mean values of FA and NSA in our population were $25^{\circ} \pm 12^{\circ}$ and $134^{\circ} \pm 5^{\circ}$ respectively, compared to $30^{\circ} \pm 9^{\circ}$ for FA and $139^{\circ} \pm 7^{\circ}$ for NSA in the group of ambulant children of Bobroff's study [7]. Since it is known that the values of FA and NSA decrease during growth [26,29,30], the difference in results for FA could be related to the increased mean age of our population (10.9 ± 4.0 years) compared to Bobroff's population (8.2 ± 2.3 years). Our results for the mean values of FA in children with GMFCS levels I ($24^{\circ} \pm 13$) and II ($27^{\circ} \pm 11$) were inferior to those previously obtained by physical examination [2], where the authors had reported 30° and 36° for children with GMFCS levels I and II respectively. This finding means that physical examination could overestimate the measurement of FA in ambulant children with CP, in comparison with the EOS[®] system. When comparing our results to those obtained by 3D CT scan [6], we found that the values of FA and NSA in our population ($25^{\circ} \pm 12^{\circ}$ and $134^{\circ} \pm 5^{\circ}$ respectively) were inferior to those of Gose's population ($41.7^{\circ} \pm 11.9^{\circ}$ and $146.7^{\circ} \pm 7^{\circ}$), consisting of a group of children with GMFCS levels II and III. This result could be related to the high prevalence of ambulant children with GMFCS level III in Gose's population (N=41/61), which contrasted with the predominance of children with GMFCS level I in our study (N=17/27). In addition to the fact that FA and NSA are correlated to the degree of motor impairment in children with CP [2,7], this difference in results could also be related to the difference in age between the 2 studies (Gose's population: 5.3 years, current study: 10.9 years) [26].

The added value of our results is that the CP population included in this study, aged from 6 to 19 years, had no history of either surgical or medical interventions on their hips or knees, as is common in the literature. The evaluation of such patients would be highly informative of the natural evolution of the musculoskeletal system in ambulant children with CP who are slightly affected. All previous studies on patients with CP [4,7] included subjects who had been previously treated by various techniques. Because of the current advances in the early management of children with CP, it is not often that we can

study the natural history of the evolution of skeletal deformities in children with spastic CP. The absence of previous treatment in our population could be due to the fact that the patients originated from remote areas where access to proper diagnosis and treatment for CP is scarce, or that orthopedic treatment had not been previously required. However, this group is not fully representative of the natural evolution of skeletal deformities in children with CP because of its cross-sectional nature. Since a prospective study is not possible for ethical reasons, our results could be valuable for understanding the progression of this pathology in ambulatory children.

4.3. Comparison between CP and TD children

The current study showed that pelvic incidence (PI) and sacral slope (SS) were significantly increased in children with CP compared to TD children. The difference between the two groups is greater than the previously reported uncertainties for these parameters using the EOS[®] technique [18]. Pelvic tilt and SS are positional parameters of the pelvis and thus reflect dynamic sagittal balance. Therefore, the significant difference in SS (Table 3) reflects a change in the posture of CP children, which should affect their sagittal balance given the important correlation between SS and lumbar lordosis [31]. However, PI is an anatomical parameter, which is only affected by a morphological change in the pelvis. The significant difference between the pathological and control groups for PI suggests a skeletal deformity of the pelvis in the CP group and subgroups (GMFCS levels I and II). Future studies should consider the functional or clinical implications of these abnormalities and whether they must be treated.

Furthermore, femoral anteversion (FA) was significantly increased in ambulant children with CP as well as in children with GMFCS levels I and II, compared to the TD children, which is in accordance with the results of previous studies, where different techniques were used to assess FA [2,7]. The difference found in this study between the two groups is greater than the previously reported uncertainties for these parameters using the EOS[®] technique [16,17]. Typically developing children are born with elevated FA, which later decreases during growth and stabilizes around skeletal maturity [26]. The elevated values of FA in children with CP, compared to the control group, suggest that this normal reduction of FA does not occur at the same rate as for TD children, even in slightly affected children with CP. It was also notable that FA was significantly increased in both groups of children with GMFCS levels I and II when compared to the TD group.

The elevated FA in the CP group is known to be related to spasticity, abnormal motion strategies during growth and delays in achieving independent ambulation, which can lead to skeletal malalignment and lever arm dysfunction [1,5,32]. Moreover, the neck shaft angle (NSA) was significantly increased in the CP population. This could be related to the abnormal motion strategies and weight-bearing on the lower limbs.

There were no significant differences between the CP and TD groups for any of the acetabular parameters. This indicates that major acetabular deformities are not encountered in ambulatory children with CP (GMFCS I and II), at least in our population; however, future studies should assess acetabular parameters in ambulant children with GMFCS level III, which usually present more severe skeletal deformities.

Moreover, no significant differences were found for tibial parameters between the TD and CP groups. This result could indicate that proximal skeletal deformities of the pelvis and femur are more frequently encountered than tibial abnormalities in children with GMFCS levels I and II. However, it is known that abnormal tibial torsion, in the majority of children with CP, is acquired during growth and gradually increases in childhood [28].

Therefore, a prospective study would be necessary to understand the natural history of tibial deformities in ambulant children with CP.

A larger sample size of TD children and ambulant children with CP is required in order to build a database for the calculation of 3D subject-specific musculoskeletal parameters for the pelvis and lower limbs in both populations. Our population is not representative of all types of ambulant children with CP; more precisely, it does not include children with GMFCS level III. This group of children requires assistive devices to walk and usually presents more severe skeletal abnormalities compared to the group of children with GMFCS levels I and II [2]. The absence of this group of children from our study is related to our restricted inclusion criteria, requiring the absence of orthopedic treatment, even on soft tissue, at the levels of the hips and knees.

5. Conclusion

In conclusion, this study showed that even slightly impaired ambulant children with CP present an anteverted and abducted femur. The orientation of the acetabulum and the tibial torsion were not found to be affected; however morphological and postural changes at the pelvis in the sagittal plane were noted. The low dose biplanar X-ray technique could be routinely used in daily practice in order to assess in 3D pelvic and lower limb deformities in children with CP. The quantification of these subject-specific skeletal malalignments related to both posture and morphology, when combined with gait analysis, would be of paramount importance in order to understand to which extent they alter the walking pattern of each patient.

Acknowledgments

This study was funded by the research council of the University of Saint-Joseph (grant FM244) and the CEDRE Project (grant 11SCIF44/L36). Both institutions did not interfere in any part of this study.

Conflict of interest

None.

References

- [1] J.R. Gage, T.F. Novacheck, An update on the treatment of gait problems in cerebral palsy, *J. Pediatr. Orthop. Part B* 10 (2001) 265–274, doi:<http://dx.doi.org/10.1097/01202412-200110040-00001>.
- [2] J. Robin, H.K. Graham, P. Selber, F. Dobson, K. Smith, R. Baker, Proximal femoral geometry in cerebral palsy: a population-based cross-sectional study, *J. Bone Joint Surg. Br.* 90 (2008) 1372–1379, doi:<http://dx.doi.org/10.1302/0301-620X.90B10.20733>.
- [3] S. Aktas, M.D. Aiona, M. Orendurff, Evaluation of rotational gait abnormality in the patients cerebral palsy, *J. Pediatr. Orthop.* 20 (2000) 217–220, doi:<http://dx.doi.org/10.1097/01241398-200003000-00016>.
- [4] F. Miller, Y. Liang, M. Merlo, H.T. Harcke, Measuring anteversion and femoral neck-shaft angle in cerebral palsy, *Dev. Med. Child Neurol.* 39 (1997) 113–118.
- [5] G. Chan, F. Miller, Assessment and treatment of children with cerebral palsy, *Orthop. Clin. North Am.* 45 (2014) 313–325, doi:<http://dx.doi.org/10.1016/j.ocl.2014.03.003>.
- [6] S. Gose, T. Sakai, T. Shibata, T. Murase, H. Yoshikawa, K. Sugamoto, Morphometric analysis of the femur in cerebral palsy: 3-dimensional CT study, *J. Pediatr. Orthop.* 30 (2010) 568–574, doi:<http://dx.doi.org/10.1097/BPO.0b013e3181e4f38d>.
- [7] E.D. Bobroff, H.G. Chambers, D.J. Sartoris, M.P. Wyatt, D.H. Sutherland, Femoral anteversion and neck shaft angle in children with cerebral palsy, *Clin. Orthop. Relat. Res.* (1999) 194–204.
- [8] T. Terjesen, The natural history of hip development in cerebral palsy, *Dev. Med. Child Neurol.* 54 (2012) 951–957, doi:<http://dx.doi.org/10.1111/j.1469-8749.2012.04385.x>.
- [9] A. Connelly, P. Flett, H.K. Graham, J. Oates, Hip surveillance in Tasmanian children with cerebral palsy, *J. Paediatr. Child Health* 45 (2009) 437–443, doi:<http://dx.doi.org/10.1111/j.1440-1754.2009.01534.x>.
- [10] J.R. Davids, A.D. Marshall, E.R. Blocker, S.L. Frick, D.W. Blackhurst, E. Skewes, Femoral anteversion in children with cerebral palsy, *J. Bone Joint Surg.* 85 (2003) 481–488.
- [11] E. Viehweger, C. Bérard, A. Berruyer, M.C. Simeoni, Bilan articulaire des membres inférieurs d'un enfant atteint d'une infirmité motrice cérébrale, *Annales de Readaptation et de Médecine Physique* 50 (2007) 258–265, doi:<http://dx.doi.org/10.1016/j.annrmp.2007.02.004>.
- [12] M. Wynter, N. Gibson, M. Kentish, S. Love, P.K.G.H. Thomason, The Consensus Statement on Hip Surveillance for Children with Cerebral Palsy: Australian Standards of Care, *J. Pediatr. Rehabil. Med.* 4 (2011) 183–195.
- [13] J.R. Davids, Identification of common gait disruption patterns in children with cerebral palsy, *J. Am. Acad. Orthop. Surg.* 22 (2014) 782–790.
- [14] C. Delin, S. Silvera, C. Bassinet, P. Thelen, J.L. Rehel, P. Legmann, et al., Ionizing radiation doses during lower limb torsion and anteversion measurements by EOS stereoradiography and computed tomography, *Eur. J. Radiol.* 83 (2014) 371–377, doi:<http://dx.doi.org/10.1016/j.ejrad.2013.10.026>.
- [15] Y. Chaibi, T. Cresson, B. Aubert, J. Hausselle, P. Neyret, O. Hauger, et al., Fast 3D reconstruction of the lower limb using a parametric model and statistical inferences and clinical measurements calculation from biplanar X-rays, *Comput. Methods Biomech. Biomed. Eng.* 15 (2012) 457–466, doi:<http://dx.doi.org/10.1080/10255842.2010.540758>.
- [16] A. Assi, Y. Chaibi, A. Presedo, J. Dubouset, I. Ghanem, W. Skalli, Three-dimensional reconstructions for asymptomatic and cerebral palsy children's lower limbs using a biplanar X-ray system: a feasibility study, *Eur. J. Radiol.* 82 (2013) 2359–2364, doi:<http://dx.doi.org/10.1016/j.ejrad.2013.07.006>.
- [17] M. Thépaut, S. Brochard, J. Leboucher, M. Lempereur, E. Stindel, V. Tissot, et al., Measuring physiological and pathological femoral anteversion using a biplanar low-dose X-ray system: validity, reliability, and discriminative ability in cerebral palsy, *Skeletal Radiol.* 45 (2016) 243–250, doi:<http://dx.doi.org/10.1007/s00256-015-2298-y>.
- [18] V. Rampal, J. Hausselle, P. Thoreux, P. Wicart, W. Skalli, Three-dimensional morphologic study of the child's hip: which parameters are reproducible? *Clin. Orthop. Relat. Res.* 471 (2013) 1343–1348, doi:<http://dx.doi.org/10.1007/s11999-012-2660-5>.
- [19] R.J. Palisano, P. Rosenbaum, D. Bartlett, M.H. Livingston, Content validity of the expanded and revised Gross Motor Function Classification System, *Dev. Med. Child Neurol.* 50 (2008) 744–750, doi:<http://dx.doi.org/10.1111/j.1469-8749.2008.03089.x>.
- [20] J.S. Steffen, I. Obeid, N. Aurouer, O. Hauger, J.M. Vital, J. Dubouset, et al., 3D postural balance with regard to gravity line: an evaluation in the transversal plane on 93 patients and 23 asymptomatic volunteers, *Eur. Spine J.* 19 (2010) 760–767, doi:<http://dx.doi.org/10.1007/s00586-009-1249-5>.
- [21] D. Mitton, S. Deschenes, S. Laporte, B. Godbout, S. Bertrand, J.A. De Guise, W. Skalli, 3D reconstruction of the pelvis from bi-planar radiography, *Comput. Methods Biomech. Biomed. Eng.* 9 (2006) 1–5.
- [22] D.W. Murray, The definition and measurement of acetabular orientation, *J. Bone Joint Surg. Br.* 75 (1993) 228–232.
- [23] E.S. Stem, M.I. O'Connor, M.J. Kransdorf, J. Crook, Computed tomography analysis of acetabular anteversion and abduction, *Skeletal Radiol.* 35 (2006) 385–389.
- [24] J.Y. Lazennec, N. Charlot, M. Gorin, B. Roger, N. Arafati, A. Bissery, et al., Hip-spine relationship: a radio-anatomical study for optimization in acetabular cup positioning, *Surg. Radiol. Anat.* 26 (2004) 136–144, doi:<http://dx.doi.org/10.1007/s00276-003-0195-x>.
- [25] Jacob Cohen, *Statistical Power Analysis for the Behavioral Sciences*, 2nd ed., Lawrence Erlbaum Associates, United States of America, 1988.
- [26] E. Gaumétou, S. Quijano, B. Ilharborde, A. Presedo, P. Thoreux, K. Mazda, et al., EOS analysis of lower extremity segmental torsion in children and young adults, *Orthop. Traumatol.* 100 (2014) 147–151, doi:<http://dx.doi.org/10.1016/j.otsr.2013.09.010>.
- [27] K. Szuper, A.T. Schégl, E. Leidecker, C. Vermes, S. Somoskeöy, P. Than, Three-dimensional quantitative analysis of the proximal femur and the pelvis in children and adolescents using an upright biplanar slot-scanning X-ray system, *Pediatr. Radiol.* 45 (2015) 411–421, doi:<http://dx.doi.org/10.1007/s00247-014-3146-2>.
- [28] M. Jacquemier, Y. Glard, V. Pomeroy, E. Viehweger, J.-L. Jouve, G. Bollini, Rotational profile of the lower limb in 1319 healthy children, *Gait Posture* 28 (2008) 187–193, doi:<http://dx.doi.org/10.1016/j.gaitpost.2007.11.011>.
- [29] S.S. Upadhyay, R.G. Burwell, A. Moulton, P.G. Small, W.A. Wallace, Femoral anteversion in healthy children. Application of a new method using ultrasound, *J. Anat.* 169 (1990) 49–61.
- [30] A.R. Shands Jr, M.K. Steele, Torsion of the femur; a follow-up report on the use of the Dunlap method for its determination, *J. Bone Joint Surg. Am.* 40-A (1958) 803–816.
- [31] R. Vialle, Radiographic analysis of the sagittal alignment and balance of the spine in asymptomatic subjects, *J. Bone Joint Surg. (American)* 87 (2005) 260, doi:<http://dx.doi.org/10.2106/JBJS.D.02043>.
- [32] T.F. Novacheck, J.R. Gage, Orthopedic management of spasticity in cerebral palsy, *Child's Nerv. Syst.* 23 (2007) 1015–1031, doi:<http://dx.doi.org/10.1007/s00381-007-0378-6>.