



Science Arts & Métiers (SAM)

is an open access repository that collects the work of Arts et Métiers Institute of Technology researchers and makes it freely available over the web where possible.

This is an author-deposited version published in: <https://sam.ensam.eu>
Handle ID: <http://hdl.handle.net/10985/18116>

To cite this version :

Jean-Yves LAZENNEC, Adrien BRUSSON, Dominique FOLINAIS, A ZHANG, Aidin Eslam POUR, Marc-Antoine ROUSSEAU - Measuring extension of the lumbar-pelvic-femoral complex with the EOS® system. - European Journal of Orthopaedic Surgery & Traumatology - Vol. 25, p.1061-1068 - 2015

Any correspondence concerning this service should be sent to the repository

Administrator : scienceouverte@ensam.eu



Measuring extension of the lumbar–pelvic–femoral complex with the EOS[®] system

J. Y. Lazennec · A. Brusson · D. Folinais ·
A. Zhang · A. E. Pour · M. A. Rousseau

Abstract

Introduction Sagittal balance of the coxofemoral joint in standing position and its extension capacity determine hip/spine adaptation, especially in relation to pelvic retroversion, which may be age-associated or follow either spinal arthrodesis or vertebral osteotomies. The concept of extension reserve is essential for assessing posterior hip impingement. The global visualization of the lumbar–pelvic–femoral complex obtained by EOS[®] imaging enables this sagittal analysis of both the subpelvic region and lumbar spine by combining the reference standing position and the possibility of dynamic tests.

Materials and methods We studied 46 patients and their 92 hips. The EOS[®] radiography was performed in neu-

tral standing position and with one foot on a step, alternately the right and left feet. Pelvic incidence, sacral slope, pelvic version, and femoral version were measured twice by two operators. The global extension reserve (GER) was defined by the sum of the intrinsic extension reserve (allowed by the hips, IER) and the extrinsic extension reserve (allowed by the spine, EER). The IER for each hip corresponds to the difference in the sacro-femoral angle (SFA) for each of the two positions. The EER was measured by the difference in the sacral slope. A descriptive study was performed, together with studies of inter- and intra-observer reproducibility, right/left symmetry, and an analysis according to age, sex, and BMI.

Results The mean femoral version in the reference position was 11.7° (SD 14.3°). The reproducibility of the SFA measurement was statistically verified. The IER (mean 8.8°), EER (mean –0.7°), and GER (mean 8.2°) all differed significantly between the two sides for each patient and were not associated with age, sex, or BMI.

Discussion The femoral axis is not perpendicular to the ground in neutral position, contrary to the conventional view of this position. The measurements proposed for dynamic sagittal analysis of the hip are reproducible and make it possible to identify the IER within the GER of the spinal–pelvic–femoral complex.

Conclusion The assessment of the lumbar–pelvic–femoral complex by EOS imaging makes it possible to define the intrinsic and extrinsic extension reserves to describe the reciprocal adaptive capacities of the hips and spine.

Level of evidence IV.

Keywords Hip · EOS · Extension · Femoral version · Lumbar–pelvic–femoral complex · Sagittal balance

J. Y. Lazennec · A. Brusson · A. Zhang
Service de Chirurgie Orthopédique et Traumatologie de l'hôpital
Pitié-Salpêtrière, Assistance Publique – Hôpitaux de Paris,
47 bd de l'hôpital, 75013 Paris, France
e-mail: lazennec.jy@wanadoo.fr

J. Y. Lazennec · M. A. Rousseau (✉)
Laboratoire de Biomécanique, Arts et Métiers Paristech,
151 bd de l'hôpital, 75013 Paris, France
e-mail: marc-antoine.rousseau@avc.aphp.fr

D. Folinais
Service d'Imagerie Médicale, Clinique Maussins-Nollet,
67 rue de Romainville, 75019 Paris, France

A. E. Pour
Department of Orthopedics, University of Michigan,
1500 E. Medical Center Drive, Ann Arbor, MI 48109, USA

M. A. Rousseau
Service de Chirurgie Orthopédique et Traumatologie de l'hôpital
Avicenne, Assistance Publique – Hôpitaux de Paris,
125 rue de Stalingrad, 93000 Bobigny, France

Introduction

Sagittal balance in standing position is an essential element that spine surgeons must analyze today as they begin to integrate the subpelvic region into their postural assessments [1–3]. More recently, hip surgeons have examined this concept both for planning total hip replacements (THR) and for examining problems of instability in studies focused on the pelvis or the hip in functional positions and considering the sacroacetabular angle, functional acetabular anteversion, and the mobility cone [4–9]. It now appears clear that the sagittal balance of the spine and that of the hips is interlinked, as evidenced by the repercussions on coxofemoral biomechanics of lumbosacral arthrodesis or of the age-related spinal stiffening accompanying pelvic retroversion [10–12].

Until now, sagittal analysis has been segmented because of technical constraints: It was not possible to obtain complete and simultaneous visualization of the spine and lower limbs in patients of adult size [13]. In 1997, Mangione and Senegas [14] introduced the concept of pelvic–femoral angle to describe the sagittal balance of the subpelvic region. This was the angle between the midpoint of the sacral plate, the center of the femoral heads, and the femoral axis; the femoral axis was defined by the line joining two points along the central diaphysis (one at the lesser trochanter and another 10 cm lower). This was a static visualization while balanced and not an assessment of the hip’s extension capacity, strictly speaking. Hovorka et al. [15] went back to the concept of measuring the pelvic–femoral angle from conventional radiographic standing and dynamic images. The landmarks were approximately the same. The same difficulties were encountered for determining the femoral axis, which was defined this time by the line between the summit of the greater trochanter and the midpoint of the femoral diaphysis in the most distal portion of the image. To measure the extension reserve, patients were asked to assume the position of maximum extension—a lunge. Radiologic examination in this position made it possible to measure the extension reserve for each hip; the mean values reported ranged from $15.9 \pm 6.57^\circ$ to $10 \pm 7.89^\circ$.

By enabling the acquisition of high-definition images of the complete subject in a standing position, the development of the EOS[®] system has opened new perspectives for a global representation [16]. It was recently shown that the measurement of pelvic and acetabular indicators is as reliable with EOS[®] as with conventional radiology while providing less irradiation [11], but that study was limited to the lumbar–pelvic complex; it explored the acetabular side of the hip and did not consider the femoral component.

The principal objective of our work was to validate a new method for analyzing the sagittal balance of the hip

by EOS imaging and assess its inter- and intra-observer concordance for the pelvic–femoral region. Our secondary objective was to measure separately the coxofemoral and lumbosacral components of this global extension reserve (GER) of the spinal–pelvic–femoral complex.

Materials and methods

Population

In 2010 and 2011, EOS radiographs were taken of 46 patients (that is, 92 hips) who had no spinal or coxofemoral disease: 35 women (76 %) and 11 men (24 %), with a mean age of 54 ± 14 years (range 22–80). Mean body mass index (BMI) was 26 ± 1.5 (range 23–29). The EOS whole-body acquisitions enabled us to confirm the absence of radiologic spinal or coxofemoral damage.

Radiologic acquisitions

For the lateral radiography, the reference position was the most comfortable position while looking straightforward, with elbows flexed to approximately 45° [17]. After the reference images with feet together, two dynamic acquisitions were taken, with one foot, and then the other placed on a 25-cm step placed in front of the subject (Fig. 1). The



Fig. 1 Picture of the patient in extension in the EOS cabin with a 25-cm step

extension for each patient in the right and the left hip was thus studied.

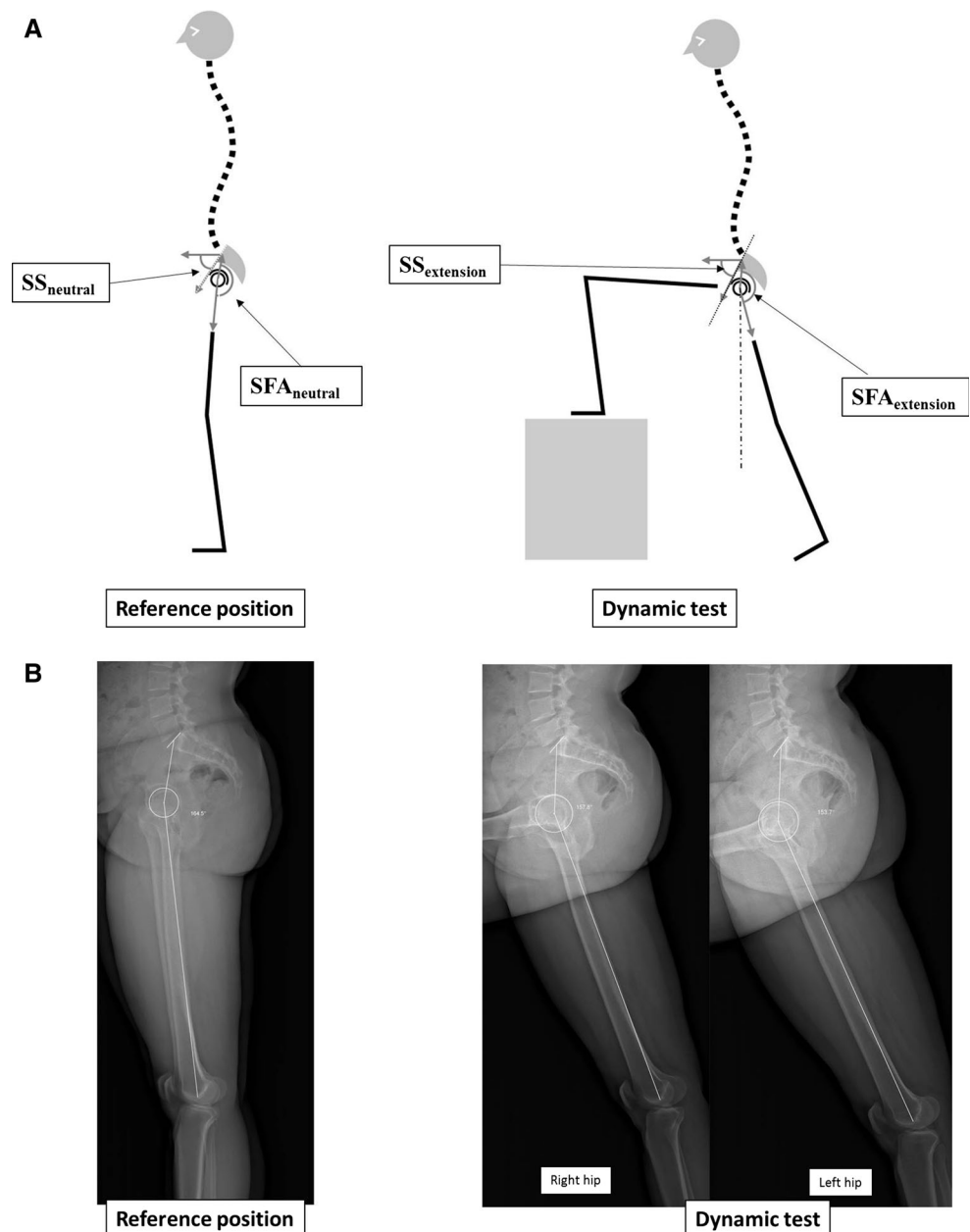
Indicators studied (Figs. 2, 3)

The indicators were measured for each hip in both neutral and extended positions on the dedicated imaging console (SterEOS 2D software) twice by two independent operators:

- Pelvic incidence (PI) [18]
- Sacral slope (SS) [18]
- Calculation of pelvic tilt (PT) according to Legaye’s formula [18]: $PT = PI - SS$

Fig. 2 Diagram representing the neutral standing position and the dynamic position in extension (a contralateral step of 25 cm) to study the sagittal balance and extension reserved of the lumbar–pelvic–femoral complex. The extrinsic extension reserve: $EER = SS_{extension} - SS_{neutral}$. In this example, the increase in the sacral slope during the test demonstrates additional extension reserve obtained by rocking the lumbopelvic bloc. The intrinsic extension reserve: $IER = SFA_{neutral} - SFA_{extension}$. The reduction of the SFA during the test indicates the presence of extension reserve of the hip

- Sacrofemoral angle (SFA) (Fig. 3). The SFA was defined as the angle between the line joining the center of the femoral head and the midpoint of the sacral plate and the line joining the center of the femoral head at the roof of the intercondylar notch (anterior end of Blumensaat’s line).
- *Calculation of femoral tilt* Femoral tilt is defined as the angle between the vertical axis through the femoral head and the line joining this point to the roof of the intercondylar notch. It therefore has a negative value when the femoral axis projects forward in front of the vertical axis through the femoral head (hip flexion contracture). In the inverse case, a positive value corresponds to extension of the hip [9]. We use the fact that femoral sagittal version (FT) + PT + SFA = 180°.



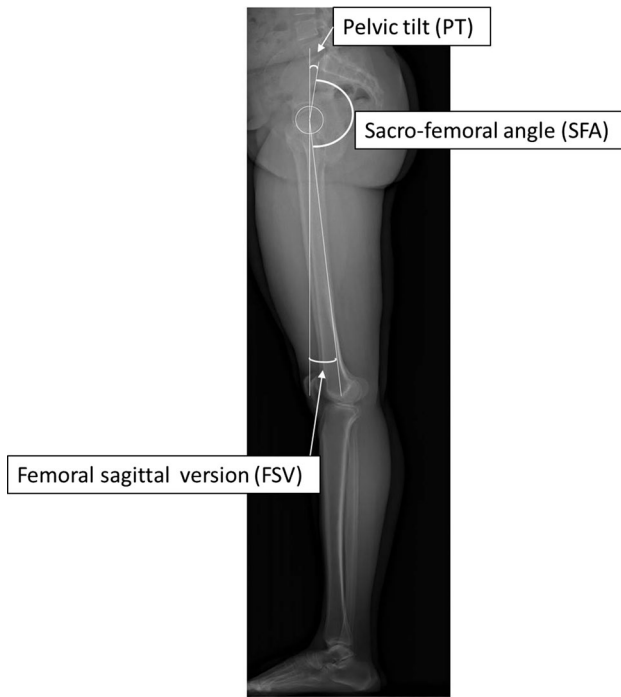


Fig. 3 Measurement of the sacro-femoral angle and relation to pelvic and femoral version

To analyze the relative roles of the spine and the hip in adaptation to extension, the components of extension reserve were defined as follows (Figs. 4, 5):

- The IER, that is, the extension reserve of the hip, is defined by the difference between the value of the SFA in the reference position and that of the SFA with the contralateral foot on the step, according to the following equation: $IER = SFA_{extended} - SFA_{neutral}$. Accordingly, reduction of the SFA during the test indicates the presence of extension reserve of the hip.
- The extrinsic extension reserve (EER) or extension reserve of the lumbosacral spine, on the other hand, is defined by the difference between the value of the sacral slope with the contralateral foot on the step and the sacral slope in reference position, according to the following equation: $EER = SS_{extended} - SS_{neutral}$. Accordingly, the increase in the sacral slope during the test demonstrates supplementary extension reserve obtained by rocking the lumbopelvic bloc.
- The GER is the sum of the two extension reserves: $GER = IER + EER$.

Analyses

The data were treated with SPSS software, version 20. The quantitative variables were described by their means, standard deviations, and ranges (min and max) for both the

neutral and extension positions. Normality was studied with Levène's test. Repeatability (intra-observer) and reproducibility (inter-observer) of indicators in the lumbopelvic region have already been reported in other series [8]. Those for indicators for the pelvic–femoral region were studied here according to the NF ISO 5725-2 standard [19] from measurements of the $SFA_{neutral}$ and $SFA_{extension}$, and the 95 % confidence intervals of the inter- and intra-observer reproducibility were calculated. For a better analysis of repeatability and reproducibility, we calculated the intra- and inter-observer intra-class correlation coefficients (ICC) and their 95 % confidence intervals. Remember that the ICC is defined as the relation between the “explained” variance (variance attributable to the source of variation, that is, the observer factor and the repetition of the measurement) and the total variance (the “explained” variance + the error variance) [20]. A new variable defined as the absolute value of the difference in the value between the two hips of the same subject was used to study the symmetry between right and left hips. The relations between extension reserve (intrinsic, extrinsic, and global) and age and BMI were studied by Pearson's method and that between extension reserve and sex by logistic regression.

Assessment of delivered dose

The mean dose measurements were assessed by the kerma method (kinetic energy released in matter, that is, per unit of mass) [20, 21]. The irradiation dose delivered to the surface was recorded for each acquisition by the EOS[®] machine. As these data do not take into account the X-rays dispersed by the patient, we estimated and added the radiation backscattered by the patient to the calculation of kerma or absorbed dose to air (DAP), in accordance with the rules defined in earlier studies [21, 22].

Results

Descriptive statistics of the indicators studied

Table 1 summarizes the descriptive radiologic results for the 92 hips. The mean GER was 8.2° for femoral version of 11.7° in neutral position. We note that the IER accounts for 63.5 % and the EER 36.5 % of the GER.

Analysis of the intra- and inter-observer reproducibility

The reproducibility of the SFA was assessed for both the neutral and extension positions (Table 2). We observed no significant differences between these repetitions and found a high intra-class coefficient.

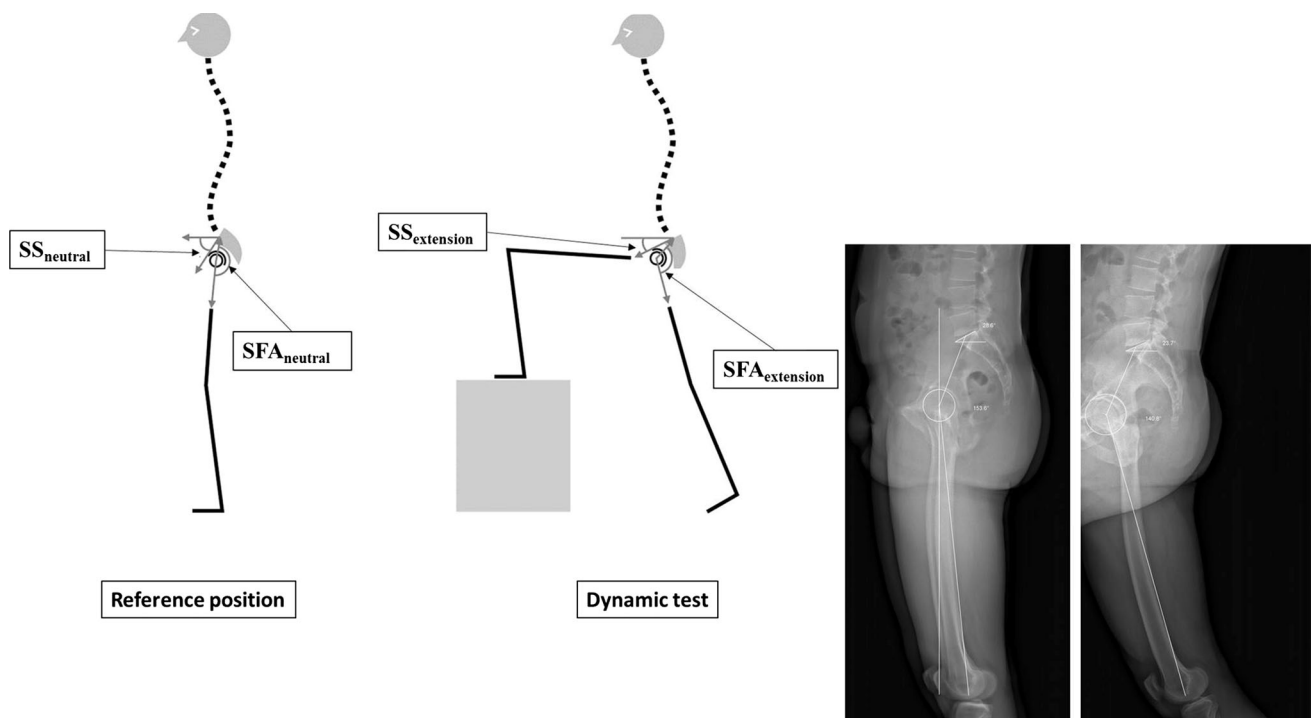


Fig. 4 Example of the calculation of the intrinsic, extrinsic, and global extension reserve of a native hip. In this case, the decrease in the sacral slope during the test (5°) demonstrates a reduction of the extension reserve due to pelvic posterior tilt (pelvic retroversion). The

intrinsic extension reserve $IER = SFA_{extension} - SFA_{neutral}$. The reduction of the SFA during the test indicates the presence of extension reserve of the hip ($154^\circ - 141^\circ = 13^\circ$). The global extension reserve (GER) is $13^\circ - 5^\circ = 8^\circ$

Analysis of the right/left symmetry of the extension reserve

The mean difference between the two sides was 11.5° for the IER, 6.6° for the EER, and 11.6° for the GER; this difference was significantly different from zero in all three cases ($p < 0.001$).

Analysis of the influence of age, sex, and BMI on the extension reserve

There was no significant linear relation between age and IER ($r = -0.168$; $p = 0.110$), EER ($r = 0.089$; $p = 0.394$), or GER ($r = -0.095$; $p = 0.366$). Nor was there any significant linear relation between BMI and IER ($r = -0.019$; $p = 0.864$), EER ($r = 0.280$; $p = 0.007$), or GER ($r = -0.1795$; $p = 0.087$). Finally, there was no significant linear relation between sex and IER ($r = -0.001$; $p = 0.955$), EER ($r = 0.008$; $p = 0.781$), or GER ($r = -0.002$; $p = 0.908$).

Doses delivered

The mean dose (DAP) delivered for the acquisition of the three images (reference standing position + dynamic right and left hip images) was 0.33 mGy ($SD = 0.09$).

Discussion

This study used the EOS system to assess the femoral version and extension reserve of the hips. Our description distinguishes the pelvic–femoral adaptation (intrinsic extension reserve) from lumbopelvic adjustment (EER). We have shown that these measurements are reproducible. The values show a moderate but statistically significant asymmetry between the two hips of the same person. Age, sex, and BMI were not correlated with IER, EER, or CER.

Few studies have addressed the subject of the sagittal balance of the hip in standing position [21]. Until now, research work has been limited by problems of the quality of image acquisition and the difficulty in visualizing the lower limbs as a whole. The measurements that we propose are based on EOS[®] acquisitions at lower doses of irradiation that also provide a complete vision of the spine and lower limbs; it is possible to determine the femoral axis from a construction that is simple to implement by using the center of the femoral head of the hip under study and the summit of Blumensaat's line of the ipsilateral knee. It appears from the start that the measurement of the pelvic–femoral angle described in the literature [14, 15] is not comparable to that of the SFA that we use. We have shown here that the measurement we propose is reproducible. Inversely, no earlier publications report any information

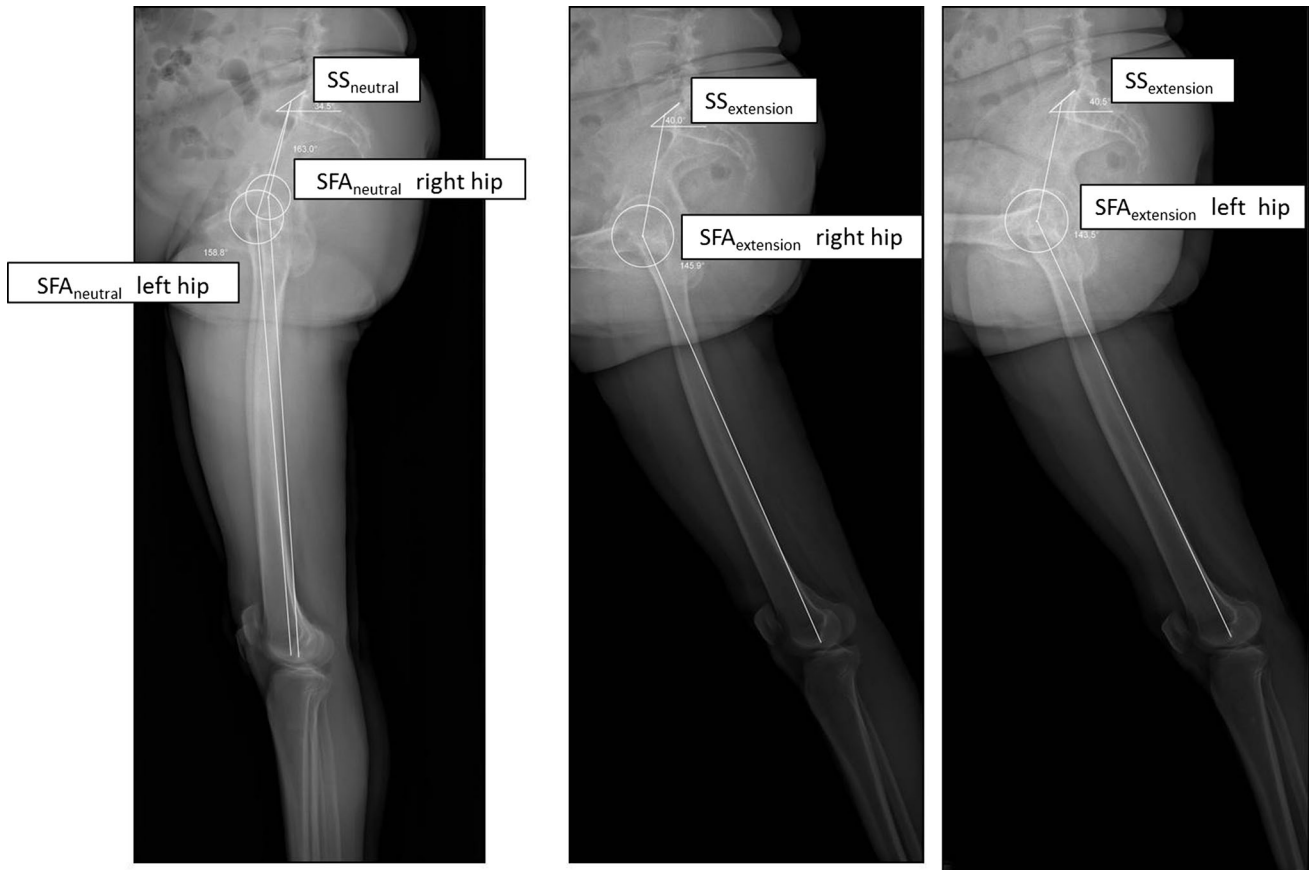


Fig. 5 In this case, we can observe a 6° increase for sacral slope (SS). The extrinsic extension reserve (EER) is 6° . For the right hip, SFA variation is $163^\circ - 146^\circ = 17^\circ$ (IER 17°) and for the left hip 16°

(IER 16°). The global extension reserve (GER) is $17^\circ + 6^\circ = 23^\circ$ for the right side and $16^\circ + 6^\circ = 22^\circ$ for the left side

about the inter- and intra-observer reproducibility of their measures.

In the static image, our study in neutral standing position shows that the femoral axis is not perpendicular to the ground in the neutral reference position, that is, that there is neither flexion forward nor extension backward, contrary to the conventional and intuitive concept of this position.

The very limited data from the literature about dynamic motion imaging are difficult to compare with the values observed in our study for different methodological reasons. Beyond the contribution of the EOS system to the measurement of the femoral axis discussed above, the test that we used with a calibrated step is not directly comparable to the lunge technique described by earlier authors. That is, the fencing position called a lunge combines with hip extension an external rotation in the coxofemoral joint and also involves the ankle. We chose to use a calibrated step because it seemed more practical to use, especially for older subjects or in the case of major disorders of postural imbalance. Finally, the radiologic studies of Mangione and Hovorka included patients with various diseases, while our series included only healthy subjects. The results that we

report here for the IER are nonetheless consistent with these studies [14, 15]. The other publications are based essentially on optoelectronic studies while walking [22, 23]. The distinction between IER and EER is part of an original description made possible by the overall view enabled by the EOS system. This was not done in the current study, but it would be interesting to use the 3D reconstruction of the pelvis for assessing the possible impact of the change of posture between neutral and standing with one leg on the step with the axial rotation of the pelvis.

Unlike older studies that reported a loss of extension with age for the subpelvic region [24, 25], we did not observe a linear correlation between the different components of extension reserve and age, sex, or BMI, but this result might be associated with its small number of subjects.

Conclusion

EOS 2D imaging allows a global assessment of a standing patient and enables us to envision a new approach to

Table 1 Descriptive statistics

Radiologic parameters	Hips ($n = 92$)				
	Mean	SD	Min	Max	p value (from normal distribution)
PI	55	11	35	81	0.216
PT _{neutral}	18.3	8.7	0	37	0.353
PT _{extended}	18.1	9	33	79	0.334
FT _{neutral}	11.7	14.3	-28	49.2	0.266
FT _{extended}	11.2	13.9	-29	48	0.256
SS _{neutral}	37.6	10.7	12.5	59.3	0.932
SS _{extended}	36.9	11.7	12.5	67	0.967
SFA _{neutral}	159.5	10.9	132	183	0.918
SFA _{extended}	150.7	15.8	103	194	0.409
IER	8.82	11.6	-23.7	47	0.241
EER	-0.65	7.7	-24	16	0.462
GER	8.16	13.2	-30	33	0.057
IER (% of GER)	63.5	24	0	100	NA
EER (% of GER)	36.5	24	0	100	NA

NA, nonapplicable; PI, pelvic incidence; PT_{neutral}, pelvic tilt in neutral position (standing); PT_{extended}, pelvic tilt in extended position (the contralateral foot on the step); FT_{neutral}, femoral tilt in neutral position (standing); FT_{extended}, femoral tilt in extended position (the contralateral foot on the step); SS_{neutral}, sacral slope in neutral position (standing); SS_{extended}, sacral slope in extended position (the contralateral foot on the step); SFA_{neutral}, sacrofemoral angle in neutral position (standing); SFA_{extended}, sacrofemoral angle in extended position (the contralateral foot on the step); IER, intrinsic extension reserve; EER, extrinsic extension reserve; GER, global extension reserve)

Relationships:

$$\text{SFA} = 180^\circ - \text{PT} - |\text{FT}|$$

$$\text{IER} = \text{SFA}_{\text{extended}} - \text{SFA}_{\text{neutral}}$$

$$\text{EER} = \text{SS}_{\text{extended}} - \text{SS}_{\text{neutral}}$$

$$\text{GER} = \text{IER} + \text{EER}$$

Table 2 Intra- and inter-observer reproducibility of the sacrofemoral angle (SFA)

	Intra-observer reproducibility					Inter-observer reproducibility				
	d	2SD	ICC	IC 95 %	p value	d	2SD	ICC	IC 95 %	p value
<i>Hips (n = 92)</i>										
SFA _{neutral}	0.16	3.5	0.990	0.983/0.992	0.525	-0.14	3.8	0.956	0.930/0.982	0.325
SFA _{extended}	0.15	3.4	0.997	0.995/0.997	0.960	-0.10	3.8	0.966	0.946/0.986	0.826

d , Mean difference between the two measurements; 2 SD, two times the standard deviation of d ; p value (ANOVA 1); ICC, intra-class correlation coefficient; 95 % CI, 95 % confidence interval of the ICC; SFA_{neutral}, sacrofemoral angle in neutral position (standing); SFA_{extended}, sacrofemoral angle in extended position (the contralateral foot on the step)

postural disorders that affect the spine and the subpelvic region simultaneously. This technology, which is less irradiating than conventional radiology, acquires images of excellent quality that make it possible to take reliable measurements of angles, as shown by the assessments of their repeatability and reproducibility. These measures allow a rigorous description of the conditions of spinal–pelvic–femoral balance or imbalance.

Despite the acquisition by a digital scanner, the short duration of the acquisition of the lateral images allows us to

conceive an individualized functional test of the extension reserve of each joint, with or without a prosthesis. The observations drawn from this study allow us to envision screening patients at risk of posterior impingement in cases of total hip replacement when the sagittal balance is disturbed, especially among aging subjects [11]. Reciprocally, the study of the extension reserve can be a simple and objective means of assessing the impact of surgery for sagittal correction of the spine and tolerance limitations of the subpelvic regions [3, 8, 26].

Conflict of interest The authors report no conflicts of interest in relation to this article.

References

1. Roussouly P, Pinheiro-Franco JL (2011) Biomechanical analysis of the spino-pelvic organization and adaptation in pathology. *Eur Spine J* 20(Suppl 5):609–618
2. Le Huec JC, Leijssen P, Duarte M, Aunoble S (2011) Thoracolumbar imbalance analysis for osteotomy planification using a new method: FBI technique. *Eur Spine J* 20(Suppl 5):669–680
3. Lazennec JY, Saillant G, Saidi K, Arafati N, Barabas D, Benazet JP, Laville C, Roy-Camille R, Ramare S (1997) Surgery of the deformities in ankylosing spondylitis: our experience of lumbar osteotomies in 31 patients. *Eur Spine J* 6:222–232
4. Lazennec JY, Charlot N, Gorin M, Roger B, Arafati N, Bissery A, Saillant G (2004) Hip–spine relationship: a radio-anatomical study for optimization in acetabular cup positioning. *Surg Radiol Anat* 26:136–144
5. Legaye J (2009) Influence of the sagittal balance of the spine on the anterior pelvic plane and on the acetabular orientation. *Int Orthop* 33:1695–1700
6. Rousseau MA, Lazennec JY, Boyer P, Mora N, Gorin M, Catonne Y (2009) Optimization of total hip arthroplasty implantation: is the anterior pelvic plane concept valid? *J Arthroplasty* 24:22–26
7. Laffargue P, Pinoit Y, Tabutin J, Giraud F, Puget J, Migaud H (2006) Computer-assisted positioning of the acetabular cup for total hip arthroplasty based on joint kinematics without prior imaging: preliminary results with computed tomographic assessment. *Rev Chir Orthop Reparatrice Appar Mot* 92:316–325
8. Lazennec JY, Brusson A, Rousseau MA (2013) Lumbar–pelvic–femoral balance on sitting and standing lateral radiographs. *Orthop Traumatol Surg Res* 99:S87–S103
9. Lazennec JY, Brusson A, Rousseau MA (2012) THA patients in standing and sitting positions: a prospective evaluation using the low-Dose “Full-Body” EOS® imaging system. *Semin Arthroplasty* 23:220–225
10. Barrey C, Roussouly P, Le Huec JC, D’Acunzi G, Perrin G (2013) Compensatory mechanisms contributing to keep the sagittal balance of the spine. *Eur Spine J* 22(Suppl 6):S834–S841
11. Lazennec JY, Brusson A, Rousseau MA (2011) Hip–spine relations and sagittal balance clinical consequences. *Eur Spine J* 20(Suppl 5):686–698
12. Lazennec JY, Riwan A, Gravez F, Rousseau MA, Mora N, Gorin M, Lasne A, Catonne Y, Saillant G (2007) Hip spine relationships: application to total hip arthroplasty. *Hip Int* 17(Suppl 5):S91–S104
13. Morvan G, Mathieu P, Vuillemin V, Guerini H, Bossard P, Zeitoun F, Wybier M (2011) Standardized way for imaging of the sagittal spinal balance. *Eur Spine J* 20(Suppl 5):602–608
14. Mangione P, Senegas J (1997) Sagittal balance of the spine. *Rev Chir Orthop Reparatrice Appar Mot* 83:22–32
15. Hovorka I, Rousseau P, Bronsard N, Chalali M, Julia M, Carles M, Amoretti N, Boileau P (2008) Extension reserve of the hip in relation to the spine: comparative study of two radiographic methods. *Rev Chir Orthop Reparatrice Appar Mot* 94:771–776
16. Dubousset J, Charpak G, Skalli W, Kalifa G, Lazennec JY (2007) EOS stereo-radiography system: whole-body simultaneous anteroposterior and lateral radiographs with very low radiation dose. *Rev Chir Orthop Reparatrice Appar Mot* 93:141–143
17. Marks M, Stanford C, Newton P (2009) Which lateral radiographic positioning technique provides the most reliable and functional representation of a patient’s sagittal balance? *Spine (Phila Pa 1976)* 34:949–954
18. Legaye J, Duval-Beaupere G (2005) Sagittal plane alignment of the spine and gravity: a radiological and clinical evaluation. *Acta Orthop Belg* 71:213–220
19. NF-ISO-5725-2 (1994) Application de la statistique - Exactitude (justesse et fidélité) des résultats et méthodes de mesure - Partie 2 : méthodes de base pour la détermination de la répétabilité et de la reproductibilité d’une méthode de mesure normalisée. Application des méthodes statistiques.
20. Shrout PE, Fleiss JL (1979) Intraclass correlations: uses in assessing rater reliability. *Psychol Bull* 86:420–428
21. Offierski CM, MacNab I (1983) Hip–spine syndrome. *Spine (Phila Pa 1976)* 8:316–321
22. Dujardin F, Selva O, Mejjad O, Pasero D, Piraux JL, Thomine JM (1995) Intra and interindividual variations of pelvic mobility in normal adult walk. *Rev Chir Orthop Reparatrice Appar Mot* 81:592–600
23. Lee LW, Zavarei K, Evans J, Lelas JJ, Riley PO, Kerrigan DC (2005) Reduced hip extension in the elderly: dynamic or postural? *Arch Phys Med Rehabil* 86:1851–1854
24. James B, Parker AW (1989) Active and passive mobility of lower limb joints in elderly men and women. *Am J Phys Med Rehabil* 68:162–167
25. Roach KE, Miles TP (1991) Normal hip and knee active range of motion: the relationship to age. *Phys Ther* 71:656–665
26. Lazennec JY, Brusson A, Rousseau MA (2012) Hip-Spine Relations: an innovative paradigm in THR Surgery. In: Samo K Fokter (ed) Recent advances in arthroplasty. InTech