



### Science Arts & Métiers (SAM)

is an open access repository that collects the work of Arts et Métiers Institute of Technology researchers and makes it freely available over the web where possible.

This is an author-deposited version published in: <https://sam.ensam.eu>  
Handle ID: <http://hdl.handle.net/10985/18276>

#### To cite this version :

Olivier BARBIER, Wafa SKALLI, Didier MAINARD - Changes in pelvic orientation after total hip arthroplasty : a prospective study with EOS™ - Acta Orthopaedica Belgica - Vol. 83, p.360-366 - 2017

Any correspondence concerning this service should be sent to the repository

Administrator : [scienceouverte@ensam.eu](mailto:scienceouverte@ensam.eu)



# Changes in pelvic orientation after total hip arthroplasty : a prospective study with EOS™

Olivier BARBIER, Waffa SKALLI , Didier MAINARD

*From the Department of arthroscopy, traumatology and orthopaedic surgery, Central Hospital, Nancy, Arts et Metiers ParisTech, Biomechanics laboratory, Paris, Department of orthopaedic surgery, Begin Military Teaching Hospital, Saint Mandé, France*

**Changes in pelvic orientation after THA could alter the relationship between the femoral stem and the acetabular component and may be responsible of dislocation and implant degeneration. EOS™ technology allows three-dimensional analysis of the pelvis in functional position with low irradiation. The purpose of the study was to evaluate changes in pelvic orientation after THA in standing position with EOS™. In a prospective study, EOS™ was performed in standing position preoperatively and 3 months after computer assisted THA for primary hip osteoarthritis. Differences between pre- and postoperative pelvic parameters values were analyzed. 40 patients were included. Changes greater than 5° was noted in 12,5% of cases for pelvic incidence, 35% of cases for sacral slope and in 22,5% of cases for pelvic version. In conclusion, pelvic parameters could be modified after THA.**

**Key words:** EOS imaging; Total hip arthroplasty; Pelvic parameters.

## INTRODUCTION

Computer navigation systems in THA were designed to improve acetabular cup positioning and to optimize postoperative hip biomechanics (21). They used the anterior pelvic plane (APP) as reference. This is a pelvic anatomical landmark that is rarely comparable to the vertical plane in clinical practice and with wide inter-individual variations

(15, 17, 23, 25). Moreover, some authors had shown variations in the pelvic orientation after THA (2, 13). These changes could alter the relationship between the femoral stem and the acetabular component and may cause dislocation and premature wear of the implants. Nevertheless, these studies are based on X-rays examination, though CT-scans are more accurate, because they are less costly and associated with less radiation exposure (2, 13, 29). EOS™ is a recent device that enables a 3D full-body visualization in static and/or functional position by simultaneously capturing two orthogonal antero-posterior and lateral images in a single scan with a substantial reduction in irradiation exposure (6, 8, 12). The purpose of this study was to analyse variations of pelvic parameters after THA with a 3D

- 
- Olivier Barbier, MD MSc
  - Wafa Skalli, PhD
  - Didier Mainard, MD PhD

*<sup>1</sup>Department of Arthroscopy, Traumatology and Orthopaedic surgery, Central Hospital, 29 Avenue De Lattre de Tassigny, 54000 Nancy, France*

*<sup>2</sup>Arts et Metiers ParisTech, Biomechanics laboratory, Paris, France*

*<sup>3</sup>Department of Orthopaedic Surgery, Begin Military Teaching Hospital, 69 Avenue de Paris, 94160 Saint Mandé, France.*

Correspondence : Olivier BARBIER, Department of Orthopedic Surgery, Begin Military Teaching Hospital, 69 Avenue de Paris, 94160 Saint Mandé, France. Tel : +33(0)1 43 985 920. Fax : +33(0)43 985 973.

E-mail : olive.barbier@gmail.com

*No benefits or funds were received in support of this study. The authors report no conflict of interests.*

approach thanks to EOS™ in a prospective cohort. Our hypotheses were that pelvic parameters could be modified after THA.

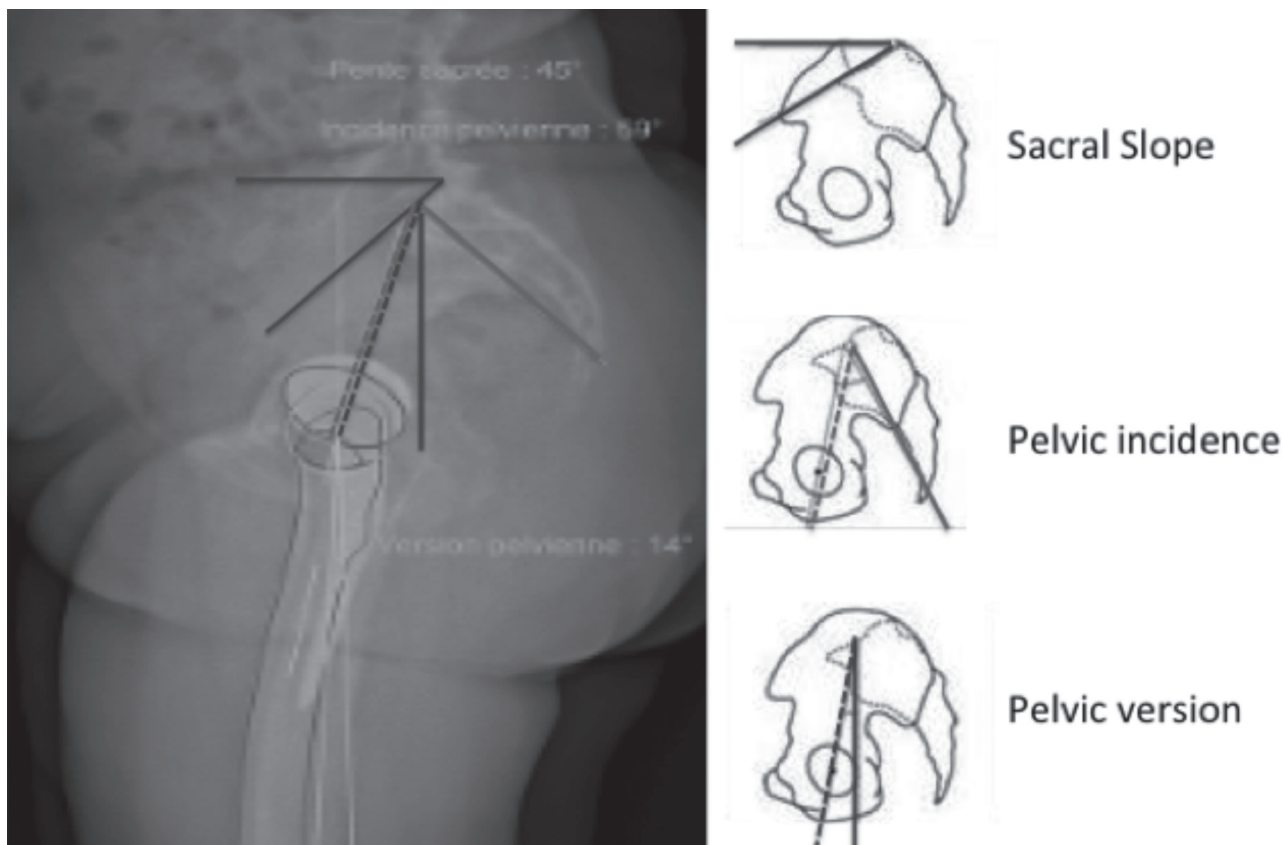
## MATERIALS AND METHODS

### Study design

In a prospective non-randomized cohort study, all patients undergoing a THA for a primary osteoarthritis of the hip over 12 months were included. Patients with hip dysplasia or previous surgery of the hip were excluded. All patients were operated by the same surgeon using a minimal invasive antero-lateral approach and a computer assisted technique (Orthopilot™) in a lateral position. The APP was used as reference for navigation. In each case, a press fit cup (Plasmacup™, B Braun, Germany) and an uncemented hydroxyapatite coated straight shaft (Excia™, B Braun, Germany) were implanted. The objective for acetabular component positioning was

15° +/- 10° anteversion and 40° +/- 10° inclination. Final per operative orientation of cup positioning was controlled with navigation. Postoperatively, all patients followed the same rehabilitation protocol.

Patients were evaluated using EOS™ as routinely in the department. For each patient, an EOS™ exam was performed in the standing position 1 month before and 3 months after THA. A standard protocol using shifted feet position as described by Lazennek and Chaibi was applied (2, 12). Radiographic success criterion described by Lazennek and al. and Chaibi et al. were used (2, 12). Measurements of pelvic angular parameters were made with a clinically validated application sterEOS™ (EOS™ imaging™, France) (5). The pelvic incidence (PI) was measured between a line perpendicular to the sacral plate at its midpoint and the line joining this point to the middle of the bicoxo-femoral axis. The sacral slope (SS) was defined by the angle subtended by a horizontal reference line and a line tangent



**Fig. 1.** — Definition of pelvic parameters measurements with EOS™.

to the sacral plate. The pelvic version (PV) was defined by the angle between the line joining the sacral plate at midpoint to the middle of the bicoxo-femoral axis and the vertical line (18-19) (fig.1). All patients were informed of the protocol of the study and gave their consent. Each pre- and postoperative measurement was performed twice separated from 1 month by two observers (one surgeon (OB) and one radiologist), independent from the operator (DM), to assess the inter and intra-observer repeatability of the pelvic measurements and investigate any significant variation of these angles after THA.

### Statistical analysis

Data were summarized and standard descriptive statistics were performed. Pelvic parameters measurements were described using the mean and the standard deviation. Inter and intra-observer repeatability of measurements by EOS™ were quantified using the 95 % confidence interval (CI) and the Bland Altman method. The Fisher exact test with a two-tail *p* value and the Pearson's intraclass correlation coefficient between the different pair of results were used for comparison of pre- and postoperative measurements (15). Deviation between pre and postoperative measurements were also quantified using Bland-Altman method. A *post-hoc* power analysis was conducted after the study, with the hypothesis that parameters remain stable after THA (>5°). An 80% power and a 0.05 level of statistical significance were set.

## RESULTS

Forty patients with primary osteoarthritis of the hip were included. The cohort included 13 males and 27 females with a mean age of 65 years (range 40-85 years, SD +/- 11) and mean BMI of 27kg/m<sup>2</sup> (18-41 kg/m<sup>2</sup>, SD +/- 6 kg/m<sup>2</sup>). Per operative measurements of the cup confirmed the good positioning with a mean inclination of 42° +/- 3° and anteversion of 20 +/- 5°.

### Analysis of intra- and inter-observer repeatability

In the whole series of measurements performed by each observer, the analysis of inter- and intra-

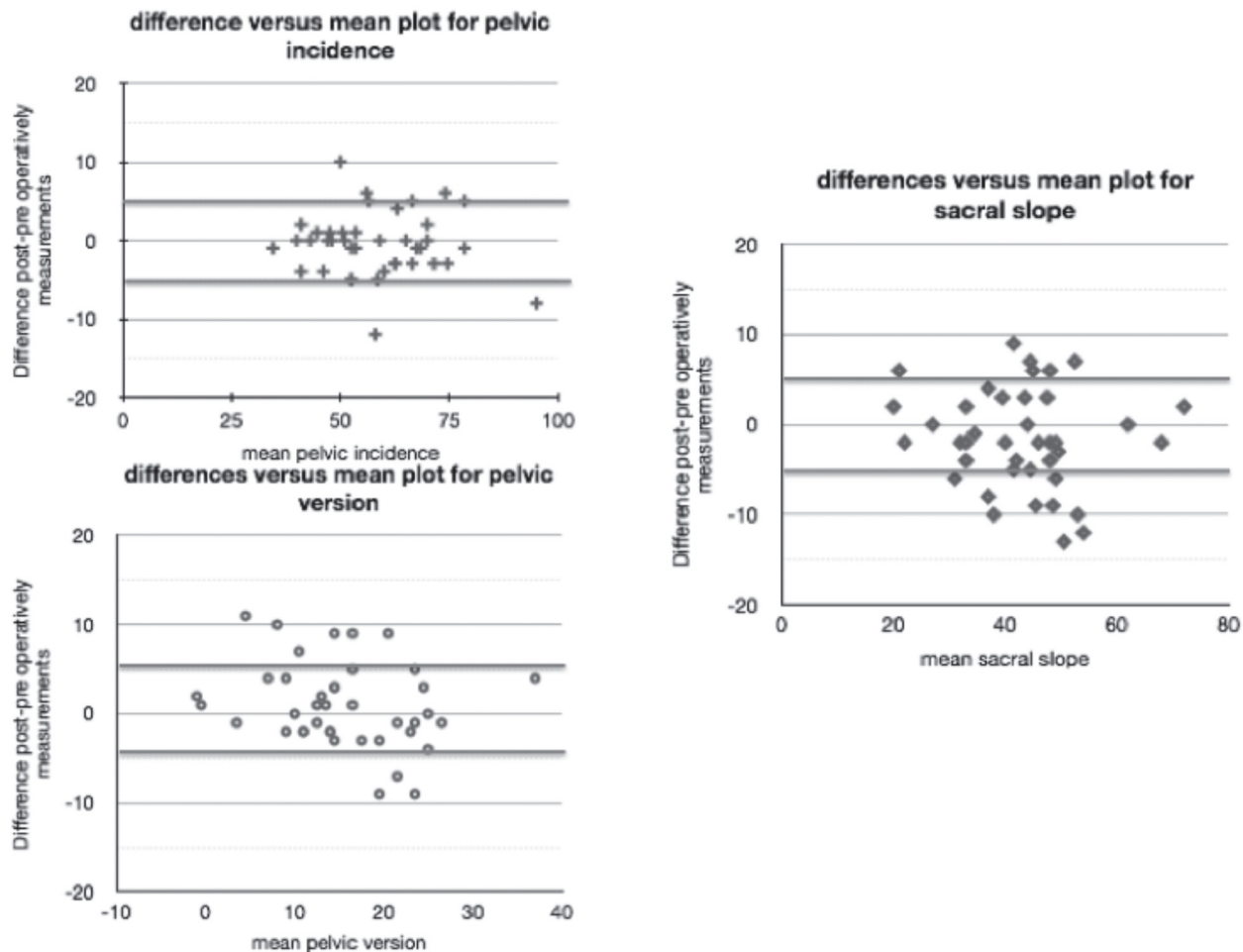
observer repeatability of EOS™ to measure pelvic parameters demonstrated a good level of agreement between the series of measurements with correlation coefficients greater than 95% for all parameters and with no significant deviation. Intra- and inter-observer repeatability were less than 5° for PI, 4° for SS and 2° for PV with a 95 %CI.

### Results of pelvic measurements

Preoperatively, mean PI was 58.5° ± 15.79, mean SS was 43.7° ± 11.91 and mean PV was 15.03° ± 15.03. Postoperatively, mean PI was 58.03° ± 12.72, mean SS was 42.08° ± 11.23 and mean PV was 16.00 ± 7.90. Considering a minimal repeatability of measurements of 5° with a 95% CI, the *post-hoc* power analysis confirmed that a sample size of 36 was enough to give us 80% power (alpha = 0.05). When pre- and postoperative parameters were compared to one another, there is not any significant difference between the measurements. The analysis of the level of agreement between pre- and postoperative measurements demonstrated correlation coefficients of 95% for PI, 89% for SS and 77% for PV. Considering a minimal repeatability of measurements of 5° with a 95% CI for all parameters, on the whole series, graphical analysis with Blant-Altman method (fig.2) show variations between pre- and post operative measurements less than 5° for the pelvic incidence in 87,5% of cases, for the sacral slope in 65.0% of cases and for the pelvic version in 77.7% of cases.

## DISCUSSION

Our study demonstrated a high level of reliability using EOS™ to measure pelvic parameters with a good inter and intra observer repeatability greater than 95%. The 95% CI for measurements in our study was less than 5°. As there are no gold standard to measure pelvic parameters in 3D and functional position to compare our results, we used the Bland-Altman method to assess the agreement of EOS™ for pelvic parameters measurements by checking that the differences between measurements versus mean of measurements are in the limit of agreement. In the literature, Lazennec et al. found



**Fig. 2.** — Differences versus mean plot for pelvic parameters variations (SS = sacral slope, PV = pelvic version, PI = pelvic incidence, Red line = 95% IC of measurements = 5°)

an absence of intra- and inter-observer error with EOS™ measurements in sitting and standing positions with a deviation ranged from +/- 2.97° to +/- 6.4° for pelvic parameters (15). Comparing with X-rays, they demonstrated the better accuracy of EOS™ technology. The same author in another papers demonstrated significant reproducibility and accuracy for the assessment of the axial rotation of the pelvis (26). EOS™ technology allows measurements of pelvic parameters with a functional and 3D analysis, with a reduction of radiation exposure and possibilities of acquisitions in functional position (8-9, 12).

Secondly, our study suggested that pelvic incidence is stable at short-term after THA with a mean deviation less than 5° only in 87.5% of cases.

Nevertheless, sacral slope and pelvic version are modified after THA in almost a quarter with a third of the cases. So, the pelvic static could be modified after THA in some cases. Literature is discussed about the variation of the pelvic parameters after THA. Pinoit et al., in a retrospective study about 19 patients on plain lateral x-rays of the pelvis in the standing position, found no variation of the orientation of the APP in the standing position after THA (24). In the same way, Blondel et al., in a prospective study measuring pelvic tilt on X-Ray in standing position in 50 cases at 3-years postoperative, found a mean difference between 3° +/- 0.3 S.D without any statistically significant variation between preoperative and 3-year follow-up values (p>0.05) (4). According to them, it would

be interesting to integrate the value of the pelvic tilt in computer assisted THA to achieve acetabular cup positioning. On the contrary, Taki et al., in a retrospective study about 86 patients, measuring on X-ray the pelvic tilt angle in the sagittal plane in standing and supine positions 2 to 4 years after THA, concluded that both the standing and supine, pelvic tilt angle significantly posteriorly gradually increased after THA and after 1 year, changes tended to plateau (28). Nishihara et al., in a cohort of 101 patients, measured with CT-scan the pelvic tilt angle before and 1 year after THA and found that variation of the pelvic tilt angle was more than 10° in 13 % of the patients (22). Moreover, Sariali et al. noted that patients affected by osteoarthritis had a posterior pelvic extension that decreased post-operatively after THA but did not return to norm (27). Nevertheless, these studies had bias of measurements because X-ray measurements are less accurate than EOS™ and CT-scan are made in dorsal decubitus whereas some authors had reported that the APP is not vertical, and presents major inter individual variations in static conditions and changes in standing, supine or sitting position (1, 4, 7, 15, 22, 24, 26-28). Our study is the first in literature that allows a 3D and functional analysis with EOS™ and confirms possible changes in pelvic parameters after THA in some patients. In fact, pelvic parameters are not only determined by the hip joint biomechanics but it is also affected by spinal alignment, flexion of the knees, and strength of the muscles. A number of patients with hip osteoarthritis have knee flexion or lumbar degeneration. Variation of pelvic incidence could be explained by a variation of the mobility of the ilio-sacral articulation, due to the adaptation of the pelvis to a spinal disorder, with a posteriorly pelvic tilt and a decrease of the flexum of the hip after surgery (11, 16, 27). Moreover, some subjects have a small sacral slope angle in standing position (sacrum is more vertical than usual) with a posterior pelvic tilt and others have a sacral slope greater than 50° (sacrum is more horizontal) with an anterior pelvic tilt. It is important to identify patients with a small sacral slope because they have a low faculty to adapt pelvic position in order to prevent dislocation. During THA, surgeons should be careful for acetabular positioning in case

of spinal disorder or flexion of knee because the functional acetabular anteversion after THA could be different from the per operative anteversion due to variations of the sacral tilt (14, 20, 27, 30). This post-operative change of pelvic orientation could generate a significant modification in the final cup anteversion and thus may predispose to posterior dislocation and premature implant degeneration. If this post-operative alteration to pelvic orientation cannot be anticipated, computer-aided surgery for cup positioning may not improve the accuracy of the acetabular anteversion in some patients (20, 27). Variation of the posteriorly pelvic version of 1° caused an increase of the functional anteversion of the cup of 0,7° (15, 20). So, it is important to identify these out-liners before surgery in order to anticipate potential complications. It is necessary to consider this notion of functional anteversion during THA to obtain a compromise between stability and mobility. In computer assisted THA, the APP is used as reference but may be weighted by the pelvic tilt specific to each patient. Its value established in standing position cannot be reliable in the lateral or dorsal positions to pre or postoperative measurement.

Our study exhibits a limitation that is the absence of control group. To investigate only the effect of THA on the change in pelvic parameters, the control group should be patients with osteoarthritis with an indication of THA who would not be operated that appeared us not ethical. Nevertheless, pelvic parameters in our study are in the mean of the general population and patients with hip osteoarthritis with pelvic incidence between 51,7° to 60,5° (10-11, 27). Another limitation of our study is that we did not have measured spinal and lower limb parameters. Pelvic orientation will also be affected by contralateral hip disease or arthroplasty as well as any disorder of the lower limb, particularly if there is a leg length discrepancy. These factors could be analysed. We focused on the change after THA in the standing positions. Moreover, it would be interesting to correlate this variation in pelvic parameters to the analysis of the cup orientation and the anteversion of the femoral neck in order to analyse the risk of dislocation of the THA. These parameters were not measurable with EOS™ at the



beginning of our study and should be integrated in a next study.

In conclusion, our study confirmed that in some cases pelvic parameters could change and surgeon should be careful when he positions THA components, especially in patients with spinal disorder or articular stiffness. So, while navigation clearly improves the anatomical position of the cup during THA, the functional orientation of the cup could be modified due to significant changes between preoperative and postoperative pelvic orientation that may predispose to posterior dislocation and premature implant degeneration.

## REFERENCES

1. Ala Eddine T, Migaud H, Chantelot C, Cotten A, Fontaine C, Duquenois A. Variations of pelvic anteversion in the lying and standing positions analysis of 24 control subjects and implications for CT measurement of position of a prosthetic cup. *Surg Radiol Anat* 2001 ; 23 : 105-10.
2. Babisch JW, Layher F, Amiot LP. The rationale for tilt-adjusted acetabular cup navigation. *J Bone Joint Surg Am* 2008 ; 90 : 357-365.
3. Bland JM, Altman DG. Statistical methods for assessing agreement between two methods of clinical measurement. *Lancet* 1986 ; 1 : 307-10.
4. Blondel B, Parratte S, Tropiano P, Pauly V, Aubaniac JM, Argenson JN. Pelvic tilt measurement before and after total hip arthroplasty. *Orthop Traumatol Surg Res* 2009 ; 95 : 568-572.
5. Chaïbi Y, Cresson T, Aubert B, Hausselle J, Neyret P, Hauger O, de Guise JA, Skalli W. Fast 3D reconstruction of the lower limb using a parametric model and statistical inferences and clinical measurements calculation from biplanar X-rays. *Comput Methods Biomech Biomed Engin* 2012 ; 15 : 457-466.
6. Deschenes S, Charron G, Beaudoin, Labelle H, Dubois J, Miron MC, Parent S. Diagnostic imaging of spinal deformities: reducing patients radiation dose with a new slot-scanning X-ray imager. *Spine*. 2010 Apr; 35 : 989-994.
7. DiGioia AM, Hafez MA, Jaramaz B, Levison TJ, Moody JE. Functional pelvic orientation measured from lateral standing and sitting radiographs. *Clin Orthop Relat Res*. 2006 ; 453 : 272-276.
8. Dubousset J, Charpak G, Skalli W, Kalifa G, Lazennec JY. EOS stereo-radiography system: whole-body simultaneous anteroposterior and lateral radiographs with very low radiation dose. *Rev Chir Orthop Reparatrice Appar Mot* 2007 ; 93 : 141-143.
9. Dubousset J, Charpak G, Dorion I, Skalli W, Lavaste F et al. A new 2D and 3D imaging approach to musculoskeletal physiology and pathology with low-dose radiation and the standing position : the EOS system. *Bull Acad Natl Med*. 2005 ; 189 : 287-97.
10. Guigui P, Levassor N, Rillardon L, Wodecki P, Cardinne L. Physiological value of pelvic and spinal parameters of sagittal balance: analysis of 250 healthy volunteers. *Rev Chir Orthop Reparatrice Appar Mot*. 2003 ; 89 : 496-506.
11. Hammerberg EM, Wood KB. Sagittal profile of the elderly. *J Spinal Disord Tech*. 2003 ; 16 : 44-50.
12. Kalifa G, Charpak Y, Maccia C, Fery-Lemonnier E, Bloch J et al. Evaluation of a new low-dose digital x-ray device: first dosimetric and clinical results in children. *Pediatr Radiol* 1998 ; 28 : 557-561.
13. Kalteis TA, Handel M, Herbst B, Grifka J, Renkawitz T. In vitro investigation of the influence of pelvic tilt on acetabular cup alignment. *J Arthroplasty* 2009 ; 24: 152-157.
14. Kalteis T, Handel M, Herold T, et al. Position of the acetabular cup – accuracy of radiographic calculation compared to CT-based measurement. *Eur J Radiol* 2006 ; 58 : 294-300.
15. Lazennec JY, Rousseau MA, Rangel A et al. Pelvis and total hip arthroplasty acetabular component orientations in sitting and standing positions: measurements reproducibility with EOS imaging system versus conventional radiographies. *Orthop Traumatol Surg Res* 2011 ; 97 : 373-380.
16. Lazennec JY, Charlot N, Gorin M, Roger B, Arafati N, Bissery A, Saillant G. Hip-spine relationship: a radio-anatomical study for optimization in acetabular cup positioning. *Surg Radiol Anat* 2004 ; 26 : 136-144.
17. Legaye J. Influence of the sagittal balance of the spine on the anterior pelvic plane and on the acetabular orientation. *Int Orthop* 2009 ; 33 : 1695-1700.
18. Legaye J, Duval-Beaupere G, Hecquet J, Marty C. Pelvic incidence: a fundamental pelvic parameter for three-dimensional regulation of spinal sagittal curves. *Eur Spine J* 1998 ; 7 : 99-103.
19. Legaye J, Duval-Beaupere G. Sagittal plane alignment of the spine and gravity: a radiological and clinical evaluation. *Acta Orthop Belg* 2005 ; 71 : 213-220.
20. Lembeck B, Mueller O, Reize P, Wuelker N. Pelvic tilt makes acetabular cup navigation inaccurate. *Acta Orthop* 2005 ; 76 : 517-523.
21. Mainard D. Navigated and nonnavigated total hip arthroplasty: results of two consecutive series using a cementless straight hip stem. *Orthopedics* 2008 ; 31 : 22-26.
22. Nishihara S, Sugano N, Nishii T, Ohzono K, Yoshikawa H. Measurements of pelvic flexion angle using three-dimensional computed tomography. *Clin Orthop Relat Res* 2003 ; 140-151.
23. Philippot R, Wegrzyn J, Farizon F, Fessy MH. Pelvic balance in sagittal and Lewinnek reference planes in the standing, supine and sitting positions. *Orthop Traumatol Surg Res* 2009 ; 95 : 70-76.

24. **Pinoit Y, May O, Girard J, Laffargue P, Ala Eddine T, Migaud H.** Low accuracy of the anterior pelvic plane to guide the position of the cup with imageless computer assistance: variation of position in 106 patients. *Rev Chir Orthop Reparatrice Appar Mot.* 2007 ; 93 : 455-460.
25. **Rousseau MA, Lazennec JY, Boyer P, Mora N, Gorin M, Catonne Y.** Optimization of total hip arthroplasty implantation: is the anterior pelvic plane concept valid? *J Arthroplasty* 2009 ; 24 : 22-26.
26. **Rousseau MA, Brusson A, Lazennec JY.** Assessment of the axial rotation of the pelvis with the EOS imaging system: intra- and inter-observer reproducibility and accuracy study. *Eur J Orthop Surg Traumatol* 2013 ; 24 : 891-5.
27. **Sariali E, Lazennec JY, Khiami F, Gorin M, Catonne Y.** Modification of pelvic orientation after total hip replacement in primary osteoarthritis. *Hip Int* 2009 ;19 : 257-263
28. **Taki N, Mitsugi N, Mochida Y, Akamatsu Y, Saito T.** Change in pelvic tilt angle 2 to 4 years after total hip arthroplasty. *J Arthroplasty* 2012 ; 27 : 940-944.
29. **Wan Z, Malik A, Jaramaz B, Chao L, Dorr LD.** Imaging and navigation measurement of acetabular component position in THA. *Clin Orthop Relat Res.* 2009 ; 467 : 32-42.
30. **Wolf A, Digioia AM, Mor AB, Jaramaz B.** Cup alignment error model for total hip arthroplasty. *Clin Orthop Relat Res* 2005 : 132-7.