



Science Arts & Métiers (SAM)

is an open access repository that collects the work of Arts et Métiers Institute of Technology researchers and makes it freely available over the web where possible.

This is an author-deposited version published in: <https://sam.ensam.eu>
Handle ID: <http://hdl.handle.net/10985/20226>

To cite this version :


Claudio VERGARI, Wafa SKALLI, Kariman ABELIN-GENEVOIS, Jean Claude BERNARD, Zongshan HU, Jack Chun Yiu CHENG, Winnie Chiu Wing CHU, Ayman ASSI, Mohammad KARAM, Ismat GHANEM, Tito BASSANI, Fabio GALBUSERA, Luca Maria SCONFENZA, Marco BRAYDA-BRUNO, Isabelle COURTOIS, Eric EBERMEYER, Raphaël VIALLE, Tristan LANGLAIS, Jean DUBOUSSET - Effect of curve location on the severity index for adolescent idiopathic scoliosis: a longitudinal cohort study - European Radiology p.- - 2021

Any correspondence concerning this service should be sent to the repository

Administrator : scienceouverte@ensam.eu



Effect of curve location on the severity index for adolescent idiopathic scoliosis: a longitudinal cohort study

Claudio Vergari¹  · Wafa Skalli¹ · Kariman Abelin-Genevois² · Jean Claude Bernard² · Zongshan Hu³ · Jack Chun Yiu Cheng³ · Winnie Chiu Wing Chu⁴ · Ayman Assi⁵ · Mohammad Karam⁵ · Ismat Ghanem⁵ · Tito Bassani⁶ · Fabio Galbusera⁶ · Luca Maria Sconfienza^{6,7} · Marco Brayda-Bruno⁶ · Isabelle Courtois⁸ · Eric Ebermeyer⁸ · Raphael Vialle⁹ · Tristan Langlais⁹ · Jean Dubousset¹

Abstract

Objectives Adolescent idiopathic scoliosis (AIS) is the most common spinal disorder in children. A severity index was recently proposed to identify the stable from the progressive scoliosis at the first standardized biplanar radiographic exam. The aim of this work was to extend the validation of the severity index and to determine if curve location influences its predictive capabilities.

Methods AIS patients with Cobb angle between 10° and 25°, Risser 0–2, and no previous treatment were included. They underwent standing biplanar radiography and 3D reconstruction of the spine and pelvis, which allowed to calculate their severity index. Patients were grouped by curve location (thoracic, thoracolumbar, lumbar). Patients were followed up until skeletal maturity (Risser ≥ 3) or brace prescription. Their outcome was compared to the prediction made by the severity index.

Results In total, 205 AIS patients were included; 82% of them (155/189, 95% confidence interval [74–90%]) were correctly classified by the index, while 16 patients were unclassified. Positive predictive ratio was 78% and negative predictive ratio was 86%. Specificity (78%) was not significantly affected by curve location, while patients with thoracic and lumbar curves showed higher sensitivity (≥ 89%) than those with thoracolumbar curves (74%).

Conclusions In this multicentric cohort of 205 patients, the severity index was used to predict the risk of progression from mild to moderate scoliosis, with similar results of typical major curve types. This index represents a novel tool to aid the clinician and the patient in the modulation of the follow-up and, for progressive patients, their decision for brace treatment.

Key Points

- *The severity index of adolescent idiopathic scoliosis has the potential to detect patients with progressive scoliosis as early as the first exam.*
- *Out of 205 patients, 82% were correctly classified as either stable or progressive by the severity index.*
- *The location of the main curve had small effect on the predictive capability of the index.*

Keywords Prognostic factors · X-ray diagnosis · Predictive value of tests · Spine

✉ Claudio Vergari
c.vergari@gmail.com

¹ Arts et Métiers Institute of Technology, Université Sorbonne Paris Nord, IBHGC - Institut de Biomécanique Humaine Georges Charpak, HESAM Université, 151 bd de l'Hôpital, F-75013 Paris, France

² Department of Orthopaedic Surgery and Children Conservative Treatment, Croix-Rouge française, Centre Médico-Chirurgical et de Réadaptation des Massues, Lyon, France

³ SH Ho Scoliosis Research Laboratory, Department of Orthopaedics and Traumatology, Faculty of Medicine, The Prince of Wales Hospital, The Chinese University of Hong Kong, Shatin, Hong Kong SAR

⁴ Department of Imaging and Interventional Radiology, Faculty of Medicine, The Prince of Wales Hospital, The Chinese University of Hong Kong, Shatin, Hong Kong SAR

⁵ Laboratory of Biomechanics and Medical Imaging, Faculty of Medicine, University of Saint-Joseph, Beirut, Lebanon

⁶ IRCCS Istituto Ortopedico Galeazzi, Milan, Italy

⁷ Dipartimento di Scienze Biomediche per la Salute, Università degli Studi di Milano, Milan, Italy

⁸ Unite Rachis, CHU - Hopital Bellevue, Saint-Etienne, France

⁹ Sorbonne Université, Department of Pediatric Orthopaedics, Hôpital Armand Trousseau, Assistance Publique-Hôpitaux de Paris (AP-HP), Paris, France

Abbreviations

AIS	Adolescent idiopathic scoliosis
AUC	Area under the curve
R O C curve	Receiver operating characteristic curve
SOSORT	Society on Scoliosis Orthopaedic and Rehabilitation Treatment

Introduction

Adolescent idiopathic scoliosis (AIS) is the most common spinal disorder in children and adolescents [1], affecting 1–4% of the population. If left untreated, it can lead to pulmonary impairment in the most severe cases [2, 3] and lead to a reduced quality of life [4]. Diagnosis and decision-taking are mainly based on the serial radiological follow-up assessment of severity, usually using the Cobb angle, which is measured on a single frontal radiograph to evaluate scoliosis severity, and also the patient's skeletal maturity (Risser sign, Tanner stage) [5].

At the beginning of puberty, 44% of patients with a Cobb angle $< 20^\circ$, and 52% of patients with a Cobb angle between 20 and 30° risk progressive scoliosis [6]. The aim of conservative treatment is to slow down the progression of the deformity, thus reducing the risk of further progression and the need of surgery. Early treatment is more effective than late [7], but there is no consensus on how early this treatment should start. This is a difficult question to answer because treatment is cumbersome for these young and active patients, and therefore exploratory studies aiming to analyze early treatment are ethically questionable since they would necessitate overtreatment of non-progressive patients.

This raises the issue of detecting and predicting objectively as early as possible those curves that will eventually progress. Uncertainty of this prediction in clinical routine can lead to overtreatment (too much unnecessary burden on the patient) or undertreatment (not able to prevent the progression of the deformity early enough).

In the recent years, 3D analyses based on biplanar spinal radiographs are becoming standard practice. In AIS, there is a very characteristic three-dimensional pattern of deformity, which includes the location of the apical vertebra in the major curvature (curve location: thoracic, thoracolumbar, lumbar), a flattening of the spine in the sagittal plane and a torsion of the spine within the scoliotic curve. Spinal torsion is often overlooked, due to the difficulties in measuring spinal parameters in the axial plane using conventional radiography [8].

It has therefore been suggested that quantifying the 3D geometry of the scoliotic curve can help to detect patients with risk of progression at an earlier stage [9]. In a pilot study of 65 patients with mild AIS, a severity index based on the 3D reconstruction of the spine was able to correctly classify

82% of the patients as progressive or stable. The 3D reconstruction of the spine can be obtained using low-dose biplanar radiography and validated reconstruction methods [10, 11].

However, the potential effect of curve location could not be analyzed in the previous pilot study, due to the small cohort included. This is an important aspect to investigate because different curve topologies might present a different phenotype of progressive curves. Hence, the accuracy of the severity index might depend on curve location, and indications for its clinical use could be affected. The aim of this paper was to extend the validation to a larger multicenter cohort and to determine if curve location has an effect on the predictive capabilities of the severity index.

Materials and methods

The study was approved by the ethical committee (CPP Ile de France VI 6001 and local hospitals' ethical committees). Patient informed consent was collected for patients included prospectively, and it was waived for retrospective anonymized data which was acquired in clinical routine. Part of this cohort ($N = 55$) was already presented in a previous paper validating a custom reconstruction method for the spine [10].

Subjects

Patients were included prospectively and retrospectively from six clinical centers in four different countries (France, Hong Kong, Lebanon, Italy, with a minimal of 10% of inclusions per team), between 2013 and 2020. Inclusion criteria were confirmed diagnosis of AIS, Cobb angle between 10° and 25° , European Risser sign < 3 [12], age > 10 years, and no previous treatment of scoliosis.

Patients were excluded if they presented with supernumerary thoracic vertebrae, transition anomalies, or in case of non-standard free-standing position [13] in biplanar radiography (described below). Non-idiopathic scoliosis (i.e., scoliosis for which an underlying cause was determined) was excluded through clinical and neurological assessment and magnetic resonance imaging.

Patients were classified by major curve location, according to the location of the apex: thoracic (apex between T2 and T11), thoracolumbar (apex in T12 or L1), and lumbar (apex between L2 and L4) [14].

Patients were followed radiologically at regular intervals between 3 months and 1 year as decided by the practice of the respective centers. All patients underwent standing biplanar radiography (EOS system, EOS Imaging) at inclusion, and EOS or conventional radiography at each follow-up exam.

Follow-up ceased when the patient reached skeletal maturity with no progression and no treatment ("stable patients,"

with Risser sign ≥ 3 and Cobb angle $\leq 25^\circ$) or until prescription of brace (“progressive patients”). Quantitative criteria were applied to decide brace treatment, according to the International Society on Scoliosis Orthopaedic and Rehabilitation Treatment guidelines, i.e., Cobb angle $> 25^\circ$ and a Risser sign ≤ 2 , or a 5° increase of Cobb angle or vertebral axial rotation in 6 months [5], together with a worsening of the clinical profile. Clinicians were blinded to the patient’s severity index when examining patients.

The idiopathic character of the scoliosis, Risser sign, and the progression were confirmed for all patients by consensus between the prescribing clinician and an expert surgeon (last author, 55 years of experience) who analyzed all biplanar radiographs. Patients without clear consensus were excluded from the study.

Imaging and 3D reconstruction

The spine of all patients (T1 to pelvis) was reconstructed in 3D using previously validated methods [10, 11]. These methods are semi-automatic; i.e., they yield a 3D reconstruction of the spine after a manual digitization of anatomical structures and a fine tuning of pre-positioned 3D models which are retro projected on the frontal and lateral radiographs. The pelvic acetabula were used to define an anatomical reference, which allowed computing the patient’s anatomical sagittal and coronal planes.

Reconstructions were performed by six operators (surgeons, clinicians, and engineers) in the different centers. Further quality control was performed by one operator with 10 years of experience in 3D reconstruction (first author).

Severity index

While the procedure to obtain the 3D reconstruction was semi-automatic, the calculation of the following parameters was automatic. Six three-dimensional spinal parameters were thus computed: Cobb angle, vertebral axial rotation at the apical level, inter-vertebral rotation at the upper and lower end vertebrae, the torsion index [15], and the hypokyphosis index [16]. Axial rotations and intervertebral rotations are well known; torsion index is the mean of the sum of intervertebral axial rotations from lower junction to apex and from apex to upper junction. The hypokyphosis index is the difference between the kyphosis measured from the vertebrae adjacent to the apex (i.e., apex +1 and apex -1) and the same value computed at the same level in a cohort of asymptomatic subjects.

The severity index for each patient was then calculated automatically from a predictive discriminant analysis model which was previously described [16]. Briefly, the model is built on an independent cohort of 3D reconstructions including asymptomatic subjects, pre-brace, and severe AIS patients. Based on the similarity between a given spine and these

three groups, the model outputs the severity index, i.e., a value between 0 and 1. The index was weighted according to the patient’s European Risser sign, to account for the lower risk of progression at more advance skeletal growth; a multiplicative factor of 1, 0.8, or 0.7 was applied to the index of patients with Risser 0, 1, or 2, respectively. These multiplicative factors are consistent with the decreasing risk of progression at Risser 2 (52%) relative to Risser 0–1 (68%, $52\%/68\% = 0.76$), according to Bunnell et al [6].

An index lower than 0.4 is indicative for a stable curve, while an index higher than 0.6 is indicative for a progressive one. No prediction is issued for values in-between.

Statistics

True positives and true negatives were those patients with a correct prediction of progression or no progression, respectively. False negatives were progressive patients with a prediction of no progression, while false positives were stable patients with a prediction of progression.

Sensitivity was defined as the ratio of true positive over all progressive, while specificity as true negatives over all stable. Positive predictive ratio was defined as the ratio of true positives over all predicted as progressive, while the negative predictive ratio was the ratio of true negatives over all predicted stable. The overall ratio of correctly classified patients was the number of correctly classified patients over the number of classified patients.

Considering a specificity of 74% and sensitivity of 92%, which were assessed in previous studies, a cohort of 150 patients would be sufficient to determine sensitivity and specificity with a marginal error of 5% [10, 17].

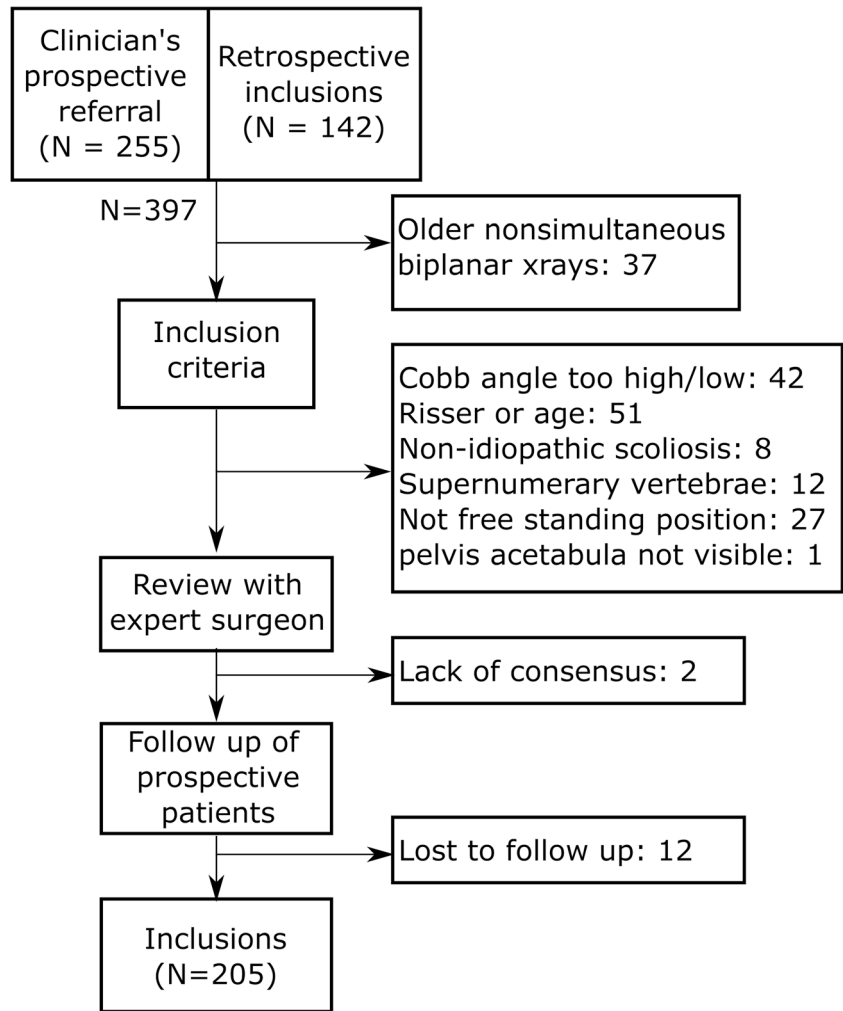
Sensitivity and specificity between different groups were compared with receiver operating characteristic (ROC) curves and area under the curve (AUC). 95% confidence bound of the ROC curve was calculated with a bootstrap procedure and 10,000 iterations. AUC between 0.8 and 0.9 is considered excellent discrimination [18].

Normality of variables was tested with Lilliefors’ test. Differences were analyzed with Mann-Whitney tests, and significance was set at $\alpha = 0.05$. Results are presented as mean \pm standard deviation for continuous variables and as value [95% confidence interval] for percentage ratios.

Results

Two hundred five patients were included (Fig. 1), with 96/205 (47%) progressive patients and 109 stable ones (53%), and a follow-up time between 6 months and 2.5 years. Patients with Risser 2 in this cohort had a very low rate of progression (7/42, 17%) compared to Risser 0–1 (89/163, 55%).

Fig. 1 STROBE flow diagram of patient inclusion



All geometrical parameters were significantly different between the progressive and stable groups (Table 1, Fig. 2). Sixteen patients (8%) were not classified; among the patients with a conclusive severity index (189/205), the overall ratio of correctly classified patients was 82% (155/189 patients, 95% CI [74–90], Table 2). Sensitivity was 87% [80–94] and specificity was 78% [69–86] (Table 2). Positive predictive ratio was 78% [69–87] and negative predictive ratio was 86% [80–93].

Eighty-eight patients had thoracic curves, sixty-five lumbar, and fifty-two thoracolumbar (Table 3). Figure 3 shows the ROC plots for the whole cohort and for each curve location. AUC showed excellent discrimination power (AUC = 0.87). Thoracolumbar and lumbar patients showed a sensitivity and specificity similar to the whole cohort (i.e., their optimal operating points were within the 95% confidence interval of the cohort; Fig. 3). In total, 93% and 89% of progressive thoracic and thoracolumbar curves were correctly detected by the index, respectively, but thoracolumbar curves showed lower sensitivity (74% [56–92], Table 3). Specificity was not significantly affected by curve location.

Analysis of false positives and negatives

Twenty-two patients out of 109 stable patients (20%) were false positives; i.e., they were predicted as progressive but they did not progress. Twelve out of 96 progressive (12%) were false negative. False positives showed a significantly more severe deformity than false negatives; they had a higher Cobb angle ($18.7 \pm 2.4^\circ$ vs $12.1 \pm 1.7^\circ$, $p = 0.0001$) and higher torsion ($5.2 \pm 2.5^\circ$ vs $1.3 \pm 1.3^\circ$, $p = 0.001$). In particular, false negatives had a Cobb angle lower than 16° .

Examples of cases of progressive and stable scoliosis as demonstrated by the severity index are provided in Fig. 4, while Fig. 5 shows examples of false positive and negatives.

Table 2 Confusion matrix of the severity index

	S-index ≤ 0.4	$0.4 < \text{S-index}$ < 0.6	S-index ≥ 0.6
Stable scoliosis (N = 109)	76 (78%)	11	22 (20%)
Progressive scoliosis (N = 96)	12 (13%)	5	79 (87%)

Table 1 Demographic and geometrical data of patients with Risser 0–1. *p* values result from Mann-Whitney tests between progressive and stable patients. Values are reported as mean ± standard deviation

	Cohort	Stable patients	Progressive patients	<i>p</i> value (stable vs progressive)
Sample size	205	109	96	-
Gender				-
Female	171	90	81	-
Male	34	19	15	-
Age	12 ± 1	12 ± 1	11 ± 1	<i>p</i> < 0.0001
Risser sign				
0	120	42	78	-
1	43	32	11	-
2	42	35	7	-
Cobb angle	16 ± 4.41	14.7 ± 4.57	17.4 ± 3.79	<i>p</i> < 0.0001
Hypokyphosis index (°)	-1.1 ± 3.1	-0.31 ± 3.1	-2 ± 2.8	<i>p</i> < 0.001
Torsion index (°)	4.35 ± 2.65	3.47 ± 2.06	5.34 ± 2.89	<i>p</i> < 0.0001
Intervertebral axial rotation at the lower end vertebra (°)	2.1 ± 3.2	1.4 ± 3.3	2.9 ± 3	<i>p</i> < 0.001
Intervertebral axial rotation at the upper end vertebra (°)	-3 ± 3.2	-1.9 ± 3.2	-4.2 ± 2.9	<i>p</i> < 0.0001
Vertebral axial rotation at the apex (°)	6.3 ± 4.4	5.2 ± 3.6	7.6 ± 4.8	<i>p</i> < 0.001

Examples of how inadequate positioning can affect spinal curvature and severity index measurements are provided in Fig. 6.

Discussion

In this study, the severity index was able to correctly classify 82% of patients with AIS as progressive or stable, with a rate of 8% who could not be confidently classified into either category. This is a promising result for the early detection of progressive scoliosis, which is the main potential advantage of the severity index over standard of care. While clinical and

radiological considerations tend to observe the progression when it starts, or to exclude it when skeletal maturity is reached, the aim of the severity index is to predict the same outcome but months, and sometimes years, in advance. This prediction may allow for early treatment and intervention. The effects of major curve location on the severity index were reviewed, and severity score index was least sensitive for those with thoracolumbar scoliosis (Table 3).

Interestingly, patients with Risser 2 in this cohort had a very low rate of progression (17%) compared to Risser 0–1 (55%). Bunnell observed that patients with Risser sign 3–4 had a risk of progression of 18%, and this risk was increased to 52% for Risser 1–2 and 68% for Risser 0 [6]. Hence, the risk observed in the present cohort according to Risser appears shifted by 1.

This study included patients with a Cobb angle up to 25°. This could be a limitation of the study because risk of further progression is considered to be higher after 20° Cobb angle and Risser < 3. Hence, these patients could be already considered as progressive, when limiting the definition of progression to the coronal plane. However, 7 of these patients (23%) did not further progress; hence, early detection of progression remains relevant in these patients. Besides, removing those patients between 20° and 25° Cobb angle does not significantly affect the results, since the overall rate of correct prediction was 82% in patients with Cobb angle < 20°.

Cobb angle is still the gold standard to assess scoliosis patients in clinical routine. It can be measured rapidly, and it has the advantage of summarizing the curve severity with a single angular value. Full 3D analysis is more comprehensive, but it is not yet widespread. This is probably due to the difficulty of obtaining

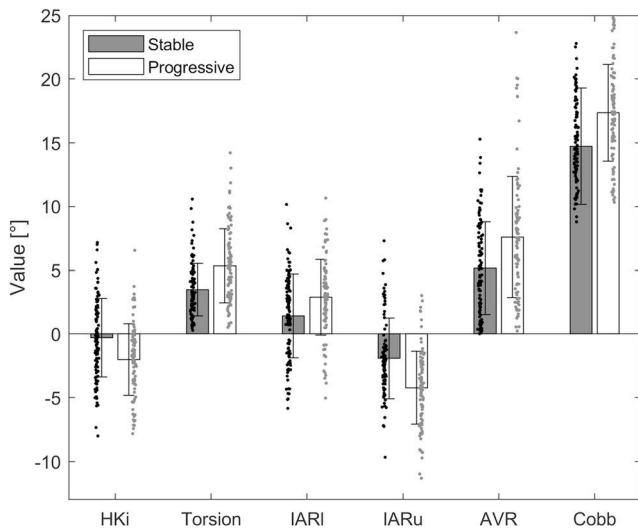


Fig. 2 Parameters to calculate the severity index in stable and progressive patients (mean ± standard deviation). HKi, hypokyphosis index; IARI and IARu, intervertebral rotation at lower and upper end vertebrae; AVR, axial vertebral rotation

Table 3 Number of patients in each group, sensitivity, and specificity of the severity index according to curve location (CI, 95% confidence interval)

Type of curvature	Total cases	Thoracic	Thoracolumbar	Lumbar
Sample size	205	88	52	65
Stable patients	109	46	27	36
Progressive patients	96	42	25	29
Correctly classified (%)	82	83	81	82
Sensitivity [CI] (%)	87 [80–94]	93 [85–100]	74 [56–92]	89 [77–100]
Specificity [CI] (%)	78 [69–86]	73 [59–86]	88 [74–100]	77 [62–91]

an accurate 3D reconstruction, which requires a trained operator and can be time-consuming. This is being addressed through the development of automatic or quasi-automatic reconstruction methods [19, 20]. However, another limiting factor for the use of 3D analysis is the definition of which parameters are relevant and how these parameters can be combined to quantify the severity of the deformity. The severity index tries to answer this question by providing a single value to quantify the 3D pattern of the scoliosis deformity. Figure 2 shows that the single parameters which are used to calculate the index are not sufficiently different in stable and progressive patients, while their combined pattern is.

Curve location had a relatively small impact on the predictive power of the severity index. ROC curves showed an excellent discrimination power for the whole cohort, but also for each curve topology (Fig. 2). Thoracic and lumbar curves showed higher sensitivity than thoracolumbar ones.

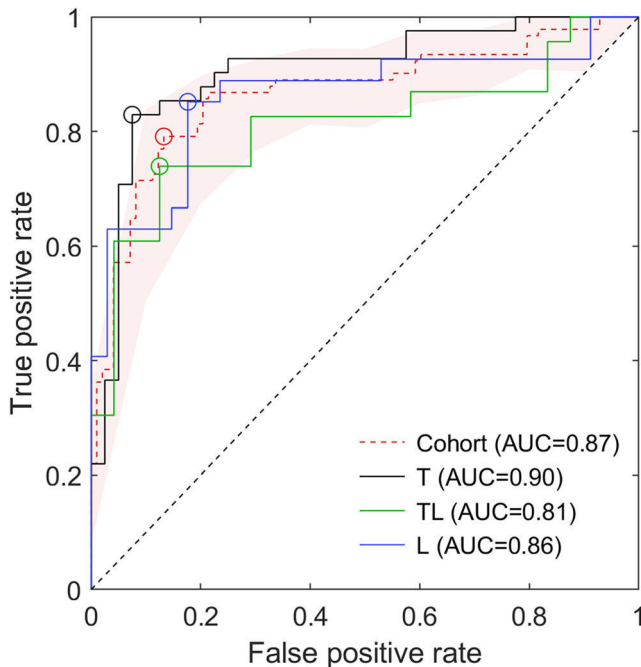


Fig. 3 Receiver operating characteristic (ROC) plots for the detection of progressive patients in the whole cohort and according to curve types (T, thoracic; TL, thoracolumbar; L, lumbar). Circles represent the optimal operating points of the curve, while the shaded area is the 95% confidence bound of the cohort ROC

However, only 52 curves were thoracolumbar, while 88 were thoracic and 65 were lumbar. Thus, it is possible that this difference between groups could decrease on a larger cohort.

Obtaining the 3D radiographic parameters describing spinal geometry requires performing a 3D reconstruction of the spine. In this multicenter international study, reconstructions were performed by 6 operators using previously validated methods. The standard biplanar radiographic device and reconstruction methods which are available in clinics are sufficient to calculate the severity index. However, the clinically available reconstruction method [11] requires a trained operator and an accurate reconstruction to obtain a robust severity index. More recently, a quasi-automatic method was proposed, which allowed calculating the severity index with a percentage agreement between operators above 80%, even when operators had a 1-day experience [10, 21]. Nevertheless, the manual or quasi-automatic character of these methods is still considered a limitation for the widespread diffusion in clinical routine. Work is in progress to obtain full automation of the 3D reconstruction, in order to eliminate any operator effect while maintaining the level of accuracy required to obtain a robust prediction through the severity index.

Another limitation to our work may include the patient positioning. In order to obtain a robust prediction with the severity index, the patient must be in the free standing position described by Faro et al [13]. Variations of this position can alter the subject's posture, thus the geometry of the spine, affecting the radiographic geometrical parameters which are calculated with the 3D reconstruction [16]. A few examples of bad positions are provided in Fig. 4: when patients put their hands against the radiography cabin, they can tend to hold their arms too high or asymmetrically. These postures can alter the natural spinal geometry and therefore the severity index. In this work, 27 patients were excluded for non-conforming position at the beginning of data collection (Fig. 1). However, in our experience, sensitization of the radiological team to the importance of natural patient posture was sufficient to reduce exclusions.

The overall rate of correct prediction was consistent with the previous results on the severity index [9, 10]. Dolan et al recently proposed a model to predict scoliosis progression [22], and they obtained a positive and negative predictive ratios of 0.7 and 0.85, respectively, which are not far from those obtained in this study (0.78 and 0.86, respectively). However, the two models have

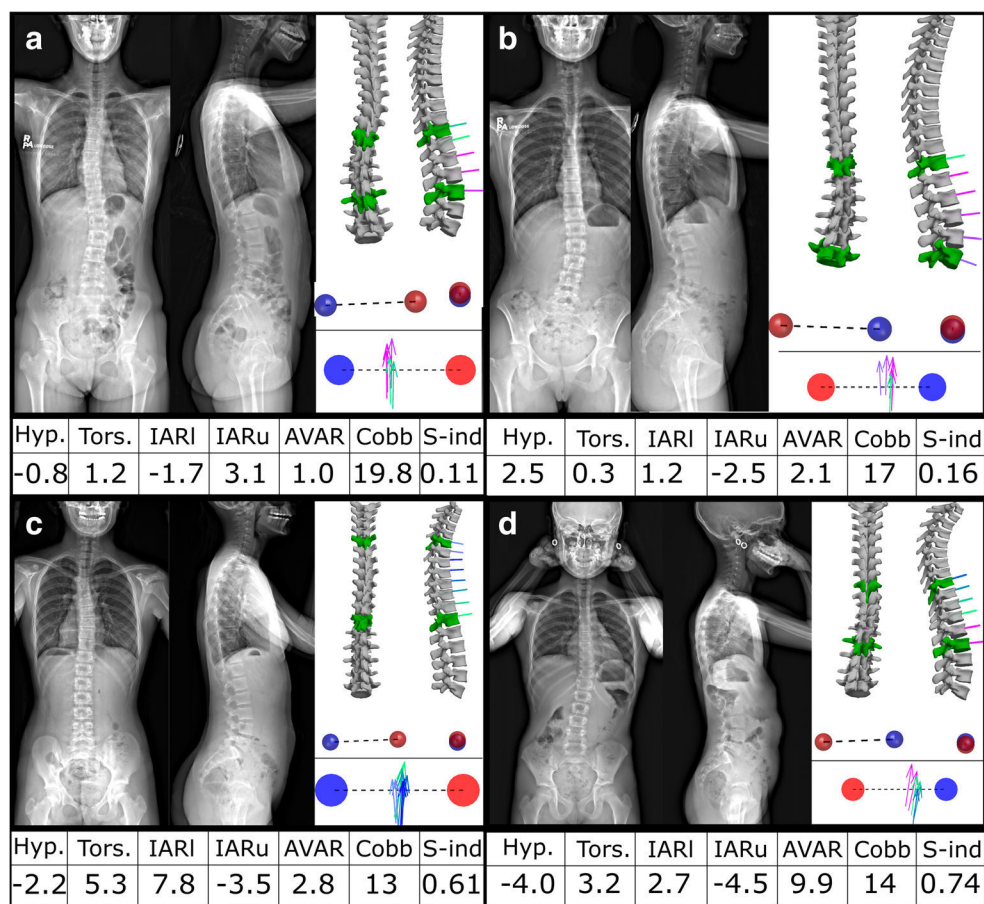


Fig. 4 Examples of two stable patients (**a**, **b**) and two progressive ones (**c**, **d**). Each panel shows the patient's biplanar radiography at inclusion, the 3D reconstruction of the spine, and pelvic acetabula. A top view of the scoliotic curve was also included where the vertebrae were represented as vectors as proposed by Illes et al [27]. **a** A 12-year-old girl with moderate Cobb angle (19.4°), but with normal hypokyphosis index (1.1°; a normal index would be 0°) and low intervertebral rotations at the end vertebrae; it was correctly classified as stable by the severity index despite the high Cobb angle. **b** A 15-year-old girl who also has a high Cobb angle of 17°, but a normal lordosis and low axial rotations, so she was correctly

classified as stable by the severity index ($s\text{-index} = 0.2$). **c** An 11-year-old girl with low Cobb angle (13°), but also a slightly flat back at the apical vertebra (hypokyphosis = -2.2°), high torsion, and high intervertebral rotation at the lower junction; her severity index correctly classified her as progressive. **d** A 10-year-old girl with high axial rotations and flat sagittal profile at the thoracolumbar junction; she was correctly classified as progressive by the index even if her Cobb angle was low (13.7°) (Hyp., hypokyphosis index (°); Tors., torsion index (°); IARI/IARu, intervertebral axial rotation at the lower/upper end vertebra (°); AVAR, apical vertebral axial rotation (°); S-ind, severity index)

different complementary aims: Dolan et al predicted curve progression $\geq 45^\circ$, i.e., towards the need of surgery, while the severity index in this study aims at predicting progression of mild to moderate scoliosis at the first exam, i.e., to start brace treatment as soon as possible and to reduce radiation exposure for patients at low risk of progression.

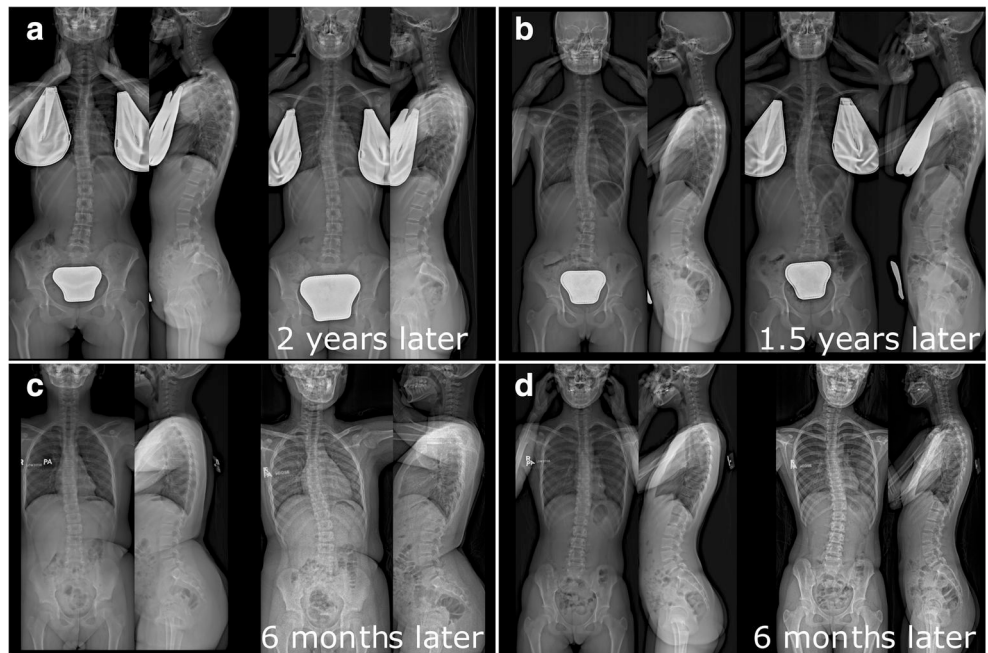
The risk factors identified by Dolan et al were Cobb angle, the presence of a thoracic curve, and the skeletal maturity, evaluated using the simplified skeletal maturity scoring system [23]. Similarly, Kadoury et al were able to classify 81% (out of 133) patients as stable or progressive. But again, Cobb angle at inclusion was higher than in the present study ($23^\circ \pm 8^\circ$ vs $16.0^\circ \pm 3.7^\circ$, $p < 0.0001$), and therefore the application field is different. The target population for the severity index used in this study is that of very mild scoliosis, and its aim is to

start an effective early treatment by brace when needed, while avoiding overtreatment.

False negatives were observed in the present study, for whom treatment could have started later than optimal, as well as false positive who risked overtreatment. A thorough analysis of these cases is underway, aiming to understand how to improve the severity index to bring the rate of correct predictions closer to 100%. It is possible that combining the three-dimensional analysis and an estimation of skeletal maturity could improve the models' predictive power. Further improvement could be attained by including 3D morphological parameters, such as vertebral slenderness and wedging [24, 25].

Nevertheless, such predictive models represent an additional useful tool to help the clinical decisions, and they can be integrated with other clinical information which might

Fig. 5 Examples of two false positives (**a** and **b**, Risser 1, 13 years old) and two false negatives (**c** and **d**, 12 years old, Risser 2 and 0, respectively). Patients in **a** and **b** had a Cobb angle of 20° at their first exam, and a vertebral axial rotation of the apex of 6 and 15° , respectively. Nevertheless, when they reached Risser 3, their deformity was not significantly changed. On the other hand, patients in **c** and **d** had Cobb angle of 10° and 12° , but only 6 months later they significantly progressed



influence the outcome, such as the presence of scoliosis in the family, the patient being pre- or post-menarche, and potential brace-wear compliance [26]. In this framework, the potential

use of the severity index in clinical routine could be as follows: a patient presenting an index lower than 0.4 should not end his follow-up, but rather increase the delay before the next

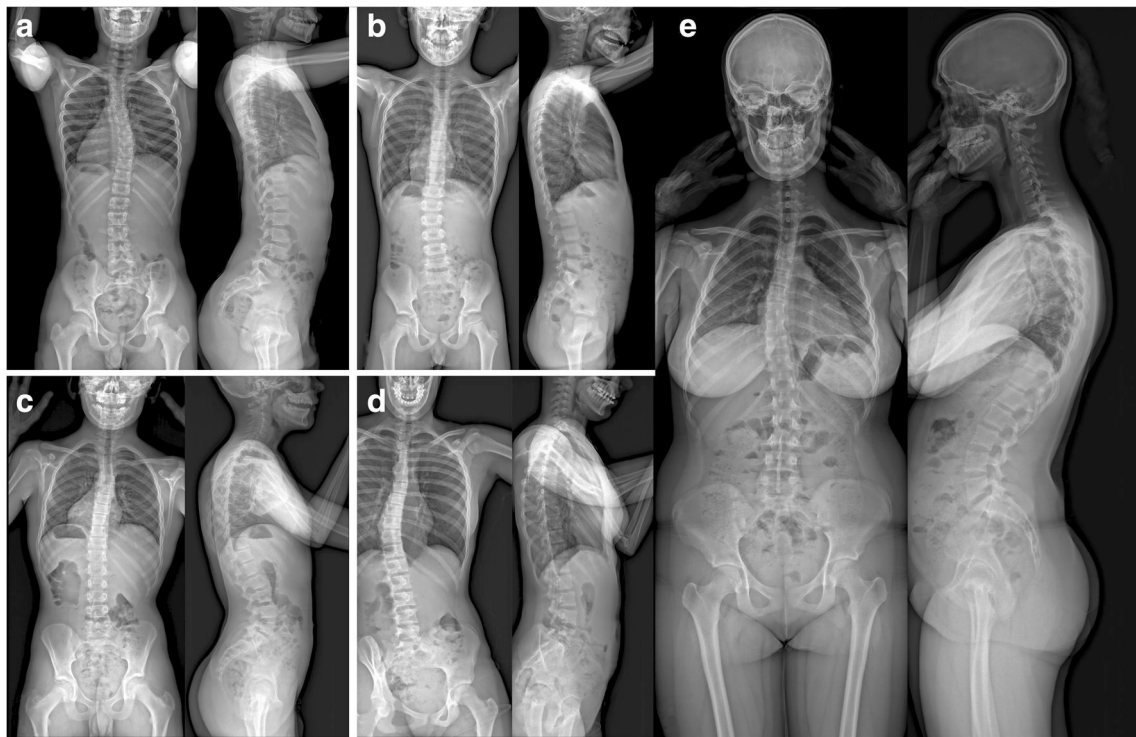


Fig. 6 Examples of how inadequate patient positioning can alter the spinal geometry, and therefore affect the severity index. Two patients (**a**, **b**) have positioned their arms too high, and the other two (**c**, **d**) hold their arms asymmetrically. Furthermore, the patient in **d** also presents a

different length of lower limbs. The patient in **e** shows a correct free-standing position: the patient holds her elbows flexed and her fingers level with the zygomatic arch. This improves visibility of the ribcage. The head is in a natural position; the patients look straight in front of them

radiological exam. Similarly, an index higher than 0.6 does not necessarily mean an immediate need of bracing, but it should alert the patient, his or her parents, and the physicians of an increased risk of progression.

The main strength of the present work is the multicenter, multioperator, and international nature of the data collection and processing: data was included from six clinical centers in four different countries, and 3D reconstructions were performed by six operators. Even with such heterogeneity of data sources, the severity index correctly classified 83% of AIS patients as stable or progressive. The positive predictive ratio was 78%; in other words, if a patient was classified as progressive, it progressed in 78% of the cases. Power analysis suggests that the severity index's sensitivity and specificity were determined with a marginal error lower than 5%, which of course could be further decreased with a larger cohort. Furthermore, this study showed that the severity index was only marginally affected by the curve location, showing comparable performance in those with typical major thoracic, lumbar, and thoracolumbar curves. Hence, we believe that this index is reasonably robust for routine clinical use, provided that the appropriate acquisition protocols are respected.

Acknowledgements The authors are grateful to the BiomecAM chair program on subject-specific musculoskeletal modelling (with the support of ParisTech and Yves Cotrel Foundations, Société Générale, Covea, and Proteor).

Funding This study has received funding from the BiomecAM chair program on subject-specific musculoskeletal modelling (with the support of ParisTech and Yves Cotrel Foundations, Société Générale, Covea, and Proteor).

Declarations

Guarantor The scientific guarantor of this publication is Wafa Skalli.

Conflict of interest Dr. Skalli has a patent related to biplanar X-rays and associated 3D reconstruction methods, with no personal financial benefit (royalties rewarded for research and education) licensed to EOS Imaging. Dr. Vialle reports personal fees and grants (unrelated to this study) from EOS Imaging.

Statistics and biometry Several authors have significant statistical expertise.

Informed consent Written informed consent was obtained from all subjects (patients) in this study.

Ethical approval Institutional Review Board approval was obtained.

Study subjects or cohorts overlap Some study subjects or cohorts have been previously reported in:

- (N=55) Vergari et al, 2019: Quasi-automatic early detection of progressive idiopathic scoliosis from biplanar radiography a preliminary validation. *European Spine Journal*.

- (N=65) Skalli et al, 2017: Early detection of progressive adolescent idiopathic scoliosis a severity index. *Spine*.

Methodology

- prospective and retrospective
- diagnostic study
- multicenter study

References

1. Konieczny MR, Senyurt H, Krauspe R (2013) Epidemiology of adolescent idiopathic scoliosis. *J Child Orthop* 7:3–9. <https://doi.org/10.1007/s11832-012-0457-4>
2. Kearon C, Viviani GR, Kirkley A, Killian KJ (1993) Factors determining pulmonary function in adolescent idiopathic thoracic scoliosis. *Am Rev Respir Dis* 148:288–294. <https://doi.org/10.1164/ajrccm/148.2.288>
3. Danielsson AJ (2013) Natural history of adolescent idiopathic scoliosis: A tool for guidance in decision of surgery of curves above 50°. *J Child Orthop* 7:37–41. <https://doi.org/10.1007/s11832-012-0462-7>
4. Tones M, Moss N, Polly DWJ (2006) A review of quality of life and psychosocial issues in scoliosis. *Spine (Phila Pa 1976)* 31:3027–3038. <https://doi.org/10.1097/01.brs.0000249555.87601.fc>
5. Negrini S, Donzelli S, Aulisa AG et al (2018) 2016 SOSORT guidelines: Orthopaedic and rehabilitation treatment of idiopathic scoliosis during growth. *Scoliosis Spinal Disord* 13:3. <https://doi.org/10.1186/s13013-017-0145-8>
6. Bunnell WP (1986) The natural history of idiopathic scoliosis before skeletal maturity. *Spine (Phila Pa 1976)* 11:773–776
7. Hresko MT, Talwalkar V, Schwend R et al (2016) Early detection of idiopathic scoliosis in adolescents. *J Bone Joint Surg Am* 98:e67. <https://doi.org/10.2106/JBJS.16.00224>
8. Illés TS, Lavaste F, Dubouset JF (2019) The third dimension of scoliosis: The forgotten axial plane. *Orthop Traumatol Surg Res* 105:351–359. <https://doi.org/10.1016/j.otsr.2018.10.021>
9. Skalli W, Vergari C, Ebermeyer E et al (2017) Early detection of progressive adolescent idiopathic scoliosis: A severity index. *Spine (Phila Pa 1976)* 42:823–830. <https://doi.org/10.1097/BRS.0000000000001961>
10. Vergari C, Gajny L, Courtois I et al (2019) Quasi-automatic early detection of progressive idiopathic scoliosis from biplanar radiography: A preliminary validation. *Eur Spine J* 28:1970–1976. <https://doi.org/10.1007/s00586-019-05998-z>
11. Humbert L, De Guise JA, Aubert B et al (2009) 3D reconstruction of the spine from biplanar X-rays using parametric models based on transversal and longitudinal inferences. *Med Eng Phys* 31:681–687. <https://doi.org/10.1016/j.medengphy.2009.01.003>
12. Bitan FD, Veliskakis KP, Campbell BC (2005) Differences in the Risser grading systems in the United States and France. *Clin Orthop Relat Res* 190–195. <https://doi.org/10.1097/01.blo.0000160819.10767.88>
13. Faro FD, Marks MC, Pawelek J, Newton PO (2004) Evaluation of a functional position for lateral radiograph acquisition in adolescent idiopathic scoliosis. *Spine (Phila Pa 1976)* 29:2284–2289
14. O'Brien MF, Kulklo TR, Blanke KM, Lenke LG (2008) Radiographic measurement manual. Medtronic Sofamor Danek USA, Inc
15. Steib J-P, Dumas R, Mitton D, Skalli W (2004) Surgical correction of scoliosis by in situ contouring: A detorsion analysis. *Spine (Phila*

- Pa 1976) 29:193–199. <https://doi.org/10.1097/01.BRS.0000107233.99835.A4>
16. Skalli W, Vergari C, Ebermeyer E et al (2017) Early detection of progressive adolescent idiopathic scoliosis. *Spine (Phila Pa 1976)* 42:823–830. <https://doi.org/10.1097/BRS.0000000000001961>
 17. Hajian-Tilaki K (2014) Sample size estimation in diagnostic test studies of biomedical informatics. *J Biomed Inform* 48:193–204. <https://doi.org/10.1016/j.jbi.2014.02.013>
 18. Hosmer DW, Lemeshow S, Sturdivant RX (2013) *Applied logistic regression*, 3rd edn. John Wiley & Sons, Hoboken
 19. Gajny L, Ebrahimi S, Vergari C et al (2019) Quasi-automatic 3D reconstruction of the full spine from low-dose biplanar X-rays based on statistical inferences and image analysis. *Eur Spine J* 28: 658–664. <https://doi.org/10.1007/s00586-018-5807-6>
 20. Aubert B, Vazquez C, Cresson T et al (2019) Toward automated 3D spine reconstruction from biplanar radiographs using CNN for statistical spine model fitting. *IEEE Trans Med Imaging* 38:2796–2806. <https://doi.org/10.1109/TMI.2019.2914400>
 21. Gajny L, Ebrahimi S, Vergari C et al (2018) Quasi-automatic 3D reconstruction of the full spine from low-dose biplanar X-rays based on statistical inferences and image analysis. *Eur Spine J*. <https://doi.org/10.1007/s00586-018-5807-6>
 22. Dolan LA, Weinstein SL, Abel MF et al (2019) Bracing in Adolescent Idiopathic Scoliosis Trial (BrAIST): Development and validation of a prognostic model in untreated adolescent idiopathic scoliosis using the simplified skeletal maturity system. *Spine Deform* 7:890–898.e4. <https://doi.org/10.1016/j.jspd.2019.01.011>
 23. Sanders JO, Khoury JG, Kishan S et al (2008) Predicting scoliosis progression from skeletal maturity: A simplified classification during adolescence. *J Bone Jt Surg* 90:540–553. <https://doi.org/10.2106/JBJS.G.00004>
 24. Nault ML, Mac-Thiong JM, Roy-Beaudry M et al (2014) Three-dimensional spinal morphology can differentiate between progressive and nonprogressive patients with adolescent idiopathic scoliosis at the initial presentation: A prospective study. *Spine (Phila Pa 1976)* 39:601–606. <https://doi.org/10.1097/BRS.0000000000000284>
 25. Vergari C, Karam M, Pietton R et al (2020) Spine slenderness and wedging in adolescent idiopathic scoliosis and in asymptomatic population: An observational retrospective study. *Eur Spine J* 29: 726–736. <https://doi.org/10.1007/s00586-020-06340-8>
 26. Lindeman M, Behm K (1999) Cognitive strategies and self-esteem as predictors of brace-wear noncompliance in patients with idiopathic scoliosis and kyphosis. *J Pediatr Orthop* 19:493–499. <https://doi.org/10.1097/00004694-199907000-00013>
 27. Illes T, Tunyogi-Csapo M, Somoskeoy S (2011) Breakthrough in three-dimensional scoliosis diagnosis: Significance of horizontal plane view and vertebra vectors. *Eur Spine J* 20:135–143. <https://doi.org/10.1007/s00586-010-1566-8>