



### **Science Arts & Métiers (SAM)**

is an open access repository that collects the work of Arts et Métiers Institute of Technology researchers and makes it freely available over the web where possible.

This is an author-deposited version published in: <https://sam.ensam.eu>  
Handle ID: <http://hdl.handle.net/10985/20421>

#### **To cite this version :**

E. GAUMÉTOU, Sergio QUIJANO, Brice ILHARREBORDE, A. PRESEDO, Patricia THOREUX, Keyvan MAZDA, Wafa SKALLI - EOS analysis of lower extremity segmental torsion in children and young adults - Orthopaedics & Traumatology: Surgery & Research - Vol. 100, n°1, p.147-151 - 2014

Any correspondence concerning this service should be sent to the repository

Administrator : [scienceouverte@ensam.eu](mailto:scienceouverte@ensam.eu)



# EOS analysis of lower extremity segmental torsion in children and young adults

E. Gaumétou<sup>a,\*</sup>, S. Quijano<sup>b,2</sup>, B. Ilharreborde<sup>a,1</sup>, A. Presedo<sup>a,1</sup>, P. Thoreux<sup>b,2</sup>, K. Mazda<sup>a,1</sup>, W. Skalli<sup>b,2</sup>

<sup>a</sup> Service de chirurgie orthopédique pédiatrique, université Paris-Diderot, Paris 7 University, hôpital Robert-Debré, AP-HP, 48, boulevard Sérurier, 75019 Paris, France

<sup>b</sup> Biomechanics laboratory, Arts et Métiers ParisTech, 151, boulevard de l'Hôpital, 75013 Paris, France

## A B S T R A C T

**Introduction:** Lower limb torsion varies substantially among healthy children during growth. Values reported in the literature to date have been obtained using semi-quantitative clinical or 2D measurement methods. Quantitative 3D measurement would help determine the physiological range of lower limb torsion. Low-dose stereoradiography with 3D reconstruction provides a good alternative. Its use increases in pediatrics because of radiation minimization. Previous studies have shown accurate and reproducible results of lower limbs reconstruction in adults and children but the torsional parameters haven't been measured yet. The present study reports the values of lower limb segmental torsion and its course during growth in a cohort of healthy children and young adults using the EOS low-dose biplanar X-ray.

**Hypothesis:** EOS 3D reconstruction is an accurate and reproducible method to measure the torsional parameters in children.

**Materials and methods:** Femoral torsion (FT) and tibial torsion (TT) were studied on 114 volunteers (228 lower limbs) from 6 to 30 years of age divided by age into 5 groups. The EOS™ acquisitions were obtained in subjects standing with their feet offset.

**Results:** Mean FT decreased during growth, passing from 21.6° to 18°, whereas mean TT increased from 26.8° to 34.7°. There was a statistically significant difference between the 2 extreme age groups, but no difference was found between any other age groups. The ICC for intra-observer reproducibility was 0.96 and 0.95 for FT and TT for the first operator, and 0.79 and 0.83 for the second operator respectively. The ICC for inter-observer reproducibility was 0.84 and 0.82 respectively.

**Discussion:** The course of lower limb segmental torsion observed was consistent with literature reports based upon clinical and 2D measurements. 3D reconstruction of EOS low-dose biplanar imaging appears to be a safe and reliable tool for lower limbs measurements, especially for investigating lower limb segmental torsion in children and adults.

**Level of evidence:** Level IV.

### Keywords:

Femoral torsion course  
Tibial torsion course  
Lower limb torsion  
EOS 3D reconstructions  
Skeletal imaging  
Child

## 1. Introduction

Lower limb torsion varies substantially among healthy children during growth. Femoral torsion is in-between 35°–41° at birth and declines gradually until reaching a mean of 12°–15° at adulthood. Tibial torsion is internal torsion at birth changing gradually to a

mean of 19° of external torsion at adulthood, with great variations [1]. Disorders during growth or disease can result in malalignment and lower limb torsional abnormalities. The diagnosis and treatment should be based on accurate measurements [2]. Rotational problems have often been ignored because being more difficult to measure than frontal-plane and sagittal-plane deformities [3,4]. The only previous literature values of normal torsional course with growth were determined using semi-quantitative clinical measurement methods [3,5–9]. Radiographic measurement methods are rarely used because of their complexity and lack of reproducibility [10–12]. Computed tomography (CT) is the current gold standard for quantitative 3D measurement, but its use is limited, particularly in children, because of ionizing radiation [2,13–22]. The radiation exposure does not allow either repeated 3D examinations for

\* Corresponding author. Tel.: +33 1 40 03 30 49; fax: +33 1 40 03 22 98; +33 1 40 03 22 17.

E-mail addresses: [elodie.gaumetou@ensam.eu](mailto:elodie.gaumetou@ensam.eu), [elodie.gaumetou@rdb.aphp.fr](mailto:elodie.gaumetou@rdb.aphp.fr) (E. Gaumétou).

<sup>1</sup> Tel.: +33 1 40 03 20 00; fax: +33 1 40 03 22 98.

<sup>2</sup> Tel.: +33 1 44 24 62 99.

follow-up, or full-body 3D modeling [23–25]. In addition, CT-scan imaging is performed with the patient in a reclining position, where inter-articular compensation mechanisms are hardly measurable [26]. Low-dose stereoradiography with 3D reconstruction provides a fast and accurate alternative, providing a full-length weight-bearing biplanar X-ray in less than 20 seconds [4,26]. Its use increases in pediatrics because of X-rays exposure 800 to 1000 times inferior to CT-scan [4,27–30]. Published studies had shown accurate and reproducible results of lower limbs reconstruction in adults and children [25,26,31]. The torsional parameters haven't been studied yet in children. The goal of this study was to measure physiological lower limb torsional values and their course during growth in a healthy population of children and young adults using EOS biplanar X-rays with 3D reconstruction.

We hypothesized that EOS 3D reconstruction is an accurate way to measure the torsional parameters in children.

## 2. Material and methods

### 2.1. Radiological parameters

The parameters determined were femoral torsion (FT) and tibial torsion (TT). Femoral torsion is also designated femoral anteversion, i.e. the angular difference between the axis of the femoral neck and the bicondylar axis of the distal femur, both projected on a plane perpendicular to the shaft axis. Tibial torsion is the angle between the proximal tibial bicondylar axis and the bimalleolar axis, projected on a plane perpendicular to the shaft axis.

### 2.2. Patients

The population consisted of 114 healthy volunteers (228 lower limbs), from 6 to 30 years old. They have been divided by age into 5 groups, 6–7 years, 8–9 years, 10–12 years, 13–15 years and 16–30 years. All had low-dose biplanar X-rays using the EOS system (EOS™ Imaging, France). These data acquisitions were from the database of the *Arts et Métiers, ParisTech*. All patients were prospectively included after IRB approval. All of these lower limbs were asymptomatic.

### 2.3. Acquisitions and 3D reconstructions

Acquisitions were performed according to the shifted-feet standing position protocol, in which the patient is positioned so as

to simplify the process of bony structures recognition [26]. Three-dimensional reconstructions were performed using *idex4* 4.8.4. The fast 3D reconstruction method was utilized with rapid adjustments for measurement of torsion, previously described and validated by Chaibi et. al. [26]. This method allows obtaining a 3D simplified personalized parametric model. Then the model could be corrected to obtain a full 3D morpho-realistic personalized parametric model of the lower limb (Fig. 1). The clinical measurements are automatically extracted from the final envelope. The same specifically trained operator performed all 3D reconstructions. Two studies were performed to assess operator qualification. The first one aimed at assessing the intra-observer reproducibility. Two reconstructions were achieved by the first author in 6 10- to 12-year-old subjects. The second one was conducted to validate inter-observer reproducibility. Radiographs from 12 patients, randomly chosen in the 6 to 12 age category, were reconstructed 3 times by 2 operators. Among the two operators, one was senior pediatric orthopaedic surgeons (operator 1, who followed a practical course with examination), and one was experienced with the method (operator 2).

### 2.4. Statistical analysis

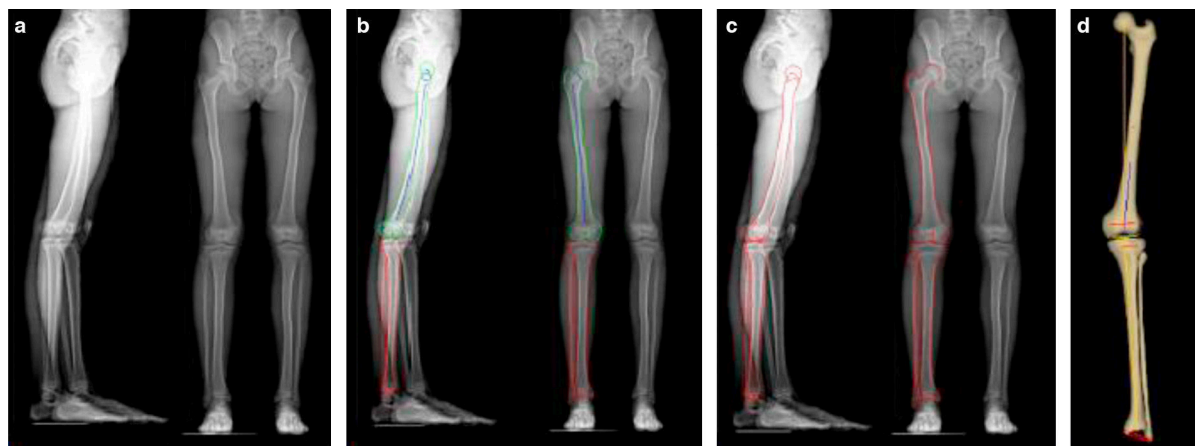
Student *t*-tests and Mann-Whitney tests were used to compare subgroup values of FT and of TT. The threshold for significance was  $P < 0.05$ . Inter-observer and intraobserver reproducibility was assessed by computing the intraclass correlation coefficient (ICC).

## 3. Results

Torsional values are reported in Table 1. There was a statistically significant difference between the 2 extreme age groups regarding both parameters but no difference was found between consecutive age groups. During growth, femoral torsion decreased ( $P = 0.01$ ) and tibial torsion increased ( $P = 0.0006$ ). Torsional course is represented in Fig. 2. The mean FT in the whole population of this study was  $18^\circ \pm 9^\circ$  and mean TT was  $31^\circ \pm 8^\circ$ .

The results of the intra-observer reproducibility study showed good intra-observer reproducibility with  $2.9^\circ$  variation of femoral torsion and  $4.1^\circ$  variation of tibial torsion. The ICC for the intra-observer reproducibility was 0.96 and 0.95 for FT and TT respectively for the first operator, and 0.79 and 0.83 respectively for the second operator. The ICC for inter-observer reproducibility was 0.84 and 0.82 respectively.

Time reconstruction was about 10 minutes for 2 lower limbs.

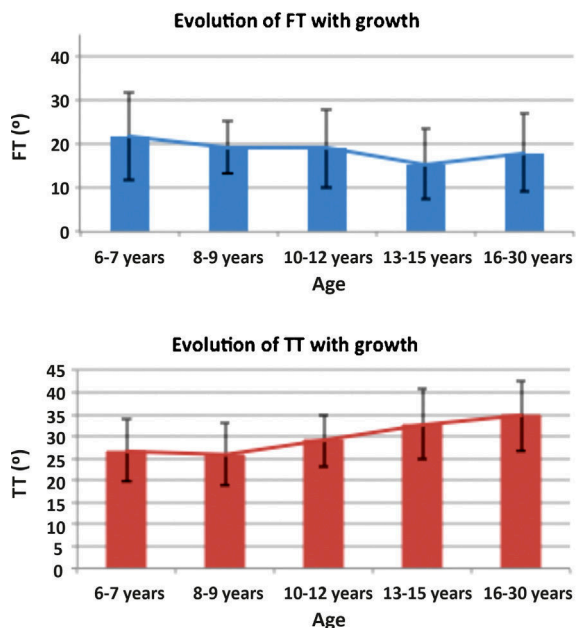


**Fig. 1.** Different steps of the reconstruction method: a) biplanar X-ray before 3D reconstruction; b) the operator was asked to adjust 3 circles representing the projection of the femoral head and the femoral condyles on both X-ray radiographs. Those projections were optimized by semiautomatic identification of a few anatomical landmarks, permitting computation of an initial model that was superimposed on the X-ray; c) further adjustments were made, so as to adjust the contours to the anatomical landmarks; d) 3D lower limb obtained were automatically calculated.

**Table 1**  
Torsion values for each groups of the study (degrees).

	6–7 years	8–9 years	10–12 years	13–15 years	16–30 years
N lower limbs	34	22	96	32	44
Mean age	6.6	8.9	10.9	14.1	23.3
Mean FT ±SD	21.6 ± 10	19.4 ± 6.4	19 ± 9	15.3 ± 8	18 ± 9.1
(Minima–Maxima)	(0.6–39.5)	(9.3–34)	(–2.8–38.7)	(4.9–40.4)	(0.2–36.8)
Mean TT ±SD	26.8 ± 6.6	25.9 ± 6.7	29.6 ± 6.3	32.8 ± 8.3	34.7 ± 7.8
(Minima–Maxima)	(11.7–45)	(10.5–37.3)	(12.6–44.8)	(12.3–57.9)	(19.8–51.6)

SD: standard deviation; FT: femoral torsion; TT: tibial torsion.



**Fig. 2.** Torsional profile evolution with growth for femoral torsion (FT) and tibial torsion (TT).

#### 4. Discussion

The values of lower limb segmental torsion during the course of growth measured in the present study with this new imaging technique are consistent with the evolution of these values previously reported in the literature [3,5,6,8,9,11,32].

##### 4.1. Femoral torsion

The present study confirms the decrease in femoral torsion during growth (Table 2). Comparison is difficult because of the differences in radiographic protocols (Tables 2 and 3). Using the Netter technique of clinical measurement [9,11] in 1319 healthy school children, Jacquemier et al. [5] observed that mean FT ranged from

21° at 5 years to 9.5° at 10 years of age in boys, and from 37° at 5 years to 16.7° at 10 years of age in girls. Bedouelle [9] prospectively studied the course of FT in children and described four different evolutive profiles, in three of which torsion reversed spontaneously during growth, two gradually and one step by step. Fabry et al. [6] reported the course of femoral anteversion in 432 healthy children. Using 2D radiological measurements, they reported a mean anteversion of 26.7° at 5 years, decreasing to 15.3° at 16 years of age. CT or MRI measurements have been reported only in adults and slice orientation for calculating 3D angles is problematic with these examinations [7,8,33]. Mean FT ranged from 10° [33] to 16° [7,8] in those studies, findings that appear underestimated compared with the present results.

##### 4.2. Tibial torsion

The course of tibial torsion observed in the present study was consistent with literature data showing that external rotation increases with age until 13–15 years and remained in the ranges observed in different publications (Table 3). Jacquemier et al. [5] found that TT, defined as the angle between the transmalleolar axis and the coronal plane, was relatively stable with an increase from 35° at 5 years to 36° at 10 years of age, in both the females and males. However, using torsionmeter measurements, Hutchins et al. [34] observed an increase in TT of 7° in boys and 4° in girls between 5 and 25 years of age. Staheli et al. [3] reported a similar increase between birth and 10 to 15 years of age. At completion of growth, TT stabilized at an average of 23° ranging from 0° to 45°, regardless of the age interval. They confirmed that the tightfoot angle was less accurate than the transmalleolar axis because of foot deformities (hindfoot varus or valgus, foot adduction or abduction). The wide range of values found in the literature can be partly explained by the various assessment methods [5], and a larger use of low-dose biplanar X-ray might eliminate this bias in the future.

##### 4.3. Advantages

The ability to measure the anatomical parameters of the lower limb in 3D is essential in the analysis of lower limb, diagnosis and preoperative planning. The low-dose stereography is an accurate

**Table 2**  
Comparison with literature values for femoral torsion (in degrees).

FT	Current (EOS)	Jacquemier (Clin)	Fabry (X-rays)	Schneider (MRI)	Jend (CT)	Goutallier (CT)	Duparc (CT)
5 years	21.6	21 (M)/37 (F)	26.7				
7 years	21.6	16 (M)/31 (F)	23.2				
8 years	19.4	12 (M)/26.7 (F)	21.3				
10 years	19	9.5 (M)/16.7 (F)	20.9				
12 years	19		19.9				
13 years	15.3		20				
15 years	15.3		15.4				
16 years	18		15.3				
30 years	18			10.4	15.2 ± 12	15.3	16

M: male; F: female; Clin: clinical; FT: femoral torsion.

**Table 3**  
Comparison with literature values for tibial torsion (in degrees).

TT	Current(EOS)	Jacquemier (Clin)	Staheli (Clin)	Hutchins (Clin)	Schneider (MRI)	Jend (CT)	Goutallier (CT)	Duparc (CT)
5 years	26.8	35	12–20	10				
7 years	26.8	33	12–20					
8 years	25.9	34	20–25					
10 years	29.6	36	25–30					
12 years	29.6		25–30					
13 years	32.8		25–30					
15 years	32.8		25–30					
16 years	34.7		25–20					
30 years	34.7		23	17.4 (M)/13.9 (F)	41.7	40 ± 9	24.9	27.7 ± 11

M: male; F: female; Clin: clinical; TT: tibial torsion.

method, reliable, inexpensive, reproducible and three-dimensional on subjects in physiological standing position [4,25,26]. The radiation exposure is very limited, allowing its use for children follow-up. The measurements made are independent of the position of the patient in the cabin and of the operator experience. There is no magnification error. It allows the visualization of the entire limb and spine at the same time.

#### 4.4. Limitations of the study

One limitation of the present study was the arbitrary choice of age groups. A more judicious choice of age groups might exist, and separation by gender might have been more enlightening. The patients could also have been classified according to skeletal maturity, for example using Risser index, which is easily assessed with EOS. Future prospective longitudinal studies could clarify the course of FT and TT in relation to skeletal growth.

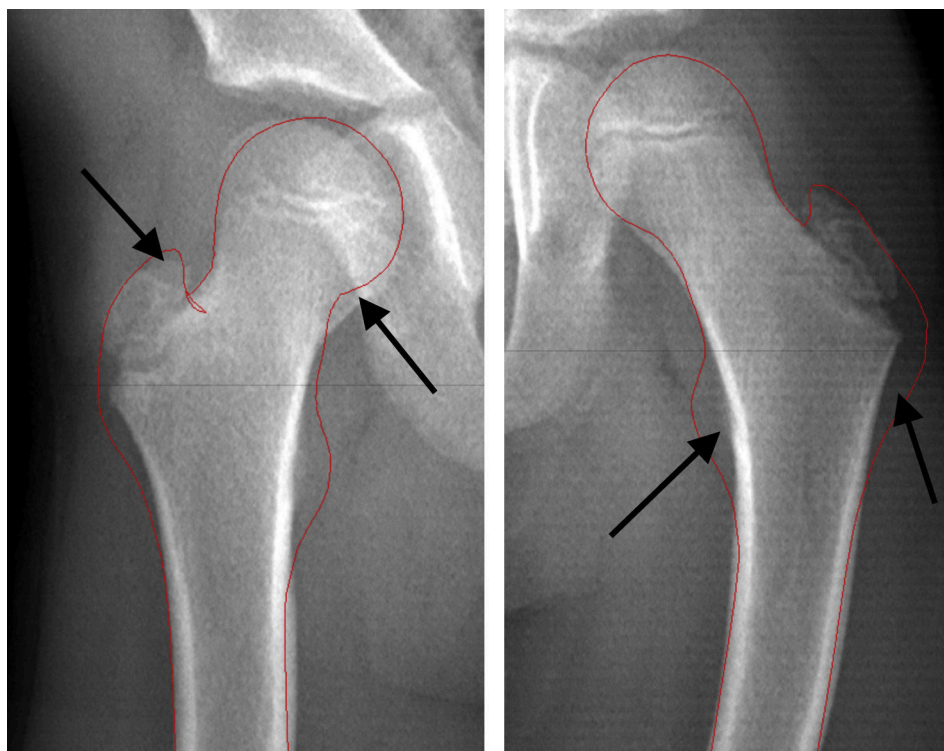
The current reconstruction method still has some limitations, especially regarding young children with immature skeletons. As a matter of fact, the statistical model applied to the child in order to obtain a patient specific 3D reconstruction is derived from an

adult database. Presedo et al. [31] investigated the feasibility of the EOS technique in children 5 years of age or older, and reported some inaccuracy and lack of reproducibility due to the absence of femoral head sphericity and to the incomplete ossification of the internal malleolus, in the 6–7 year group (Figs. 3 and 4). This suggests the need to further develop the model to extend reconstructions to specific anatomies.

Validating the use of EOS in children would have required a comparison between torsional values obtained from EOS and CT-Scans, but the dose of irradiation delivered for the CT-scan acquisitions precludes its use in young healthy children. Thus the only alternative left was comparison with literature data.

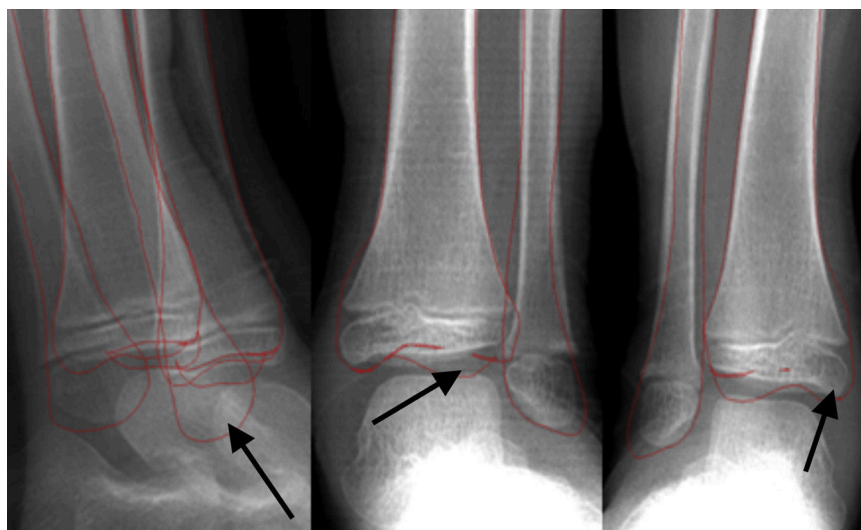
#### 4.5. Reproducibility

The results obtained in the inter-intra-observer reproducibility study are within the margins of previously published values [26]. The ICC intra-observer for FT varies in-between 0.79–0.96 and 0.83–0.95 for TT, based on the operator experience with the reconstruction method. The ICC inter-observer is consistent with the article of Folinais et al. [35] which obtained an inter-observer



**Fig. 3.** Hip biplanar X-ray at 6 years. Black arrows show the zones with a poor definition: the lesser trochanter is not visible, the femoral head is not round and the femoral neck appears thicker than normal.





**Fig. 4.** Ankle biplanar X-ray in a 6-year-old child. Black arrows show the zones with a poor definition due to incomplete ossification.

ICC of 0.94 for FT and 0.84 for TT, in adults, on reconstructions made by 3 experienced radiologists. In this study, the anatomical landmarks identification difficulties for calculating FT and TT may have influenced the results.

Although the limitations previously mentioned, the EOS 3D reconstruction method based on low-dose biplanar X-rays provided normative data of lower limb segmental torsion in children and the course of FT and TT during growth, that could not be obtained to date. The low-dose biplanar X-ray is a good way to assess the segmental torsions since the clinical measurements obtained were consistent with those found in the literature, while greatly reducing radiation exposure [25,35]. It provides a control database that can serve for investigating torsional abnormalities in various disorders such as leg length discrepancies, cerebral palsy or lower limbs congenital pathologies.

#### Disclosure of interest

The authors declare that they have no conflicts of interest concerning this article.

#### References

- [1] Gray A, Meyer F, Leyvraz P. Anomalies morphologiques des membres inférieurs dans la gonarthrose. *Médecine et hygiène. Rev Med Suisse* 2002;60:2374–9.
- [2] Jakob RP, Haertel M, Stussi E. Tibial torsion calculated by computerised tomography and compared to other methods of measurement. *J Bone Joint Surg Br* 1980;62-B(2):238–42.
- [3] Staheli LT, et al. Lower-extremity rotational problems in children. Normal values to guide management. *J Bone Joint Surg Am* 1985;67(1):39–47.
- [4] Guenoun B, et al. Reliability of a new method for lower-extremity measurements based on stereoradiographic three-dimensional reconstruction. *Orthop Traumatol Surg Res* 2012;98(5):506–13.
- [5] Jacquemier M, et al. Rotational profile of the lower limb in 1319 healthy children. *Gait Posture* 2008;28(2):187–93.
- [6] Fabry G, MacEwen GD, Shands Jr AR. Torsion of the femur. A follow-up study in normal and abnormal conditions. *J Bone Joint Surg Am* 1973;55(8):1726–38.
- [7] Goutallier D, et al. Influence of lower limb torsional deformities on the development of femoro-tibial degenerative arthritis. *Orthop Traumatol Surg Res* 1997;83:613–21.
- [8] Duparc F, et al. [Femoral and tibial bone torsions associated with internal femoro-tibial osteoarthritis. Index of cumulative torsions]. *Rev Chir Orthop Reparatrice Appar Mot* 1992;78(7):430–7.
- [9] Bedouelle J. Antetorsion of the femoral neck. *Rev Chir Orthop Reparatrice Appar Mot* 1982;68(1):5–13.
- [10] Phillips HO, et al. Measurement of femoral torsion: comparison of standard roentgenographic techniques with ultrasound. *J Pediatr Orthop* 1985;5(5):546–9.
- [11] Ruwe PA, et al. Clinical determination of femoral anteversion. A comparison with established techniques. *J Bone Joint Surg Am* 1992;74(6):820–30.
- [12] Wangermez J, Labarbe P. [Measurement of tibiofibular torsion with profile radiography. Relation to the shape of the plantar arch]. *Bull Assoc Anat (Nancy)* 1975;59(167):1013–7.
- [13] Hernandez RJ, et al. CT determination of femoral torsion. *AJR Am J Roentgenol* 1981;137(1):97–101.
- [14] Jend HH, et al. Measurement of tibial torsion by computer tomography. *Acta Radiol Diagn (Stockh)* 1981;22(3A):271–6.
- [15] Kristiansen LP, et al. The normal development of tibial torsion. *Skelet Radiol* 2001;30(9):519–22.
- [16] Moussa M. Rotational malalignment and femoral torsion in osteoarthritic knees with patellofemoral joint involvement. A CT scan study. *Clin Orthop Relat Res* 1994;304:176–83.
- [17] Sayli U, et al. Determination of tibial torsion by computed tomography. *J Foot Ankle Surg* 1994;33(2):144–7.
- [18] Seber S, et al. Rotational profile of the lower extremity and foot progression angle: computerized tomographic examination of 50 male adults. *Arch Orthop Trauma Surg* 2000;120(5–6):255–8.
- [19] Song HR, et al. Rotational profile of the lower extremity in achondroplasia: computed tomographic examination of 25 patients. *Skelet Radiol* 2006;35(12):929–34.
- [20] Strecker W, et al. Length and torsion of the lower limb. *J Bone Joint Surg Br* 1997;79(6):1019–23.
- [21] Yagi T. Tibial torsion in patients with medial-type osteoarthritic knees. *Clin Orthop Relat Res* 1994;302:52–6.
- [22] Yagi T, Sasaki T. Tibial torsion in patients with medial-type osteoarthritic knee. *Clin Orthop Relat Res* 1986;213:177–82.
- [23] Mettler Jr FA, et al. Effective doses in radiology and diagnostic nuclear medicine: a catalog. *Radiology* 2008;248(1):254–63.
- [24] Mueller DL, et al. Pediatric radiation exposure during the initial evaluation for blunt trauma. *J Trauma* 2011;70(3):724–31.
- [25] Gheno R, et al. Three-dimensional measurements of the lower extremity in children and adolescents using a low-dose biplanar X-ray device. *Eur Radiol* 2012;22(4):765–71.
- [26] Chaibi Y, et al. Fast 3D reconstruction of the lower limb using a parametric model and statistical inferences and clinical measurements calculation from biplanar X-rays. *Comput Methods Biomech Biomed Engin* 2012;15(5):457–66.
- [27] Dubouset J, et al. [Skeletal and spinal imaging with EOS system]. *Arch Pediatr* 2008;15(5):665–6.
- [28] Dubouset J, et al. [EOS stereo-radiography system: whole-body simultaneous anteroposterior and lateral radiographs with very low radiation dose]. *Rev Chir Orthop Reparatrice Appar Mot* 2007;93(6 Suppl):141–3.
- [29] Ilharborde B, et al. Angle measurement reproducibility using EOS three-dimensional reconstructions in adolescent idiopathic scoliosis treated by posterior instrumentation. *Spine (PhilaPa 1976)* 2011;36(20):E1306–13.
- [30] Kalifa G, et al. Evaluation of a new low-dose digital x-ray device: first dosimetric and clinical results in children. *Pediatr Radiol* 1998;28(7):557–61.
- [31] Presedo A, Bowen JR. Development of torsional and angular alignment analysis of deformity of the femur and tibia. *Orthopaedic care textbook*; 2005.
- [32] Staheli LT, Engel GM. Tibial torsion: a method of assessment and a survey of normal children. *Clin Orthop Relat Res* 1972;86:183–6.
- [33] Schneider B, et al. Measurement of femoral antetorsion and tibial torsion by magnetic resonance imaging. *Br J Radiol* 1997;70(834):575–9.
- [34] Hutchins PM, et al. Tibiofibular torsion in normal and treated clubfoot populations. *J Pediatr Orthop* 1986;6(4):452–5.
- [35] Folinais D, et al. Measuring femoral and rotational alignment: EOS system versus computed tomography. *Orthop Traumatol Surg Res* 2013;99:509–16.