



Science Arts & Métiers (SAM)

is an open access repository that collects the work of Arts et Métiers Institute of Technology researchers and makes it freely available over the web where possible.

This is an author-deposited version published in: <https://sam.ensam.eu>
Handle ID: [.http://hdl.handle.net/10985/20722](http://hdl.handle.net/10985/20722)

To cite this version :

Antonio GENNARI, Tristan LANGLAIS, Stéphane LITRICO, Sylvain PERSOHN, Jérôme ALLAIN, Wafa SKALLI - Biomechanical specimen assessment by low dose biplanar X-ray study of fusion constructions using a posterior lumbar cage with integrated anchors and posterior adjunctive fixators - Computer Methods in Biomechanics and Biomedical Engineering p.1-7 - 2021

Any correspondence concerning this service should be sent to the repository

Administrator : scienceouverte@ensam.eu



Biomechanical specimen assessment by low dose biplanar X-ray study of fusion constructions using a posterior lumbar cage with integrated anchors and posterior adjunctive fixators

A. Gennari^{a,b}, T. Langlais^{a,c}, S. Litrico^b, S. Persohn^a, J. Allain^d and W. Skalli^a

^aArts et Metiers ParisTech, Institut de Biomecanique Humaine Georges Charpak, Paris, France; ^bNeurosurgery, Spine Unit, CHU, Nice, France; ^cDépartement Othopédie Pédiatrique, Hôpital des Enfants, Purpan, Toulouse Université, France; ^dOrthopedic Surgery, Spine Unit, Clinique Geoffroy Saint-Hilaire, Paris, France

KEYWORDS

Lumbar spine; transfacet screw; interspinous anchor; spine biomechanics; arthrodesis

ABSTRACT

The objective was to compare L4/5 range of motions of fusion constructs using anchored cages. Twelve human cadaveric spine were tested in intact condition, and divided into TLIF and PLIF groups. Testing consisted in applying pure moments in flexion-extension, lateral bending and axial rotation. The computation of intersegmental motion was assessed using 3D biplanar radiographs. In TLIF group, the addition of contralateral transfacet decreased flexion-extension motion (39%; $p=0.036$) but without difference with the ipsilateral pedicle screw construction (53%; $p=0.2$). In PLIF group, the addition of interspinous anchor reduced flexion-extension motion (12%; $p=0.036$) but without difference with the bilateral pedicle screw construction (17%; $p=0.8$).

1. Introduction

Low back pain is a prevalent disorder, with occurrence rates varying between 60% and 90%. When disc degeneration associated with pain and functional limitations fails to respond to non-operative treatment, surgery such as lumbar fusion may be required to impend mobility and relieve symptoms (Fritzell et al. 2001). Interbody fusion using a cage is usually recommended for maintaining disc height, correcting segmental lordosis, and supporting bony fusion (Pavlov et al. 2004). Different surgical approaches are used to accomplish interbody fusion. Transforaminal lumbar interbody fusion (TLIF) and posterior lumbar interbody fusion (PLIF) approaches allow a direct access to neural elements. TLIF is accomplished via a unilateral foraminal approach, inserting one cage obliquely after external facetectomy (Harms and Jerszensky 1998). This technique can be used to remediate ipsilateral foraminal stenosis or lumbar herniation recurrence. Classic PLIF uses two posterior cages, requires in some cases a bilateral medial facetectomy, and remains widely used in cases of lumbar canal stenosis. Adjunctive posterior fixation is often required in addition to cages to provide immediate intersegmental stiffness. Bilateral pedicle screw (BPS) fixation still

remains the gold standard because of the superior stiffness it provides (Gerber et al. 2006), but this is technically demanding and may be associated with high complication rates (Esses et al. 1993). Additionally, placement of the upper pedicle screw near the facet joint surface is closely related to adjacent segment degeneration (Heo et al. 2015). Therefore, a need exists for a posterior spinal stabilization method that requires less invasive surgical exposure for their implantation. Transfacet screws (TFS) and interspinous anchors (ISA) are posterior stabilization implants that have gained popularity because of decreased surgical exposure upon implantation. Facet fixation with TFS is either an alternative for primary fusion or an augmentation to an interbody fusion and is associated with decreased cost, smaller incisions, and less morbidity. TFS can augment TLIF procedures; however, TFS cannot be implanted after a PLIF procedure, as the facet joints must remain intact. Alternatively, ISAs have gained increased acceptance as posterior stabilization devices because of reduced disruption of paraspinal musculature and reduced risk of damage to neural and vascular elements. ISA implants can be used to augment PLIF, TLIF, and anterior cages.

Table 1. Group description (mean and range).

Group	Age (years)	Gender	BMD (mg/cm ³)	Disc height (mm)
TLIF group (n = 6)	58.2 (51 – 64)	5 M/1F	102.8 (66 – 171)	9.8 (7.5 – 12.7)
PLIF group (n = 6)	59.2 (57 – 65)	4 M/2F	98.9 (75 – 124)	10.1 (8.0 – 15.0)

The purpose of this study was to investigate the biomechanical behavior of TLIF and PLIF constructs using an original interbody cage with integrated anchors. This cage was tested alone and with less invasive adjunctive posterior fixator, either TFS for TLIF or ISA for PLIF. The behavior of these TFS and ISA fixators were compared with those of traditional pedicle screws. On the other hand, we used an original biomechanical test bench including low dose biplanar X-rays system in order to compute intersegmental motion.

2. Materials and methods

2.1. Specimens preparation

Twelve fresh human cadaveric lumbar spine (donor average age 58.7 years [45–65 years], 9 males, 3 females) segments from L3 to the sacrum were obtained from accredited sources for biomechanical testing. Prior to biomechanical testing, bone mineral quality was assessed via a quantitative computed tomography scan and a calibration phantom (Electron density phantom model 062; CIRS ink, Norfolk Virginia). Each specimen was preserved in a sealed double storage bag at -22°C until preparation. Specimens were thawed for 12 h at 23°C ; all muscles were excised, keeping all the osseoligamentous and disc structures intact. Then, five radio-opaque fiducial markers (2 mm-diameter steel balls) were fixed on the L4 and L5 vertebrae to obtain a triaxial geometrical frame of reference for each vertebra. A pedicle clamp was fixed to the L3 vertebra, and the sacrum was reinforced with wood screws and embedded in a block of polymethyl methacrylate (PMMA). Specimens were regularly sprayed during testing with 0.9% saline solution to prevent desiccation.

2.2. Study protocol

All specimens were biomechanically tested in the intact condition to establish a baseline mechanical response (INTACT). Then, specimens were separated into two groups (TLIF Group and PLIF Group) by a stratified randomization on confounding factors (BMD, age, sex). Group characteristics are detailed in Table 1. Test conditions assigned to each group are detailed in Table 2 and described below. Including the INTACT, TLIF Group

Table 2. Test conditions description (TFS: transfacet screws; ISA: interspinous anchors; BPS: bilateral pedicle screws; IPS: ipsilateral pedicle screw).

Test condition	TLIF group	PLIF group
INTACT	Intact	Intact
INSTR1	1 TLIF cage with integrated fixation	2 PLIF cages with integrated fixation
INSTR2	INSTR1 + contralateral TFS	INSTR1 + ISA
INSTR3	INSTR1 + BPS	INSTR1 + BPS
ISNTR4	INSTR1 + IPS	N/A

samples underwent five test conditions, and PLIF Group samples underwent four test conditions. Treatment devices used in test conditions for both groups are depicted in Figure 1. In the TLIF Group, a lumbar lordotic PEEK cage with anchor (Avenue® T and VerteBRIDGE®, LDR Medical, France) was inserted obliquely at L4-L5 through an extraforaminal approach and right lateral facetectomy and was tested (INSTR1). Subsequently, a contralateral transfacet screw (TFS) (FacetBRIDGE™, LDR Medical, France) was added according to Boucher's technique (Boucher, 1959) and tested (INSTR2) (Figure 2a). Then, the TFS was removed, and bilateral pedicle screws (BPS) (Spine Tune® TL, LDR Medical, France) were implanted and tested (INSTR3). Finally, the contralateral pedicle screw was removed, leaving the ipsilateral pedicle screw (IPS) unaltered for the final test (INSTR4). In the PLIF Group, specimens underwent bilateral laminotomy and medial facetectomy, preserving spinous processes and supraspinous ligaments. Two lumbar lordotic PEEK cages with integrated anchors (Avenue® T and VerteBRIDGE®, LDR Medical, France) were inserted in the L4-L5 space and tested (INSTR1). Following this, an interspinous anchor (ISA) (InterBRIDGE®, LDR Medical, France) was implanted and tested (INSTR2). The ISA was then removed and BPS (Spine Tune® TL, LDR Medical, France) were implanted and tested (INSTR3).

2.3. Biomechanical testing

Each specimen underwent two pre-conditioning loading cycles and one data collection loading cycle. The cycles were comprised of pure moments applied about the flexion-extension, lateral bending, and axial rotation axes with no axial pre-load. Each loading cycle started from 0 to 7.5 Nm (Wilke et al. 1998) with loading increments of 1.5 Nm. Motion was governed via load control using a six-axis load cell (FTD-Gamma SI-130-10, ATI Industrial Automation, USA) and a motor (Gearmotor 3242G024C, FAULHABER,

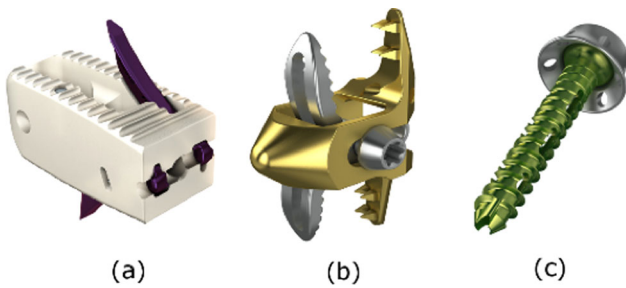


Figure 1. Implants used. (a) lumbar cage with integrated anchor (Avenue® T); (b) Interspinous anchor (ISA, InterBRIDGE®); (c) Transfacet screw (TFS, FacetBRIDGE™).

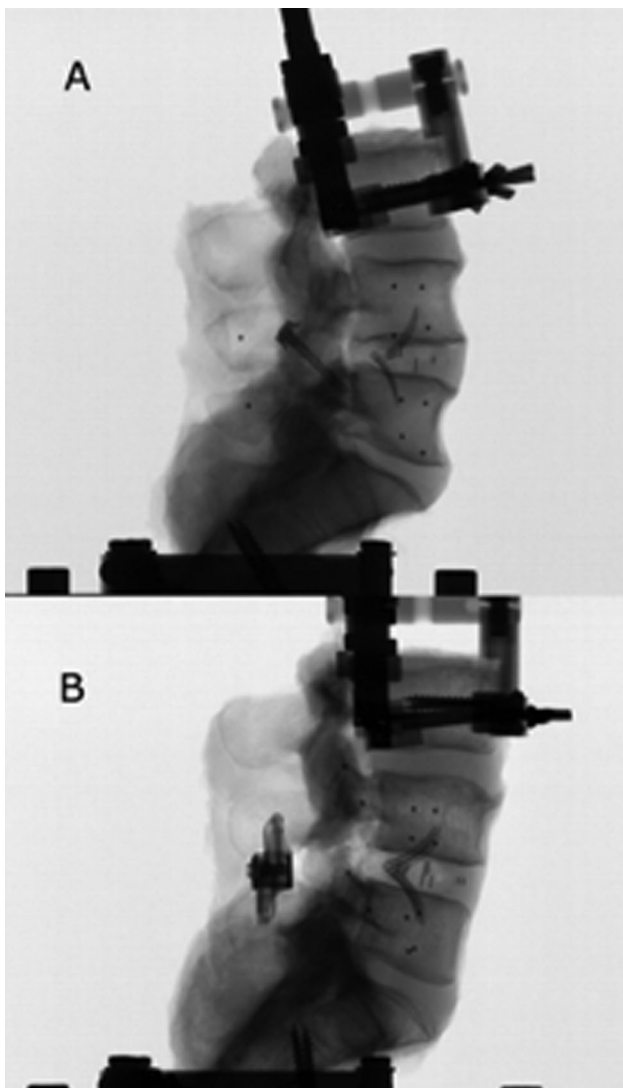


Figure 2. Two examples of instrumented configurations. (a) INSTR2 TLIF Group (anchored posterior lumbar cage with contralateral TFS); (b) INSTR2 PLIF Group (2 anchored posterior lumbar cages with ISA).

France) rigidly connected to the pedicle clamp at the L3 vertebra. If presents, coupled motions are allowed by the system.




Figure 3. Test bench integrated in EOS system with lumbar specimen loaded.

2.4. Specimen motion analysis

To analyze specimen's motion as a result of the moments applied, the test bench was integrated into a biplanar X-rays system (EOS® system, EOS Imaging, Paris, France) (Figure 3). Biplanar radiographic images of the specimens in the initial neutral unloaded position allowed both 3D reconstruction of each vertebra, according to the method previously described (Humbert et al. 2009), and 3D marker assessment, allowing registration of the marker coordinate frame to the anatomic vertebral frame. The initial solution was calculated automatically by statistical inference and image analysis. The resulting 3D reconstructed vertebrae were retro-projected on the front and side X-ray. The operator needed to adjust manually about 20 points of vertebral contours for each vertebra. Each reconstruction took 15 min, and the operator was skilled (i.e., 40 reconstructions beforehand). The software was a research version of STEREOS software (EOS Imaging; France). Then, biplanar radiographic images were acquired at each loading increment in order to track markers and accurately compute L4–L5 intersegmental motion. All translational and rotational components of the L4–L5

Table 3. Comparison of normalized range of motion (RoM) between conditions for each group.

Group	Motion	Normalized RoM (% of intact)			
		INSTR1	INSTR2	INSTR3	INSTR4
TLIF	Flexion-Extension	79 ± 26	39 ± 10 ^{*,†}	23 ± 14 ^{*,†}	53 ± 25 ^{*,◇}
	Lateral Bending	102 ± 25	67 ± 13 ^{*,†}	17 ± 8 ^{*,†,‡}	63 ± 16 ^{*,†}
	Axial Rotation	103 ± 40	55 ± 22 [†]	42 ± 23 ^{*,†}	81 ± 37 [◇]
PLIF	Flexion-Extension	70 ± 22 [*]	12 ± 4 ^{*,†}	17 ± 12 ^{*,†}	N/A
	Lateral Bending	86 ± 26	79 ± 23	18 ± 7 ^{*,†,‡}	N/A
	Axial Rotation	170 ± 95	93 ± 30 [†]	49 ± 23 [†]	N/A

Values are Mean ± SD.

^{*}, [†], [‡], [◇] represent the significant differences, respectively, with Intact, Instr1, Instr2 and Instr3 condition.

intersegmental motion were calculated by measuring the relative displacement of the radio-opaque fiducial markers of L4 with respect to L5. This method was used to compute the behavior of lower cervical spine: reproducibility tests estimated 95% confidence intervals of 0.02° on vertebral rotation and up to 0.02 mm on facet displacements (Muth-Seng et al. 2019).

2.5. Data analysis

Angular rotation ranges of motion (RoM) were computed for each configuration and each loading case. RoM were normalized to intact configuration and expressed in percentage of intact RoM. The coupled motions were also assessed. A Shapiro-Wilk statistical test ($\alpha=0.01$) was used to test normality of the samples. Then, for each group, an ANOVA ($\alpha=0.05$) was used to compare the normalized RoM or coupled motions between test conditions with post hoc multi-comparison tests performed using a Tukey test ($\alpha=0.05$).

3. Results

We did not observe any fracture, screw loosening or device failure during the study.

3.1. TLIF group

TLIF results are presented in Table 3 and Figure 4. The cage with integrated anchors (INSTR1) lowered RoM in FE when compared to the INTACT (79%; $p=0.29$). Mean increases in LB and AR were lower than 4° (102% for LB and 103% for AR; $p=0.67$ and 0.52, respectively). The addition of contralateral TFS (INSTR2) significantly decreased RoM for FE and LB compared to INTACT, (FE: 39% and LB: 67%; $p=0.036$ for each measure). Also, compared to the INSTR1, INSTR2 significantly reduced RoM in FE,

LB and AR ($p<0.05$). The lowest normalized RoM were observed with the BPS (INSTR3) with significant differences with INTACT and INSTR1 for all rotations ($p<0.05$). Compared to the TFS (INSTR2), INSTR3 presented a significant decrease of RoM only in LB (17%; $p=0.04$). Finally, contralateral TFS (INSTR2) compared to ipsilateral pedicle screw (IPS) (INSTR4) lowered RoM in FE (39% vs. 53%; $p=0.2$) and in AR (55% vs. 81%; $p=0.14$). In LB coupled to the EF, RoM was increased by 60% in the INSTR3 comparatively other INSTR ($p=0.03$).

3.2. PLIF group

PLIF results are presented in Table 3 and Figure 5. The cages with integrated anchors (INSTR1) lowered significantly RoM in FE compared to INTACT, (70%; $p=0.045$). The increased RoM in AR (170%) should be noticed. The addition of ISA (INSTR2) significantly reduced RoM from the fixed cage alone (INSTR1) in all FE and AR (FE: 12% vs. 70%, AR: 93% vs. 170%; $p=0.036$ and 0.034, respectively). BPS configuration (INSTR3) significantly reduced RoM in LB when compared to ISA construct (INSTR2) (18% vs. 79%; $p=0.036$). In AR coupled to the EF, RoM was reduced by 60% in the INSTR 3 configuration compared to the other configurations ($p=0.02$).

4. Discussion

This study investigated the immediate stiffness of posterior lumbar fusion constructs using a biomechanical testing device integrated in an EOS X-ray system. The aimed at comparing the biomechanical behavior of an original PEEK anchored cages in TLIF or PLIF constructs in association with less invasive adjunctive posterior fixators (TFS and ISA) with classical bilateral pedicle screws. Both contralateral TFS with a TLIF cage and ISA with PLIF cages succeed in reduction flexion-extension intervertebral motion compared to intact condition and cages alone. They also showed equivalent outcomes compared to bilateral pedicle screws in reducing flexion-extension intervertebral motion. On the other hand, EOS® system was recently used to compute cervical (Muth-Seng et al. 2019) and thoracic spine (Gaume et al. 2020) behavior but this is the first in vitro biomechanical study using this kind of test bench to assess lumbar spine range of motions. This protocol ensured the accuracy of motion tracking and also avoid optical markers which can comes into contact with each other's during larges movements. Using a TLIF cage, Chin et al.

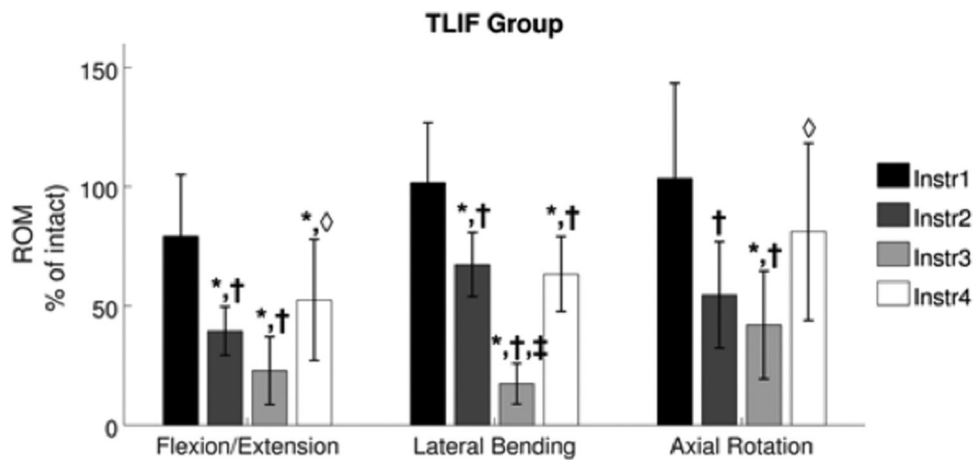


Figure 4. Mean and standard deviation of normalized ranges of motion (RoM) during flexion-extension, lateral bending and axial rotation loading for TLIF Group. ($n = 6$ specimens/bar). *: Significant difference with Intact; †: Significant difference with Instr1; ‡: Significant difference with Instr2; ♦: Significant difference with Instr3.

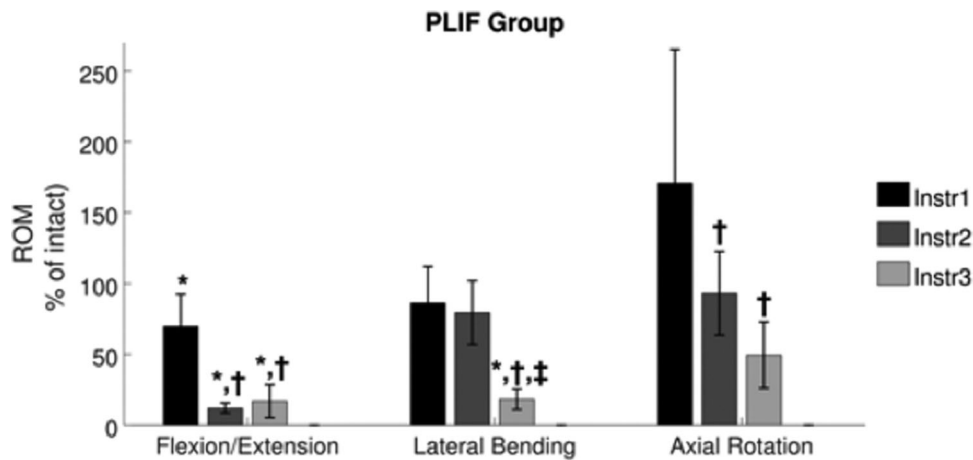


Figure 5. Mean and standard deviation of normalized ranges of motion (RoM) during flexion-extension, lateral bending and axial rotation loading for PLIF Group. ($n = 6$ specimens/bar). *: Significant difference with Intact; †: Significant difference with Instr1; ‡: Significant difference with Instr.

(2015) found bilateral TFS provided greater stiffness than BPS in all directions of motion except in lateral bending (Beaubien et al. 2004). However, it was for a bilateral implantation and not a contralateral one. Also, TFS augmenting ALIF lowered motion as much as BPS configurations in all modes for bilateral TFS implantation as well as bilateral translaminar implantation (Beaubien et al. 2004). Contralateral TFS implantation was performed in the current study through an ipsilateral approach according to Boucher's technique (Beoucher 1959). This procedure permits minimally invasive surgery to avoid muscle disruption and could represent an alternative to the pedicle screws. An alternative posterior fixation for TLIF could be ipsilateral pedicle screw in order to minimize muscle disruption with satisfying clinical and radiological results (Chen et al. 2018). Nevertheless, RoM are lower for the TFS in FE and

AR and almost similar in LB. Generally, less rigid construct like posterior hybrid fixation succeed in achieving fusion (Korovessis et al. 2004): IPS constructs providing a high fusion rate (Giorgi et al. 2018), those biomechanical results are suggesting a strong ability of the TFS construct to fuse. To our knowledge, there is no clinical or biomechanical study evaluating unilateral TFS with TLIF construct which could be an interesting option to achieve fusion. ISA is another less-invasive posterior technique to enhance posterior interbody fusion. Addition of an ISA in the PLIF group significantly reduced RoM in FE compared to intact and PLIF cages alone. Compared to BPS, this type of fixation provided similar motion reduction in FE but not in LB and AR. These results are in agreement with those observed for ALIF (Kornblum et al. 2013), PLIF (Phan et al. 2016) or TLIF (Kaibara et al. 2010; Tegy et al. 2013).

Stand-alone constructs with anchored cage succeeded in reducing RoM compared to intact conditions only in flexion-extension for PLIF. This is in agreement with the literature as no biomechanical studies have demonstrated stabilizing effects of stand-alone posterior implants: TLIF cage with integrated screws (Keiler et al. 2014) or expandable PLIF cage (Bhatia et al. 2012; Soriano-Baron et al. 2018) did not succeed in reducing RoM as stand-alone construct. Several clinical studies have investigated stand-alone posterior cage and found good clinical outcomes for TLIF approaches (Kotil et al. 2013) as well as PLIF approaches (Van del Kelft and Van Goethem 2015). However, authors reported high subsidence rate, loss of disc height and loss of lumbar lordosis in their radiological findings (Lequin et al. 2014). For those reasons, posterior fixation remains recommended in case of posterior cage even with integrated fixation. The potential utility of such fixation is more to avoid device migration and micro-mobility than a real segmental stabilization. Instrumentation of the degenerative spine aims at lowering spinal mobility by increasing spinal stiffness to achieve spinal fusion. The underlying question is how stiff is stiff enough to guarantee the arthrodesis. Concerning clinical studies, ISA combined with PLIF seems to be an effective technique to treat degenerative disc disease. It provides good clinical outcomes (Kim et al. 2012) and can also achieve fusion which rate varies from 85 to 92.5% (Kim et al. 2012; Chen and Chen 2017). This technique could also avoid adjacent segment disease when compare to BPS (Kim et al. 2012). One of the limitations of this model relates to the *in vitro* nature of the evaluation, which does not include the stiffness provided by the lumbar spine musculature. Although follower loads may be proposed to mimic muscle effects, it remains controversial because of the sensitivity to its placement. Furthermore, it has been demonstrated that there is no significant change in lumbar spine RoM with or without axial pre-load (Schilling et al. 2014). Another limitation of our study is that we did not perform an analysis of adjacent segments according to the different instrumentations. It is well studied that the facet and disc constraints of the adjacent segments are disturbed after arthrodesis (Cheh et al. 2007; Zhou et al. 2021).

5. Conclusion

The configurations, using fixed posterior lumbar cages in addition with transfacet screws or interspinous anchors, reduced RoM in flexion-extension when

compared to the intact condition. Pedicle screws gave more stability when assessing lateral bending and axial rotation. Nevertheless, fixed posterior lumbar cages in addition with transfacet screws or interspinous anchors could provide an interesting alternative to the classic bilateral pedicle screws approach in some cases.

Disclosure statement

Stephane Litrico and Jerome Allain reports grants from for Zimmer Biomet, outside the submitted work. Antoine Gennari, Tristan Langlais, Sylvain Persohn, Wafa Skalli declare no potential conflict of interest.

Funding

LDR Medical, now part of Zimmer Biomet provided financial and technical support for the conduct of the research.

References

- Beaubien BP, Mehbod AA, Kallemeier PM, Lew WD, Buttermann GR, Transfeldt EE, Wood KB. 2004. Posterior augmentation of an anterior lumbar interbody fusion: minimally invasive fixation versus pedicle screws in vitro. *Spine*. 29(19):E406–E412.
- Bhatia NN, Lee KH, Bui CN, Luna M, Wahba GM, Lee TQ. 2012. Biomechanical evaluation of an expandable cage in single-segment posterior lumbar interbody fusion. *Spine*. 37(2):E79–E85.
- Boucher HH. 1959. A method of spinal fusion. *J Bone Joint Surg Br*. 41-B(2):248–259.
- Cheh G, Bridwell KH, Lenke LG, Buchowski JM, Daubs MD, Kim Y, Baldus C. 2007. Adjacent segment disease following lumbar/thoracolumbar fusion with pedicle screw instrumentation: a minimum 5-year follow-up. *Spine (Phila Pa 1976)*. 32(20):2253–2257.
- Chen MH, Chen JY. 2017. A Novel Non pedicular Screw-Based Fixation in Lumbar Spondylolisthesis. *BioMed Res Int*. :5619350.
- Chen DJ, Yao C, Song Q, Tang B, Liu X, Zhang B, Dai M, Nie T, Wan Z. 2018. Unilateral versus bilateral pedicle screw fixation combined with Transforaminal Lumbar Interbody Fusion for the treatment of low lumbar degenerative disc diseases: Analysis of clinical and radiographic results. *World Neurosurg*. 115:e516–e522.
- Chin KR, Reis MT, Reyes PM, Newcomb AG, Neagoe A, Gabriel JP, Sung RD, Crawford NR. 2015. Stability of transforaminal lumbar interbody fusion in the setting of retained facets and posterior fixation using transfacet or standard pedicle screws. *Spine J*. 15(5):1077–1082.
- Esses SI, Sachs BL, Dreyzin V. 1993. Complications associated with the technique of pedicle screw fixation. A selected survey of ABS members. *Spine (Phila Pa 1976)*. 18(15):2231–2239.
- Fritzell P, Hägg O, Wessberg P, Nordwall A, Swedish Lumbar Spine Study Group. 2001. 2001 Volvo Award Winner in Clinical Studies: Lumbar fusion versus

- nonsurgical treatment for chronic low back pain: a multicenter randomized controlled trial from the Swedish Lumbar Spine. Study Group. *Spine*. 26(23):2521–2534.
- Gaume M, Persohn S, Vergari C, Glorion C, Skalli W, Miladi L. 2020. Biomechanical cadaver study of proximal fixation in a minimally invasive bipolar construct. *Spine Deform*. 8(1):33–38.
- Gerber M, Crawford NR, Chamberlain RH, Fifield MS, LeHuec JC, Dickman CA. 2006. Biomechanical assessment of anterior lumbar interbody fusion with an anterior lumbosacral fixation screw-plate: comparison to stand-alone anterior lumbar interbody fusion and anterior lumbar interbody fusion with pedicle screws in an unstable human cadaver model. *Spine*. 31(7):762–768.
- Giorgi H, Prebet R, Andriantsimiavona R, Tropiano P, Blondel B, Parent HF. 2018. Minimally invasive transforaminal lumbar interbody fusion with unilateral pedicle screw fixation (UNILIF): morbidity, clinical and radiological 2-year outcomes of a 66-patient prospective series. *Eur Spine J*. 27(8):1933–1939.
- Harms JG, Jeszenszky D. 1998. Die posteriore, lumbale, interkorporelle Fusion in unilateraler transforaminaler Technik. *Orthop Traumatol*. 10(2):90–102.
- Heo Y, Park JH, Seong HY, Lee YS, Jeon SR, Rhim SC, Roh SW. 2015. Symptomatic adjacent segment degeneration at the L3-4 level after fusion surgery at the L4-5 level: evaluation of the risk factors and 10-year incidence. *Eur Spine J*. 24(11):2474–2480.
- Humbert L, De Guise JA, Aubert B, Godbout B, Skalli W. 2009. 3D reconstruction of the spine from biplanar X-rays using parametric models based on transversal and longitudinal inferences. *Med Eng Phys*. 31(6):681–687.
- Kaibara T, Karahalios DG, Porter RW, Kakarla UK, Reyes PM, Choi SK, Yaqoobi AS, Crawford NR. 2010. Biomechanics of a lumbar interspinous anchor with transforaminal lumbar interbody fixation. *World Neurosurg*. 73(5):572–577.
- Keiler A, Schmoelz W, Erhart S, Gnanalingham K. 2014. Primary stiffness of a modified transforaminal lumbar interbody fusion cage with integrated screw fixation: cadaveric biomechanical study. *Spine*. 39(17):E994–E1000.
- Kim HJ, Bak KH, Chun HJ, Oh SJ, Kang TH, Yang MS. 2012. Posterior interspinous fusion device for one-level fusion in degenerative lumbar spine disease: comparison with pedicle screw fixation - preliminary report of at least one year follow up. *J Korean Neurosurg Soc*. 52(4):359–364.
- Kornblum MB, Turner AW, Cornwall GB, Zatushevsky MA, Phillips FM. 2013. Biomechanical evaluation of stand-alone lumbar polyether-ether-ketone interbody cage with integrated screws. *Spine J*. 13(1):77–84.
- Korovessis P, Papazisis Z, Koureas G, Lambiris E. 2004. Rigid, semirigid versus dynamic instrumentation for degenerative lumbar spinal stenosis: a correlative radiological and clinical analysis of short-term results. *Spine*. 29(7):735–742.
- Kotil K, Ali Akçetin M, Savaş Y. 2013. Clinical and radiologic outcomes of TLIF applications with or without pedicle screw: a double center prospective pilot comparative study. *J Spin Disord Tech*. 26(7):359–366.
- Lequin MB, Verbaan D, Bouma GJ. 2014. Posterior lumbar interbody fusion with stand-alone Trabecular Metal cages for repeatedly recurrent lumbar disc herniation and back pain. *SPI*. 20(6):617–622.
- Muth-Seng C, Brauge D, Soriau N, Sandoz B, Van den Abbeele M, Skalli W, Laporte S. 2019. Experimental analysis of the lower cervical spine in flexion with a focus on facet tracking. *J Biomech*. 93:220–225.
- Pavlov PW, Meijers H, van Limbeek J, Jacobs WC, Lemmens JA, Obradov-Rajic M, de Kleuver M. 2004. Good outcome and restoration of lordosis after anterior lumbar interbody fusion with additional posterior fixation. *Spine (Phila Pa 1976)*. 29(17):1893–1900.
- Phan K, Leung V, Scherman DB, Tan AR, Rao PJ, Mobbs RJ. 2016. Bilateral versus unilateral instrumentation in spinal surgery: Systematic review and trial sequential analysis of prospective studies. *J Clin Neurosci*. 30:15–23.
- Schilling C, Pfeiffer M, Grupp TM, Blömer W, Rohlmann A. 2014. The effect of design parameters of interspinous implants on kinematics and load bearing: an in vitro study. *Eur Spine J*. 23(4):762–771.
- Soriano-Baron H, Newcomb AGUS, Malhotra D, Palma AE, Jr, Martinez-Del-Campo E, Crawford NR, Theodore N, Kelly BP, Kaibara T. 2018. Biomechanical Analysis of an Expandable Lumbar Interbody Spacer. *World Neurosurg*. 114:e616–e623.
- Techy F, Mageswaran P, Colbrunn RW, Bonner TF, McLain RF. 2013. Properties of an interspinous fixation device (ISD) in lumbar fusion constructs: a biomechanical study. *Spine J*. 13(5):572–579.
- Van de Kelft E, Van Goethem J. 2015. Trabecular metal spacers as standalone or with pedicle screw augmentation, in posterior lumbar interbody fusion: a prospective, randomized controlled trial. *Eur Spine J*. 24(11):2597–2606.
- Wilke HJ, Wenger K, Claes L. 1998. Testing criteria for spinal implants: recommendations for the standardization of in vitro stability testing of spinal implants. *Eur Spine J*. 7(2):148–154.
- Zhou C, Cha T, Wang W, Guo R, Li G. 2021. Investigation of Alterations in the Lumbar Disc Biomechanics at the Adjacent Segments After Spinal Fusion Using a Combined In Vivo and In Silico Approach. *Ann Biomed Eng*. 49(2):601–616.