



### **Science Arts & Métiers (SAM)**

is an open access repository that collects the work of Arts et Métiers Institute of Technology researchers and makes it freely available over the web where possible.

This is an author-deposited version published in: <https://sam.ensam.eu>  
Handle ID: <http://hdl.handle.net/10985/20781>

#### **To cite this version :**


Youngwoo KIM, Aidin Eslam POUR, Jean Yves LAZENNEC - How do global sagittal alignment and posture change after total hip arthroplasty? - International Orthopaedics - Vol. 44, n°2, p.267-273 - 2019

Any correspondence concerning this service should be sent to the repository

Administrator : [scienceouverte@ensam.eu](mailto:scienceouverte@ensam.eu)



# How do global sagittal alignment and posture change after total hip arthroplasty?

Youngwoo Kim<sup>1,2,3,4</sup> · Aidin Eslam Pour<sup>5</sup>  · Jean Yves Lazennec<sup>1,2</sup>

## Abstract

**Background** Postural change after total hip arthroplasty (THA) is still a matter of discussion. Previous studies have mainly concentrated on the pelvic motions. We report the post-operative changes of the global sagittal posture using pelvic, spinal, and lower extremities parameters.

**Methods** 139 patients (primary THA, without previous spinal or lower extremity surgery) were included. We measured pelvic parameters [SS, sacral slope; PI, pelvic incidence; PT, pelvic tilt; APP angle, anterior pelvic plane angle] and the global posture parameters (SVA, sagittal vertical angle; GSA, global sagittal angle; TPA, T1 pelvic angle). Patients were categorized into low PI group  $< 45^\circ$ ,  $45^\circ < \text{medium PI} < 65^\circ$ , and high PI  $> 65^\circ$ .

**Results** Mean GSA and SVA decreased post-operatively ( $p = 0.005$  and  $p = 0.004$  respectively). The TPA change was not significant ( $p = 0.078$ ). In the low PI group, GSA ( $5.4 \pm 5.0$  to  $4.3 \pm 4.0$ ,  $p = 0.005$ ) and SVA ( $5.4 \pm 4.9$  to  $4.2 \pm 4.1$ ,  $p = 0.038$ ) decreased with more posterior pelvic tilt. Post-operative TPA was significantly higher ( $8.4 \pm 10.6$  to  $9.8 \pm 10.7$ ;  $p = 0.048$ ). In the medium PI group, SVA decreased ( $4.2 \pm 4.6$  to  $3.6 \pm 4.5$ ,  $p = 0.020$ ) with more posterior pelvic tilt. In the high PI group, pelvic and global posture parameters did not evolve significantly.

**Conclusion** PI is the key determining factor in pelvic tilt modification after THA. Patients with low PI demonstrate significant modification in spine, pelvic, and lower extremities. Pelvic tilt is the main adaptation mechanism for medium incidence patients whereas pelvic tilt does not change in high PI patients after surgery.

**Keywords** Total hip arthroplasty · Pelvic incidence · Post-operative posture change

## Introduction

Human posture has evolved to give us the upright pose in standing and sitting as bipedal mammals. The goal of this posture is to have a forward facing head and gaze. This posture is reproduced by complex work of the different muscles in the vertebrae, pelvis and lower extremity joints. Any pathology at any level of this system can cause limitation in the adaptive movement of the particular joint or vertebrae and difficulty with achieving the desired posture. This posture can be affected by severe hip degenerative joint disease (DJD) due to flexion and external rotation contracture. This results in anterior pelvic tilt due to the flexion contracture which will require some degrees of knee flexion to compensate. Literature about postural changes after total hip arthroplasty (THA) mainly concentrates on pelvic tilt. While some authors reported improvement in spinal alignment [1, 2] and spine-related problems such as low back pain [3] after THA, other studies reported that spinal sagittal alignment did not change post-operatively [4–8]. However, the precise

---

✉ Aidin Eslam Pour  
aeslampo@med.umich.edu

Youngwoo Kim  
woochan76@hotmail.co.jp

Jean Yves Lazennec  
lazennec.jy@wanadoo.fr

<sup>1</sup> Department of Orthopaedic and Trauma Surgery, Pitié-Salpêtrière Hospital, Assistance Publique-Hôpitaux de Paris, Paris, France

<sup>2</sup> Anatomy Department Faculté Pitié-Salpêtrière, Médecine Sorbonne Université, Paris, France

<sup>3</sup> Institut de Biomécanique Humaine Georges Charpak, Arts et Métiers Paris Tech, Paris, France

<sup>4</sup> Department of Orthopaedic Surgery, Graduate School of Medicine, Kyoto University, Kyoto, Japan

<sup>5</sup> Department of Orthopaedic Surgery, University of Michigan, 2912 Taubman Center, SPC 5328, 1500 E. Medical Center Dr., Ann Arbor, MI 48109, USA

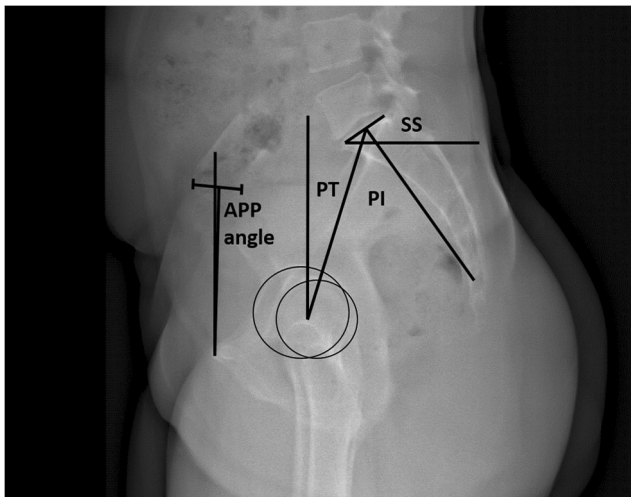
cause of controversial issue of postural change after THA remains unknown. Difference in assessment methods among investigators, ignoring the effect of the lower extremities on posture and complete focus on the variation of pelvic tilt alone can be considered as possible reasons for this discrepancy.

The pelvic incidence (PI) is considered a constant morphologic parameter with minimal changes after puberty [9, 10]. PI is defined as the angle between the line vertical to the sacral plate and the line that connects the middle of the sacrum and the femoral head axis (Fig. 1). The PI is unique for each patient. Variation of PI may lead to different patterns of pelvic compensation during daily activities [11]. The relationship between PI and posture after THA has not been well investigated in previous studies despite its potential importance in post-operative postural change. The EOS imaging system provides new opportunities regarding the global spinal and lower extremities alignment and evolution. It also provides valuable information regarding the lower limb function and pelvic motions in different functional positions [12, 13].

The purpose of this study was to evaluate the post-operative changes of the global sagittal posture using spinal and lower extremity parameters in patients with severe unilateral hip osteoarthritis (OA) using EOS imaging. We hypothesized that the patients with low PI have a limited ability of pelvic adaptation and need greater compensation using spinal and lower extremity compensatory mechanisms.

## Materials and methods

After obtaining Institutional Review Board approval, we retrospectively included 139 consecutive patients (66 female, 73 male) between June 2011 and June 2016. Table 1 shows the demographics of the patients. All patients had primary



**Fig. 1** Lateral EOS imaging of the pelvis in standing position. Illustration of the pelvic parameters. SS, sacral slope; PT, pelvic tilt; PI, pelvic incidence; APP, anterior pelvic plane

**Table 1** Demographics of the patients. The patients were divided into three groups, based on their PI: PI < 45° (low PI), 45° < PI < 65° (medium PI), and PI > 65° (high PI)

	Total	Subgroup		
		Low PI	Medium PI	High PI
Number of patients	139	24	82	33
Gender (M/F)	66/73	13/11	39/43	14/19
Age	65.3	60.4	66.4	66.3

PI, pelvic incidence; M, male; F, female

unilateral THA for symptomatic, unilateral hip osteoarthritis due to severe hip DJD. All patients with symptomatic spinal pathology, limb length discrepancy more than 10 mm, previous spinal surgery, and/or any lower extremity surgeries other than primary total hip arthroplasty (open reduction and internal fixation, osteotomy, or arthroplasty) were excluded. The patients underwent elective THA via direct anterior, posterior, or modified Watson-Jones anterolateral approaches (without violating the Gluteus Medius). All patients received cementless implants. The patients were divided into three groups, based on their PI: PI < 45° (low PI), 45° < PI < 65° (medium PI), and PI > 65° (high PI), as shown in Table 1 [14].

All patients underwent pre- and post-operative standing full-body biplanar EOS imaging. EOS acquisitions were performed in a way that maintained the natural standing position of the spine, pelvis, and lower extremities [15]. EOS images were obtained before the THA and also after patients had achieved normal gait and kinematics and were able to stand without assistance and pain following hip arthroplasty (average of 7 months; range 3–12 months). The simultaneous biplanar acquisition was used to perform stereoradiographic 3D modeling of spine, pelvis and lower extremities using specialized software (sterEOS 3D; EOS imaging SA) [15]. We measured pelvic parameters [sacral slope (SS), pelvic incidence (PI), pelvic Tilt (PT), anterior pelvic plane angle (APP angle)] (Fig. 1) and the global posture parameters [sagittal vertical angle (SVA), global sagittal angle (GSA), T1 pelvic angle (TPA)]. SS was defined as the angle between the horizontal plane and the upper endplate of S1. PI was defined as the angle between the line perpendicular to the middle of the superior endplate of S1 and the line joining this point to the bicoxofemoral axis [11]. PT was defined as the angle between the vertical plane and the line joining the middle of the upper endplate of S1 with the bicoxofemoral axis. APP angle was defined as the angle between the vertical line and the APP (the APP line corresponded to the line between the pubis symphysis and the midpoint between the two anterior superior iliac crests) [16]. Anterior orientation of the APP was defined as positive angle, posterior orientation was defined as negative angle [17]. SVA was defined as horizontal distance between the vertical line from C7 and the posterosuperior corner of S1

[18]. The changes in SS and APP were considered positive if the pelvis tilted anteriorly and negative if the pelvis was tilted posteriorly. GSA was defined as the angle between the centre of C7 and the middle of the femoral condyles and posterosuperior corner of S1 [19]. TPA was defined as the angle between the centre of T1, the center of the femoral heads and the centre of S1 [20]. TPA combines information of both the spine and the pelvic alignment, while GSA includes the compensatory movements of the lower limbs and knee joints.

## Statistical analysis

Statistical analyses were performed with Stata 14.1 (StataCorp LP, College Station, TX). Repeatability and reproducibility were assessed by calculating the interobserver and intra-observer intraclass correlation coefficient (ICC) and its 95% confidence interval (CI). Quantitative variables were described using the mean, mean difference, standard deviation (SD), and ICC with its 95% CI. Normal distribution of the values was checked by means of the Shapiro-Wilk normality test for each series of measurements. The paired Student t test and ANOVA were used for analysis. The significance level was set at less than 0.05.

## Results

The detailed data are presented in Tables 1, 2, and 3. There was no significant difference between the three subgroups in the demographics. In the analysis of all patients regardless of their PI, there were significant differences in pelvic parameters (SS, PT) and global posture parameters (SVA, GSA) after THA. After THA, the mean SS decreased from  $42.9^\circ \pm 11.6$

**Table 2** Comparison of pre-operative and post-operative pelvic and posture parameters among all study patients

	Pre-operative	Post-operative	<i>p</i> value
<b>Pelvic parameters</b>			
SS (°)	42.9 ± 11.6	41.3 ± 12.2	< 0.001*
PT (°)	14.5 ± 10.4	16.6 ± 10.3	< 0.001*
PI (°)	57.3 ± 12.4	57.9 ± 12.5	0.159
APP angle (°)	0.9 ± 9.5	-1.0 ± 9.6	< 0.001*
<b>Global posture parameters</b>			
SVA (cm)	4.3 ± 4.5	3.6 ± 4.2	0.004*
GSA (°)	4.7 ± 4.4	4.1 ± 4.3	0.005*
TPA (°)	14.9 ± 10.5	15.5 ± 10.4	0.078

SS, sacral slope; PT, pelvic tilt; PI, pelvic incidence; APP, anterior pelvic plane; SVA, sagittal vertical axis; GSA, global sagittal axis; TPA, T1 pelvic angle

**Table 3** Comparison of pre-operative and post-operative pelvic and posture parameters in subgroups based on pelvic incidence

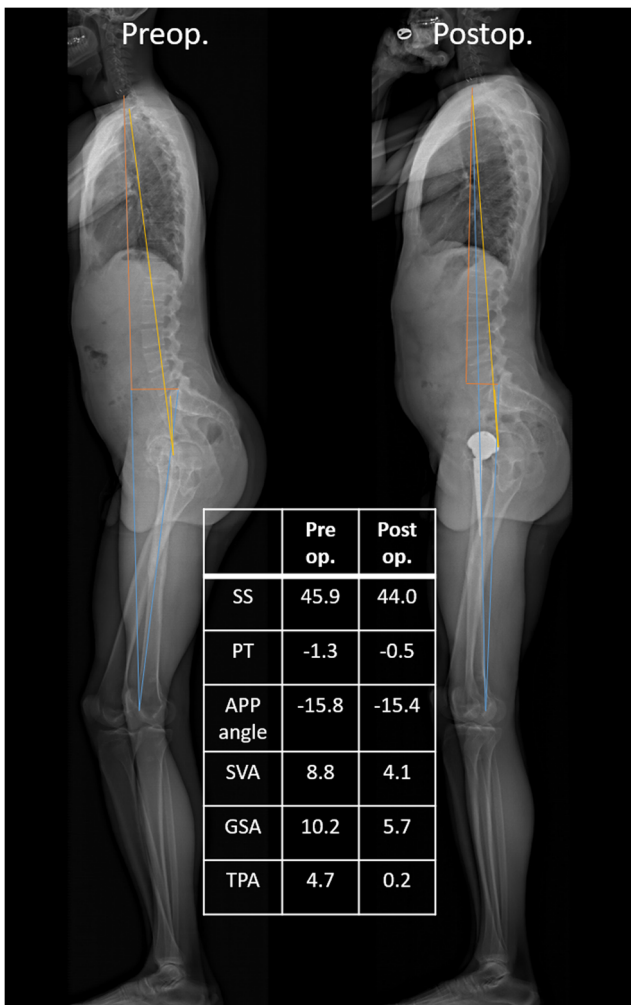
	Pre-operative	Post-operative	<i>p</i> value
<b>Low PI (PI &lt; 45°)</b>			
SS (°)	33.5 ± 10.7	31.1 ± 11.9	0.002*
PT (°)	5.8 ± 9.5	9.4 ± 11.0	0.001*
APP angle (°)	5.9 ± 9.6	3.6 ± 12.1	0.049*
SVA (cm)	5.4 ± 4.9	4.2 ± 4.1	0.038*
GSA (°)	5.4 ± 5.0	4.3 ± 4.0	0.005*
TPA (°)	8.4 ± 10.6	9.8 ± 10.7	0.048*
<b>Medium PI (45° &lt; PI &lt; 65°)</b>			
SS (°)	41.7 ± 8.0	40.0 ± 8.9	0.001*
PT (°)	14.2 ± 8.2	16.3 ± 8.8	< 0.001*
APP angle (°)	0.9 ± 7.3	-1.6 ± 7.6	< 0.001*
SVA (cm)	4.2 ± 4.6	3.6 ± 4.5	0.020*
GSA (°)	4.5 ± 4.6	4.0 ± 4.6	0.087
TPA (°)	14.9 ± 9.6	15.3 ± 9.8	0.162
<b>High PI (PI &gt; 65°)</b>			
SS (°)	52.7 ± 13.0	51.7 ± 12.0	0.219
PT (°)	21.5 ± 11.1	22.5 ± 9.9	0.145
APP angle (°)	-2.3 ± 12.8	-2.7 ± 11.2	0.149
SVA (cm)	3.9 ± 3.6	3.3 ± 3.7	0.184
GSA (°)	5.0 ± 3.2	4.4 ± 3.6	0.095
TPA (°)	19.9 ± 10.1	20.0 ± 10.1	0.467

SS, sacral slope; PT, pelvic tilt; PI, pelvic incidence; APP, anterior pelvic plane; SVA, sagittal vertical axis; GSA, global sagittal axis; TPA, T1 pelvic angle

to  $41.3^\circ \pm 12.2$  ( $p < 0.001$ ). The mean PT increased from  $14.5^\circ \pm 10.4$  to  $16.6^\circ \pm 10.3$  ( $p < 0.001$ ). The mean APP angle decreased from  $0.9^\circ \pm 9.5$  to  $-1.0^\circ \pm 9.6$  ( $p < 0.001$ ). Regarding global posture parameters, the overall mean SVA ( $4.3^\circ \pm 4.5$  to  $3.6^\circ \pm 4.2$ ;  $p = 0.005$ ) and GSA ( $4.7^\circ \pm 4.4$  to  $4.1^\circ \pm 4.3$ ;  $p = 0.004$ ) decreased. The mean TPA change was not significant ( $p = 0.078$ ).

The patients were classified to three groups according to their PI (low PI = 24 patients, medium PI = 82 patients, and high PI = 33 patients). In the low PI group, the mean PT increased (from  $5.8 \pm 9.5$  to  $9.4 \pm 11.0$ ,  $p = 0.001$ ) (Fig. 2). The mean SS decreased (from  $33.5 \pm 10.7$  to  $31.1 \pm 11.9$ ,  $p = 0.002$ ). The mean APP angle decreased (from  $5.9 \pm 9.6$  to  $3.6 \pm 12.1$ ). The mean GSA decreased ( $5.4 \pm 5.0$  to  $4.3 \pm 4.0$ ,  $p = 0.005$ ). SVA also decreased ( $5.4 \pm 4.9$  to  $4.2 \pm 4.1$ ,  $p = 0.038$ ). The mean TPA increased ( $8.4 \pm 10.6$  to  $9.8 \pm 10.7$ ,  $p = 0.048$ ).

In medium PI, the mean SS decreased ( $41.7 \pm 8.0$  to  $40.0 \pm 8.9$ ,  $p = 0.001$ ) (Fig. 3). The mean PT increased  $14.2 \pm 8.2$  to  $16.3 \pm 8.8$ ,  $p < 0.001$ . The mean APP angle decreased ( $0.9 \pm 7.3$  to  $-1.6 \pm 7.6$ ,  $p < 0.001$ ). The mean SVA decreased ( $4.2 \pm 4.6$  to  $3.6 \pm 4.5$ ,  $p = 0.02$ ). Other parameters did not change significantly.



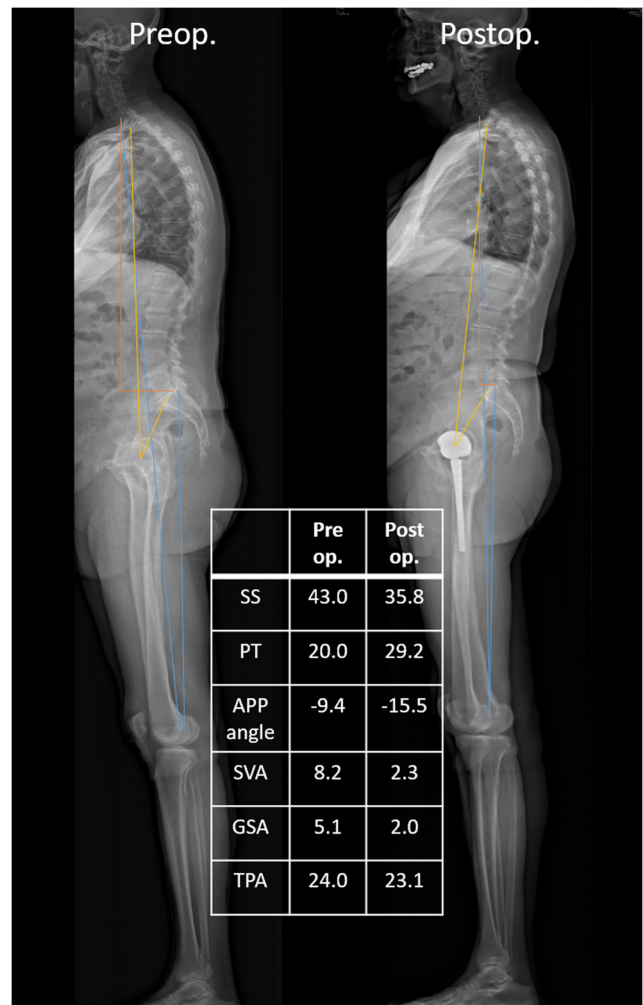
**Fig. 2** Pre-operative and post-operative lateral EOS imaging (standing) in a patient with low PI (PI = 43.3°) who underwent total hip arthroplasty. SS, sacral slope; PT, pelvic tilt; APP, anterior pelvic plane; SVA, sagittal vertical axis; GSA, global sagittal axis; TPA, T1 pelvic angle

In high PI, there were no statistically significant differences in any mean pre-operative and post-operative pelvic and global posture parameters (Fig. 4).

## Discussion

This study is among the first to report on the classification of post-operative global posture and spinopelvic parameter change after THA based on PI. Our results indicated that patients with low and medium PI had modifications of the global sagittal alignment and posture after THA while the patients with high PI had no modification of postural and spinopelvic adaptation after THA.

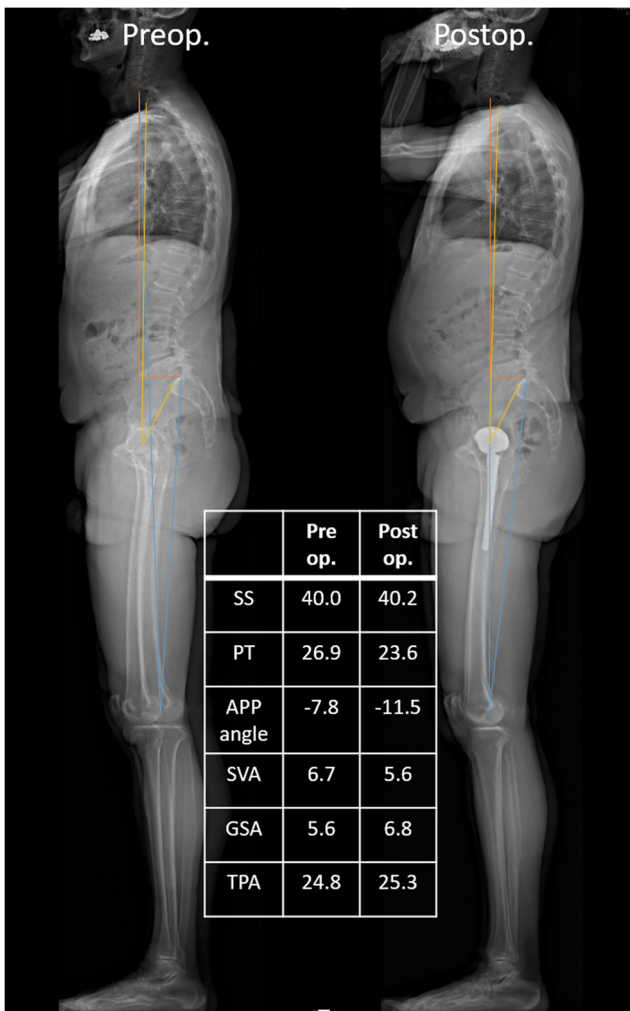
This study has several limitations. First, only a small number of subjects were investigated due to our strict inclusion and exclusion criteria. Despite having enough power, these findings need to be confirmed in a larger patient population.



**Fig. 3** Pre-operative and post-operative lateral EOS imaging (standing) in a patient with medium PI (PI = 63.0) who underwent total hip arthroplasty. SS, sacral slope; PT, pelvic tilt; APP, anterior pelvic plane; SVA, sagittal vertical axis; GSA, global sagittal axis; TPA, T1 pelvic angle

Second, we have excluded patients with previous spine or lower extremity surgeries. The findings of this study should also be investigated among those patients as their posture change after THA might be different. These limitations should be considered when interpreting the results and should be addressed in future studies.

This study confirmed significant changes in posture after THA with a tendency for increased post-operative posterior pelvic tilt associated with SVA and GSA decrease. According to the concept of the hip-spine relation, end stage hip DJD causes flexion contractures of the hip joint, which leads to compensatory change of the pelvis and the lumbar spine [21]. Okuda et al. reported that SS and lumbar lordosis (LL) angles were significantly greater in patients with hip DJD than in healthy volunteers [22]. Severe hip DJD has been reported to cause spinal and pelvic alignment abnormalities and may also cause abnormal sub-pelvic alignment [23, 24]. Day et al. reported that the patients with severe DJD had significant



**Fig. 4** Pre-operative and post-operative lateral EOS imaging (standing) in a patient with high PI (PI = 66.9) who underwent total hip arthroplasty. SS, sacral slope; PT, pelvic tilt; APP, anterior pelvic plane; SVA, sagittal vertical axis; GSA, global sagittal axis; TPA, T1 pelvic angle

pelvic tilt, higher SVA and higher GSA than the patients with limited DJD due to less hips extension and anterior pelvic tilt [23]. In our study, the GSA was significantly decreased after THA in patients with low PI, which indicates recruitment of the spine and lower extremity compensatory mechanisms due to limited ability of pelvic adaptation in patients with low PI and severe hip DJD. These patients have less lumbar lordosis and the range of sagittal pelvic adaptation is limited [25] as  $PI = SS + PT$  [26]. The patients with low PI and severe hip DJD rely on other spinopelvic and lower extremity compensatory mechanisms to keep and restore their upright posture. As a result, they extend their spine more and bend their knee joints to gain the upright posture. Any pathologic process in the lower extremities causing substantial alignment change or even shorter spinal fusion can be a risk factor with higher instability rate.

In the patients with medium PI, the change in sagittal pelvic tilt is the main variable determining the posture after THA

(Fig. 3). These patients do not need to recruit the compensatory mechanisms of spine and lower extremities. SVA is modified due to posterior pelvic tilt and restoration of hip extension ability. The patients with high PI do not have any significant postural changes after THA. In these patients, there is more lumbar lordosis and more potential extension range for the hips after the correction of hip flexion contracture [27]. These patients do not need to use the compensatory mechanisms of their spine and lower extremities substantially (Fig. 4). High PI patients have no significant postural modification because of their high hip adaptation ability. In these patients, the rate of post-operative dislocation in standing position can potentially be lower unless the patients undergo a long spinal fusion or a severe degenerative lumbar spine inducing a permanent sagittal imbalance. We found that the modification of the pelvic tilt was significant in the medium PI patients but the change was smaller compared to the patients with low PI, similar to results reported by Murphy et al. [2].

Previous studies reported that the functional standing acetabular anteversion after THA resides outside the safe zone proposed by Lewinnek [16] in most patients because of change in the anterior or posterior pelvic tilt [28]. There is  $0.7^\circ$  change in the functional acetabular anteversion per  $1^\circ$  change in posterior pelvic tilt [29]. According to these findings, it will be significantly more common to have a preoperative pelvic radiograph with anterior pelvic tilt (similar to inlet view) and a postoperative radiograph with closer to normal pelvic tilt in patients with low and medium PI. This means that the functional acetabular anteversion and abduction angles will look different between these 2 views due to the pelvic tilt. In patients with low PI, the posterior pelvic tilt is often increased after THA due to flexion contracture release. This may lead to an increased post-operative functional anteversion and posterior prosthetic impingement in standing position, which may result in anterior hip instability. Patients with high PI do not have a significant modification of their sagittal pelvic alignment after THA. In some of these patients a limited posterior pelvic tilt in sitting position may induce less anterior uncovering of the acetabulum and less posteroinferior coverage which may lead to anterior impingement and posterior dislocation in sitting position [30]. Ultimately, the effect of this postural changes on the gait needs to be studied may not significantly affect the gait pattern clinically similar to other investigations regarding the gait changes after THA [31, 32].

## Conclusion

Global spinal alignment and posture after THA must be understood using a combined analysis of the pelvic and the global postural parameters. This study points out the importance of PI measurement and its role in predicting the changes in global spinal posture after THA. Patients with severe hip DJD and

low PI use compensatory mechanisms including spinopelvic and lower extremity motions because of their limited adaptation of the pelvis. This results in more modification of global sagittal alignment after THA. Patients with severe hip DJD and high PI compensate by pelvic adaptation and as a result they do not show any modification of global sagittal alignment after THA.

## Compliance with ethical standards

**Conflict of interest** The authors declare that they have no conflicts of interest.

**Ethical review** Study approval was obtained from the Pitié-Salpêtrière Hospital review board.

**Location of study** Pitié-Salpêtrière Hospital.

## References

- Piazzolla A, Solarino G, Bizzoca D, Montemurro V, Berjano P, Lamartina C, Martini C, Moretti B (2018) Spinopelvic parameter changes and low back pain improvement due to femoral neck anteversion in patients with severe unilateral primary hip osteoarthritis undergoing total hip replacement. *Eur Spine J* 27(1):125–134
- Murphy WS, Klingenstein G, Murphy SB, Zheng G (2013) Pelvic tilt is minimally changed by total hip arthroplasty. *Clin Orthop Relat Res* 471(2):417–421
- Parvizi J, Pour AE, Hillibrand A, Goldberg G, Sharkey PF, Rothman RH (2010) Back pain and total hip arthroplasty: a prospective natural history study. *Clin Orthop Relat Res* 468(5):1325–1330
- Ben-Galim P, Ben-Galim T, Rand N, Haim A, Hipp J, Dekel S, Floman Y (2007) Hip-spine syndrome: the effect of total hip replacement surgery on low back pain in severe osteoarthritis of the hip. *Spine (Phila Pa 1976)* 32(19):2099–2102
- Bredow J, Katinakis F, Schluter-Brust K, Krug B, Pfau D, Eysel P, Dargel J, Wegmann K (2015) Influence of hip replacement on sagittal alignment of the lumbar spine: an EOS study. *Technol Health Care* 23(6):847–854
- Eguchi Y, Iida S, Suzuki C, Shinada Y, Shoji T, Takahashi K, Ohtori S (2018) Spinopelvic alignment and low back pain after total hip replacement arthroplasty in patients with severe hip osteoarthritis. *Asian Spine J* 12(2):325–334
- Radcliff KE, Orozco F, Molby N, Delasotta L, Chen E, Post Z, Ong A (2013) Change in spinal alignment after total hip arthroplasty. *Orthop Surg* 5(4):261–265
- Lazennec JY, Charlot N, Gorin M, Roger B, Arafati N, Bissery A, Saillant G (2004) Hip-spine relationship: a radio-anatomical study for optimization in acetabular cup positioning. *Surg Radiol Anat* 26(2):136–144
- Boulay C, Tardieu C, Hecquet J, Benaïm C, Mouilleseaux B, Marty C, Prat-Pradal D, Legaye J, Duval-Beaupere G, Pelissier J (2006) Sagittal alignment of spine and pelvis regulated by pelvic incidence: standard values and prediction of lordosis. *Eur Spine J* 15(4):415–422
- Legaye J, Duval-Beaupere G, Hecquet J, Marty C (1998) Pelvic incidence: a fundamental pelvic parameter for three-dimensional regulation of spinal sagittal curves. *Eur Spine J* 7(2):99–103
- Roussouly P, Pinheiro-Franco JL (2011) Biomechanical analysis of the spino-pelvic organization and adaptation in pathology. *Eur Spine J* 20(Suppl 5):609–618
- Lazennec JY, Folinis D, Bendaya S, Rousseau MA, Pour AE (2016) The global alignment in patients with lumbar spinal stenosis: our experience using the EOS full-body images. *Eur J Orthop Surg Traumatol* 26(7):713–724
- Lazennec JY, Folinis D, Florequin C, Pour AE (2018) Does patients' perception of leg length after total hip arthroplasty correlate with anatomical leg length? *J Arthroplast* 33(5):1562–1566
- Thelen T, Thelen P, Demezou H, Aunoble S, Le Huec JC (2017) Normative 3D acetabular orientation measurements by the low-dose EOS imaging system in 102 asymptomatic subjects in standing position: analyses by side, gender, pelvic incidence and reproducibility. *Orthop Traumatol Surg Res* 103(2):209–215
- Dubouset J, Charpak G, Dorion I, Skalli W, Lavaste F, Deguise J, Kalifa G, Ferey S (2005) A new 2D and 3D imaging approach to musculoskeletal physiology and pathology with low-dose radiation and the standing position: the EOS system. *Bull Acad Natl Med* 189(2):287–297 discussion 97-300
- Lewinnek GE, Lewis JL, Tarr R, Compere CL, Zimmerman JR (1978) Dislocations after total hip-replacement arthroplasties. *J Bone Joint Surg Am* 60(2):217–220
- DiGioia AM, Hafez MA, Jaramaz B, Levison TJ, Moody JE (2006) Functional pelvic orientation measured from lateral standing and sitting radiographs. *Clin Orthop Relat Res* 453:272–276
- Schwab F, Patel A, Ungar B, Farcy JP, Lafage V (2010) Adult spinal deformity-postoperative standing imbalance: how much can you tolerate? An overview of key parameters in assessing alignment and planning corrective surgery. *Spine (Phila Pa 1976)* 35(25):2224–2231
- Diebo BG, Oren JH, Challier V, Lafage R, Ferrero E, Liu S, Vira S, Spiegel MA, Harris BY, Liabaud B, Henry JK, Errico TJ, Schwab FJ, Lafage V (2016) Global sagittal axis: a step toward full-body assessment of sagittal plane deformity in the human body. *J Neurosurg Spine* 25(4):494–499
- Protopsaltis T, Schwab F, Bronsard N, Smith JS, Klineberg E, Mundis G, Ryan DJ, Hostin R, Hart R, Burton D, Ames C, Shaffrey C, Bess S, Errico T, Lafage V, International Spine Study G (2014) The T1 pelvic angle, a novel radiographic measure of global sagittal deformity, accounts for both spinal inclination and pelvic tilt and correlates with health-related quality of life. *J Bone Joint Surg Am* 96(19):1631–1640
- Offierski CM, MacNab I (1983) Hip-spine syndrome. *Spine (Phila Pa 1976)* 8(3):316–321
- Okuda T, Fujita T, Kaneuji A, Miaki K, Yasuda Y, Matsumoto T (2007) Stage-specific sagittal spinopelvic alignment changes in osteoarthritis of the hip secondary to developmental hip dysplasia. *Spine (Phila Pa 1976)* 32(26):E816–E819
- Day LM, DelSole EM, Beaubrun BM, Zhou PL, Moon JY, Tishelman JC, Vigdorichik JM, Schwarzkopf R, Lafage R, Lafage V, Protopsaltis T, Buckland AJ (2018) Radiological severity of hip osteoarthritis in patients with adult spinal deformity: the effect on spinopelvic and lower extremity compensatory mechanisms. *Eur Spine J* 27(9):2294–2302
- Weng W, Wu H, Wu M, Zhu Y, Qiu Y, Wang W (2016) The effect of total hip arthroplasty on sagittal spinal-pelvic-leg alignment and low back pain in patients with severe hip osteoarthritis. *Eur Spine J* 25(11):3608–3614
- Schwab F, Lafage V, Patel A, Farcy JP (2009) Sagittal plane considerations and the pelvis in the adult patient. *Spine (Phila Pa 1976)* 34(17):1828–1833
- Schwab FJ, Blondel B, Bess S, Hostin R, Shaffrey CI, Smith JS, Boachie-Adjei O, Burton DC, Akbarnia BA, Mundis GM, Ames CP, Kebaish K, Hart RA, Farcy JP, Lafage V, International Spine Study G (2013) Radiographical spinopelvic parameters and

- disability in the setting of adult spinal deformity: a prospective multicenter analysis. *Spine (Phila Pa 1976)* 38(13):E803–E812
27. Lazennec JY, Brusson A, Rousseau MA (2011) Hip-spine relations and sagittal balance clinical consequences. *Eur Spine J* 20(Suppl 5): 686–698
  28. Lazennec JY, Thauront F, Robbins CB, Pour AE (2017) Acetabular and femoral anteversions in standing position are outside the proposed safe zone after total hip arthroplasty. *J Arthroplast* 32(11): 3550–3556
  29. Maratt JD, Esposito CI, McLawhorn AS, Jerabek SA, Padgett DE, Mayman DJ (2015) Pelvic tilt in patients undergoing total hip arthroplasty: when does it matter? *J Arthroplast* 30(3):387–391
  30. Yoshimoto H, Sato S, Masuda T, Kanno T, Shundo M, Hyakumachi T, Yanagibashi Y (2005) Spinopelvic alignment in patients with osteoarthritis of the hip: a radiographic comparison to patients with low back pain. *Spine (Phila Pa 1976)* 30(14):1650–1657
  31. Martz P, Bourredjem A, Maillefert JF, Binquet C, Baulot E, Ornetti P, Laroche D (2019) Influence of body mass index on sagittal hip range of motion and gait speed recovery six months after total hip arthroplasty. *Int Orthopaedics*. <https://doi.org/10.1007/s00264-018-4250-y>
  32. Weber M, Weber T, Woerner M, Craiovan B, Worlicek M, Winkler S, Grifka J, Renkawitz T (2015) The impact of standard combined anteversion definitions on gait and clinical outcome within one year after total hip arthroplasty. *Int Orthop* 39(12):2323–2333. <https://doi.org/10.1007/s00264-015-2777-8>

**Publisher's note** Springer Nature remains neutral with regard to jurisdictional claims in published maps and institutional affiliations.