



### **Science Arts & Métiers (SAM)**

is an open access repository that collects the work of Arts et Métiers Institute of Technology researchers and makes it freely available over the web where possible.

This is an author-deposited version published in: <https://sam.ensam.eu>  
Handle ID: <http://hdl.handle.net/10985/21359>

#### **To cite this version :**

Raphaël PIETTON, Houssam BOULOSSA, Tristan LANGLAIS, Jessica TAYTARD, Nicole BEYDON, Wafa SKALLI, Raphaël VIALLE, Claudio VERGARI - Estimating pulmonary function after surgery for adolescent idiopathic scoliosis using biplanar radiographs of the chest with 3D reconstruction - The Bone & Joint Journal (BJJ) - Vol. 104-B, n°1, p.112-119 - 2022

Any correspondence concerning this service should be sent to the repository

Administrator : [scienceouverte@ensam.eu](mailto:scienceouverte@ensam.eu)



## ■ SPINE

# Estimating pulmonary function after surgery for adolescent idiopathic scoliosis using biplanar radiographs of the chest with 3D reconstruction

R. Pietton,  
H. Bouloussa,  
T. Langlais,  
J. Taytard,  
N. Beydon,  
W. Skalli,  
C. Vergari,  
R. Vialle

### Aims

This study addressed two questions: first, does surgical correction of an idiopathic scoliosis increase the volume of the rib cage, and second, is it possible to evaluate the change in lung function after corrective surgery for adolescent idiopathic scoliosis (AIS) using biplanar radiographs of the ribcage with 3D reconstruction?

### Methods

A total of 45 patients with a thoracic AIS which needed surgical correction and fusion were included in a prospective study. All patients underwent pulmonary function testing (PFT) and low-dose biplanar radiographs both preoperatively and one year after surgery. The following measurements were recorded: forced vital capacity (FVC), slow vital capacity (SVC), and total lung capacity (TLC). Rib cage volume (RCV), maximum rib hump, main thoracic curve Cobb angle (MCCA), medial-lateral and anteroposterior diameter, and T4-T12 kyphosis were calculated from 3D reconstructions of the biplanar radiographs.

### Results

All spinal and thoracic measurements improved significantly after surgery ( $p < 0.001$ ). RCV increased from 4.9 l (SD 1) preoperatively to 5.3 l (SD 0.9) ( $p < 0.001$ ) while TLC increased from 4.1 l (SD 0.9) preoperatively to 4.3 l (SD 0.8) ( $p < 0.001$ ). RCV was correlated with all functional indexes before and after correction of the deformity. Improvement in RCV was weakly correlated with correction of the mean thoracic Cobb angle ( $p = 0.006$ ). The difference in TLC was significantly correlated with changes in RCV ( $p = 0.041$ ). It was possible to predict postoperative TLC from the postoperative RCV.

### Conclusion

3D rib cage assessment from biplanar radiographs could be a minimally invasive method of estimating pulmonary function before and after spinal fusion in patients with an AIS. The 3D RCV reflects virtual chest capacity and hence pulmonary function in this group of patients.

Cite this article: *Bone Joint J* 2022;104-B(1):112–119.

### Introduction

Adolescent idiopathic scoliosis (AIS) is defined as a 3D deformity of the trunk which develops during growth, causing abnormal curvature of the spine in the coronal and sagittal planes and changes in shape of the rib cage. Idiopathic scoliosis, which accounts for approximately 85% of cases, is defined as a structural scoliosis for which no cause has been established.<sup>1</sup>

The respiratory impact of scoliosis is multifactorial.<sup>2</sup> It is usually associated with the

development of a restrictive ventilatory defect caused by dysfunction of the chest wall and diaphragm. Pulmonary function tests (PFTs) are currently the reference technique to evaluate this restrictive ventilatory impairment, but obtaining reliable static volumes relies heavily on patient compliance.<sup>3,4</sup> In severe cases, pulmonary function impairment due to thoracic scoliosis can lead to an increased morbidity and early mortality.<sup>5</sup>

Several studies have shown the relationship between trunk deformity and respiratory

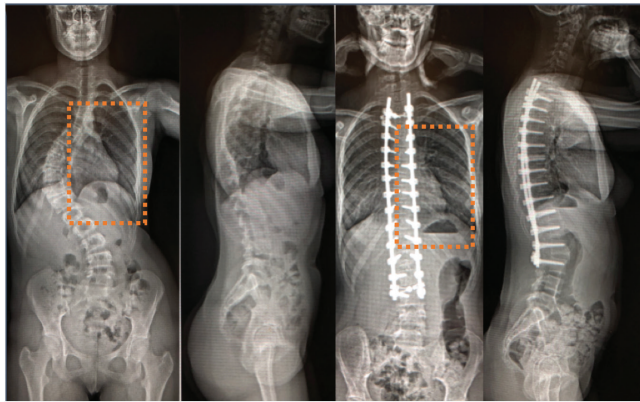


Fig. 1

Preoperative and postoperative biplanar radiographs of a 15-year-old female. The dashed rectangles illustrate the restoration of the intercostal spaces on the concave side.

**Table I.** Changes in spinal and rib cage indexes.

Parameter	Preoperative	Postoperative	p-value*
Mean Cobb angle, ° (SD)	68.2 (17.0)	19.7 (11.9)	< 0.001
Mean T4-T12 kyphosis, ° (SD)	20.8 (17.6)	34.5 (11.4)	0.001
Mean hypokyphosis index, ° (SD)	-4.8 (4.5)	-1.2 (3.4)	< 0.001
Mean rib hump, ° (SD)	12.0 (7.8)	8.7 (4.5)	0.005
Mean rib cage volume, l (SD)	4.9 (1.0)	5.3 (0.9)	< 0.001
Mean rib cage ML diameter, mm (SD)	230.9 (18.7)	233.0 (17.1)	0.010
Mean rib cage AP diameter, mm (SD)	143.6 (15.4)	137.0 (13.6)	0.009
Mean apical vertebral rotation, ° (SD)	-12.3 (19.3)	-6.3 (9.44)	0.036

\*Paired Wilcoxon test.

AP, anteroposterior; ML, medial-lateral; SD, standard deviation.

impairment. Dreimann et al<sup>6</sup> identified curve magnitude and thoracic hypokyphosis as risk factors for a significant decrease in forced vital capacity (FVC). However, Newton et al<sup>7</sup> found a significant but very limited influence of these same factors on the magnitude of respiratory impairment in severe scoliosis. For Newton et al,<sup>7</sup> although spinal parameters are significantly correlated with lung function, their influence is less. Their variability would only explain 20% of the changes in lung function. These studies investigated different spinal parameters using standard radiographs. In practice, 2D analysis is insufficient to assess scoliotic deformities as it completely ignores the axial plane. CT or MRI are traditionally used to assess the scoliotic spine in three dimensions but have the disadvantage of being carried out with the patient supine, which modifies spinal curvatures in both planes.<sup>8</sup> Furthermore, increasing concerns about radiation safety and the use of CT scans in children limit their applicability in routine clinical practice. In the last decade, whole-body biplanar radiographs have become the new gold standard in the analysis of these deformities.<sup>9,10</sup> In addition to reducing the exposure to radiation, they allow a semi-automated

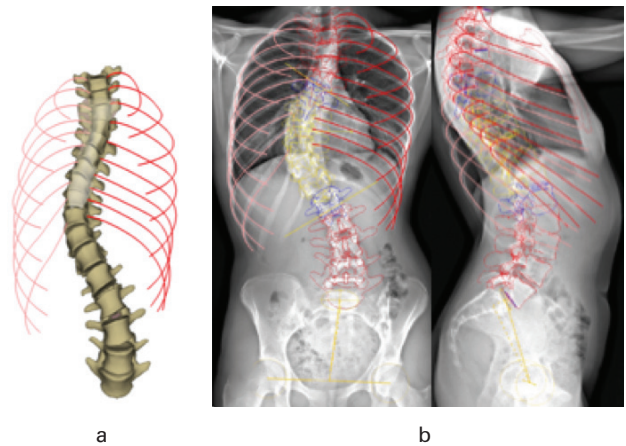


Fig. 2

Rib cage and spine 3D reconstructions. a) Final 3D reconstruction. b) Anteroposterior and lateral views.

**Table II.** Pre- and postoperative lung function.

Indexes, litres	Preoperative	Postoperative	p-value*
Mean TLC (SD)	4.1 (0.9)	4.3 (0.8)	0.001
Mean SVC (SD)	2.9 (0.7)	3.3 (0.6)	< 0.001
Mean FVC (SD)	3.0 (0.7)	3.2 (0.6)	< 0.001
Mean FRC (SD)	2.0 (0.5)	2.1 (0.4)	0.628
Mean FEV1/FVC ratio (SD)	0.82 (0.077)	0.84 (0.079)	0.021

\*Paired Wilcoxon test.

FRC, functional residual capacity; FVC, forced vital capacity; SD, standard deviation; SVC, slow vital capacity; TLC, total lung capacity.

3D reconstruction of the spine and rib cage in the standing position, even in severe cases.<sup>11,12</sup>

A recent study highlighted the relationship between 3D rib cage volume (RCV) using biplanar radiographs and total lung capacity (TLC) as assessed by PFT.<sup>13</sup> Unlike spinal fusion through an anterior approach,<sup>14</sup> posterior spinal fusion (PSF) for AIS improves respiratory function and, above all, prevents long-term respiratory deterioration.<sup>5</sup> However, no studies to date have evaluated the 3D morphological changes in the rib cage and spine after AIS surgery using biplanar radiographs, nor the resultant changes in lung function.

The aim of this study was therefore to evaluate whether pre- and postoperative biplanar radiographs of the rib cage and spine with 3D reconstruction could be used to estimate respiratory function in patients with an AIS.

## Methods

**Patients.** A total of 47 patients with severe thoracic AIS were included in a prospective study between January 2017 and December 2017. Written consent was obtained from parents or trustees. The study was approved by the institutional board (CPP-Paris VI-16-06). The cohort was composed of a consecutive series of patients followed by a single senior orthopaedic surgeon (RV). Patients with the following criteria were excluded: secondary scoliosis (neuromuscular, syndromic, congenital, or post-traumatic); a previous history of surgery; spinal infection; chronic respiratory failure; inability to perform PFT;

**Table III.** Differences between spinal and rib cage indexes in both preoperative forced vital capacity % groups.

Spinal and rib cage parameters	Pathological FVC%	Normal FVC%	p-value*
Total, n	21	24	
Mean Cobb angle, ° (SD)	73.2 (25)	63 (11.2)	0.058
Mean T4-T12 kyphosis, ° (SD)	21.6 (21)	19.9 (14.8)	0.782
Mean hypokyphosis index, ° (SD)	-5.4 (4.8)	-4.4 (4.7)	0.234
Mean rib hump, ° (SD)	12.5 (8)	9.9 (4.4)	0.484
Mean rib cage volume, l (SD)	4.6 (0.9)	5.2 (0.8)	0.023
Mean rib cage width, mm (SD)	226.9 (17.0)	234.9 (16.8)	0.039
Mean rib cage AP diameter, mm (SD)	138.7 (15.5)	145 (14.1)	0.138
Mean apical vertebral rotation, ° (SD)	-16.7 (19.5)	-5.5 (19.6)	0.057

\*Paired Wilcoxon test.

AP, anteroposterior; FVC, forced vital capacity; SD, standard deviation.

**Table IV.** Main pre- and postoperative differences between each normal and pathological forced vital capacity group.

Variable	Normal FVC group		Pathological FVC group	
	Preop	Postop	Preop	Postop
n	24	33	21	12
FVC, %	81	79	56	57
Total lung capacity, l	4.3	4.3	3.8	4.3
Cobb angle, °	63	17	73	27
Rib cage volume, l	5.1	5.3	4.6	5.3

FVC, forced vital capacity.

and severe intellectual deficiency. All patients had PFTs and biplanar radiographs immediately before surgery and two years postoperatively. All patients were initially followed for thoracic AIS with or without a history of brace treatment. No patient underwent selective thoracic fusion or thoracoscopic anterior release. Facetectomies were performed on the concave side of the curve. Two polyaxial pedicle screws were placed at each vertebral level. Two 6 mm diameter chrome-cobalt rods were bent according to the surgical plan. The concave rod was first fixed at the upper and lower instrumented vertebrae. After ensuring sufficient fixation on at least two levels, upper and lower, the rod was orientated to the ideal sagittal plane. A minimum of five translation tools (“persuaders”) were placed on the concave side. The posteromedial translation was made using persuaders for progressive rod to screws approximation. The thoracic deformity was then progressively reduced by the concave persuaders to bring each vertebra to the pre-contoured rod. The spine was translated medially and posteriorly. After applying the maximal correction using the concave rod, the convex rod was sited. The two rods were bent in the same manner and no overbending was used on the concave side.

**Imaging protocol and 3D modelling.** Patients were in free-standing position and were tidal breathing while radiographs were taken (Figure 1). The anteroposterior and lateral exposure parameters were 83 kV/ 200 mA and 102 kV/ 200 mA, respectively. A 3D reconstruction of the spine and rib cage was performed using a semiautomated process, which was validated in

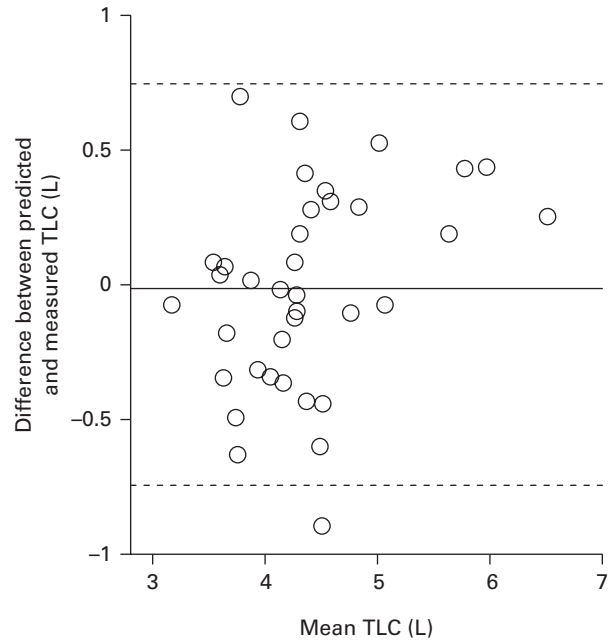


Fig. 3

Agreement between measured and predicted total lung capacity (TLC)-Bland-Altman graph. The horizontal line is the mean bias while dashed lines represent twice the 95% confidence intervals of the difference between predicted and measured TLC.

previous studies.<sup>15,16</sup> The operator was blinded from patients’ pulmonary function during the reconstruction process.

**Spinal and rib cage parameters.** The following structural measurements of the rib cage and spine were obtained automatically using 3D reconstructions:<sup>17–19</sup> Cobb angle (°); apical vertebral rotation (AVR, °); thoracic kyphosis (T4-T12, °); lumbar lordosis (L1-S1, °); rib hump (°); RCV (l); hypokyphosis index (°); maximum rib cage anteroposterior diameter (AP diameter, mm); and maximum medial-lateral diameter (ML diameter) (mm).<sup>20</sup> Hypokyphosis index was defined as the difference between the local kyphosis (or lordosis) of the given patient at the apex and the mean value at the equivalent level for non-scoliotic subjects.<sup>21</sup>

**Pulmonary function test.** All patients underwent PFT including plethysmography and standard spirometry (Body Box, MediSoft, Belgium) in the same centre according to European Respiratory Society (ERS) recommendations.<sup>22,23</sup> The following measurements were obtained: TLC; slow vital capacity (SVC); FVC; Forced Expiratory Volume in 1 s (FEV<sub>1</sub>) to FVC ratio, and functional residual capacity (FRC). Operators were blinded to patients’ deformity characteristics during PFT. According to the spirometry guidelines on the severity of pulmonary impairment, patients with a TLC below 80% and with a FEV<sub>1</sub>/FVC ratio higher than 70% were considered to have a restrictive pattern. According to the guidelines for the severity of pulmonary impairment,<sup>24</sup> patients were classified as follows: patients with a FVC of more than 80% were considered to have no pulmonary impairment. Mild impairments were defined as FVC% values between 65% and 80%. Moderate and severe impairments were defined as FVC% values between

**Table V.** Preoperative correlations between functional and radiological indexes.

Variable	T4-T12 kyphosis	L1-S1 lordosis	HK index	AVR	Cobb angle	Width	AP diameter	Rib hump	RCV
<b>p-values*</b>									
TLC	0.991	0.591	0.006	0.052	0.017	0.003	0.001	0.671	< 0.001
FVC	0.548	0.677	0.017	0.022	0.066	0.001	< 0.001	0.658	< 0.001
SVC	0.708	0.541	0.020	0.004	0.012	0.004	< 0.001	0.096	< 0.001
FEV1 ratio	0.271	0.322	0.267	0.203	0.386	0.071	0.016	0.063	0.035
<b>R coefficients</b>									
TLC	0.00	-0.09	0.43	0.31	-0.38	0.46	0.53	-0.07	0.78
FVC	0.09	-0.06	0.36	0.34	-0.28	0.50	0.58	-0.07	0.78
SVC	0.06	-0.10	0.36	0.44	-0.39	0.44	0.53	-0.26	0.77
FEV1 ratio	0.17	-0.15	-0.17	0.20	-0.13	-0.27	-0.36	-0.28	-0.32

\*Spearman's rank test.

AP, anteroposterior; AVR, apical vertebral rotation; FEV1, forced expiratory volume in one second; FVC, forced vital capacity; HK, hypokyphosis; RCV, rib cage volume; SVC, slow vital capacity; TLC, total lung capacity.

**Table VI.** Postoperative correlations between functional and radiological indexes.

Variable	T4-T12 kyphosis	L1-S1 lordosis	HK index	AVR	Cobb	Width	AP diameter	Rib hump	RCV
<b>p-values*</b>									
TLC	0.647	0.657	0.116	0.002	0.800	0.097	< 0.001	0.875	< 0.001
FVC	0.349	0.367	0.028	0.016	0.526	0.117	< 0.001	0.216	< 0.001
SVC	0.753	0.568	0.023	0.001	0.870	0.176	< 0.001	0.362	< 0.001
FEV1 ratio	0.961	0.881	0.981	0.311	0.955	0.028	0.127	0.310	0.011
<b>R coefficients</b>									
TLC	0.07	-0.07	0.25	0.48	-0.04	0.26	0.65	-0.02	0.81
FVC	0.14	-0.14	0.33	0.36	-0.10	0.24	0.58	-0.19	0.72
SVC	0.05	-0.09	0.35	0.50	-0.03	0.21	0.63	-0.14	0.69
FEV1 ratio	0.01	0.02	0.00	0.16	-0.01	-0.34	-0.24	-0.16	-0.38

\*Spearman's rank test.

AP, anteroposterior; AVR, apical vertebral rotation; FEV1, forced expiratory volume in one second; FVC, forced vital capacity; HK, hypokyphosis; RCV, rib cage volume; SVC, slow vital capacity; TLC, total lung capacity.

50% and 65% and below 50%, respectively. A FVC cut-off value of 65% was used to define pulmonary function pathological status.

**Demographic data.** Overall, 45 patients (38 female) with a thoracic AIS were included in the study. According to the Lenke classification,<sup>25</sup> 33 patients had a Lenke type 1 curve and 12 a Lenke type 2. Mean age at surgery was 14.7 years (12 to 17). The mean Risser stage was 3.48 (standard deviation (SD) 1.1). A total of 18 patients had a previous history of asthma. All patients with asthma were asymptomatic and did not require additional treatment for at least four weeks prior to PFT, in accordance with current guidelines.<sup>26</sup> Of the 45 patients, 26 had previously undergone brace treatment. In terms of ethnicity, 23 were European Caucasian, ten were Middle Eastern, seven were Black African, and five were Southeast Asian.

**Statistical analysis.** Volumes were expressed as litres or as a percentage of predicted volume, but expression in litres was used for statistical analyses. Differences were analyzed using paired Wilcoxon tests and Mann-Whitney U tests and correlations using Spearman's rank test. Significance was set at  $\alpha = 0.05$ . A predictive model was then developed to estimate postoperative TLC from the postoperative radiological indexes, using stepwise linear regression. The limits of agreement of the model were expressed as Bland-Altman graphs. Statistical analysis was conducted using SPSS v20 (IBM, USA).

## Results

The surgical technique of choice was posterolateral translation with an all-pedicle-screw construct. There were no major perioperative complications. Figure 1 illustrates posterolateral translation with all-pedicle-screw constructs. Dashed rectangles illustrate the changes in intercostal distances of the hemithorax on the concave side. Figure 2 shows 3D final reconstructions as well as lateral and anteroposterior views.

**Spinal and rib cage parameters.** All patients underwent biplanar radiographs preoperatively and at a mean of 1.42 years (SD 0.49) postoperatively. The mean Cobb angle was 68.2° (SD 17°; 47° to 128°) preoperatively and 19.7° postoperatively (SD 11.9°, 3° to 47°) ( $p < 0.001$ ). The T4-T12 kyphosis increased significantly from 20.8° preoperatively to 34.5° postoperatively ( $p < 0.001$ , paired Wilcoxon test). All spinal and thoracic measurements improved postoperatively (Table I). In particular, the mean RCV increased significantly from 4.9 l (SD 1.0) preoperatively to 5.3 l (SD 0.9) postoperatively ( $p < 0.001$ ).

**Pulmonary function.** All patients underwent PFT immediately before surgery and at a mean of 1.60 years (SD 0.44) after surgery. A total of 30 patients had a restrictive pattern. The mean FVC or TLC were not significantly different whether or not patients had a previous history of brace treatment ( $p = 0.821$  (FVC),  $p = 0.742$  (TLC), Mann-Whitney U test) or asthma. The



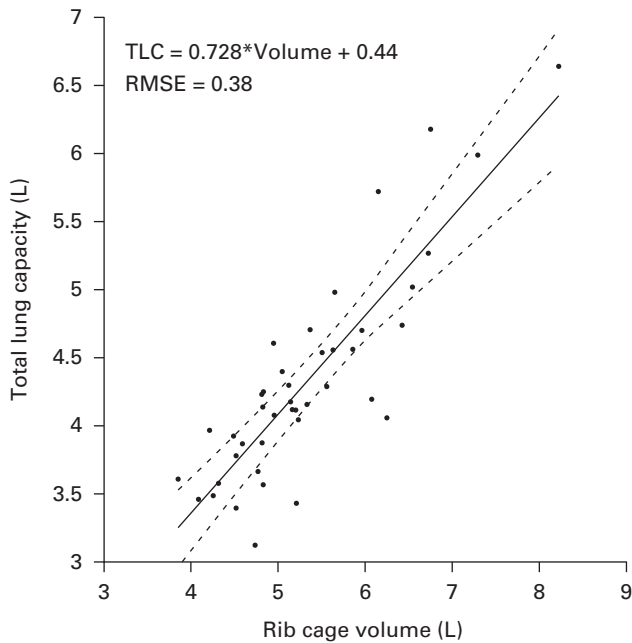


Fig. 4

Difference between predicted and measured total lung capacity (TLC). RMSE, root mean square error.

mean TLC was 4.1 l (SD 0.87) preoperatively and 4.3 l (SD 0.76) postoperatively ( $p = 0.001$ , paired Wilcoxon test). The mean FVC increased significantly from 3.0 l (SD 0.7) preoperatively to 3.2 l (SD 0.6) postoperatively ( $p < 0.001$ , paired Wilcoxon test). FRC did not vary significantly between the preoperative measurement (2.05 l) and final follow-up (2.07 l) ( $p = 0.628$ , paired Wilcoxon test). Lung function results are summarized in Table II. According to the different FVC% groups, there were 12 patients in the “no impairment” and “mild impairment” groups, 16 patients in the “moderate impairment” group, and five patients in the “severe impairment” group. These different groups were combined into a pathological FVC% (FVC < 65%, 21 patients) group and a normal FVC% (FVC > 65%, 24 patients) group. The preoperative differences between both groups are summarized in Table III. Rib cage measurements such as RCV, anteroposterior diameter, and spinal penetration index (SPI) showed significant differences. Spinal measurements did not differ between FVC% groups. Nine of the 16 patients in the moderate impairment group had a FVC of more than 65% postoperatively (non-pathological), while three of the five patients in the severe impairment group had an increase in FVC beyond 50%. The effect of surgical correction on FVC% and the differences between groups are illustrated in Figure 3 while Table IV shows the main pre- and postoperative differences between each normal and pathological FVC group.

**Preoperative correlation between trunk deformity and pulmonary function.** The preoperative Cobb angle was weakly correlated with TLC ( $r = -0.38$ ;  $p = 0.017$ , Spearman’s rank test). Hypokyphosis and apical vertebra rotation were also weakly correlated with pulmonary indices. No significant correlation was found between the other spinal and pelvic measurements

and the preoperative pulmonary function. Preoperatively, RCV was correlated with TLC ( $r = 0.78$ ;  $p < 0.001$ , Spearman’s rank test), SVC ( $r = 0.78$ ;  $p < 0.001$ , Spearman’s rank test), and FVC ( $r = 0.76$ ;  $p < 0.001$ , Spearman’s rank test). The maximal AP diameter was also correlated with all pulmonary function indices. Results are summarized in Table IV and Table V.

**Surgical correction and pulmonary changes.** Postoperatively, TLC remained correlated with RCV ( $r = 0.81$ ;  $p < 0.001$ ). Table V and Table VI illustrate the postoperative correlations between radiological and functional indices. Finally, it was possible to predict the postoperative TLC from the postoperative RCV as shown in Figure 4; the root mean square error between the predicted and measured TLC was 0.38 l. Bland-Altman plots<sup>27</sup> (Figure 3), analyzing differences between predicted TLC and postoperative TLC, illustrate this agreement without outliers. This showed that the differences between estimated and measured TLC are distributed around the mean TLC.

## Discussion

This study reports data from a homogeneous cohort of prospectively enrolled AIS patients who were recruited to explore the level of agreement between 3D rib cage measurements obtained from biplanar radiographs and pulmonary function indices obtained from PFT.

The use of CT does not allow the acquisition of trunk images in the standing position. The cumulative radiation dose may also increase the risk of cancer in adulthood,<sup>28</sup> and 3D reconstructions from CT scans are time-consuming in routine clinical practice. Some studies have suggested the use of dynamic MRIs.<sup>8</sup> Recently, a significant relationship has been shown between chest measurements, such as the hump or the apical vertebral rotation and clinical parameters, using MRI. This is an interesting approach but, for the time being, it is reserved for research activities. The 3D rib cage reconstruction method from biplanar radiographs compared to CT scans has been validated in several studies.<sup>15,16</sup> An accuracy and reproducibility study of this method in mild idiopathic scoliosis confirmed the effectiveness of this technique.<sup>29</sup> Finally, a reproducibility study of rib cage reconstruction in severe cases of idiopathic scoliosis confirmed a very good inter- and intraoperator reproducibility of this technique.<sup>12</sup>

The correlation between Cobb angle and lung function is still controversial. Redding et al<sup>30</sup> found weak correlations between Cobb angle and PFT results, while Johnston et al<sup>31</sup> reported a stronger correlation. However, the different measurements were made on standard radiographs without any 3D analysis. Wang et al<sup>32</sup> recently showed an association between FVC and spinal and thoracic measurements. These authors insisted on the link between thoracic measurements, such as translation and rotation of the apical vertebra, and the severity of the Cobb angle with respiratory impairment. Buckland et al<sup>33</sup> in a similar study concluded that there was no significant increase in RCV and TLC after surgery. The difference between our results and this study may be explained by a higher severity of Cobb angle in our study population (68° vs 48°). Even though Cobb angle measurement is at the centre of the decision-making process and surgical planning, it is not certain that it should still play a fundamental role in the risk-benefit ratio explained to patients

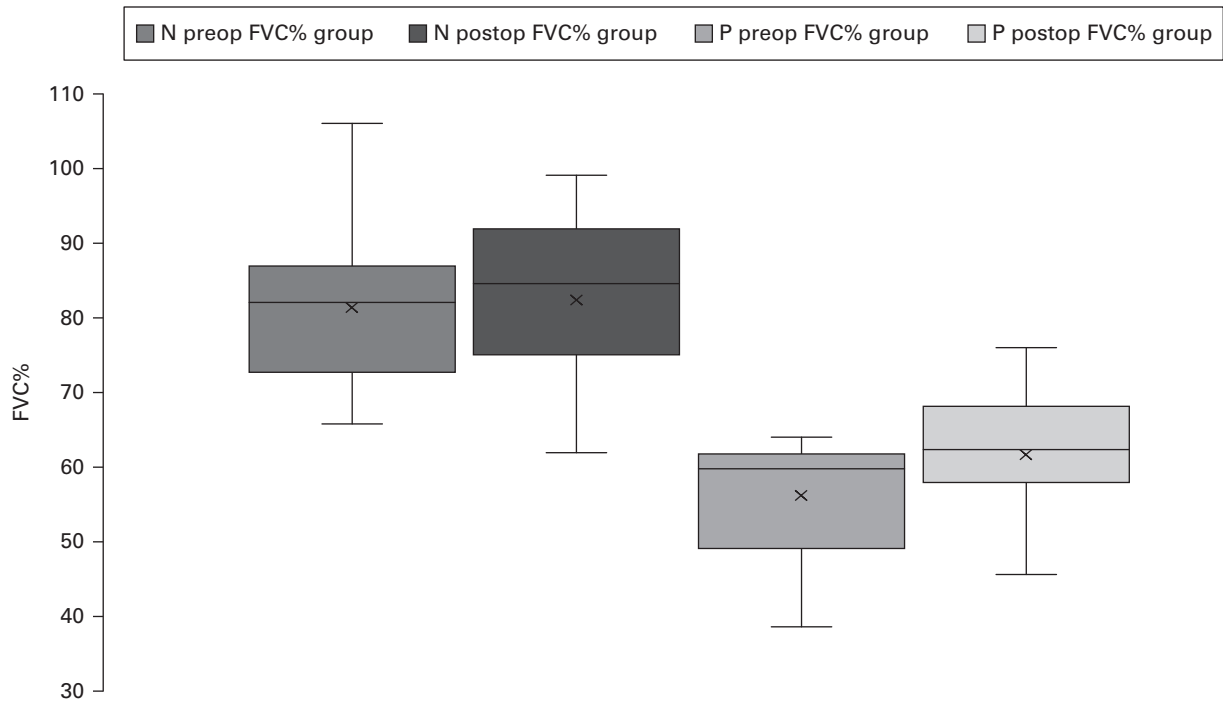


Fig. 5

Surgical correction and forced vital capacity (FVC%) changes between groups.

and their parents concerning their respiratory condition before surgery. Bouloussa et al,<sup>13</sup> in a recent study assessing 3D rib cage reconstructions and the impairment of pulmonary function in preoperative AIS, showed that RCV was the most important structural factor affecting lung function in patients with AIS and a severe thoracic curve (Cobb angle > 50°). The best correlation was found with TLC, suggesting that poor RCV was a predictor for the diagnosis of a restrictive ventilatory defect on PFT. This study confirms these results. Spinal measurements are poor predictors of impairment of pulmonary function.

This was further confirmed by the predictive model, which was developed in this study and illustrated in Figure 5. Postoperative TLC could be predicted from postoperative RCV. Therefore, RCV is a key 3D measurement in the preoperative and postoperative assessment of pulmonary function in AIS.

In a study on AIS of variable severity, Ilharborde et al<sup>10</sup> also showed a relationship between RCV measured from the same procedure and TLC. The present study shows the effectiveness of surgical correction by posteromedial screw translation. This technique, initially described with the use of sublaminar bands, can therefore be used with pedicle screws. Spinal measurements were all improved by surgery, including restoration of the thoracic kyphosis. The assessment of the 3D correction of the different spinal and thoracic measurements in this study tends to show that the increase in the RCV is probably multifactorial.

Although we have observed a strong relationship between spinal and thoracic measurements, the improvement of pulmonary function secondary to surgery cannot be explained simply by the correction of the Cobb angle. Only the RCV

and the anteroposterior diameter were significantly related to improvement in the pulmonary function indices. One of the hypotheses that could explain the increase in RCV after surgery is the restitution of the volume of the concave hemithorax, as shown in the dashed rectangle in Figure 1.

The prognosis for pulmonary function is known to be of particular importance in ensuring that AIS patients remain healthy. As part of the natural history of AIS, patients with a severe thoracic curve have been reported to be at high risk of developing a restrictive ventilatory pattern. Long-term pulmonary function results after spinal fusion are becoming crucial. Akazawa et al,<sup>5</sup> in a study of long-term respiratory impairment in patients undergoing surgery for AIS, found more severe restrictive ventilatory defects in patients with greater rib humps and apical vertebral rotation. This illustrates the importance of performing vertebral derotation to correct the rib cage deformity. Kato et al<sup>34</sup> concluded in a recent review of the literature that there was no evidence of improvement in lung function after surgery for adolescent scoliosis. However, the authors themselves emphasized the heterogeneity of the different studies and the variability of the surgical techniques used. A prospective study is needed to evaluate the long-term respiratory result after surgical correction using modern techniques. Implants and modern reduction techniques will hopefully improve the long-term results.

The fact that we did not see a significant difference between pre- and postoperative FRC suggests that the increase in TLC is indeed due to an increase in RCV and not to alveolar development.

In total, 18 patients out of 45 (31.4%) had a history of asthma with the typical findings of obstructive lung disease. However, in all cases, the asthma was controlled, without long-term medication or symptoms reported four weeks prior to PFT. One study reported the increased incidence of obstructive lung disease in patients with AIS, but its pathophysiology remains uncertain.<sup>35</sup> Extrinsic mechanisms such as compression (indirectly caused by rib humps or apical rotation), gas trapping, and intrinsic mechanisms (including hypersecretion) have been suggested.<sup>36</sup> However, excluding these patients would have compromised the external validity of the study. Moreover, TLC was measured using plethysmography and not by the dilution technique, which gives a reliable result even in case of bronchial obstruction. The sample of patients is relatively small, however, and this is the first study on this topic. A larger number of participants would permit a better investigation of the influence of certain measurements, particularly of thoracic kyphosis.<sup>6,7</sup> Some authors have been able to highlight the role of hypokyphosis in the severity of respiratory impairment. It was not possible to corroborate these results in this study, nor was it possible to verify the relationship between hypokyphosis and respiratory failure because the mean kyphosis of the study population was within normal values.

In conclusion, this study describes an innovative way to approach pulmonary function in AIS. It gives a better understanding of the relationship between rib cage correction and the improvement in pulmonary function. In addition, this natural posture, weightbearing analysis of both spine and rib cage, through paired low-dose biplanar radiographs, explains the postoperative improvement in respiratory function in AIS patients with PSF. The 3D RCV appears to reflect virtual chest capacity.



### Take home message

- This prospective study provides an explanation for the postoperative improvement of respiratory function in adolescent idiopathic scoliosis patients with posterior

spinal fusion.

- The 3D rib cage volume appears to be a virtual chest capacity reflecting respiratory function.

### References

- Hwang SW, Mackel CE, Samdani AF, Stephen JH, Bennett JT, Baaj AA. Evaluation and management of adolescent idiopathic scoliosis: a review. *Neurosurg Focus*. 2017;43(4):E2.
- Tsiligiannis T, Grivas T. Pulmonary function in children with idiopathic scoliosis. *Scoliosis*. 2012;7(1):7.
- Takahashi S, Suzuki N, Asazuma T, Kono K, Ono T, Toyama Y. Factors of thoracic cage deformity that affect pulmonary function in adolescent idiopathic thoracic scoliosis. *Spine*. 2007;32(1):106–112.
- Xue X, Shen J, Zhang J, Zhao H, Li S, Wang Y. An analysis of thoracic cage deformities and pulmonary function tests in congenital scoliosis. *Eur Spine J*. 2015;24(7):1415–1421.
- Akazawa T, Kuroya S, Iinuma M, et al. Pulmonary function and thoracic deformities in adolescent idiopathic scoliosis 27 years or longer after spinal fusion with Harrington instrument. *J Orthop Sci*. 2018;23(1):45–50.
- Dreimann M, Hoffmann M, Kossow K, Hitzl W, Meier O, Koller H. Scoliosis and chest cage deformity measures predicting impairments in pulmonary function: a cross-sectional study of 492 patients with scoliosis to improve the early identification of patients at risk. *Spine (Phila Pa 1976)*. 15;39(24):2024–2033.
- Newton PO, Faro FD, Gollogly S, Betz RR, Lenke LG, Lowe TG. Results of preoperative pulmonary function testing of adolescents with idiopathic scoliosis. A study of six hundred and thirty-one patients. *J Bone Joint Surg Am*. 2005;87-A(9):1937–1946.
- Chu WC, BK N, AM L, Lam T- P, Lam WW, Cheng JC. Dynamic magnetic resonance imaging in assessing lung function in adolescent idiopathic scoliosis: a pilot study of comparison before and after posterior spinal fusion. *J Orthop Surg Res*. 2007;2(1):20.
- Dubouset J, Charpak G, Skalli W, Kalifa G, Lazennec JY. EOS stereoradiography system: whole-body simultaneous anteroposterior and lateral radiographs with very low radiation dose. *Rev Chir Orthopédique Réparatrice Appar Mot*. 2007;93(6 Suppl):141–143. [Article in French].
- Ilharreborde B, Dubouset J, Le Huec JC. Use of EOS imaging for the assessment of scoliosis deformities: application to postoperative 3D quantitative analysis of the trunk. *Eur Spine J*. 2014;23(Suppl 4):S397.
- Ilharreborde B, Steffen JS, Nectoux E, et al. Angle measurement reproducibility using EOS three-dimensional reconstructions in adolescent idiopathic scoliosis treated by posterior instrumentation. *Spine*. 2011;36(20):E1306-13.
- Pietton R, Bouloussa H, Vergari C, Skalli W, Vialle R. Rib cage measurement reproducibility using biplanar stereoradiographic 3D reconstructions in adolescent idiopathic scoliosis. *J Pediatr Orthop*. 2020;40(1):36–41.
- Bouloussa H, Pietton R, Vergari C, Haen TX, Skalli W, Vialle R. Biplanar stereoradiography predicts pulmonary function tests in adolescent idiopathic scoliosis: a cross-sectional study. *Eur Spine J*. 2019;28(9):1962–1969.
- Yaszay B, Jankowski PP, Bastrom TP, Lonner B, Betz R, Shah S. Progressive decline in pulmonary function 5 years post-operatively in patients who underwent anterior instrumentation for surgical correction of adolescent idiopathic scoliosis. *Eur Spine J*. 2019;28(6):1322–1330.
- Jolivet E, Sandoz B, Laporte S, Mitton D, Skalli W. Fast 3D reconstruction of the rib cage from biplanar radiographs. *Med Biol Eng Comput*. 2010;48(8):821–828.
- Mitton D, Zhao K, Bertrand S, Zhao C, Laporte S, Yang C. 3D reconstruction of the ribs from lateral and frontal X-rays in comparison to 3D CT-scan reconstruction. *J Biomech*. 2008;41(3):706–710.
- Aubert B, Vergari C, Ilharreborde B, Courvoisier A, Skalli W. 3D reconstruction of rib cage geometry from biplanar radiographs using a statistical parametric model approach. *Comput Methods Biomech Biomed Eng Imaging Vis*. 2014;4(5):281–295.
- Humbert L, De Guise JA, Aubert B, Godbout B, Skalli W. 3D reconstruction of the spine from biplanar X-rays using parametric models based on transversal and longitudinal inferences. *Med Eng Phys*. 2009;31(6):681–687.
- Sabourin M, Jolivet E, Miladi L, Wicart P, Rampal V, Skalli W. Three-dimensional stereoradiographic modeling of rib cage before and after spinal growing rod procedures in early-onset scoliosis. *Clinical Biomechanics*. 2010;25(4):284–291.
- Dubouset J, Wicart P, Pomeroy V, Barois A, Estournet B. Spinal penetration index: new three-dimensional quantified reference for lordoscoliosis and other spinal deformities. *J Orthop Sci*. 2003;8(1):41–49.
- Dickson RA, Lawton JO, Archer IA, Butt WP. The pathogenesis of idiopathic scoliosis. Biplanar spinal asymmetry. *J Bone Joint Surg Br*. 1984;66-B(1):8–15.
- Miller MR, Hankinson J, Brusasco V, Burgos F, Casaburi R, Coates A. Standardisation of spirometry. *Eur Respir J*. 2005;26(2):319–338.
- Wanger J, Clausen JL, Coates A, Pedersen OF, Brusasco V, Burgos F. Standardisation of the measurement of lung volumes. *Eur Respir J*. 2005;26(3):511–522.
- Tzelepis GE, McCool FD. The Respiratory System and Chest Wall Diseases. In: *Murray and Nadel's Textbook of Respiratory Medicine*. Elsevier, 2016: 1707–1722.
- Lenke LG, Betz RR, Harms J, Bridwell KH, Clements DH, Lowe TG. Adolescent idiopathic scoliosis: a new classification to determine extent of spinal arthrodesis. *J Bone Joint Surg Am*. 2001;83-A(8):1169–1181.
- No authors listed. Global Initiative for Asthma. 2021. <https://ginasthma.org/> (date last accessed 4 November 2021).
- Bland JM, Altman DG. Statistical methods for assessing agreement between two methods of clinical measurement. *Lancet*. 1986;1(8476):307–310.
- Law M, W-K M, Lau D, Chan E, Yip L, Lam W. Cumulative radiation exposure and associated cancer risk estimates for scoliosis patients: Impact of repetitive full spine radiography. *Eur J Radiol*. 2016;85(3):S0720-048X(15)30216-3:625–628.
- Courvoisier A, Ilharreborde B, Constantinou B, Aubert B, Vialle R, Skalli W. Evaluation of a three-dimensional reconstruction method of the rib cage of mild scoliotic patients. *Spine Deform*. 2013;1(5):321–327.
- Redding G, Song K, Inscore S, Efficann E, Campbell R. Lung function asymmetry in children with congenital and infantile scoliosis. *Spine J*. 2008;8(4):639–644.
- Johnston CE, Richards BS, Sucato DJ, Bridwell KH, Lenke LG, Erickson M. Correlation of preoperative deformity magnitude and pulmonary function tests in adolescent idiopathic scoliosis. *Spine*. 2011;36(14):1096–1102.



32. Wang Y, Yang F, Wang D, et al. Correlation analysis between the pulmonary function test and the radiological parameters of the main right thoracic curve in adolescent idiopathic scoliosis. *J Orthop Surg Res.* 2019;14(1):443.
33. Buckland AJ, Woo D, Vasquez-Montes D, et al. The Relationship Between 3-dimensional Spinal Alignment, Thoracic Volume, and Pulmonary Function in Surgical Correction of Adolescent Idiopathic Scoliosis: A 5-year Follow-up Study. *Spine.* 2020;45(14):983–992.
34. Kato S, Murray JC, Ganau M, Tan Y, Oshima Y, Tanaka S. Does posterior scoliosis correction improve respiratory function in adolescent idiopathic scoliosis? A systematic review and meta-analysis. *Global Spine J.* 2018;9(8):866–873.
35. Boyer J, Amin N, Taddonio R, Dozor AJ. Evidence of airway obstruction in children with idiopathic scoliosis. *Chest.* 1996;109(6):1532–1535.
36. Farrell J, Garrido E. Effect of idiopathic thoracic scoliosis on the tracheobronchial tree. *BMJ Open Respir Res.* 2018;5(1):e000264.

#### Author information:

R. Pietton, MD, Orthopaedic Surgeon, Department of Paediatric Orthopaedics, Sorbonne Université, Paris, France; Arts et Métiers Paris Tech, Institut de Biomécanique Humaine Georges Charpak/IBHCG, Paris, France.

H. Bouloussa, MD, Orthopaedic Surgeon  
T. Langlais, MD, Orthopaedic Surgeon  
R. Vialle, MD, PhD, Head of Department  
Department of Paediatric Orthopaedics, Sorbonne Université, Paris, France.

J. Taytard, MD, PhD, Pulmonologist, Department of Pediatric Pulmonology, Sorbonne Université, Armand Trousseau Hospital, Paris, France.

N. Beydon, MD, Head of Department, Department of Pulmonary Function Test and Sleep Center, Sorbonne Université, Armand Trousseau Hospital, Paris, France.

W. Skalli, PhD, Head of Department  
C. Vergari, PhD, Biomechanical Researcher

Arts et Métiers Paris Tech, Institut de Biomécanique Humaine Georges Charpak/IBHCG, Paris, France.

#### Author contributions:

R. Pietton: Methodology, Data curation, Manuscript – original draft, Manuscript – review & editing.

H Bouloussa: Data curation, Writing – review & editing

T. Langlais: Supervision, Validation, Writing – review & editing.

J. Taytard: Formal analysis, Supervision, Validation, Writing – review & editing.

N. Beydon: Conceptualization, Data curation, Methodology, Supervision, Writing – review & editing.

W. Skalli: Conceptualization, Methodology, Supervision.

C. Vergari: Conceptualization, Methodology, Software, Supervision, Writing – review & editing.

R. Vialle: Conceptualization, Methodology, Supervision, Writing – review & editing.

#### Funding statement:

No funds were received in support of this work. No benefits in any form have been or will be received from a commercial party related directly or indirectly to the subject of this article.

#### ICMJE COI statement:

R. Vialle has a consulting agreement with Stryker spine and Nuvasive.

J. Taytard reports consultancy fees and payment for development of educational presentations from Roche, and expenses from ADEP Assistance, all unrelated to the study. C. Vergari reports an institutional grant from the BiomecAM chair program for the study. W. Skalli reports a grant from the Paris Tech Foundation, the BiomecAM chair program on subject-specific modeling, and financial support from the Cotrel Foundation, Proteor, Covea, and Societe Generale, related to the study. W. Skalli also reports patents and royalties related to the EOS system and associated 3D reconstruction methods.

This article was primary edited by A. C. Ross