



Science Arts & Métiers (SAM)

is an open access repository that collects the work of Arts et Métiers Institute of Technology researchers and makes it freely available over the web where possible.

This is an author-deposited version published in: <https://sam.ensam.eu>
Handle ID: <http://hdl.handle.net/10985/24202>



This document is available under CC BY-ND license

To cite this version :

Sandrine BOUSIGUES, Laurent GAJNY, Sharon ABIHSSIRA, Cécile HEIDSIECK, X. OHL, Nicola HAGEMEISTER, Wafa SKALLI - 3D reconstruction of the scapula from biplanar X-rays for pose estimation and morphological analysis - Medical Engineering and Physics - Vol. 120, p.104043 (1-17) - 2023

Any correspondence concerning this service should be sent to the repository

Administrator : scienceouverte@ensam.eu



3D reconstruction of the scapula from biplanar X-rays for pose estimation and morphological analysis

S. Bousigues (1), L. Gajny (1), S. Abihssira (1,2), C. Heidsieck (1), X. Ohl (3), N. Hagemeister (4), W. Skalli (1)

1. Arts et Métiers, Institut de Biomécanique Humaine Georges Charpak, Paris, France
2. Hand, Upper Limb and Peripheral Nerve Surgery, Georges-Pompidou European Hospital APHP
3. Hôpital Maison-Blanche, CHU de Reims, France
4. Ecole de Technologie Supérieure, Montréal, Canada

Abstract

Background: Patient-specific scapular shape in functional posture can be highly relevant to clinical research. Biplanar radiography is a relevant modality for that purpose with already two existing assessment methods. However, they are either time-consuming or lack accuracy. The aim of this study was to propose a new, more user-friendly and accurate method to determine scapular shape.

Methods: The proposed method relied on simplified manual inputs and an upgraded version of the first 3D estimate based on statistical inferences and Moving-Least Square (MLS) deformation of a template. Then, manual adjustments, with real-time MLS algorithm and contour matching adjustments with an adapted minimal path method, were added to improve the match between the projected 3D model and the radiographic contours. The accuracy and reproducibility of the method were assessed (with 6 and 12 subjects, respectively).

Findings: The shape accuracy was in average under 2 mm (1.3 mm in the glenoid region). The reproducibility study on the clinical parameters found intra-observer 95% confidence intervals under 3 mm or 3° for all parameters, except for glenoid inclination and Critical Shoulder Angle, ranging between 3° and 6°.

Interpretation: This method is a first step towards an accurate reconstruction of the scapula to assess clinical parameters in a functional posture. This can already be used in clinical research on non-pathologic bones to investigate the scapulothoracic joint in functional position.

Keywords:

Biplanar radiography, Scapula, 3D reconstruction, Patient specific modelling, Scapula coordinate system, Reproducibility study

Introduction

The importance of knowing the patient-specific shape of the scapula for surgical planning is widely acknowledged [1]. Clinical parameters such as glenoid size, version, and inclination are commonly calculated to select the most appropriate implant and its orientation [1]–[3]. Various imaging modalities can be used to assess scapular shape, such as MRI [4], CT-scan [5], and biplanar X-rays [6]–[8]. CT-scans remain the most accurate method of assessing scapular shape, particularly in the glenoid region.

Recent studies [9], [10] have shown that information on the position and the orientation of this bone can improve therapeutic management. In reverse total shoulder arthroplasty cases, the ideal retroversion angle for the humeral component appears associated with the orientation of the scapula [9]. Other areas of clinical research that could benefit from this data include rotator cuff tear pathologies [11], [12], and novel rehabilitation practices in patients with poor shoulder posture because of thoracic hyperkyphosis [13]. Parameters related to scapular position and orientation can be calculated using either external measurements, such as an inclinometer [14] or a goniometer [15], or medical imaging such as CT-scan, MRI or biplanar X-rays. A major drawback with CT-scans or MRI is that patients are in the supine position during acquisition. Therefore, biplanar radiography becomes an interesting alternative to obtain relevant information on both the shape and the orientation of the scapula while the patient is standing.

In order to obtain data on the clinical parameters and the orientation of the scapula, an accurate 3D reconstruction and a robust coordinate system are required. Various coordinate systems have been described in the literature [16]–[19] and many studies have assessed normal and abnormal scapular kinematics or pseudo-kinematics [12], [20], [21]. Recent studies show that a “glenoid-oriented” coordinate system [22] is worth considering when studying scapular kinematics, especially when a 3D model is available. Previously developed 3D reconstruction methods [23], [24] to quantify glenohumeral displacements [6], [8], and to study scapular pseudo-kinematics [12] have used biplanar radiography. However, these lacked accuracy, were too time-consuming and required intensive training. Indeed, the first method described requires an expert user and reconstruction takes about 20 minutes [6] and while the second method takes only 5 minutes for an expert user, the systematic error was more than 3 mm.[25].

The aim of this study was to propose a user-friendly 3D reconstruction method of the scapula based on biplanar radiographs and to assess its accuracy. Clinical parameters and a coordinate system were determined and calculations based on anatomical landmarks extracted from the 3D reconstructions. The reproducibility of these parameters and of the chosen scapular coordinate system was also assessed to further evaluate the method.

Methods :

Materials

1. Subjects

Biplanar radiographs from a previous study were collected retrospectively [8]. The study was approved by local ethics committees (CE09.261 – CHUM 2010-02-03, and BD07.001, Canada). Radiographs were taken in 40° axial rotation relative to the antero-posterior view of the patient with the EOS acquisition system (hereafter called Rx40) (fig. 1). This technique was

chosen to avoid bony superimposition of both shoulders and the spine observed with a strict lateral view (EOS Imaging, Montréal, Canada) [8]. The EOS acquisition system allows the simultaneous acquisition of two low-dose X-ray images in two orthogonal planes. The images collected were used to assess the reproducibility of the proposed method.

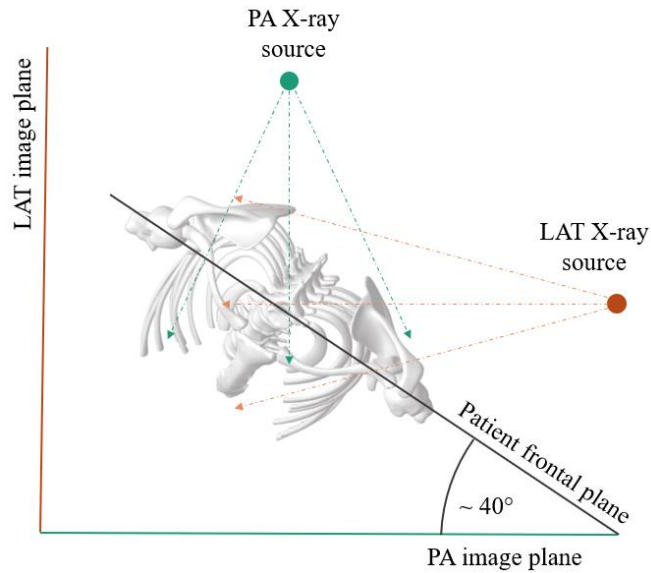


Figure 1: Orientation of the patient in the EOS cabin

To evaluate the accuracy of the method, CT-scans from six cadavers were used. There were no CT-scans of the patients for ethical reasons. To create artificial EOS images, biplane Digitally Reconstructed Radiographs (DRR), were generated from each scan using an internal software from a prior publication [26]. This process reproduces the vertical X-ray scanning method of the EOS system. DRR were generated to replicate in vivo EOS images, as if the patient was in the same Rx40 position (fig. 2).

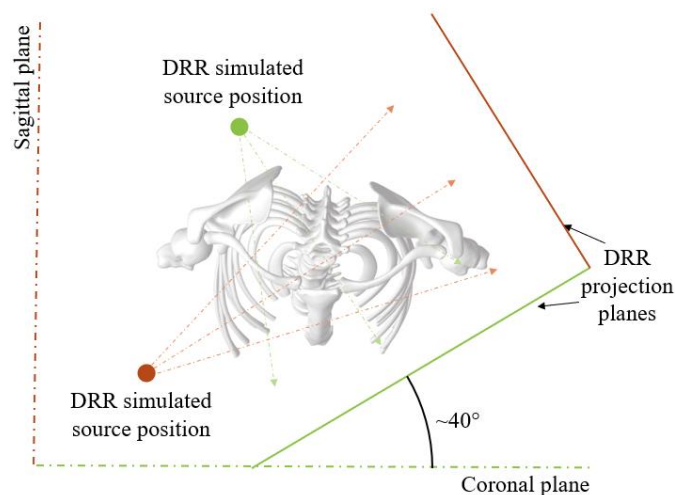


Figure 2: Digitally Reconstructed Radiographs (DRR) projection planes

2. 3D meshes database

A database of 40 scapula meshes described in a previous study [27] was used. Each scapula was meshed and registered using the Statismo software framework [7]:[28]. Elements annotated

on the 2D images will be referred to as landmarks and elements taken from the 3D reconstruction referred to as points. A mean mesh was generated from an in internal software and divided into seven main regions or landmarks (lateral and medial borders, glenoid, coracoid, acromial tip, scapular spine and scapular joint line) and sub-regions to assess more specific areas such as the anterior border of the glenoid. This produced a reduced number of points representing key 3D anatomical elements of the scapulae. The scapulae were then aligned using a local coordinate system based on three scapular landmarks: the glenoid inferior border, the scapular inferior angle and the trigonum spinae (TS). This database was used to generate a statistical model that will be described in the following section.

Methods

The reconstruction method involves the following steps: **1.** Anatomical landmarks (2D coordinates) were digitized on both radiographs. **2.** A first estimate was computed **3.** Interactive manual and semi-automatic adjustments were made. **4.** A coordinate system and **5.** Clinical parameters for the scapula were computed.

1. Anatomical landmark digitization on radiographs

The following landmarks were annotated on each radiograph: the inferior and superior borders of the glenoid, the inferior and superior angles of the scapula, the coracoid tip and the TS.

1.1. First estimate computation

The process is summarized in fig. 3 and detailed here.

From the 2D digitized stereo-corresponding landmarks, we computed the 3D coordinates of a primary set of points (fig. 3 a) and b)). A local coordinate system was computed for inference purposes (fig. 3b). All scapulae from the database were aligned according to this coordinate system.

The anterior and posterior borders of the glenoid were unclear on the frontal radiograph and the view altered by bony superimposition on the lateral radiograph. Hence, these were inferred before computing the first estimate. Data were inferred using a posterior shape model [29] (with 2 mm noise modelling to account for uncertainty in the manual annotations). The primary and additional point sets were then used to deform the above-mentioned scapula mean mesh.

Prior to mesh deformation, the primary and additional 3D points were also defined on the mean mesh (fig. 3d). Then, the mean mesh was deformed using a Moving Least Square (MLS) algorithm [30] to fit the model's landmarks to the annotated and inferred landmarks on the radiographs.

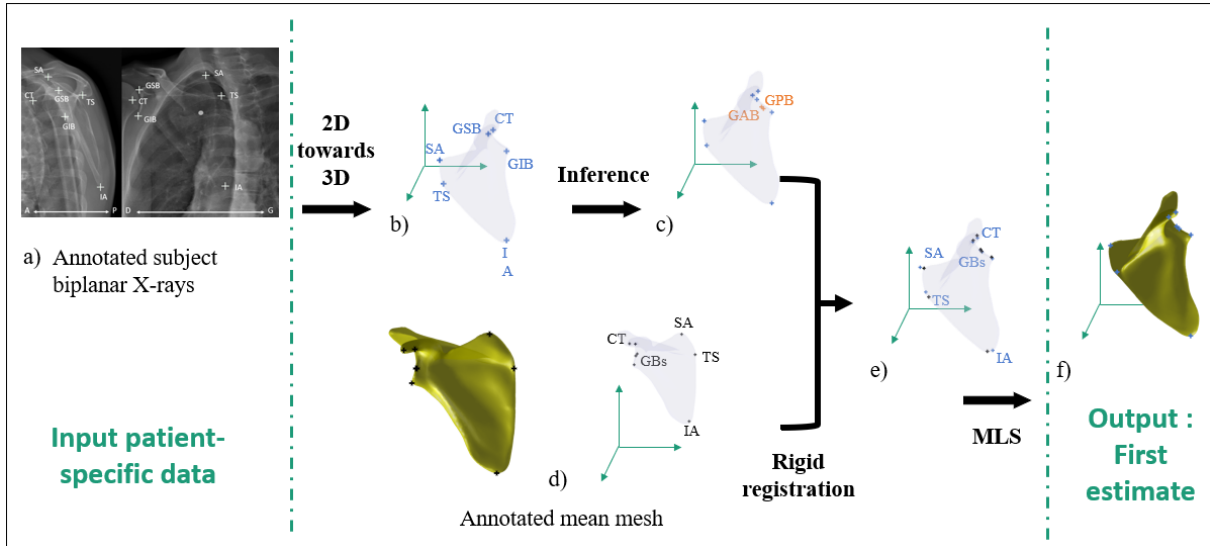


Figure 3 : a) Annotation step ; b) 3D primary set of points (CT : Coracoid Tip, GIB : Glenoid Inferior Border, GSB : Glenoid Superior Border, IA : Inferior Angle, SA : Superior Angle, TS : Trigonum Spinae) ; c) 3D annotated and inferred landmarks (GAB : Glenoid Anterior Border, GPB : Glenoid Posterior Border) ; d) Mean mesh and extracted landmarks (GBs : Glenoid Borders) ; e) 3D annotated and inferred landmarks (blue) and mean mesh extracted landmarks (black) ; f) 3D reconstruction first estimate

2. Interactive adjustments

2.1. Manual adjustments

The first estimate was projected onto both radiographs and the bony contours were extracted [31], [32]. Sixteen stereo-corresponding handles were then placed on the projected contours of the object (see fig. 4) at the coracoid process, the glenoid, the inferior angle, the superior angle, the root of the spine, and partially at the acromion. These handles were editable by the user to adjust the contours of the first estimate to the contours viewed on the radiographs. Each adjustment triggered real-time MLS [30] deformations of the first estimate. Then, if the operator needed to refine the acromion, another MLS deformation step with more specific landmarks was possible. This manual adjustment procedure was performed in three to five minutes, producing an estimate as close as possible to the final model, thus facilitating the next step.

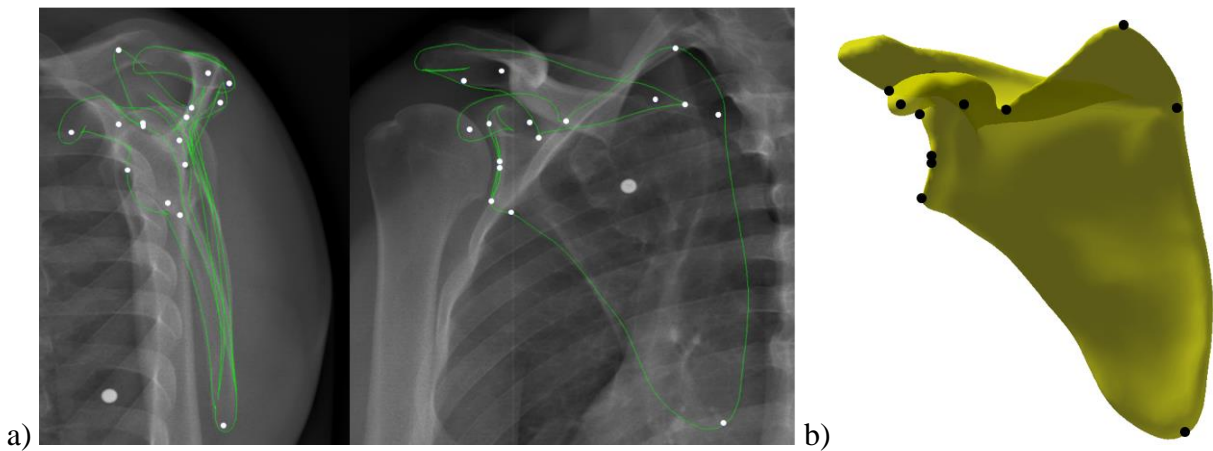


Figure 4: MLS deformation handle in the first phase of manual refinement a) : on the biplanar radiograph b) on a 3D model

2.2. Further adjustments

A Minimal Path Algorithm (MPA) [33] combined with a kriging algorithm [34] adapted from Girinon et al., [35] was then implemented for the final adjustments. First, a median recursive filter was applied to the images. Some of the contours of the coarse model were projected onto the images, and a search band was created around these contours. The gradient cost map was associated with the pixels forming this search strip.

Once the new contour was identified, the 3D object was deformed using a kriging algorithm to follow the new contour. An option was then added to the adapted minimal path method [36] to allow the operator to confirm that the contour was correctly identified.

3. Coordinate system definition

A scapula coordinate system (SCS) was proposed to quantify the position and orientation of the scapula. It was defined using three anatomical landmarks: the geometrical center of the glenoid, the TS and the Inferior Angle (IA) [17] (see fig. 5 d). The Z axis was then defined by the line between the center of the glenoid and the TS. The Y axis was the vector orthogonal to the plane defined by the center of the glenoid, the TS and the IA of the scapula. The X axis was orthogonal to the Z and the Y axes.

4. Clinical measurements

The following parameters, suggested in a previous study [7], [25] were automatically computed as described below and in fig. 5 :

- The height and width of the glenoid were computed as the distance between the inferior and superior borders of the glenoid and between the anterior and posterior borders, respectively [37] [38].
- The morphological inclination of the glenoid [25], [39]. Intrinsic to the shape of the scapula and therefore it does not vary whether the patient is in the supine or standing position.
- The inclination of the glenoid in a functional posture [25], [40]. Changes in a standing position and may vary according to the orientation of the scapula.
- The glenoid version [25]. Calculated in the plane defined by the TS, the glenoid anterior border (GAB) and the glenoid posterior border (GPB) to calculate the angle

between the orientation of the glenoid and the plane of the scapula passing through the TS and the centre of the glenoid.

- The Critical Shoulder Angle (CSA) [41]. Calculated between the vector defined by the inferior and superior borders of the glenoid and the vector defined by the glenoid's inferior border and the Critical Acromion Point [42].

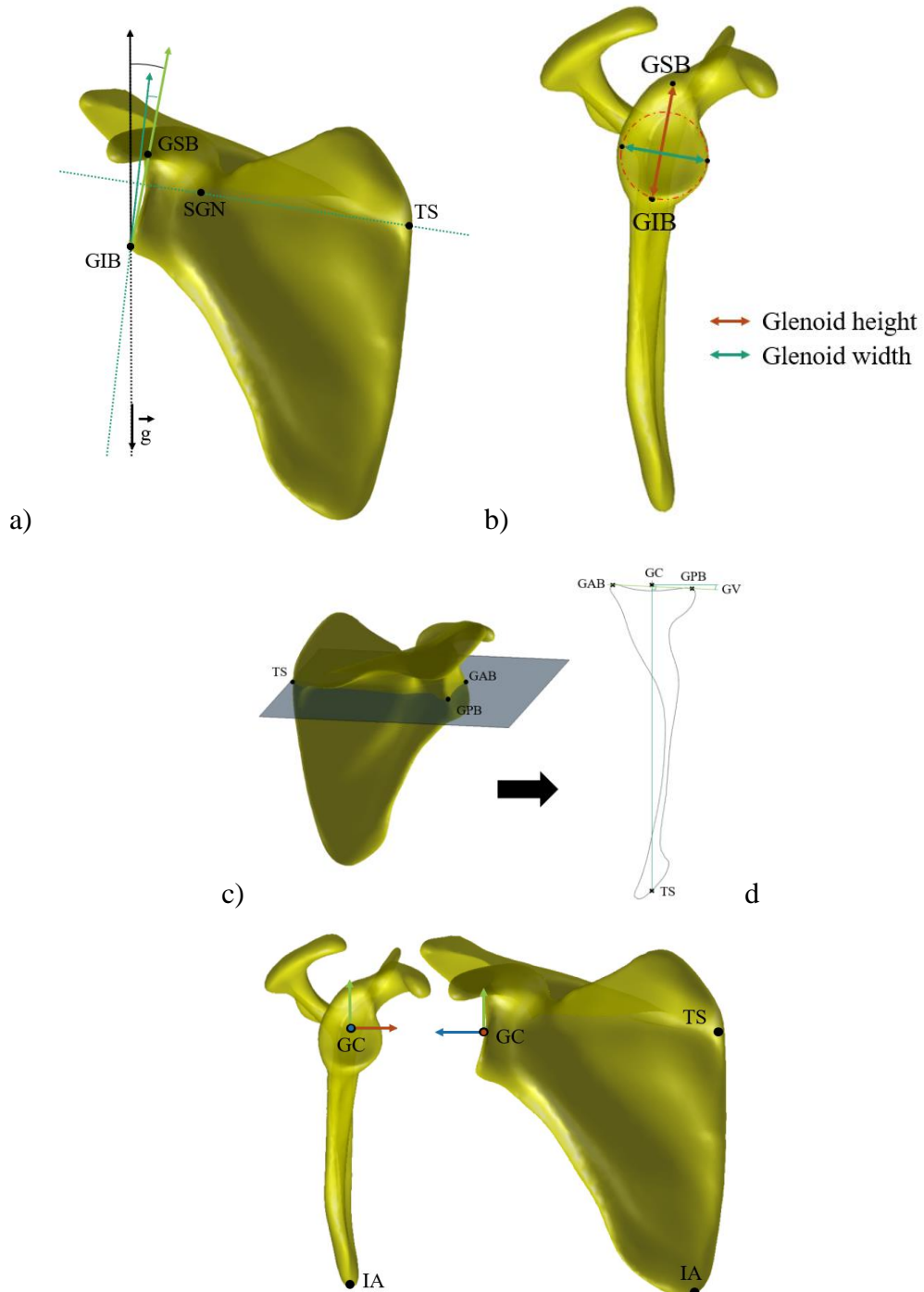


Figure 5 : Inspired from Zhang 2016 a) Positional inclination angle : angle between a vector collinear to the gravity vector (\vec{g}) oriented in the opposite direction and the vector defined by the inferior and superior rims of the glenoid ; Morphological inclination angle defined by a vector orthogonal to the SGN (Spino Glenoid Notch) and TS line oriented upwards and the GIB-BSG vector; CSA : 3D angle computed between the GIB-ASA vector and GIB-GSB vector
 b) Glenoid height and width, c) Glenoid version d) Scapular coordinate system: Scapular coordinate system (GC = Glenoid Centre, TS = Trigonum Spinae, IA= Inferior Angle)

5. Evaluation

5.1. Accuracy study

To evaluate the accuracy, the reconstruction method was applied to the DRRs from the six cadaver CT-scans. The CT images were also segmented and reconstructed using the Avisio software, as described in a previous study [25], to use the same mesh topology as the one for the EOS reconstructions. The 3D reconstructed scapulae from the DRRs were then compared to the CT-scan reconstructions using a point-to-surface metric. The average errors per region were computed with a metric considering point to point Euclidean distances (AVD : Average Distance) [43] as follows: For two finite sets of points A and B AVD was defined $AVD(A,B) = \max(d(A,B),d(B,A))$ with $d(A,B) = \frac{1}{N} \sum_{a \in A} \min_{b \in B} \|a - b\|$ with a and b, being points of the A and B sets. This metric is reciprocal, the value given does not depend on the direction in which it is calculated (from the object to the reference or from the reference to the object).

5.2. Reproducibility study

Reproducibility was evaluated using in vivo biplanar radiographs of 12 scapulae from 12 patients (six women, six men with a mean age of 58 years old (range: 53-64 years)). Three operators (one resident in shoulder surgery (OP1) and two biomedical engineers (OP2, OP3)) each performed the 3D reconstruction three times. The repeatability and reproducibility of the clinical parameters and the coordinate system positions and orientations were evaluated by computing the reproducibility standard deviation as recommended by the ISO 5725-2 standard, and the associated 95 % confidence interval. The reproducibility standard deviation (S_R) was computed as follows:

$$S_R = \sqrt{\frac{\sum_{i=1}^n S_{Ri}^2}{n}}$$

With $S_{Ri}^2 = S_{intra}^2 + S_{inter}^2$, S_{Ri}^2 being the reproducibility variance for the subject i computed as the sum of the intra operator variance (S_{intra}^2) and the inter operator variance (S_{inter}^2). 95% Confidence Interval (95% CI) was $2 * S_R$.

Results

1. Accuracy study

The overall mean error for the point-to-surface metric was 1.8 mm (with a standard deviation of 1.2 mm and a maximum of 13.1 mm on all the reconstructions). On the glenoid area, the mean bias was 1.3 mm with a standard deviation of 0.6 mm.

In the scapular areas, the mean point-to-surface error was less than 2 mm for the coracoid process and the glenoid, and between 2 and 3 mm for the acromion, the scapular spine, as well

as the lateral and medial borders. Local maxima were found at the medial border, the spine and the tip of the acromion and could reach 9 mm.

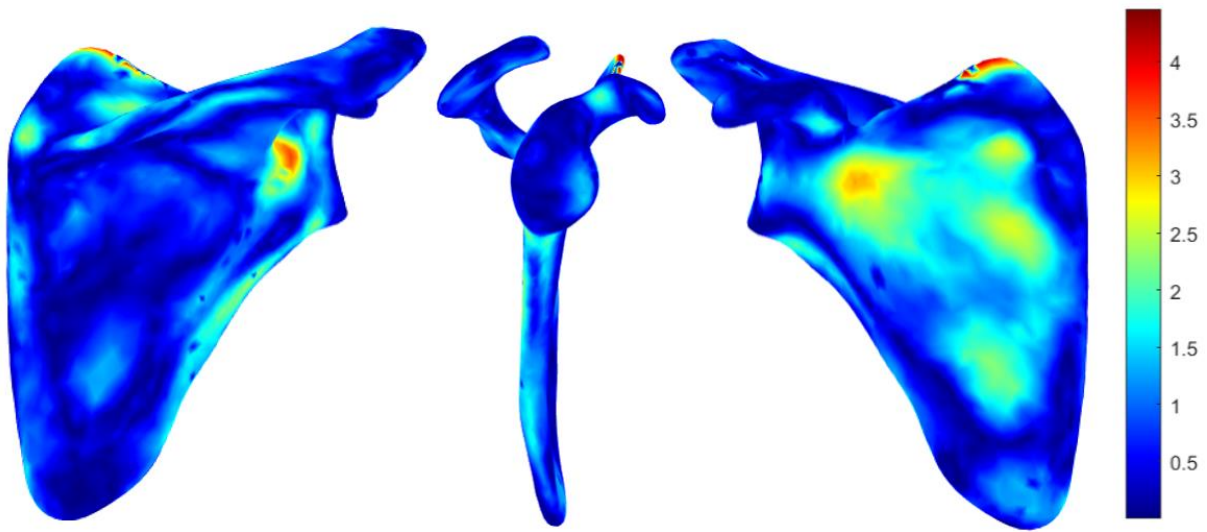


Figure 6: Mean error map obtained on the cadaveric scapulae between the 3D scan reconstruction and the EOS system 3D reconstruction using the presented method

2. Reproducibility study

Table 1 presents the 95% CI for inter observer reproducibility for the 108 reconstructions (3 operators x 3 repetitions x 12 pairs of radiographs).

The intra-observer 95% CI were under 3 mm or 3° for the clinical parameters except for the CSA and the glenoid inclination, with a 95% intra-observer CI between 3° and 6°.

These results are detailed further in fig. 7 with the Bland-Altman plots showing the clinical parameters.

The reproducibility for scapula position and orientation was less than 2 mm and 6° using the coordinate system presented above.

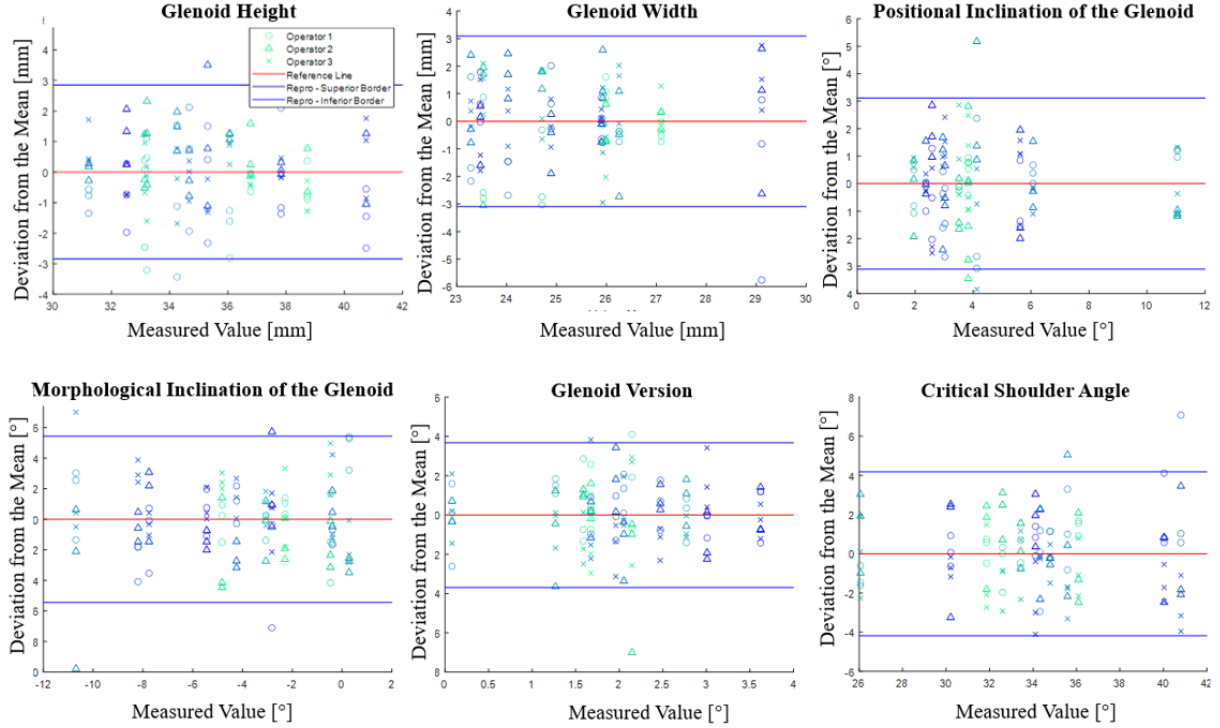


Figure 7: Glenoid height and width Bland-Altman plots

Discussion

1. Method

The 3D reconstruction of the scapula from biplanar radiographs comes with two imperatives: being user-friendly and precise. Two prior studies proposed a 3D reconstruction of the scapula from biplanar x-rays using the EOS system. Lagacé et al., [6] used seven positions and images to generate their reconstruction. Their method requires some back and forth between the images to refine the model. A later study [25] needed only one pair of images, but the accuracy and robustness needed to be improved. The method we propose here represents the next step in these endeavors, aiming to be both accurate and user-friendly.

First, we selected anatomical landmarks based on the following considerations. A study on the reproducibility of bony landmarks for the shoulder [44] reported that the coracoid tip and the glenoid inferior border had the best reproducibility. As the position of the scapula varies greatly, we chose to annotate landmarks like the Trigonum Spinae, the inferior angle of the scapula (easy to see on the lateral view), and the superior border of the glenoid. Although the visibility of the superior angle of the scapula can vary depending on the orientation of the scapula, we chose to keep it in the annotation process because it provides good information on the position of the scapula, when available.

Statistical shape models are used to infer the shape of an object from partial data (here, the annotated and inferred landmarks), while taking into consideration the variability of this object. Albrecht et al., [29] report a method to account for a “noise” or deviation from the model with partial data. This is particularly relevant with a manual annotation process where variations are common. The deviation from the model was approximately 2 mm, based on a preliminary study on the variability in manual annotation. The posterior shape model method was used to infer the anterior and posterior borders of the glenoid from the annotated landmarks.

These landmark points were inferred from a statistical model because of the variability associated with manual annotation input.

To be able to use the minimal path algorithm, an initial estimate close to the final estimate is necessary. This explains the manual adjustments made to the model prior to the further adjustments. For the latter, the most visible anatomical structures were chosen on the radiographs as candidates for the minimal path. The essential criterion when choosing an anatomical structure was to ensure it was isolated (no bony superimposition). One exception was made for the lateral border on the frontal view because the signal was strong, and the neighbouring bones are the ribs which would create orthogonal overlays.

Some modifications were made to the minimal path method previously used for femur reconstruction [36]. First, given that several factors impact the shape and view of the scapula, such as the position of the subject in the EOS booth and the position of the scapula in relation to the rib cage, we decided to let the operator choose the correctly identified contours to avoid altering the model.

One way to simplify this process would be to use automatic segmentation algorithms such as the one proposed by Namayega et al., [45]. As the initial annotation method has been simplified as much as possible, the proposed method is already usable for clinical research. Its use in different projects will make it possible to gather an annotation database and move towards more automatic methods of analysis and implementation in clinical routine.

Other studies have focused on measuring the kinematics of the shoulder with biplanar videography [46], [47]. However, these require a 3D reconstruction from a CT-scan or an MRI to generate the 3D model. In this context, the presented method offers an alternative to the CT scan/MRI for 3D reconstruction, reducing radiation exposure (CT) and lowering acquisition and processing costs.

2. Accuracy study

The reconstructions for the accuracy study were done by a non-expert operator. The overall and glenoid reconstruction errors were evaluated with the same metric as the one used in Zhang's study [7] to make consistent comparisons. The mean error for the overall shape of the scapula (1.8 mm) was lower than in the previous study (3.2 mm) [7], [25].

Local error maxima were found on the medial border, and the spine of the scapula. The shape of those structures was not of the greatest clinical interest, but their intersection marks the location of the Trigonum Spinae which is essential. Therefore, it may have an impact on the coordinate systems and some clinical parameters.

3. Reproducibility study

There was some discussion between an engineer and a clinician to standardize the annotation and the deformation process of a few anatomical landmarks. The glenoid inferior border, the scapular notch, the inferior angle and the trigonum spinae were the main landmarks discussed. The glenoid's inferior border is easy to see on the frontal view on healthy bones (with no major deformation), but harder to identify on the lateral view. A consensus was made to use the signal with the highest intensity. The inferior angle of the scapula was harder to standardize because it is difficult to see on the frontal view. There was no consensus for this landmark.

The trigonum spinae is a point of particular interest. It is critical to certain clinical parameters (the morphological inclination of the glenoid and glenoid version), and to compute coordinate systems. Hence, it is useful to characterize the shape and the position of the scapula. However, identifying its precise location remains challenging because of variations in the position of the scapula.

In terms of the clinical parameters, considering the anatomical variations found in the population, and the reproducibility results, glenoid height and glenoid inclination in a functional posture were the most robust.

4. Limitations

There are still limitations to this method. An important clinical parameter, glenoid version, was not among the most robust. It was computed using the anterior and posterior borders of the glenoid and the trigonum spinae [25]. However, the anterior and posterior borders of the glenoid are difficult to identify on radiographs. Considering that the angle is measured based on these border, and that the glenoid is a small structure, it is sensitive to small errors. This clinical parameter is commonly measured with a preoperative gleno-humeral joint CT-scan, either with an automatic calculation software or manually on the CT slices. This suggests that this method is not meant to replace CT-scans [48] particularly in case of major bone deformity, but will rather add complementary information.

For ethical reasons, we did not obtain CT-scan images of the individuals who underwent EOS acquisition. Therefore, two separate and independent studies were made to validate the proposed method. The first one used the EOS images to assess reproducibility. The second one used the CT-scans and DRR images to assess accuracy. The use of DRR may have had an impact on results, but they were generated with a process that replicates the one used for EOS X-rays, which should minimize this potential bias.

The manual adjustment process can also lead to some variability but is necessary because there is no baseline data. Manual adjustments will hopefully decrease as contour extraction methods evolve.

This method has not been tested on pathologic bones with major deformity (such as osteophytes, or erosion). Future studies focusing on posture could provide a better understanding of the scapulothoracic joint.

5. Perspectives

This method provides a reliable reconstruction of the patient's scapula in a standing position. It provides morphological and pose reproducible data on the scapula for clinical research on asymptomatic volunteers which is interesting to provide normative data. This tool also offers new avenues for studies aiming at a better understanding of the scapulothoracic and acromioclavicular joints. Several research avenues are possible including the impact of having a medialized, lower center of rotation on the scapulothoracic joint with a reverse prosthesis [3]. It may also be possible to study the effect of clavicle shortening on posture and the scapulothoracic joint by adding a clavicle model. This method may also improve our understanding of why there are asymptomatic patients with rotator cuff tears, while others experience a loss of mobility and pain. [12]. Finally, other studies have focused on spinal and thoracic 3D reconstructions [49], postural alignment [50] and on the 3D reconstruction of

thoracic structures [51]. Combining all those methods would make it possible to investigate the associations between spinal postural alignment and the scapulo-thoracic joint and compensate for the lack of information identified in the literature [52].

Conclusions

The method presented provides the user with good information on the overall shape of the scapula (with a mean error of 1.8 mm) and has the potential to be part of a more general assessment of its position since low-dose radiographs are taken with the patient in a functional posture. Therefore, we consider this method as a promising first step for a useful algorithm and a good complement to CT-scan examination. Nevertheless, it must be noted that a CT-scan may be needed when a more comprehensive assessment of the glenoid is necessary.

Acknowledgments

The authors thank the ParisTech BiomecAM chair program on subject-specific musculoskeletal modelling with the financial support of COVEA as well as the ETS Marcelle Gauvreau chair program. The authors thank Kathleen Beaumont for English editing of this article.

Statements

Competing interests: None declared

Funding: ParisTech BiomecAM chair program on subject-specific musculoskeletal modelling with the financial support of COVEA and the ETS Marcelle Gauvreau chair program

Ethical approval: CE09.261 – CHUM 2010-02-03, Canada

References

- [1] H. R. Hoenecke, J. C. Hermida, C. Flores-Hernandez, and D. D. D’Lima, ‘Accuracy of CT-based measurements of glenoid version for total shoulder arthroplasty’, *Journal of Shoulder and Elbow Surgery*, vol. 19, no. 2, pp. 166–171, Mar. 2010, doi: 10.1016/j.jse.2009.08.009.
- [2] R. J. Friedman, K. B. Hawthorne, and B. M. Genez, ‘The use of computerized tomography in the measurement of glenoid version.’, *The Journal of Bone & Joint Surgery*, vol. 74, no. 7, pp. 1032–1037, Aug. 1992, doi: 10.2106/00004623-199274070-00009.
- [3] P. Boileau, D. J. Watkinson, A. M. Hatzidakis, and F. Balg, ‘Grammont reverse prosthesis: Design, rationale, and biomechanics’, *Journal of Shoulder and Elbow Surgery*, vol. 14, no. 1, Art. no. 1, Jan. 2005, doi: 10.1016/j.jse.2004.10.006.
- [4] Z. Yang *et al.*, ‘Automatic bone segmentation and bone-cartilage interface extraction for the shoulder joint from magnetic resonance images’, *Phys. Med. Biol.*, vol. 60, no. 4, Art. no. 4, Feb. 2015, doi: 10.1088/0031-9155/60/4/1441.
- [5] S. Gupta and P. Dan, ‘Bone geometry and mechanical properties of the human scapula using computed tomography data’, *Trends Biomater. Artif. Organs.*, vol. 17, p. 10, 2004.
- [6] P. Y. Lagacé *et al.*, ‘3D reconstruction of the scapula from biplanar radiographs’, San Diego, California, USA, Feb. 2012, p. 83143L. doi: 10.1117/12.911527.
- [7] C. Zhang, ‘Contribution à la modélisation morphofonctionnelle 3D de l’épaule’, p. 145, 2016.
- [8] C. Zhang *et al.*, ‘Investigation of 3D glenohumeral displacements from 3D reconstruction using biplane X-ray images: Accuracy and reproducibility of the

- technique and preliminary analysis in rotator cuff tear patients’, *Journal of Electromyography and Kinesiology*, vol. 29, pp. 12–20, Aug. 2016, doi: 10.1016/j.jelekin.2015.08.002.
- [9] P. Moroder, ‘The influence of posture and scapulothoracic orientation on the choice of humeral component retrotorsion in reverse total shoulder arthroplasty’, p. 10.
- [10] P. Moroder *et al.*, ‘Patient Posture Affects Simulated ROM in Reverse Total Shoulder Arthroplasty: A Modeling Study Using Preoperative Planning Software’, *Clin Orthop Relat Res*, vol. 480, no. 3, pp. 619–631, Mar. 2022, doi: 10.1097/CORR.0000000000002003.
- [11] A. Yamamoto *et al.*, ‘The impact of faulty posture on rotator cuff tears with and without symptoms’, *Journal of Shoulder and Elbow Surgery*, vol. 24, no. 3, pp. 446–452, Mar. 2015, doi: 10.1016/j.jse.2014.07.012.
- [12] X. Ohl *et al.*, ‘3D scapular orientation on healthy and pathologic subjects using stereoradiographs during arm elevation’, *Journal of Shoulder and Elbow Surgery*, vol. 24, no. 11, Art. no. 11, Nov. 2015, doi: 10.1016/j.jse.2015.04.007.
- [13] S. Jung, U. Hwang, J.-H. Kim, G.-T. Gwak, and O. Kwon, ‘Effect of improved thoracic kyphosis on forward shoulder posture after mobilization in individuals with thoracic hyperkyphosis’, *Clinical Biomechanics*, vol. 97, p. 105707, Jul. 2022, doi: 10.1016/j.clinbiomech.2022.105707.
- [14] M. P. Johnson, P. W. McClure, and A. R. Karduna, ‘New Method to Assess Scapular Upward Rotation in Subjects With Shoulder Pathology’, *J Orthop Sports Phys Ther*, vol. 31, no. 2, Art. no. 2, Feb. 2001, doi: 10.2519/jospt.2001.31.2.81.
- [15] N. Short, M. Mays, R. Ford, and E. Fahrney, ‘Proposed method for goniometric measurement of scapular protraction and retraction’, *Journal of Hand Therapy*, vol. 34, no. 1, pp. 148–150, Jan. 2021, doi: 10.1016/j.jht.2019.02.002.
- [16] P. M. Ludewig, D. R. Hassett, R. F. LaPrade, P. R. Camargo, and J. P. Braman, ‘Comparison of scapular local coordinate systems’, *Clinical Biomechanics*, vol. 25, no. 5, pp. 415–421, Jun. 2010, doi: 10.1016/j.clinbiomech.2010.01.015.
- [17] C. D. Bryce, A. C. Davison, G. S. Lewis, L. Wang, D. J. Flemming, and A. D. Armstrong, ‘Two-Dimensional Glenoid Version Measurements Vary with Coronal and Sagittal Scapular Rotation’, *The Journal of Bone and Joint Surgery-American Volume*, vol. 92, no. 3, Art. no. 3, Mar. 2010, doi: 10.2106/JBJS.I.00177.
- [18] X. Ohl, P.-Y. Lagacé, F. Billuart, O. Gagey, W. Skalli, and N. Hagemeister, ‘Robustness and Reproducibility of a Glenoid-centered Scapular Coordinate System Derived from Low-dose Stereoradiography Analysis’, *Journal of Applied Biomechanics*, vol. 31, no. 1, pp. 56–61, Feb. 2015, doi: 10.1123/JAB.2013-0310.
- [19] G. Wu *et al.*, ‘ISB recommendation on definitions of joint coordinate systems of various joints for the reporting of human joint motion—Part II: shoulder, elbow, wrist and hand’, *Journal of Biomechanics*, vol. 38, no. 5, Art. no. 5, May 2005, doi: 10.1016/j.jbiomech.2004.05.042.
- [20] P. M. Ludewig, V. Phadke, J. P. Braman, D. R. Hassett, C. J. Cieminski, and R. F. LaPrade, ‘Motion of the Shoulder Complex During Multiplanar Humeral Elevation’, *The Journal of Bone and Joint Surgery-American Volume*, vol. 91, no. 2, pp. 378–389, Feb. 2009, doi: 10.2106/JBJS.G.01483.
- [21] A. R. Karduna, P. W. McClure, L. A. Michener, and B. Sennett, ‘Dynamic Measurements of Three-Dimensional Scapular Kinematics: A Validation Study’, *Journal of Biomechanical Engineering*, vol. 123, no. 2, Art. no. 2, Apr. 2001, doi: 10.1115/1.1351892.

- [22] C. W. Kolz *et al.*, ‘Reliable interpretation of scapular kinematics depends on coordinate system definition’, *Gait & Posture*, vol. 81, pp. 183–190, Sep. 2020, doi: 10.1016/j.gaitpost.2020.07.020.
- [23] T. Mutsvangwa, W. Wasswa, V. Burdin, B. Borotikar, and T. S. Douglas, ‘Interactive patient-specific 3D approximation of scapula bone shape from 2D X-ray images using landmark-constrained statistical shape model fitting’, in *2017 39th Annual International Conference of the IEEE Engineering in Medicine and Biology Society (EMBC)*, Jeju, Korea (South), Jul. 2017, pp. 1816–1819. doi: 10.1109/EMBC.2017.8037198.
- [24] R. L. Lawrence, K. Roseni, and M. J. Bey, ‘Correspondence between scapular anatomical coordinate systems and the 3D axis of motion: A new perspective on an old challenge’, *Journal of Biomechanics*, vol. 145, p. 111385, Dec. 2022, doi: 10.1016/j.jbiomech.2022.111385.
- [25] A.-M. Cauchon, P. Tétreault, C. Bascans, W. Skalli, and N. Hagemeister, ‘Morphologic and radiologic parameters correlating to shoulder function at diagnosis for patients with rotator cuff tear’, *Journal of Shoulder and Elbow Surgery*, vol. 29, no. 11, pp. 2272–2281, Nov. 2020, doi: 10.1016/j.jse.2020.03.027.
- [26] P. W. de Bruin, B. L. Kaptein, B. C. Stoel, J. H. C. Reiber, P. M. Rozing, and E. R. Valstar, ‘Image-based RSA: Roentgen stereophotogrammetric analysis based on 2D–3D image registration’, *Journal of Biomechanics*, vol. 41, no. 1, Art. no. 1, Jan. 2008, doi: 10.1016/j.jbiomech.2007.07.002.
- [27] X. Ohl, F. Billuart, P.-Y. Lagacé, O. Gagey, N. Hagemeister, and W. Skalli, ‘3D morphometric analysis of 43 scapulae’, *Surg Radiol Anat*, vol. 34, no. 5, pp. 447–453, Jul. 2012, doi: 10.1007/s00276-012-0933-z.
- [28] M. Luthi, T. Gerig, C. Jud, and T. Vetter, ‘Gaussian Process Morphable Models’, *IEEE Trans. Pattern Anal. Mach. Intell.*, vol. 40, no. 8, pp. 1860–1873, Aug. 2018, doi: 10.1109/TPAMI.2017.2739743.
- [29] T. Albrecht, M. Lüthi, T. Gerig, and T. Vetter, ‘Posterior shape models’, *Medical Image Analysis*, vol. 17, no. 8, Art. no. 8, Dec. 2013, doi: 10.1016/j.media.2013.05.010.
- [30] A. Cuno, C. Esperanca, A. Oliveira, and P. R. Cavalcanti, ‘3D As-Rigid-As-Possible Deformations Using MLS’, p. 8, 2007.
- [31] S. Benameur, M. Mignotte, S. Parent, H. Labelle, W. Skalli, and J. A. De Guise, ‘3D biplanar reconstruction of scoliotic vertebrae using statistical models’, in *Proceedings of the 2001 IEEE Computer Society Conference on Computer Vision and Pattern Recognition. CVPR 2001*, Dec. 2001, vol. 2, p. II–II. doi: 10.1109/CVPR.2001.991014.
- [32] S. Laporte, W. Skalli, J. A. De Guise, F. Lavaste, and D. Mitton, ‘A Biplanar Reconstruction Method Based on 2D and 3D Contours: Application to the Distal Femur’, *Computer Methods in Biomechanics and Biomedical Engineering*, vol. 6, no. 1, pp. 1–6, Feb. 2003, doi: 10.1080/1025584031000065956.
- [33] L. Vincent, ‘MINIMAL PATH ALGORITHMS FOR THE ROBUST DETECTION OF LINEAR FEATURES IN GRAY IMAGES’, p. 8.
- [34] F. Trochu, ‘A contouring program based on dual kriging interpolation’, *Engineering with Computers*, vol. 9, no. 3, pp. 160–177, Sep. 1993, doi: 10.1007/BF01206346.
- [35] F. Girinon, L. Gajny, S. Ebrahimi, L. Dagneaux, P. Rouch, and W. Skalli, ‘2 Quasi Automated Reconstruction Of The Femur From Bi-planar 3 X-rays’, p. 15.
- [36] F. Girinon, L. Gajny, S. Ebrahimi, L. Dagneaux, P. Rouch, and W. Skalli, ‘Quasi-automated reconstruction of the femur from bi-planar X-rays’, *Computer Methods in Biomechanics and Biomedical Engineering: Imaging & Visualization*, vol. 8, no. 5, pp. 529–537, Sep. 2020, doi: 10.1080/21681163.2020.1725915.
- [37] Y. W. Kwon, K. A. Powell, J. K. Yum, J. J. Brems, and J. P. Iannotti, ‘Use of three-dimensional computed tomography for the analysis of the glenoid anatomy’, *Journal of*

- Shoulder and Elbow Surgery*, vol. 14, no. 1, pp. 85–90, Jan. 2005, doi: 10.1016/j.jse.2004.04.011.
- [38] C. D. Bryce, A. C. Davison, G. S. Lewis, L. Wang, D. J. Flemming, and A. D. Armstrong, ‘Two-Dimensional Glenoid Version Measurements Vary with Coronal and Sagittal Scapular Rotation’, *The Journal of Bone and Joint Surgery-American Volume*, vol. 92, no. 3, pp. 692–699, Mar. 2010, doi: 10.2106/JBJS.I.00177.
- [39] J. L. Bishop, S. K. Kline, K. J. Aalderink, R. Zael, and M. J. Bey, ‘Glenoid inclination: In vivo measures in rotator cuff tear patients and associations with superior glenohumeral joint translation’, *Journal of Shoulder and Elbow Surgery*, vol. 18, no. 2, Art. no. 2, Mar. 2009, doi: 10.1016/j.jse.2008.08.002.
- [40] P. Habermeyer, P. Magosch, V. Luz, and S. Lichtenberg, ‘Three-Dimensional Glenoid Deformity in Patients with Osteoarthritis: A Radiographic Analysis’, *The Journal of Bone & Joint Surgery*, p. 8, 2006.
- [41] B. K. Moor, S. Bouaicha, D. A. Rothenfluh, A. Sukthakar, and C. Gerber, ‘Is there an association between the individual anatomy of the scapula and the development of rotator cuff tears or osteoarthritis of the glenohumeral joint?: A radiological study of the critical shoulder angle’, *The Bone & Joint Journal*, vol. 95-B, no. 7, pp. 935–941, Jul. 2013, doi: 10.1302/0301-620X.95B7.31028.
- [42] M. R. Karns, M. Jacxsens, W. J. Uffmann, D. C. Todd, H. B. Henninger, and R. T. Burks, ‘The critical acromial point: the anatomic location of the lateral acromion in the critical shoulder angle’, *Journal of Shoulder and Elbow Surgery*, vol. 27, no. 1, pp. 151–159, Jan. 2018, doi: 10.1016/j.jse.2017.08.025.
- [43] A. A. Taha and A. Hanbury, ‘Metrics for evaluating 3D medical image segmentation: analysis, selection, and tool’, *BMC Med Imaging*, vol. 15, no. 1, p. 29, Dec. 2015, doi: 10.1186/s12880-015-0068-x.
- [44] X. Ohl, C. Stanchina, F. Billuart, and W. Skalli, ‘Shoulder bony landmarks location using the EOS® low-dose stereoradiography system: a reproducibility study’, *Surg Radiol Anat*, vol. 32, no. 2, Art. no. 2, Feb. 2010, doi: 10.1007/s00276-009-0566-z.
- [45] C. Namayega, B. Malila, T. S. Douglas, and T. E. M. Mutsvangwa, ‘Contour detection in synthetic bi-planar X-ray images of the scapula: Towards improved 3D reconstruction using deep learning’, in *2020 IEEE 20th International Conference on Bioinformatics and Bioengineering (BIBE)*, Cincinnati, OH, USA, Oct. 2020, pp. 303–307. doi: 10.1109/BIBE50027.2020.00056.
- [46] M. Akbari-Shandiz, R. L. Lawrence, A. M. Ellingson, C. P. Johnson, K. D. Zhao, and P. M. Ludewig, ‘MRI vs CT-based 2D-3D auto-registration accuracy for quantifying shoulder motion using biplane video-radiography’, *Journal of Biomechanics*, vol. 82, pp. 375–380, Jan. 2019, doi: 10.1016/j.jbiomech.2018.09.019.
- [47] R. L. Lawrence, R. Zael, and M. J. Bey, ‘Measuring 3D In-vivo Shoulder Kinematics using Biplanar Videoradiography’, 2021.
- [48] J. J. Reid, B. F. Kunkle, A. T. Greene, J. K. Eichinger, and R. J. Friedman, ‘Variability and reliability of 2-dimensional vs. 3-dimensional glenoid version measurements with 3-dimensional preoperative planning software’, *Journal of Shoulder and Elbow Surgery*, vol. 31, no. 2, pp. 302–309, Feb. 2022, doi: 10.1016/j.jse.2021.07.011.
- [49] L. Gajny, S. Ebrahimi, C. Vergari, E. Angelini, and W. Skalli, ‘Quasi-automatic 3D reconstruction of the full spine from low-dose biplanar X-rays based on statistical inferences and image analysis’, *Eur Spine J*, vol. 28, no. 4, Art. no. 4, Apr. 2019, doi: 10.1007/s00586-018-5807-6.
- [50] C. Vergari *et al.*, ‘Quasi-automatic early detection of progressive idiopathic scoliosis from biplanar radiography: a preliminary validation’, *Eur Spine J*, vol. 28, no. 9, Art. no. 9, Sep. 2019, doi: 10.1007/s00586-019-05998-z.

- [51] B. Aubert, C. Vergari, B. Ilharreborde, A. Courvoisier, and W. Skalli, '3D reconstruction of rib cage geometry from biplanar radiographs using a statistical parametric model approach', *Computer Methods in Biomechanics and Biomedical Engineering: Imaging & Visualization*, vol. 4, no. 5, Art. no. 5, 2014, doi: 10.1080/21681163.2014.913990.
- [52] E. Barrett, 'Is thoracic spine posture associated with shoulder pain, range of motion and function? A systematic review', *Manual Therapy*, p. 9, 2016.