



Science Arts & Métiers (SAM)

is an open access repository that collects the work of Arts et Métiers Institute of Technology researchers and makes it freely available over the web where possible.

This is an author-deposited version published in: <https://sam.ensam.eu>
Handle ID: <http://hdl.handle.net/10985/24823>

To cite this version :

Tristan LANGLAIS, Alois BOUY, Gauthier ELOY, Nicolas MAINARD, Wafa SKALLI, Claudio VERGARI, Raphael VIALLE - Sagittal plane assessment of manual concave rod bending for posterior correction in adolescents with idiopathic thoracic scoliosis (Lenke 1 and 3) - Orthopaedics & Traumatology: Surgery & Research - Vol. 109, n°6, p.103654 (1-6) - 2023

Any correspondence concerning this service should be sent to the repository

Administrator : scienceouverte@ensam.eu



Original article

Sagittal plane assessment of manual concave rod bending for posterior correction in adolescents with idiopathic thoracic scoliosis (Lenke 1 and 3)

Tristan Langlais^{a,b,c,*}, Alois Bouy^a, Gauthier Eloy^a, Nicolas Mainard^a, Wafa Skalli^b, Claudio Vergari^b, Raphaël Vialle^a

^a Service d'orthopédie pédiatrique, hôpital Armand-Trousseau, Sorbonne université, Paris, France

^b Institut de Biomécanique Humaine Georges Charpak-IBHGC, Arts et Métiers Institute of Technology, Université Sorbonne Paris Nord, HESAM Université, 75013 Paris, France

^c Service d'orthopédie pédiatrique, hôpital des Enfants, Purpan, Toulouse université, Toulouse, France

A B S T R A C T

Objectives: The objectives of this study were to evaluate the repeatability and reproducibility of a method for measuring freehand rod bending and to analyze the relationship between the rod's bend and the resulting sagittal correction.

Materials and methods: All the children who underwent correction by posterior translation using pedicle screws at all levels were included prospectively in 2018 and 2019. The rod's sagittal parameters were measured retrospectively by three independent surgeons on two separate occasions using the same protocol. After the rods were bent but before they were inserted, the surgeon traced the contours of the rods on a sheet of paper that was later scanned and analyzed semiautomatically. The spinal parameters were calculated based on biplanar radiographs taken preoperatively, postoperatively and at the final follow-up visit. Patients who had less than 10° thoracic kyphosis (T5–T12) made up the "Lenke N–" subgroup.

Results: Thirty patients were included (14 of whom were Lenke N–) who had a Cobb angle of $59.2 \pm 11.3^\circ$ preoperatively and $13.3 \pm 8.4^\circ$ postoperatively ($p < 0.00001$). The inter- and intrarater ICC for the rod measurements were > 0.9 (excellent). The mean kyphosis of the concave rod was $48.4 \pm 5.7^\circ$ (38.3 – 60.9°). The mean change in T5–T12 kyphosis was $9.7 \pm 10.8^\circ$ (-14.3 – 30.8°) ($p < 0.0001$) in the entire population, while it was $17.7 \pm 7.1^\circ$ (5.5 – 30.8°) ($p < 0.0001$) in the Lenke N– subgroup. The change in thoracic kyphosis was positively correlated with the kyphosis of the concave rod ($\rho = 0.52$; $p = 0.003$).

Conclusion: This study found excellent reproducibility and repeatability of measuring freehand rod bending. The kyphosis applied to the concave rod is positively correlated to the change in the resulting kyphosis and made it possible to restore satisfactory thoracic kyphosis.

Level of evidence: III.

1. Introduction

Idiopathic thoracic scoliosis often causes thoracic hypokyphosis secondary to rotation of the apical vertebra [1,2]. Surgery consists of a correction then fusion, which in most instances is a long-lasting solution [3]. The objective of balanced three-dimensional correction [4] is to simultaneously:

- restore balance in the shoulders and waist;
- lessen the gibbus deformity;
- ensure the intervertebral disc at the interior end is horizontal [5];
- provide thoracic kyphosis appropriate for the patient.

Several posterior translation techniques are effective for restoring thoracic kyphosis such as sublaminar fixation [6] and all-pedicle screw fixation [7,8]. This translation can be applied to a single concave rod, a single convex rod or both at the same time [9]. The correction technique, rod bend, and type of rod alloy can impact the correction achieved [7,10]. Rod bending is a delicate step involving the meticulous application of a freehand curvature that cannot be

* Corresponding author. Service d'orthopédie pédiatrique, hôpital des Enfants, Purpan, 330, avenue de la Grande-Bretagne, 31030 Toulouse, France.
E-mail address: tristanlanglais@yahoo.fr (T. Langlais).

quantified easily but is crucial to restoring sagittal balance. Few studies have investigated and analyzed freehand bending [11,12].

Consequently, we asked ourselves the following questions: can freehand bending of the rod be measured in a reliable manner? Does this bending restore the sagittal balance? We hypothesized that there is a reliable method for measuring the rod bend applied by the surgeon that can be used to analyze its effects on sagittal balance for correcting idiopathic scoliosis. Thus, the objectives of this study were to evaluate the repeatability and reproducibility of a method for measuring freehand rod bending and to analyze the relationship between the rod's bend and the resulting sagittal correction.

2. Materials and methods

2.1. Patients

All the children who underwent posterior fusion for idiopathic adolescent thoracic scoliosis (Lenke 1 and 3) [13] were enrolled consecutively and prospectively in 2018 and 2019. Surgery was proposed when the Cobb angle was greater than 40°, the Risser sign was grade 3 or higher, the triradiate cartilage was closed and a coronal imbalance and/or thoracic hypokyphosis (i.e., T5–T12 angle less than 10°) was observed. Exclusion criteria were a transitional vertebrae, prior surgery on the spine and traction by halo brace. Biplanar radiographs were made preoperatively, postoperatively (5 to 7 days post-surgery) and at the final follow-up visit in a standardized standing position [14].

Two subgroup analyses were carried out:

- using the criteria of Lenke et al. [13], a “Lenke N–” subgroup was made up of patients whose T5–T12 angle was less than 10°;
- using the four sagittal classifications described by Abelin-Genevois et al. [1,15].

The study was approved by our ethics committee. Each patient's legal guardian was informed of the study and provided written consent.

2.2. Surgical technique

All patients were operated on by the same surgeon using the same technique [7]. Once the polyaxial screws (Xia® 3 Spinal System, Stryker) were inserted at each level, the length of the 6 mm CoCr concave rod was measured then bent manually using a spinal rod bender. Reduction was done by progressive posteromedial translation through posterior traction tubes (SUK Reduction Tubes, Xia 3, Stryker) on the concave rod. The 6 mm CoCr convex rod was measured, bent manually and then implanted as a neutralization rod. The goal was to achieve between 10 and 40° of thoracic kyphosis.

2.3. Semi-automated measurement of rod parameters

The rod parameters were measured retrospectively using a standardized protocol. After bending the rods but before implanting them, the surgeon traced the contour of each rod on a sheet of paper (blue line on Fig. 1B) and labeled its orientation. The sheet was scanned and analyzed by an application developed using MATLAB 2020b software (The MathWorks, Inc. Natick, MA). A surgeon placed 10 points (including the ends of the rod) along the rod's length (red dots on Fig. 1B). The software automatically marked the contour of the rod (solid red line on Fig. 1B) and then calculated the maximum thoracic kyphosis and lumbar lordosis generated from the tangent lines (dotted black line on Fig. 1B), which correspond

Table 1
Characteristics of study population (n = 30).

Features	
Sex	28 girls 2 boys
Mean age at surgery (years)	14.4 (12–17)
Mean follow-up (months)	24.5 (22–26.5)
Type of curvature – Lenke (n)	1 (19) 3 (11)
Proximal apex vertebra (n)	T2 (7) T3 (16) T4 (6) T5 (1)
Distal apex vertebra (n)	L1 (1) L2 (6) L3 (14) L4 (9)

to the rod's inflexion point (red “X” on Fig. 1B). Two measurements for each rod (concave and convex) were done at two different times by three surgeons who were not involved in the original surgical procedure.

2.4. Measurement of sagittal spinal parameters

These measurements were done using a previously validated 3D quasi-automatic method [16] (Fig. 1A and C). The hypokyphosis index was defined as the difference between the patient's local kyphosis (or lordosis) at the apex of the thoracic curvature and mean value at the equivalent level for persons without scoliosis [17,18]. Posterior translation of the apical vertebra of the thoracic curvature [19] was calculated by projecting the anatomical center of the vertebra in the axial plane, relative to a vertical axis centered on the hips. Posterior translation of the apical vertebra corresponded to a positive value.

2.5. Statistical analysis

An intraclass correlation coefficient (ICC) > 0.90 corresponded to excellent intra- and interrater reliability. A Bland-Altman plot [20] was used to determine the limits of interrater reliability for the measurement of concave thoracic kyphosis, the primary endpoint for this study. Quantitative data were compared using the Wilcoxon test or the Mann-Whitney test. A Spearman test was used to analyze the correlation between quantitative variables. The change in thoracic kyphosis was the difference between post- and preoperative kyphosis. A *p*-value < 0.05 was considered a significant difference. Simple linear regression was used to analyze:

- the relationship between changes in thoracic kyphosis obtained relative to the concave rod's thoracic kyphosis for each patient;
- the relationship between preoperative T5–T12 kyphosis with the difference between the mean kyphosis applied to the concave rod and the postoperative thoracic kyphosis measured.

The Real Statistics Resource Pack (version 7.6) was used for these tests.

3. Results

3.1. Patients

Thirty-two patients were enrolled in the study. Two were subsequently excluded (Table 1) because of incomplete radiographs and/or incorrect positioning during the radiographs. Fourteen

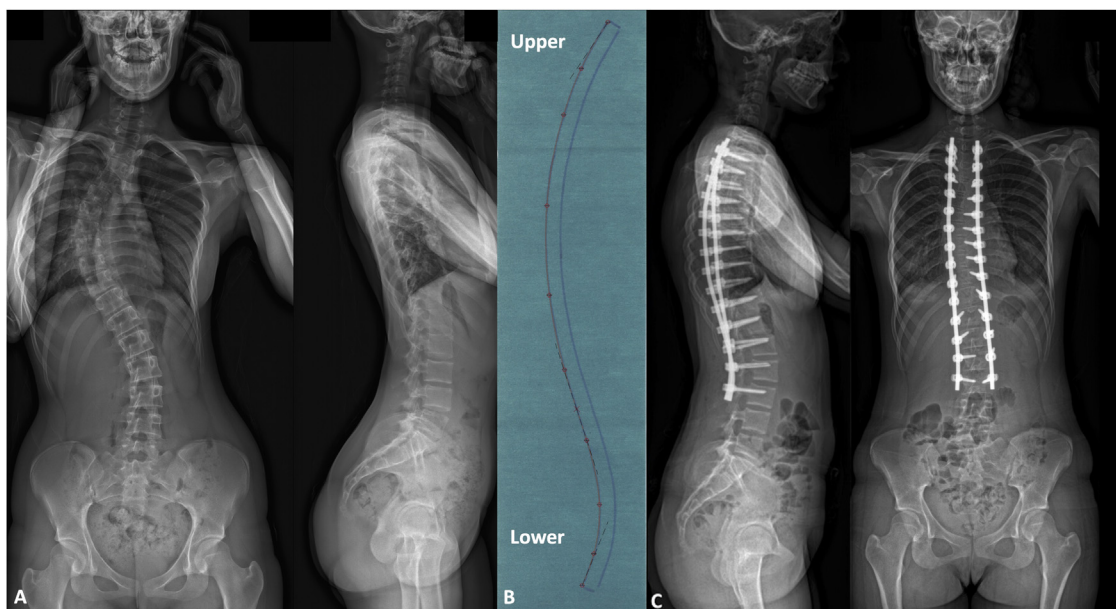


Fig. 1. Preoperative radiographs of a female adolescent with thoracic lordosis (A). The thoracic kyphosis is 46.4° on the concave rod and the lordosis is 40.9° (B). The postoperative T5–T12 kyphosis is 21.2° (C).

patients were in the Lenke N– subgroup. In the Abelin-Genevois classification, 9 patients were type 1, 20 patients were type 2a and 1 patient was type 3; the latter patient’s thoracic kyphosis was 35.7° preoperatively and 38.9° postoperatively, the lumbar lordosis went from 69.7 to 57.3° and the Cobb angle changed from 48.8 to 15.1° .

3.2. Rod parameters

The mean intrarater ICC was 0.95 for the concave rod’s kyphosis and 0.95 for the lordosis, while it was 0.96 for the convex rod’s kyphosis and 0.95 for the lordosis. The interrater ICC was 0.93 for the kyphosis and 0.94 for the lordosis of the concave rod. It was 0.94 for the kyphosis and 0.96 for the lordosis of the convex rod. Fig. 2 shows the variability between raters.

The mean kyphosis for the concave rod was $48.4^\circ \pm 5.7^\circ$ (38.3° – 60.9°); it was $49.7^\circ \pm 4.9^\circ$ (39.6° – 58°) ($p=0.1$) for the convex rod. The mean lordosis for the concave rod was $37.4 \pm 8.2^\circ$ (20.5 – 53.2°); it was $37.7^\circ \pm 7.6^\circ$ (21.3° – 50.9°) ($p=0.7$) for the convex rod. The mean difference per patient between the left and right rods was $3.5^\circ \pm 3.1^\circ$ (0.3° – 14.3°) for kyphosis and $3.6^\circ \pm 2.4^\circ$ (0.1° – 8.6°) ($p=0.7$) for lordosis.

3.3. Sagittal spinal parameters

In the entire study population, the mean change in T5–T12 kyphosis was $9.7^\circ \pm 10.8^\circ$ (-14.3° – 30.8°) ($p<0.0001$) and while it was $17.7^\circ \pm 7.1^\circ$ (5.5° – 30.8°) ($p<0.0001$) in the Lenke N– subgroup. All the Lenke N– patients had thoracic kyphosis greater than the minimum target level ($>10^\circ$) (Fig. 1C). The lumbar lordosis increased significantly only in the Lenke N– subgroup ($p=0.01$) (Table 2).

Patients who were classified as type 2a in the Abelin-Genevois classification had better thoracic kyphosis restoration ($p<0.0001$) and hypokyphosis index reduction ($p<0.001$) (Table 3).

The kyphosis of the concave rod was negatively correlated with preoperative kyphosis ($\rho=-0.40$; $p=0.02$), which means that concave bending of the thoracic kyphosis was greater in cases of thoracic hypokyphosis. The change in thoracic kyphosis was positively correlated with the kyphosis of the concave rod ($\rho=0.52$; $p=0.003$). Fig. 3 shows the relationship between the variation in

thoracic kyphosis achieved relative to the kyphosis of the concave rod for each patient ($R^2=0.35$) while Fig. 4 shows how the rod’s bending affected the outcome ($R^2=0.55$).

There was no significant difference between the spinal parameters measured at the final follow-up (mean of 24.5 months; 22–26.5) and immediate postoperative period ($p>0.05$).

4. Discussion

4.1. Analysis of rod bending

Previous studies [11,12] have used a similar method in which the contour of the rods is traced. The maximum curvature was measured from tangent lines on the tracings; we also calculated the lumbar lordosis. For the first time, an inter/intrarater analysis (30×2 measurements by parameter $\times 2$ rods/rater) was done and concluded the ICC was excellent.

In our study, the correction technique is based on the concave rod. The convex rod acts as a neutralization rod, thus its measured kyphosis is nearly the same as the concave rod ($p=0.1$). The difference in bending was less than 5° while Le Navéaux et al. [11] reported a mean difference of about 15° between convex and concave rods. The difference in bending is typically due to surgeon preference or the surgical strategy. In the translation technique, it is typical to under-contour the thoracic kyphosis of the convex rod to lessen the gibbus deformity due to rib crushing, although this is a theoretical concept. We did not measure the clinical gibbus deformity in our study. The convex rod must be perfectly bent to match the profile achieved by the concave correction if we want to avoid excessive loading on the convex implants. This was important in our study since the rods used were 6 mm CoCr devices, with a high risk of implant pullout.

In the translation technique using a single concave rod, the alloy material chosen for the rod is also important. It must be deformable before it is implanted but still maintain its elastic strength so the target correction can be achieved. CoCr alloy has a higher modulus of elasticity than titanium, but a lower limit of elasticity.

No study has evaluated the learning curve for freehand rod bending, which remains operator dependent. This step can be eliminated by using patient-specific pre-bent rods [9]. However, using

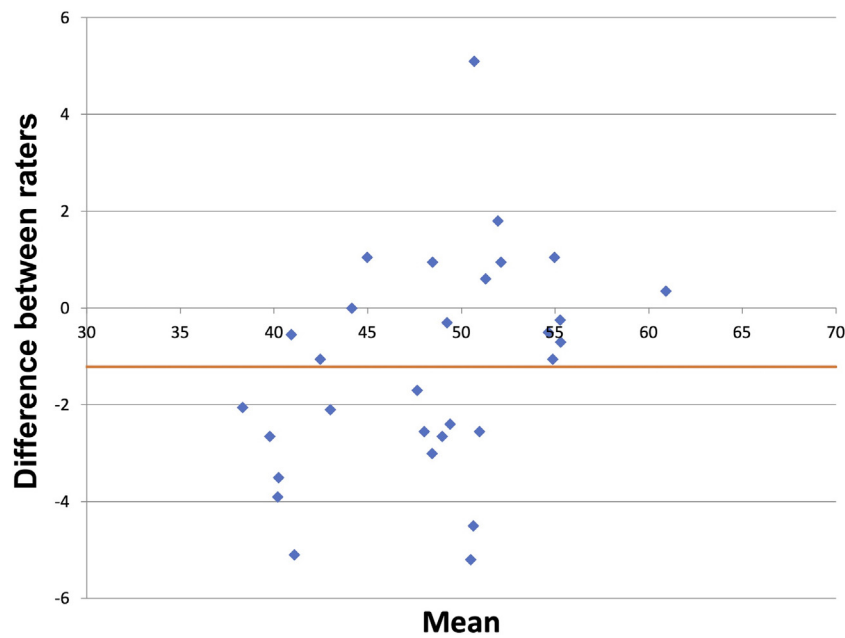


Fig. 2. Bland-Altman plot showing the interrater variability for the measurement of the concave rod's thoracic kyphosis. The mean of differences is shown as a horizontal line.

Table 2
Spinal parameters in the entire study population and in the Lenke N- subgroup.

	Entire population (n=30)				Lenke N- (n=14)			
	Preoperative	Postoperative	Final review	<i>p</i> ^a	Preoperative	Postoperative	Final review	<i>p</i> ^a
Cobb angle (°)	59.2 ± 11.3 (42.4–81.8)	13.3 ± 8.4 (2.3–30.4)	17.3 ± 6.6 (5.9–29.1)	<0.00001	62.5 ± 9.4 (42.5–74.1)	18.2 ± 6 (11.8–28.5)	20.5 ± 8.6 (5.9–27.3)	<0.00001
Kyphosis T5–T12 (°)	17.3 ± 13.2 (–4.7; 50.6)	27.0 ± 8.4 (14.9; 51.8)	26.5 ± 9.6 (12.3; 53.3)	<0.0001	5.9 ± 4.3 (–4.7; 9.4)	23.6 ± 7.1 (14.9; 39.8)	23.2 ± 8.4 (12.3; 40.6)	<0.0001
Lordosis L1–S1 (°)	47.8 ± 10.8 (28.7; 69.7)	47.7 ± 12 (17.2; 63.1)	50.8 ± 9.8 (23.8; 65.2)	0.4	43.9 ± 7.7 (28.7; 57.1)	51 ± 11.2 (28.8; 62.6)	50.8 ± 12.6 (30.3; 61.8)	0.01
Hypokyphosis index (°)	–4.9 ± 3.1 (–10; 0.9)	–2.8 ± 2.4 (–8.2; 1.9)	–2.3 ± 2.4 (–6.6; 2.7)	0.002	–7 ± 1.7 (–9; –4.3)	–2.2 ± 2.9 (–8.2; 1.9)	–2.4 ± 2.3 (–6.6; 2.5)	<0.001
Translation apical vertebra (mm)	12 ± 9.2 (0.2–32.7)				19 ± 5.9 (8–32.7)			

^a For the pre- or postoperative comparison.

Table 3
Spinal parameters by Abelin-Genevois subtype (1 and 2a^b).

	Type 1 (n=9)				Type 2a (n=20)			
	Preoperative	Postoperative	Final review	<i>p</i> ^a	Preoperative	Postoperative	Final review	<i>p</i> ^a
Cobb angle (°)	61 ± 13.9 (43.2–81.8)	10.5 ± 6.1 (3.7–21.5)	15.3 ± 7.7 (6.7–27.3)	<0.00001	58.9 ± 10.2 (42.4–74.1)	14.4 ± 9.4 (2.3–30.4)	19.8 ± 5.8 (5.9–29.1)	<0.00001
Kyphosis T5–T12 (°)	30.7 ± 10.3 (20.9; 50.6)	29.5 ± 9.7 (19.9; 51.8)	30.6 ± 11.4 (18; 53.3)	0.37	10.3 ± 8.2 (–4.7; 29.5)	25.3 ± 7.4 (14.9; 43.2)	24.4 ± 7.7 (12.3; 40.6)	<0.0001
Lordosis L1–S1 (°)	49.8 ± 11.6 (34.9; 69.7)	46.7 ± 11.7 (29.9; 63.1)	52 ± 11 (31.7; 65.2)	0.10	45.7 ± 9.4 (28.7; 67.7)	47.5 ± 12.6 (17.2; 62.6)	49.7 ± 9.3 (23.8; 62.5)	0.27
Hypokyphosis index (°)	–2.8 ± 3.5 (–10; 0.3)	–2.3 ± 1.6 (–4.6; 0.7)	–2.3 ± 1.9 (–5.3; –0.1)	0.45	–6 ± 2.4 (–9; 0.9)	–3.2 ± 2.6 (–8.2; 1.9)	–2.5 ± 2.4 (–6.6; 2.7)	<0.001
Translation apical vertebra (mm)	4.8 ± 2.6 (0.2–10.5)				15.9 ± 9 (0.6–32.7)			

^a For the pre- or postoperative comparison.

^b The values for the single patient with type 3 are not shown.

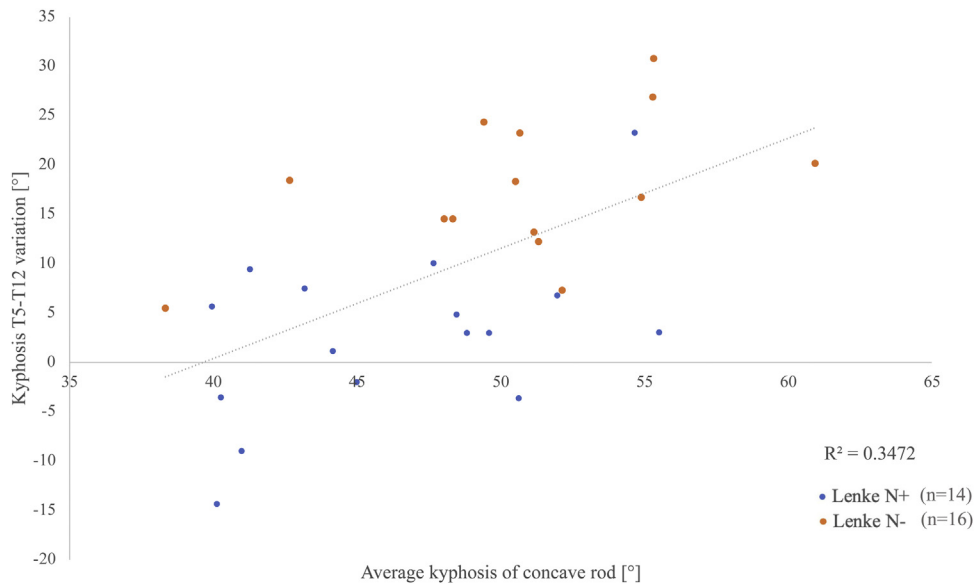


Fig. 3. Linear relationship between the variation in T5–T12 thoracic kyphosis and the kyphosis of the concave rod.

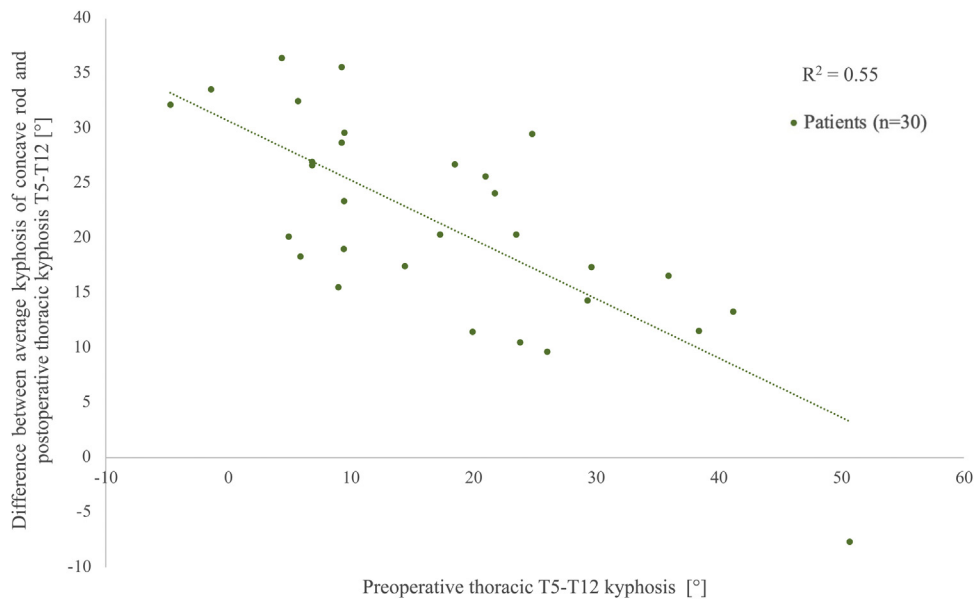


Fig. 4. Linear relationship between preoperative thoracic kyphosis and the difference between the mean kyphosis of the concave rod and the measured postoperative T5–T12 kyphosis.

this type of rod requires mastery of other – equally challenging – factors such as the functional position in the EOS “cabin”, which can alter the sagittal spinal parameters [14] and perfect planning of the limit vertebra because the length of the precurved rod cannot be changed intraoperatively.

4.2. Relationship between rod curvature and sagittal correction achieved

The objective of surgical treatment was achieved because the patients who had thoracic hypokyphosis had more normal kyphosis based on the classifications of Lenke et al. [13] and Abelin-Genevois et al. [1,15]. The results on Fig. 3 suggest that over-bending of the concave rod is needed, especially when a larger correction is desired. Previous studies [16,21] have found a loss of correction due to flattening of the rod because the vertebral column is stiff. Serhan et al. [22] showed that 5.5 mm CoCr rods underwent plastic

deformation after having been bent 30° on a synthetic spine model and recovered only 48% of their shape after release. Le Navéaux et al. [11] found about 20° loss in the concave rod’s bend (CoCr 5.5 mm), as did Cidambi et al. [12]. Using a 6 mm titanium rod led to about 16° loss of correction in the study by Salmingo et al. [21]. Using a two CoCr rod technique may be an alternative to minimize this loss of correction. Solla et al. [9] recommend 10° overcorrection in patients who had thoracic hypokyphosis.

In our study, the curvature given to the concave rod affects the postoperative T5–T12 kyphosis. Other factors [23] could be integrated into studies such as the density and type of implants [24], need for posterior laminectomy, flexibility of the curvature, location of the apex of the thoracic kyphosis.

In the Lenke N– subgroup, the lumbar lordosis increased significantly by about 10°. This increase happened because the surgeon considered the global sagittal balance and intuitively increased the lordosis curvature for patients with thoracic hypokyphosis. Nev-

ertheless, this increase in postoperative lumbar lordosis was not found in the Abelin-Genevois type 2a subgroup patients. Our explanation is that type 2a patients have less than 20° T5–T12 kyphosis while the Lenke N– subgroup included patients whose thoracic kyphosis was less than 10°. Here again, this technique is controlled by the surgeon's assessment and visual evaluation.

4.3. Limitations

One of the limitations of this study is that we did not directly evaluate the likely loss of bend in the concave rod. The kyphosis and lordosis measured on the rods correspond to the maximum kyphosis and lordosis imparted by the surgeon. The inflexion point might be different depending on the manual bending of the rod. Furthermore, we did not take into account the reducibility of the curvature.

5. Conclusion

This study found excellent reproducibility and repeatability of measuring the freehand rod bending applied during the surgical treatment of idiopathic scoliosis in adolescents. The maximum thoracic kyphosis applied to the concave rod is positively correlated with the change in the resulting kyphosis and made it possible to restore satisfactory thoracic kyphosis, especially in patients with hypokyphosis.

Disclosure of interest

R. Vialle received personal subsidies from NuVasive and Stryker unrelated to this study. The other authors declare that they have no competing interest.

Funding

None.

Authors' contributions

T. Langlais: writing.

A. Bouy: data analysis.

G. Eloy: data analysis and revisions.

N. Mainard: data analysis and revisions.

W. Skalli: revisions.

C. Vergari: revisions and statistics.

R. Vialle: revision and scientific guarantor.

Use of AI: no use of generative AI and AI-assisted technologies in the writing process.

References

- [1] Abelin-Genevois K. Sagittal balance of the spine. *Orthop Traumatol Surg Res* 2021;107:102769.
- [2] Pesenti S, Jouve JL, Morin C, Wolff S, Sales de Gauzy J, Chalopin A, et al. Evolution of adolescent idiopathic scoliosis: results of a multicenter study at 20 years' follow-up. *Orthop Traumatol Surg Res* 2015;101:619–22.
- [3] Clément JL, Solla F, Tran A, Morin C, Lakhal W, Sales de Gauzy J, et al. Five-year outcomes of the first distal uninstrumented vertebra after posterior fusion for adolescent idiopathic scoliosis Lenke 1 or 2. *Orthop Traumatol Surg Res* 2017;103:727–31.
- [4] Dubouset J, Chopin D, Seringe R. Have we made true progress in surgical indications and determining the limitations of spinal fusion in patients with idiopathic scoliosis? *Orthop Traumatol Surg Res* 2018;104:555–6.
- [5] Castelein RM, Pasha S, Cheng JC, Dubouset J. Idiopathic scoliosis as a rotatory decompensation of the spine. *J Bone Miner Res* 2020;35:1850–7.
- [6] Hirsch C, Ilharreborde B, Fournier J, Mazda K, Bonnard C. Adolescent idiopathic scoliosis correction achieved by posteromedial translation using polyester bands: a comparative study of subtransverse process versus sublaminar fixation. *Orthop Traumatol Surg Res* 2014;100:791–5.
- [7] Lamerain M, Bachy M, Dubory A, Kabbaj R, Scemama C, Vialle R. All-pedicle screw fixation with 6-mm-diameter cobalt-chromium rods provides optimized sagittal correction of adolescent idiopathic scoliosis. *Clin Spine Surg* 2017;30:E857–63.
- [8] Allia J, Clément JL, Rampal V, Leloutre B, Rosello O, Solla F. Influence of derotation connectors on 3D surgical correction of adolescent idiopathic scoliosis. *Clin Spine Surg* 2018;31:E209–15.
- [9] Solla F, Clément JL, Cunin V, Bertonecchi CM, Fièrè V, Rampal V. Patient-specific rods for thoracic kyphosis correction in adolescent idiopathic scoliosis surgery: preliminary results. *Orthop Traumatol Surg Res* 2020;106:159–65.
- [10] Sabah Y, Clément JL, Solla F, Rosello O, Rampal V. Cobalt-chrome and titanium alloy rods provide similar coronal and sagittal correction in adolescent idiopathic scoliosis. *Orthop Traumatol Surg Res* 2018;104:1073–7.
- [11] Le Navéaux F, Aubin CE, Parent S, Newton PO, Labelle H. 3D rod shape changes in adolescent idiopathic scoliosis instrumentation: how much does it impact correction? *Eur Spine J* 2017;26:1676–83.
- [12] Cidambi KR, Glaser DA, Baström TP, Nunn TN, Ono T, Newton PO. Postoperative changes in spinal rod contour in adolescent idiopathic scoliosis: an in vivo deformation study. *Spine (Phila Pa 1976)* 2012;37:1566–72.
- [13] Lenke LG, Betz RR, Harms J, Bridwell KH, Clements DH, Lowe TG, et al. Adolescent idiopathic scoliosis: a new classification to determine extent of spinal arthrodesis. *J Bone Joint Surg Am* 2001;83:1169–81.
- [14] Faro FD, Marks MC, Pawelek J, Newton PO. Evaluation of a functional position for lateral radiograph acquisition in adolescent idiopathic scoliosis. *Spine (Phila Pa 1976)* 2004;29:2284–9.
- [15] Post M, Verdun S, Roussouly P, Abelin-Genevois K. New sagittal classification of AIS: validation by 3D characterization. *Eur Spine J* 2019;28:551–8.
- [16] Vergari C, Gajny L, Courtois I, Ebermeyer E, Abelin-Genevois K, Kim Y, et al. Quasi-automatic early detection of progressive idiopathic scoliosis from biplanar radiography: a preliminary validation. *Eur Spine J* 2019;28:1970–6.
- [17] Skalli W, Vergari C, Ebermeyer E, Courtois I, Drevelle X, Kohler R, et al. Early detection of progressive adolescent idiopathic scoliosis: a severity index. *Spine (Phila Pa 1976)* 2017;42:823–30.
- [18] Vergari C, Skalli W, Abelin-Genevois K, Bernard JC, Hu Z, Cheng JCY, et al. Effect of curve location on the severity index for adolescent idiopathic scoliosis: a longitudinal cohort study. *Eur Radiol* 2021;31:8488–97.
- [19] Ilharreborde B, Pesenti S, Ferrero E, Accadbled F, Jouve JL, De Gauzy JS, et al. Correction of hypokyphosis in thoracic adolescent idiopathic scoliosis using sublaminar bands: a 3D multicenter study. *Eur Spine J* 2018;27:350–7.
- [20] Bland JM, Altman DG. Comparing methods of measurement: why plotting difference against standard method is misleading. *Lancet* 1995;346:1085–7.
- [21] Salmingo RA, Tadano S, Abe Y, Ito M. Influence of implant rod curvature on sagittal correction of scoliosis deformity. *Spine J* 2014;14:1432–9.
- [22] Serhan H, Mhatre D, Newton P, Giorgio P, Sturm P. Would CoCr rods provide better correctional forces than stainless steel or titanium for rigid scoliosis curves? *J Spinal Disord Tech* 2013;26:E70–4.
- [23] Lonner BS, Lazar-Antman MA, Sponseller PD, Shah SA, Newton PO, Betz R, et al. Multivariate analysis of factors associated with kyphosis maintenance in adolescent idiopathic scoliosis. *Spine (Phila Pa 1976)* 2012;37:1297–302.
- [24] Laumonerie P, Tibbo ME, Kerezoudis P, Langlais T, de Gauzy JS, Accadbled F. Influence of the sublaminar band density in the treatment of Lenke 1 adolescent idiopathic scoliosis. *Orthop Traumatol Surg Res* 2020;106:1269–74.