



### **Science Arts & Métiers (SAM)**

is an open access repository that collects the work of Arts et Métiers Institute of Technology researchers and makes it freely available over the web where possible.

This is an author-deposited version published in: <https://sam.ensam.eu>  
Handle ID: <http://hdl.handle.net/10985/24828>

#### **To cite this version :**

Priscilla GALINIÉ, Camille EYSSARTIER, Christophe SAURET, Mickael TORDJMAN, Marie-Line PISSONIER, Robert CARLIER, Wafa SKALLI, Claudio VERGARI - In-vivo characterization of the lumbar annulus fibrosus in adults with ultrasonography and shear wave elastography - Medical Engineering & Physics - Vol. 120, p.104044 - 2023

Any correspondence concerning this service should be sent to the repository

Administrator : [scienceouverte@ensam.eu](mailto:scienceouverte@ensam.eu)



Technical note

# In-vivo characterization of the lumbar annulus fibrosus in adults with ultrasonography and shear wave elastography

Priscilla Galinié<sup>a</sup>, Camille Eyssartier<sup>a,b</sup>, Christophe Sauret<sup>a,c</sup>, Mickael Tordjman<sup>d</sup>, Marie-line Pissonier<sup>d</sup>, Robert Carlier<sup>d</sup>, Wafa Skalli<sup>a</sup>, Claudio Vergari<sup>a,\*</sup>

<sup>a</sup> Arts et Métiers Sciences et Technologies, Institut de Biomécanique Humaine Georges Charpak, 151 bd de l'Hôpital, 75013, Paris, France

<sup>b</sup> Fédération Française de Gymnastique, Paris, France

<sup>c</sup> Centre d'Etudes et de Recherche sur l'Appareillage des Handicapés, Institution Nationale des Invalides, France

<sup>d</sup> Medical Imaging Department, Raymond Poincaré Hospital, 104 bd Raymond Poincaré, 92380, GARCHES, France

---

## ARTICLE INFO

### Keywords:

Spine  
Ultrasound waves  
Biomechanical phenomena  
Intervertebral disc degeneration  
Adult

## ABSTRACT

In vivo characterization of intervertebral disc (IVD) mechanical properties and microstructure could give an insight into the onset and progression of disc pathologies. Ultrasound shearwave elastography provided promising results in children, but feasibility in adult lumbar discs, which are deep in the abdomen, was never proved. The aim of this work was to determine the feasibility and reliability of ultrasound assessment of lumbar IVD in adults.

Thirty asymptomatic adults were included (22 to 67 years old). Subjects were lying supine, and the annulus fibrosus of the L3-L4 IVD was imaged by conventional ultrasonography and shearwave elastography. Shear wave speed (SWS) and lamellar thickness were measured. Reliability was determined through repeated measurements acquired by three operators.

Average SWS in AF at the L3L4 level was  $4.0 \pm 0.9$  m/s, with an inter-operator uncertainty of 8.7%, while lamellar thickness was  $255 \pm 27$   $\mu\text{m}$  with an uncertainty of 9.6%. Measurement was not feasible in one out of four subjects with BMI > 24 kg/m<sup>2</sup> (overweight).

Ultrasound assessment of annulus fibrosus revealed feasible, within certain limitations, and reproducible. This method gives an insight into disc microstructure and mechanical properties, and it could be applied for the early detection or follow-up of disc pathologies.

---

## 1. Introduction

Low back pain (LBP) is the leading cause of disability in the world [1]. While pain is the main symptom, and the cause is often difficult to diagnose, the intervertebral disc (IVD) and its degeneration often play a role. This is not surprising since the IVD is a key component of spine's biomechanics, and at the same time it is avascular and therefore it has low endogenous repair capability. The degeneration usually occurs progressively with aging, and is characterized by a dehydration of the tissue, which can become more fibrotic and tend to lose its micro-architecture [2,3]. This also results in a stiffening of the spinal functional unit, which is due to a combination of disc's height loss and changes in mechanical properties.

Magnetic resonance imaging (MRI) is the gold standard to assess the disc. It can provide information on disc morphology and hydration through standard imaging protocols, while more advanced methods are being developed to estimate mechanical properties through shear wave elastography [4,5]. However, MRI is difficult of access in clinical routine, and it might not be adapted for early detection of disc alteration or long-term follow-up of disc pathology.

Ultrasound shear wave elastography (SWE) has shown promising results for the non-invasive assessment of disc in vivo. It is based on the measurement of shear wave speed (SWS) in the annulus fibrosus (AF), which is directly related to the tissue's mechanical properties [6,7], and it can be coupled with conventional ultrasonography which can provide information on the AF microstructure [8–10]. SWE has been applied to

---

*List of abbreviations:* AF, annulus fibrosus; BMI, body mass index; IVD, Intervertebral disc; MRI, Magnetic resonance imaging; NP, Nucleus pulposus; SWE, Shear wave elastography; SWS, Shear wave speed.

\* Corresponding author at: Institut de Biomécanique Humaine Georges Charpak, Arts et Métiers ParisTech, 151 bd de l'Hôpital, 75013, Paris, France.

E-mail address: [c.vergari@gmail.com](mailto:c.vergari@gmail.com) (C. Vergari).

lumbar discs in children, demonstrating a stiffening of the AF in adolescent idiopathic scoliosis and recovery after arthrodesis [11].

In adults, ultrasound measurements were limited to the cervical discs [12], while lumbar discs were neglected because of the technical challenges posed by their depth within the abdominal cavity and the nature of the abdominal tissues that ultrasound must traverse. However, lumbar IVDs in adults present a specific clinical interest because they are often subject to degeneration with aging. The present work aimed to assess the feasibility and reliability of SWE and conventional ultrasonography on adult lumbar discs.

## 2. Material and methods

### 2.1. Participants

Thirty asymptomatic adults were included (14 women and 16 men, age range: 22 to 67 years old). Subjects had an average body mass index (BMI) of  $24 \pm 4 \text{ kg/m}^2$ , with values ranging between 17 (considered underweight) and  $31 \text{ kg/m}^2$  (considered obese). The exclusion criteria were the following: any musculoskeletal pathology, including back pain, previous spine surgery, or pregnancy at the time of measurement. All the participants signed an informed consent, as approved by the ethical committee CPP Ile de France VI (authorizations N. 2018-A01926-49 and N. 6001), and the study was conducted in accordance with the principles embodied in the Declaration of Helsinki and in accordance with local statutory requirements.

### 2.2. IVD imaging and protocol

A Supersonic Mach 30 (Supersonic Imagine, France) was used for the simultaneous conventional ultrasonography and SWE acquisitions. The device provides a direct measurement of SWS in the tissue, in the form of a colored chart (Fig. 2). SWS is related to the tissue shear modulus ( $\mu$ ) by the following relationship:  $SWS = \sqrt{\mu/\rho}$ , where  $\rho$  is tissue mass density ( $\sim 1000 \text{ kg/m}^3$ ) [7]. It was previously shown in vitro that SWS of the annulus is related to disc's mechanical properties [13].

Data were acquired by one operator in L3-L4 intervertebral disc, using the "general" acquisition mode. Subjects were in supine position, arms along their trunk (Fig. 1), and they were asked to maintain a steady breathing during the acquisition. The aortic bifurcation into iliac arteries was used as an anatomical landmark to locate the L4 level. The probe was tilted to be aligned with the IVD plane, and it was considered

aligned when lamellae were visible. At least 3 clips of approximately 10 s were acquired for each subject, for a total of approximately 30 frames containing the elastography and ultrasonography panels (Fig. 2). A L18-5 probe was first used in all patients and, if the signal was too attenuated (i.e., bad quality of the elastographic chart), a lower-frequency L10-2 probe was used. All SWS measurements were made in "penetration mode", while depth, brightness, size and location of the region of interest were adapted to the subject.

### 2.3. Shear wave elastography data processing

SWE data were analyzed using a previously described protocol and software [14]. In brief, the acquired clips were exported and transformed into single frames and custom software was used to calculate the average SWS in the AF in each frame. A region of interest was selected in the elastographic chart and it was semi-automatically tracked in the sequence of images, in order to ensure that the same region was tracked in all frames. The region of interest was manually placed in the AF, where the lamellae were visible. The average SWS was calculated by converting the colour red-green-blue values of each pixel in the region of interest to speed, using the colour chart available in each clip (Fig. 2). Then, an average was calculated for each movie ( $\sim 10$  images), and finally an overall average SWS per subject. Images or regions showing signal saturation (dark red or dark blue pixels) or with missing signal were excluded.

### 2.4. Ultrasonography data processing

Lamellar thickness was measured using a previously described technique [9]. Every image was processed with a histogram equalization filter to improve the contrast. Then, an operator traced three segments over the annulus in a radial direction, starting from the AF outer border to the AF inner border. Gray values along each segment were plot, and local maxima and minima were detected automatically. Midpoints between each consecutive local maximums and minimums were computed, and the lamellar thickness was calculated as the distance in pixels between two consecutive midpoints. Pixels were transformed in micrometers using the scale available on the side of each image Fig. 2).

### 2.5. Reliability and statistics

Two additional operators, one with a 7-year experience and the other

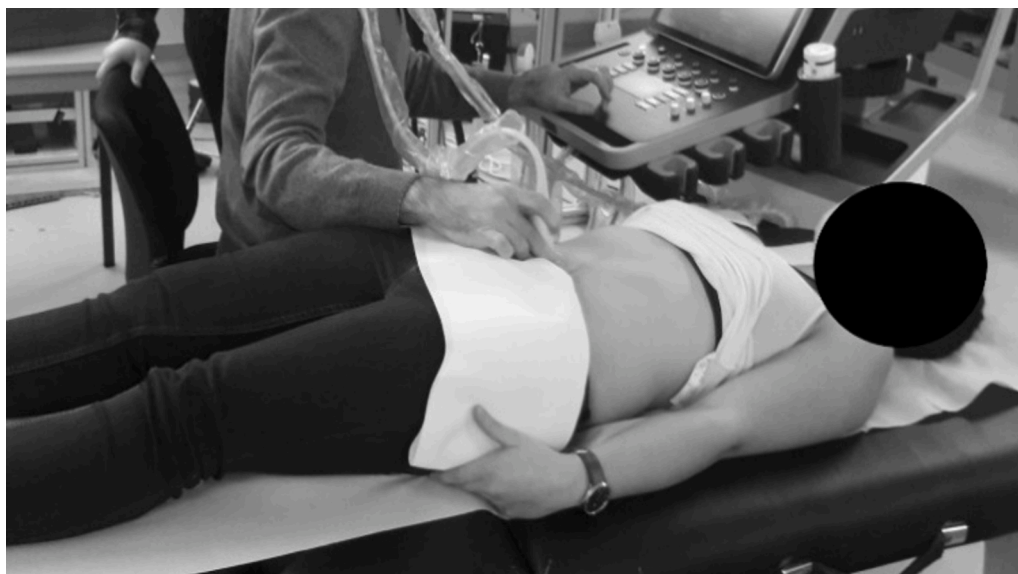

Fig. 1. - Setup for measurements in the lumbar intervertebral disc of a subject.

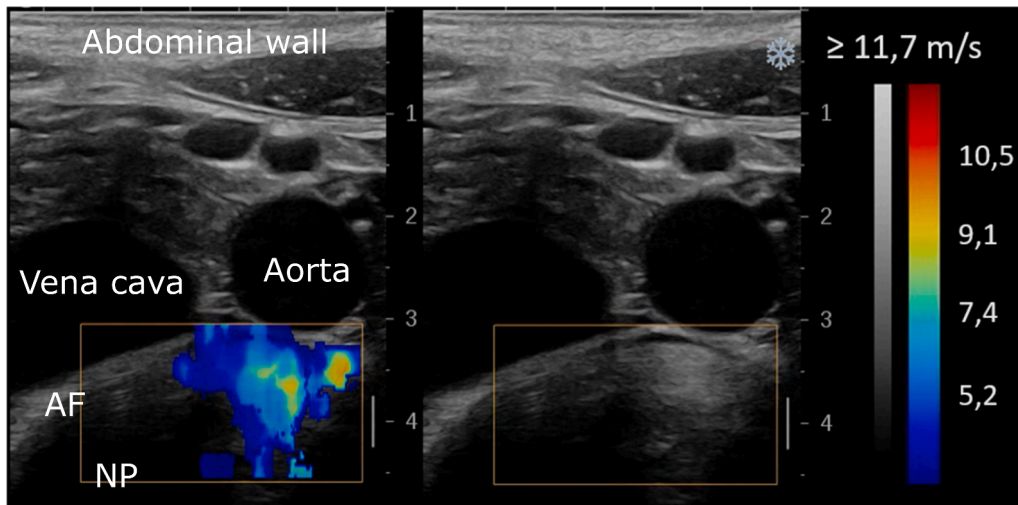


Fig. 2. – Example of data obtained with the shear wave elastography (left). The lamellae are visible in the region of interest in the annulus fibrosus (AF). The nucleus pulposus (NP) appears hypoechoic.

the same day training as the main operator, repeated the acquisitions on L3-L4 IVD of a subset of eight subjects to determine the reproducibility of SWS and lamellar thickness measurements. Uncertainty was evaluated in terms of coefficient of variation (standard deviation divided by average value), according to the 5725 ISO standard.

Data distributions of lamellar thickness and SWS were not normal according to Shapiro-Wilk normality test ( $p < 0.05$ ), and therefore, correlations between SWS, age and BMI were assessed using Spearman's test. Statistical significance was set at  $\alpha = 0.05$ . Results are reports as average  $\pm$  standard deviation. All processing was carried out in Matlab (The MathWorks Inc., Natick, MA, USA).

### 3. Results

#### 3.1. Shear wave elastography

One subject was excluded from further analysis because of a previously undiscovered scoliosis, while four subjects were excluded because their disc could not be imaged properly. Demographic data and the main results of the remaining 25 subjects was reported in Table 1. The subjects excluded due to imaging issues had a BMI between 24 and 30 kg/m<sup>2</sup>, with discs at depths between 3 and 6 cm. Average disc depth was  $3.7 \pm 1$  cm, with depths ranging from 2.5 to 6.1 cm. Disc depth was correlated with BMI ( $R = 0.7, p = 0.0007$ ).

Average SWS in AF at the L3-L4 level was  $4.0 \pm 0.9$  m/s. SWS was significantly correlated with BMI ( $R = 0.4, p = 0.04$ ) but not with age ( $p = 0.6$ ). However, as shown in Fig. 3, both correlations were significant when pooled with previously published data on children [11]. Gender did not have a significant effect on SWS ( $p = 0.7$ ). Inter-operator reproducibility of SWS was 8.7% and intra-operator repeatability was 5.6%.

Table 1  
Demographic data.

Sex	14 women and 16 men
Age (years)	$36 \pm 16.5$
Weight (m)	$68.8 \pm 13.2$
Height (kg)	$1.7 \pm 0.1$
Body mass index (kg/m <sup>2</sup> )	$23.2 \pm 3.4$
Disc depth (cm)	$3.7 \pm 0.9$
Annulus shear wave speed (m/s)	$4.0 \pm 0.9$
Lamellar thickness ( $\mu$ m)	$255.01 \pm 26.9$

#### 3.2. Ultrasonography

Eight subjects were excluded from this analysis because it was not possible to clearly image the lamellae. On the remaining twenty-two subjects, average lamellar thickness was  $255 \pm 27$   $\mu$ m, and it was correlated with SWS ( $R = 0.77, p < 0.0001$ ). Inter-operator reproducibility of lamellar thickness measurement was 24.7  $\mu$ m (9.6%) and intra-operator repeatability was 19.6  $\mu$ m (7.6%). Average pixel size of the ultrasound images was 71  $\mu$ m.

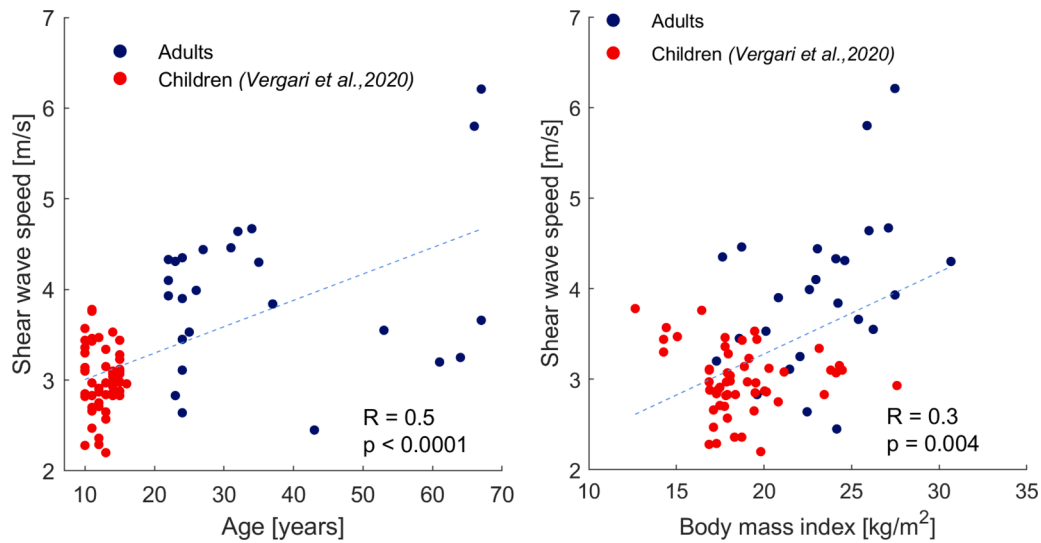
No significant effect of age or BMI were observed ( $p > 0.05$ ), but both correlations were significant when values were pooled with previous data on children (Fig. 4).

### 4. Discussion

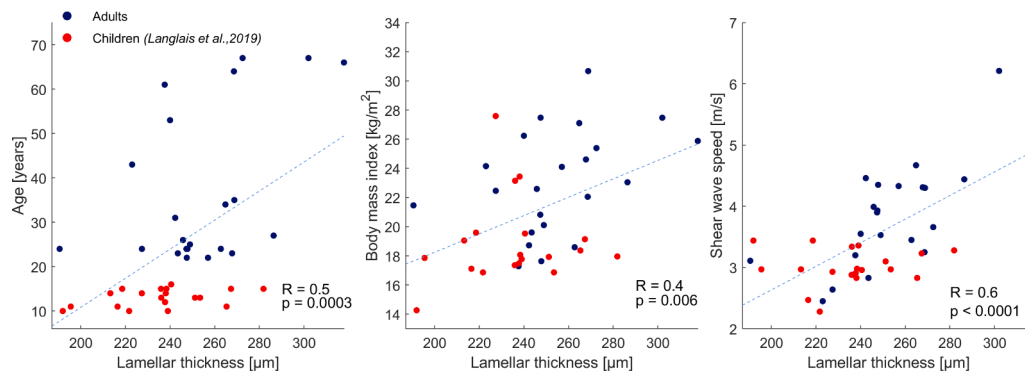
In this study, ultrasonography and SWE were applied for the first time to adult lumbar disc to assess the structural and mechanical properties of AF. Ultrasonography gave access to the lamellar thickness while SWE measured the SWS, which is related to tissue mechanical properties. While the theoretical relationship between SWS and mechanical properties is straightforward ( $SWS = \sqrt{\mu/\rho}$ ), it relies on several hypotheses which are not necessarily valid in the annulus fibrosus (homogeneity, infinite medium, etc.). For this reason, in this work only SWS was provided and not its corresponding shear modulus or, under the hypothesis of incompressibility, its Young's modulus  $E$  ( $E \approx 3\mu$ ) [7]. Therefore, SWS should be considered as a biomarker related to the intervertebral disc mechanical properties.

Reproducibility of SWE was 8.7%, with negligible operator effect, which is only slightly higher than uncertainties reported for applications in children (6.2%, [14]). SWE measurement was not possible in 4 subjects (13% of the cohort), which is not negligible. It is our opinion that the challenge in SWE of the disc in adults only partially depends on disc depth in the abdomen, but tissue characteristics and ultrasound absorption also play a role. These subjects had similar BMI and disc depths to the rest of the cohort. In other words, it appears that measurement is not feasible in one out of four subjects with BMI  $> 24$  kg/m<sup>2</sup>. Age does not seem to play a factor in feasibility, since these subjects' ages ranged between 27 and 66 years, nor does disc depth. It is possible that lower frequency probes (1-6 MHz) could allow SWE assessment of the annulus fibrosus, but resolutions obtained at this frequency might not be sufficient to characterize the lamellae.

Measurement of average lamellar thickness was not feasible in six subjects (20% of the cohort). Three of them coincided with the patients for which SWS measurement was not feasible, suggesting a limitation of



**Fig. 3.** - Correlation between shear wave speed at the L3-L4 level and subjects' age and body mass index. Data of asymptomatic children from (Vergari et al., 2020) were included.



**Fig. 4.** - Correlation between lamellar thickness at L3-L4 level and subjects' body mass index, age and disc shear wave speed.

ultrasound penetration. However, the remaining three subjects had low to normal BMI (between 17 and 26 kg/m<sup>2</sup>). While the lack of visibility of the lamellae could be still due an insufficient ultrasound penetration, it could also be due to a loss of architecture of the AF due to some stage of disc degeneration, and therefore a loss of lamellar organization. This would be consistent with the fact that the IVD tends to slowly and progressively degenerate with age starting during childhood (Wu and Huang, 2017), but this hypothesis should be confirmed with a study comparing ultrasound and MRI measurements in healthy and degenerated discs.

Previous works also found that average SWS for children and adolescents was 3.0 ± 0.3 m/s [15] whereas an average of 4.0 ± 0.8 m/s was found in the present study including adults from 22 to 67 years old. Fig. 3 confirms that this difference is due to the different age of the two cohorts. It also shows that aging affects SWS in the annulus fibrosus, corresponding to an increase of tissue stiffness with age. This is consistent with the known natural stiffening of the spine occurring with aging [2,16]. However, this aging effect observed with SWS could also include, or hide, a component of progressive but asymptomatic degeneration of the disc. For instance, previous studies proved that pathologic discs in adolescent idiopathic scoliosis are stiffer than healthy ones [15]. This hypothesis is also corroborated by the increase in variability that can be observed with age, suggesting that older discs are more affected by their history. However, this is still speculative at this stage, and it is impossible to state if some of the discs were pathological, and in particular the ones showing extreme SWS values observed, for instance higher than 5

m/s. Therefore, further studies should clarify the relevance of SWS as an early biomarker of disc degeneration by comparison with other imaging methods.

A previous study found an average lamellar thickness of 229.7 ± 91.5 µm for subjects aged from 10 to 16 years old [9], which is similar to the value obtained in this study (257.4 ± 27 µm). However, Fig. 4 suggests that ages do play a role in the lamellar organization of AF, as previously suggested by Marchand and Ahmed [17]. Lamellar thickness was also correlated with SWS (Fig. 4); this could be expected, as it confirms that AF microstructure plays a role in its macroscopic mechanical properties. It is possible that thicker lamellae correspond to more densely packed collagen fibers, and hence a stiffer tissue which would show higher SWS.

The main limitation of the proposed technique is that measurement was not possible in some subjects. This should be further investigated, to ascertain if only disc depth and the properties of the overlying tissue limit ultrasound penetration, or if the actual IVDs presented properties that impeded ultrasound penetration. In the latter case, these discs might be the ones which would benefit more from further clinical assessment, and the impossibility of acquiring SWE images could represent a biomarker itself.

Another limitation is the uncertainty concerning the measured spine level, since the aortic bifurcation corresponds to the L4 level in only 64% of the population. Spine radiographs can in some cases help in determining the location of the discs, for instance relative to the iliac crests.

## 5. Conclusions

This study showed that biomechanical and structural characterization of adult AF with shear wave elastography and ultrasonography is feasible and reliable. SWS and lamellar thickness in AF increased with age, which might be due to disc aging or slow progression of disc degeneration; this aspect requires further investigation.

SWE and ultrasonography are non-invasive and radiation-free methods, easy to access in clinical routine, and therefore they show great potential to obtain biomarkers of disc health.

## Funding

The authors are grateful to the BiomecAM chair program on subject-specific musculoskeletal modelling (with the support of ParisTech and Yves Cotrel Foundations, Société Générale, Covea and Proteor). The funding body had no involvement in study design, in the collection, analysis and interpretation of data; in the writing of the report; nor in the decision to submit the article for publication.

## Ethical approval

All the participants signed an informed consent, as approved by the ethical committee CPP Ile de France VI (authorizations N. 2018-A01926-49 and N. 6001), and the study was conducted in accordance with the principles embodied in the Declaration of Helsinki and in accordance with local statutory requirements.

## CRedit authorship contribution statement

**Priscilla Galinié:** Investigation, Data curation, Writing – original draft, Writing – review & editing. **Camille Eyssartier:** Investigation, Data curation, Writing – review & editing. **Christophe Sauret:** Resources, Writing – review & editing, Supervision, Project administration. **Mickael Tordjman:** Investigation, Resources, Writing – review & editing. **Marie-line Pissonier:** Validation, Resources, Writing – review & editing. **Robert Carlier:** Validation, Resources, Writing – review & editing. **Wafa Skalli:** Conceptualization, Writing – review & editing, Supervision, Funding acquisition. **Claudio Vergari:** Conceptualization, Software, Writing – original draft, Supervision, Project administration.

## Declaration of Competing Interest

No conflict of interest to disclose.

## References

- [1] Hartvigsen J, Hancock MJ, Kongsted A, Louw Q, Ferreira ML, Genevay S, Hoy D, Karppinen J, Pransky G, Sieper J, Smeets RJ, Underwood M, Buchbinder R, Hartvigsen J, Cherkin D, Foster NE, Maher CG, Underwood M, van Tulder M, Anema JR, Chou R, Cohen SP, Menezes Costa L, Croft P, Ferreira M, Ferreira PH, Fritz JM, Genevay S, Gross DP, Hancock MJ, Hoy D, Karppinen J, Koes BW, Kongsted A, Louw Q, Öberg B, Peul WC, Pransky G, Schoene M, Sieper J, Smeets RJ, Turner JA, Woolf A. What low back pain is and why we need to pay attention. *Lancet* 2018;391:2356–67. [https://doi.org/10.1016/S0140-6736\(18\)30480-X](https://doi.org/10.1016/S0140-6736(18)30480-X).
- [2] Galbusera F, Van Rijbergen M, Ito K, Huyghe JM, Brayda-Bruno M, Wilke HJ. Ageing and degenerative changes of the intervertebral disc and their impact on spinal flexibility. *Eur Spine J* 2014;23:324–32. <https://doi.org/10.1007/s00586-014-3203-4>.
- [3] Cao Y, Liao S, Zeng H, Ni S, Tintani F, Hao Y, Wang L, Wu T, Lu H, Duan C, Hu J. 3D characterization of morphological changes in the intervertebral disc and endplate during aging: a propagation phase contrast synchrotron microtomography study. *Scient Rep* 2017;7:43094. <https://doi.org/10.1038/srep43094>.
- [4] Co M, Dong H, Boulter DJ, Nguyen XV, Khan SN, Raterman B, Klamer B, Kolipaka A, Walter BA. Magnetic resonance elastography of intervertebral discs: spin-echo echo-planar imaging sequence validation. *J Magn Resonan Imaging* 2022;56:1722–32.
- [5] Cortes DH, Magland JF, Wright AC, Barocas VH, Elliott DM. Magnetic resonance elastography of intervertebral disc - a new biomarker for disc degeneration. In: Bioengineering Conference (NEBEC), 2012 38th Annual Northeast; 2012. p. 83–4. <https://doi.org/10.1109/nebc.2012.6206973>.
- [6] de Reuver S, Moens AJBWD, Kruyt MC, Nievelstein RAJ, Ito K, Castelein RM. Ultrasound shear wave elastography of the intervertebral disc and idiopathic scoliosis: a systematic review. *Ultrasound Med Biol* 2022;48:721–9. <https://doi.org/10.1016/j.ultrasmedbio.2022.01.014>.
- [7] Gennisson JL, Deffieux T, Fink M, Tanter M. Ultrasound elastography: principles and techniques. *Diagn Interv Imaging* 2013;94:487–95. <https://doi.org/10.1016/j.diii.2013.01.022>.
- [8] Kakitsubata Y, Theodorou SJ, Theodorou DJ, Nabeshima K, Kakitsubata S, Tamura S. Sonographic characterization of the lumbar intervertebral disk with anatomic correlation and histopathologic findings. *J Ultrasound Med Offic J Am Instit Ultrasound Med* 2005;24:489–99. <https://doi.org/10.7863/jum.2005.24.4.489>.
- [9] Langlais T, Desprairies P, Pietton R, Rohan PY, Dubouset J, Meakin JR, Winlove PC, Vialle R, Skalli W, Vergari C. Microstructural characterization of annulus fibrosus by ultrasonography: a feasibility study with an in vivo and in vitro approach. *Biomech Model Mechanobiol* 2019;18:1979–86. <https://doi.org/10.1007/s10237-019-01189-3>.
- [10] Marshburn TH, Hadfield CA, Sargsyan AE, Garcia K, Ebert D, Dulchavsky SA. New Heights in Ultrasound: first Report of Spinal Ultrasound from the International Space Station. *J Emerg Med* 2014;46:61–70. <https://doi.org/10.1016/j.jemermed.2013.08.001>.
- [11] Vergari C, Chanteux L, Pietton R, Langlais T, Vialle R, Skalli W. Shear wave elastography of lumbar annulus fibrosus in adolescent idiopathic scoliosis before and after surgical intervention. *Eur Radiol* 2020;30:1980–5. <https://doi.org/10.1007/s00330-019-06563-4>.
- [12] Vergari C, Rouch P, Dubois G, Bonneau D, Dubouset J, Tanter M, Gennisson JL, Skalli W. Non-invasive biomechanical characterization of intervertebral discs by shear wave ultrasound elastography: a feasibility study. *Eur Radiol* 2014;24:3210–6. <https://doi.org/10.1007/s00330-014-3382-8>.
- [13] Vergari C, Rouch P, Dubois G, Bonneau D, Dubouset J, Tanter M, Gennisson JL, Skalli W. Intervertebral disc characterization by shear wave elastography: an in vitro preliminary study. *Proc Inst Mech Eng Part H, J Eng Med* 2014;228:607–15. <https://doi.org/10.1177/0954411914540279>.
- [14] Vergari C, Dubois G, Vialle R, Gennisson JL, Tanter M, Dubouset J, Rouch P, Skalli W. Lumbar annulus fibrosus biomechanical characterization in healthy children by ultrasound shear wave elastography. *Eur Radiol* 2016;26:1213–7. <https://doi.org/10.1007/s00330-015-3911-0>.
- [15] Langlais T, Vergari C, Pietton R, Dubouset J, Skalli W, Vialle R. Shear-wave elastography can evaluate annulus fibrosus alteration in adolescent scoliosis. *Eur Radiol* 2018;28:2830–7. <https://doi.org/10.1007/s00330-018-5309-2>.
- [16] Wu Q, Huang JH. Intervertebral Disc Aging, Degeneration, and Associated Potential Molecular Mechanisms. *J Head Neck Spine Surg* 2017;1:555569. <https://doi.org/10.19080/JHNSS.2017.01.555569>.
- [17] Marchand F, Ahmed AM. Investigation of the lamina structure of lumbar disc annulus fibrosus. *Spine (Phila Pa 1976)* 1990;15:402–10.