Science Arts & Métiers (SAM)
is an open access repository that collects the work of Arts et Métiers Institute of Technology researchers and makes it freely available over the web where possible.

This is an author-deposited version published in: https://sam.ensam.eu
Handle ID: .http://hdl.handle.net/10985/15779

To cite this version :

Cheng ZHANG, Wafa SKALLI, Pierre-Yves LAGACÉ, Fabien BILLUART, Xavier OHL, Thierry CRESSON, Nathalie J. BUREAU, Dominique M. ROULEAU, André ROY, Patrice TÉTREAULT, Christophe SAURET, Jacques A. DE GUISE, Nicola HAGEMEISTER - Investigation of 3D glenohumeral displacements from 3D reconstruction using biplane X-ray images: Accuracy and reproducibility of the technique and preliminary analysis in rotator cuff tear patients - Journal of Electromyography and Kinesiology - Vol. 29, p.12-20 - 2016

Any correspondence concerning this service should be sent to the repository Administrator : scienceouverte@ensam.eu

Investigation of 3D glenohumeral displacements from 3D reconstruction using biplane X-ray images: Accuracy and reproducibility of the technique and preliminary analysis in rotator cuff tear patients

Cheng Zhang [a,b], Wafa Skalli [b], Pierre-Yves Lagacé [a,b], Fabien Billuart [b], Xavier Ohl [b,c], Thierry Cresson [a], Nathalie J. Bureau [d], Dominique M. Rouleau [e], André Roy [f,g], Patrice Tétreault [h], Christophe Sauret [b], Jacques A. de Guise [a], Nicola Hagemeister [a,*]

[a] *Laboratoire de recherche en imagerie et orthopédie, École de technologie supérieure, Centre de recherche du Centre hospitalier de l'Université de Montréal, QC, Canada*
[b] *Institut de Biomécanique Humaine Georges Charpak, Arts et Métiers ParisTech, Paris, France*
[c] *Département de chirurgie orthopédique et de traumatologie, Hôpital Maison-Blanche, Centre hospitalier universitaire de Reims, Reims, France*
[d] *Département de radiologie, Centre Hospitalier de l'Université de Montréal, Montréal, QC, Canada*
[e] *Service d'orthopédie, Hôpital du Sacré-Coeur de Montréal, Montréal, QC, Canada*
[f] *Service de physiatrie, Centre Hospitalier de l'Université de Montréal, Montréal, QC, Canada*
[g] *Clinique de médecine du sport du CHUM et de l'Université de Montréal, Montréal, QC, Canada*
[h] *Service d'orthopédie, Centre Hospitalier de l'Université de Montréal, Montréal, QC, Canada*

Keywords:
Glenohumeral displacement
Rotator cuff tears
3D scapula reconstruction
Biplane X-rays

A B S T R A C T

Rotator cuff (RC) tears may be associated with increased glenohumeral instability; however, this instabil-ity is difficult to quantify using currently available diagnostic tools. Recently, the three-dimensional (3D) reconstruction and registration method of the scapula and humeral head, based on sequences of low-dose biplane X-ray images, has been proposed for glenohumeral displacement assessment. This research aimed to evaluate the accuracy and reproducibility of this technique and to investigate its potential with a preliminary application comparing RC tear patients and asymptomatic volunteers. Accuracy was assessed using CT scan model registration on biplane X-ray images for five cadaveric shoulder specimens and showed differences ranging from 0.6 to 1.4 mm depending on the direction of interest. Intra- and interobserver reproducibility was assessed through two operators who repeated the reconstruction of five subjects three times, allowing defining 95% confidence interval ranging from ±1.8 to ±3.6 mm. Intraclass correlation coefficient varied between 0.84 and 0.98. Comparison between RC tear patients and asymptomatic volunteers showed differences of glenohumeral displacements, especially in the superoinferior direction when shoulder was abducted at 20° and 45°. This study thus assessed the accuracy of the low-dose 3D biplane X-ray reconstruction technique for glenohumeral displacement assess-ment and showed potential in biomechanical and clinical research.

1. Introduction

Rotator cuff (RC) tears may lead to declines in shoulder function and to abnormal glenohumeral displacement. Modified glenohumeral displacement has been observed in RC tear patients, notably superior humeral head displacement or migration (Bey et al., 2011; Keener et al., 2009; Lawrence et al., 2014; Ludewig and Cook, 2002; Poppen and Walker, 1976). However, accurate assessment of glenohumeral displacements remains difficult due to the lack of investigation tools that allow for direct tracking of glenohumeral motion in multiple functional positions.

Three-dimensional (3D) *in vivo* analysis of glenohumeral displacements in shoulder functional positions were presented in the literature using open magnetic resonance imaging (MRI) (Beaulieu et al., 1999; Graichen et al., 2000; Massimini et al., 2012; Sahara et al., 2007) or model-based fluoroscopy imaging systems (Bey et al., 2006; Boyer et al., 2008; Massimini et al., 2012; Nishinaka et al., 2008; Zhu et al., 2012). These methods first require a personalized 3D model reconstruction based on computed tomography (CT) scan (Bey et al., 2006; Nishinaka et al., 2008) or MRI (Boyer et al., 2008; Massimini et al., 2012; Zhu et al., 2012). Glenohumeral displacement analysis is then achieved

* Corresponding author at: École de technologie supérieure, 1100, Notre-Dame Ouest, Montréal H3C 1K3, QC, Canada. Tel.: +1 514 396 8678.
E-mail address: Nicola.hagemeister@etsmtl.ca (N. Hagemeister).

http://dx.doi.org/10.1016/j.jelekin.2015.08.002

by registering the model on each single plane fluoroscopy image (Nishinaka et al., 2008; Zhu et al., 2012) or on each pair of biplane images (Bey et al., 2006; Boyer et al., 2008; Massimini et al., 2012; Zhu et al., 2012). However, MRI reconstruction is time-consuming and the accuracy of 3D skeleton reconstruction is limited. Also, CT acquisition of the entire scapula risks increased radiation exposure.

Recently, a model-based 3D reconstruction technique using 2D calibrated low-dose biplane X-ray images has been proposed and validated for the spine (Pomero et al., 2004), thorax cage (Aubert et al., 2014), upper limb (Lebailly et al., 2012) and lower limb (Chaibi et al., 2012; Quijano et al., 2013) and has been adapted to the shoulder (Lagacé et al., 2012, 2010; Ohl et al., 2015). The scapula model is generated *a priori* from cadaveric bone structures, therefore, the reconstruction and registration are achieved without using additional imagery acquisitions. The geometric surface accuracy of the 3D reconstruction of the scapula with this approach has been previously validated *in vitro* with average errors within 1.0 mm compared with CT-derived model at the glenoid region and 1.3 mm for the entire scapula (Lagacé et al., 2012). The average errors of the orientation of the glenoid were less than 1.1° and errors in the estimation of the glenoid height were less than 1.0 mm (Lagacé et al., 2012, 2010). The 95% confidence interval (CI) (two times standard deviation) of the humeral head coordinates varied between 0.6 mm and 2.3 mm, depending on the shoulder abduction angles (Lagacé et al., 2010). The glenoid centered coordinate system was also proven accurate with angular variations generally under 2° (Ohl et al., 2015). However, the accuracy of the humeral head displacements according to the glenoid coordinate system has not yet been evaluated.

Thus, this study aimed to assess the accuracy and reproducibility of the low-dose model-based biplane X-ray reconstruction and registration technique for the assessment of 3D glenohumeral displacement. Then, its clinical interest was illustrated through a preliminary application comparing glenohumeral displacements in RC tear patients *versus* asymptomatic volunteers.

2. Materials and methods

2.1. Biplane X-ray acquisitions

Biplane X-ray acquisition protocol included six acquisitions for each subject using the low-dose EOS® system (EOS Imaging, Paris, France). Each acquisition produced simultaneously two calibrated X-ray images in the two orthogonal planes: posteroanterior and mediolateral planes. To avoid overlapping of the two shoulders, subjects were required to keep a standing position with an axial rotation of about 30°. More precisely, the rotation was counterclockwise from either the posteroanterior plane or the mediolateral plane, depending on the target shoulder (left or right), as illustrated in Fig. 1. Six active shoulder abduction positions in the scapular plane at approximately 10° (rest position), 20°, 30°, 45°, 60° and 90° were maintained sequentially for 10 s, which was the time required for a upper body scan. The abduction angles were confirmed using a clinical goniometer during acquisitions, relative to the vertical.

2.2. Glenohumeral displacement quantification

The reconstruction and registration technique for the quantification of the glenohumeral displacements has been previously described by Lagacé et al. (2010) using dedicated software developed in the laboratory. In summary, a morpho-realistic parametric model generated from 43 complete dry scapulae was used as *a priori* information of scapula morphology (Ohl et al., 2012). For each subject, a set of anatomical landmarks was defined as stereo-corresponding points (SCP) or non-stereo-corresponding points (NSCP). Projections of the former were visible on both views of the X-ray images, whereas the projections of the latter were only visible on one of the two views. For each scapula, the coracoid process, trigonum spinae scapulae and lateral border of the scapula were SCP, and the inferior and superior borders of the glenoid cavity, the inferior and superior angle can be both SCP and NSCP depending on the visibility of these landmarks, which may vary among different subjects and positions. To start the reconstruction, landmarks were selected on the first pair of images (shoulder in rest position). The 3D model was then projected on the two images and its shape was adjusted to fit the selected landmarks. Then fine manual adjustments were performed until there was superposition between the projected silhouette of the model and image features to obtain a 3D personalized model. The moving least squares algorithm was used for 3D surface deformation (Cresson et al., 2008; Cuno et al., 2007). For the remaining shoulder abduction positions, the same shoulder landmarks were manually identified on each pair of images for subsequent rigid registration. Also, a landmark can be NSCP in the first acquisition and became SCP, visible on both views of the images, in another acquisition; in that case, this additional information of the landmark from other acquisitions was added to improve the model.

The glenohumeral displacement data were calculated after rigid registration of the personalized model on each pair of images (Fig. 2). The glenohumeral displacements were computed as the motion of the humeral head center relative to the glenoid coordinate system. Thereby, the humerus was simplified as a sphere and a cylinder to express the humeral head displacement and shoulder abduction angle (Fig. 2). The shoulder abduction angle was computed as the angle between the centerline of the cylinder and the vertical line in the global coordinate system. The radius of the sphere was estimated from the humeral head articular surface.

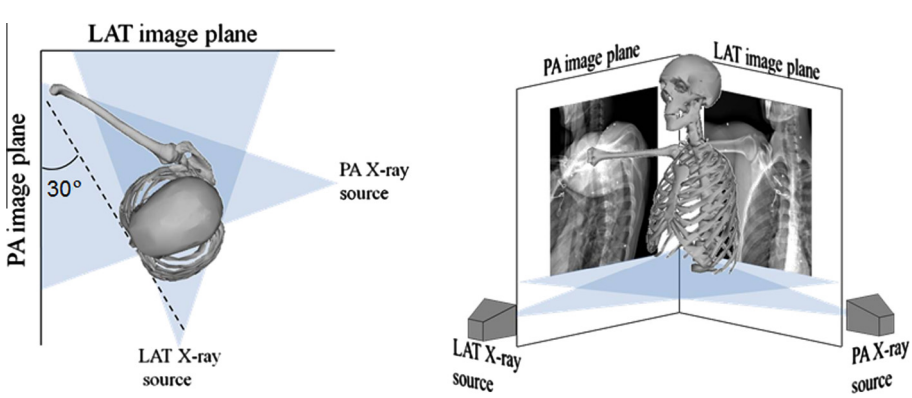

Fig. 1. Illustration of subject positioning during acquisition. Two X-ray sources and biplane detectors were positioned orthogonally. PA: posteroanterior; LAT: lateral.

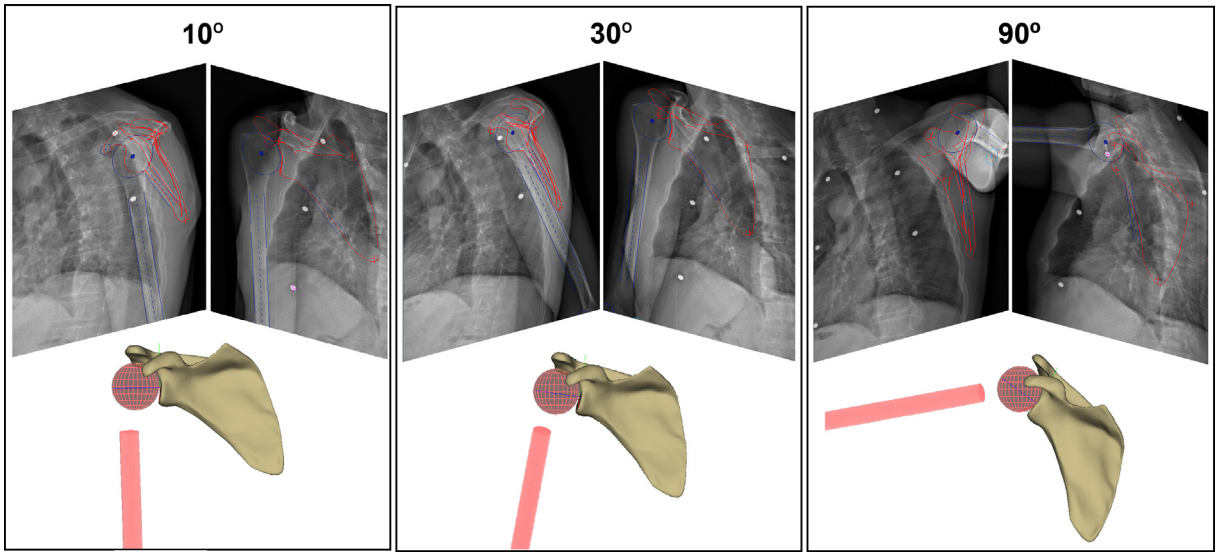

Fig. 2. Representation of 3D personalized scapula and simplified humerus models for three shoulder abduction: approximately 10° (rest position), 30° and 90°.

The origin of the glenoid coordinate system was defined as the geometric center of the ellipse that minimized the least squares distances from the nodes of the glenoid border mesh of the scapula. The *X*-axis was defined as the short axis of the ellipse, pointing forward. The *Y*-axis was defined as the long axis of the ellipse, pointing upward. And the *Z*-axis was defined as the normal vector to the estimated ellipse plane, pointing laterally (Ohl et al., 2015). Therefore, the successive position of the humeral head along the *X*-, *Y*- and *Z*-axes described the 3D glenohumeral displacements in anteroposterior, superoinferior and mediolateral directions, respectively.

To account for bone size differences, 3D glenohumeral displacements were expressed as a percentage of the width of the glenoid in the anteroposterior direction, the height of glenoid in the superoinferior direction and the radius of the humeral head in the mediolateral direction. The reconstruction and registration were operated by one experienced operator and the time required to analyze one subject was about 20 min.

2.3. Accuracy and reproducibility study

The accuracy of the 3D glenohumeral displacements was assessed using five cadaveric shoulder specimens (three shoulders from two females and two shoulders from one male; ages unknown). After the surrounding muscles were removed, the specimens were installed in the EOS booth while positioning the scapula plane (orientation and position) similarly to that described for *in vivo* subjects (Lagacé et al., 2010). Then, three biplane acquisitions were taken for three humerus abduction angles in the scapula plane (approximately 10°, 30° and 90°) while respecting a scapula rhythm of 2:1 (which means that 2/3 of the abduction was between the scapula and the thorax and 1/3 was between the humerus and the scapula). The three positions were chosen to cover the range of the six *in vivo* acquisition positions and the landmarks visibility for the intermediate positions did not vary a lot compare to the chosen positions.

Reference 3D geometry models of the cadavers were previously obtained from a CT scan (slice thickness = 0.5 mm) using SliceOMatic software (Tomovision, Montreal, Canada). The reconstructed 3D CT scapula and humeral head models were then semi-automatically registered to the biplane X-ray images with the help of tantalum and copper beads (X-medics Scandinavia, Frederiksberg, Denmark) embedded in the humerus and scapula bones before acquisition. The resulting computation of glenohumeral displacements was considered as the reference.

Intra- and interobserver reproducibility were assessed *in vivo* using acquisitions from five subjects (three men, two women, 42–65 years) by two observers, with three repetitions each (for a total of 15 reconstructions for each operator). Three shoulder abduction positions, identical to those chosen for *in vitro* accuracy validation, were used.

2.4. Preliminary study

To evaluate the potential interest of the proposed method for clinical investigations and biomechanical researches, a preliminary application was proposed and was focused on the comparison of glenohumeral displacements in RC tear patients and asymptomatic volunteers.

2.5. Subject and imaging acquisitions

Fifteen patients who presented shoulder symptoms (function decline or pain) for more than three months, full-thickness RC tears and severe fat infiltration, diagnosed on magnetic resonance images (MRI) were enrolled. The assessment of the magnitude of the RC tears took into account the supraspinatus, infraspinatus and subscapularis muscles, whereas the teres minor was excluded to simplify and reinforce the statistical analysis. Fat infiltration was examined using five stages of Goutallier's classification (Goutallier et al., 1994), and only patients who had at least one of the three RC muscles presenting *severe* fat infiltration (Goutallier scale III or IV) were included. Exclusion criteria included previous shoulder surgery. In addition, 28 asymptomatic volunteers in the similar age range without shoulder pain, function limitation, trauma or previous shoulder surgery were recruited. Six asymptomatic volunteers presented partial RC tears, but none of them presented full-thickness tears. Additionally, seven asymptomatic volunteers had intermediate fat infiltration and four presented both partial tears and intermediate fat infiltration. Acquisition protocols and clinical assessments were approved by local ethics committees (Research centers of University of Montreal and École de technologie supérieure, Montreal) and subjects gave written informed consent prior to their participation. Characteristics of the subjects are summarized in Table 1.

All participants underwent shoulder physical examinations for shoulder function evaluation, Constant-Murley Shoulder Outcome Score (Constant Score) (Constant and Murley, 1987) assessment, biplane X-ray and MRI acquisitions. The biplane X-ray acquisitions followed the protocol described above and included six shoulder abduction positions at approximately 10° (shoulder in rest position), 20°, 30°, 45°, 60° and 90°. A glenohumeral joint MRI was performed with a sequence of 1.5T-weighted Turbo-spin-echo (TE: 15 ms, TR: 1.7 s, field of view: 150 mm, flip angle: 90°, slice thickness: 4 mm, image resolution: 512 × 512 pixels) (Philips Medical System, Best, The Netherlands). Imaging diagnostic was determined by one expert radiologist. Both the fat infiltration and tear size measurements were made on the MR images. The tear size were calculated as the sum of the tear sizes of the supraspinatus, infraspinatus and subscapularis, and quantified using measuring tool available on the Picture Archiving and Communication System. For each muscle defect, the surface was calculated as the product of the transversal and longitudinal maximum lesion widths. The subjective pain was assessed by a visual analog scale from level 0 to 10, where 0 stands for *no pain* and 10 for *worst pain ever*.

2.6. Statistical analysis

Accuracy of the glenohumeral displacements was calculated as the difference between results from the evaluated technique and those from the reference. Intra- and interobserver reproducibility of 3D glenohumeral displacements were assessed by the standard deviation of the glenohumeral translation results obtained from the six reconstructions of each subject (two operators and three repetitions) that defined the 95% confidence interval (CI) (two times standard deviation). Intraclass correlation coefficient (ICC) (model II) were also calculated.

In the preliminary application, significant differences of the relative 3D glenohumeral displacements (anteroposterior, superoinferior and mediolateral directions in six shoulder abduction acquisitions) between RC tear patients and asymptomatic volunteers were tested for normal distribution and compared using *t*-test with independent samples. A $p < 0.05$ was considered significant. The statistical analysis was performed using the Statistics Toolbox of MATLAB version 2014b (MathWorks Inc.).

3. Results

3.1. Accuracy and reproducibility study

Table 2 presents the mean differences in glenohumeral displacements between the proposed technique and the reference. Mean differences were lower than 1.4 mm in the anteroposterior direction, lower than 0.9 mm in the superoinferior direction and lower than 0.6 mm in the mediolateral direction.

The 95% CI of the 3D glenohumeral location calculated following repeated analysis by two observers ranged between 1.8 mm and 3.6 mm, depending on the position and reference frame direction (Table 3). ICC values were higher than 0.84 for both anteroposterior and superoinferior directions. However, the ICC for mediolateral displacement was lower and even almost equal to zero at 90° of shoulder abduction.

Table 1
Subject characteristics.

ID of groups	Age (years)* (p = .013) (mean ± SD)	Male/female	BMI (kg/m^2)** (p = .001) (mean ± SD)	Total
RC tear patients	59.1 ± 4.7	8/7	30.0 ± 4.4	15
Asymptomatic volunteers	55.5 ± 7.5	15/13	23.1 ± 3.0	28

BMI, body mass index.
* $p < 0.05$.
** $p < 0.01$.

Table 2
Mean differences in glenohumeral displacements between the proposed technique and the reference.

Shoulder abduction angle (°)	Anteroposterior (mm)	Superoinferior (mm)	Mediolateral (mm)
10 (Rest position)	−1.4	0.1	0.6
30	−1.3	−0.5	0.5
90	−0.5	−0.9	0.3

3.2. Preliminary study

Through measurement based on 3D reconstruction, average glenohumeral abduction angles (mean ± standard deviation) that subjects maintained were actually 15 ± 5°, 24 ± 6°, 29 ± 6°, 40 ± 6°, 58 ± 7° and 84 ± 5°. The rest of the text will refer to these positions as they were indicated in the protocol: 10°, 20°, 30°, 45°, 60° and 90°. Table 4 shows shoulder outcomes comparing between RC tear patients and asymptomatic volunteers. Fig. 3a shows relative glenohumeral displacements according to the average glenoid surface and Fig. 3b shows the displacements as a function of shoulder abduction angles. In average, asymptomatic volunteers exhibited a slightly higher anterior position of the humeral head which was also more stable than in RC tear patients. Conversely, higher humeral head migration has been found in RC tear patients than in asymptomatic volunteers for shoulder abduction ranging from 20° to 60°. However, differences between groups were found significant only at 20° and 45° of shoulder abduction in the superoinferior direction.

The amplitudes of glenohumeral displacements without normalization were presented in Table 5. Average amplitudes were higher in RC tear patients in all three directions compare to asymptomatic volunteers. However, no significant difference was found.

4. Discussion

4.1. Part 1: accuracy and reproducibility study

Accuracy of the present method presented mean errors lower than 1 mm in the superoinferior and mediolateral directions but up to 1.4 mm in the anteroposterior direction. The reproducibility of the method in the anteroposterior and superoinferior directions was ±3.6 mm and ±2.5 mm (95% CI), respectively. Mediolateral displacement was less reproducible than anteroposterior and superoinferior displacements, but also the least relevant clinical parameters.

While compared to previous dual fluoroscopy registration techniques (errors less than 0.3–0.4 mm and 95% CI less than 0.5 mm) (Bey et al., 2006; Zhu et al., 2012), the present method reported

Table 3
In vivo reproducibility analysis.

Shoulder abduction angle (°)	Anteroposterior		Superoinferior		Mediolateral	
	95% CI (mm)	ICC	95% CI (mm)	ICC	95% CI (mm)	ICC
10 (Rest position)	±3.6	0.84	±2.3	0.86	±1.8	0.74
30	±2.9	0.87	±2.1	0.94	±1.9	0.66
90	±3.4	0.96	±2.5	0.98	±3.0	−0.06

ICC, model II type intraclass correlation coefficient.

Table 4
Comparison of shoulder outcomes between RC tear patients and asymptomatic volunteers.

Group	Goutallier score (0–5)	Tear size (mm^2) (mean ± SD)	Pain (0–10) (mean ± SD)	Constant score** (p = .001) (0–100) (mean ± SD)	Total
RC tear patients	3–4	1071 ± 659	6.6 ± 2.3	50.4 ± 18.1	15
Asymptomatic volunteers	0–2	–	0	93.8 ± 5.9	28

Goutallier Score was presented as the score of the most affected muscle among three muscles of interests.
** $p < 0.01$.

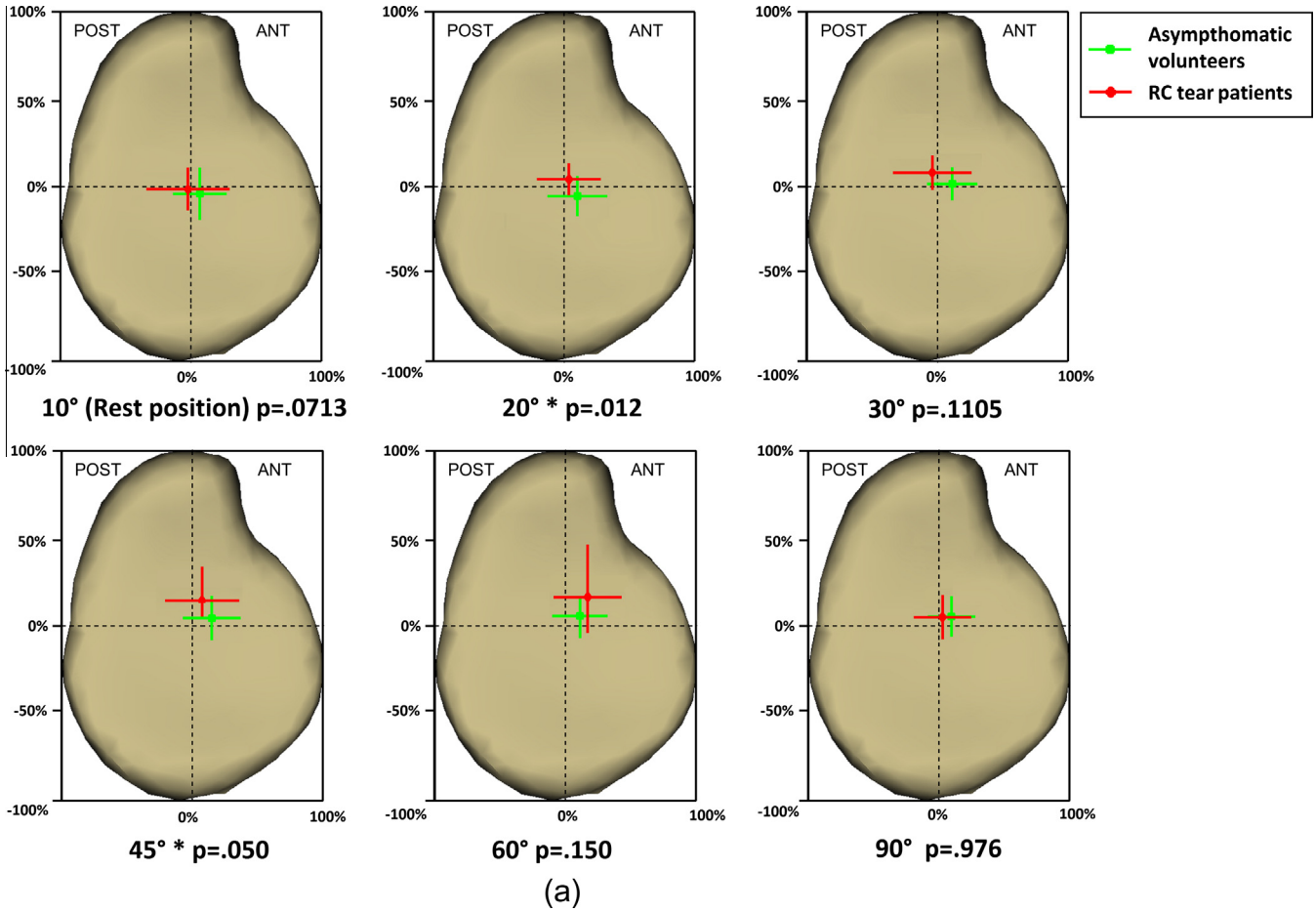

Fig. 3. Relative glenohumeral displacements in six shoulder abduction positions compared between RC tear patients and asymptomatic volunteers. Data were presented on average glenoid surface (a) and as a function of shoulder abduction angle (b). Dots represent the average position and the lines represent standard deviation. ANT: anterior; POST: posterior; SUP, superior; INF, inferior; LAT, lateral; MED, medial; GH: glenohumeral; A/P: anteroposterior; S/I, superoinferior; L/M: lateromedial. *$p < 0.05$; **$p < 0.01$.

lower accuracy and reproducibility. However, in term of the complexity of methods, the fluoroscopy based techniques require additional model segmentations from the CT scan (Bey et al., 2008, 2006; Nishinaka et al., 2008) or MRI (Boyer et al., 2008; Massimini et al., 2012; Zhu et al., 2012) that risk increased radiation or cost, whereas the present method was based on *a priori* geometry knowledge from a relatively large cadaveric database and did not require additional image acquisition for shape reconstruction. Besides, compared to conventional motion capture techniques based on skin markers (Ludewig and Cook, 2002), the accuracy of the present method was substantially improved, as the scalupa and humerus were tracked directly on X-ray images that avoided errors from skin motion relative to the bony structures. While researches using markers fitted to intracortical pins has improved accuracy, the invasive markers obstruct patient from doing natural shoulder motions and the method is difficult to apply in clinical routine (Dal Maso et al., 2015; Lawrence et al., 2014). Three-dimensional analysis were also more accurate than 2D standard X-ray measure (Chopp et al., 2010; Keener et al., 2009; Paletta et al., 1997; Poppen and Walker, 1976; Yamaguchi et al., 2000). Therefore, the present method appears as a good trade-off among method complexity, acquisition cost and accuracy.

However, accuracy and reproducibility tests performed in this study include some limitations. First, numbers of the cadaveric shoulder specimens and *in vivo* subjects were relatively small. Second, cadaveric validation for accuracy estimation was performed on dissected shoulders without the thorax cage and clavicle, which may overlap on the scapular body and the acromion. Therefore, the *in vivo* reconstruction of the scapula was more challenging due to the lower visibility of the scapula body. However, *in vivo* acquisition was performed with the patient rotated at approximately 30° to the X-ray sources and this avoided overlapping of the rib on the glenohumeral joint for most subjects. Therefore, detailed glenohumeral joint visibility in X-ray images of *in vivo* subjects ensured similar images as for *in vitro* validation for the glenohumeral joint.

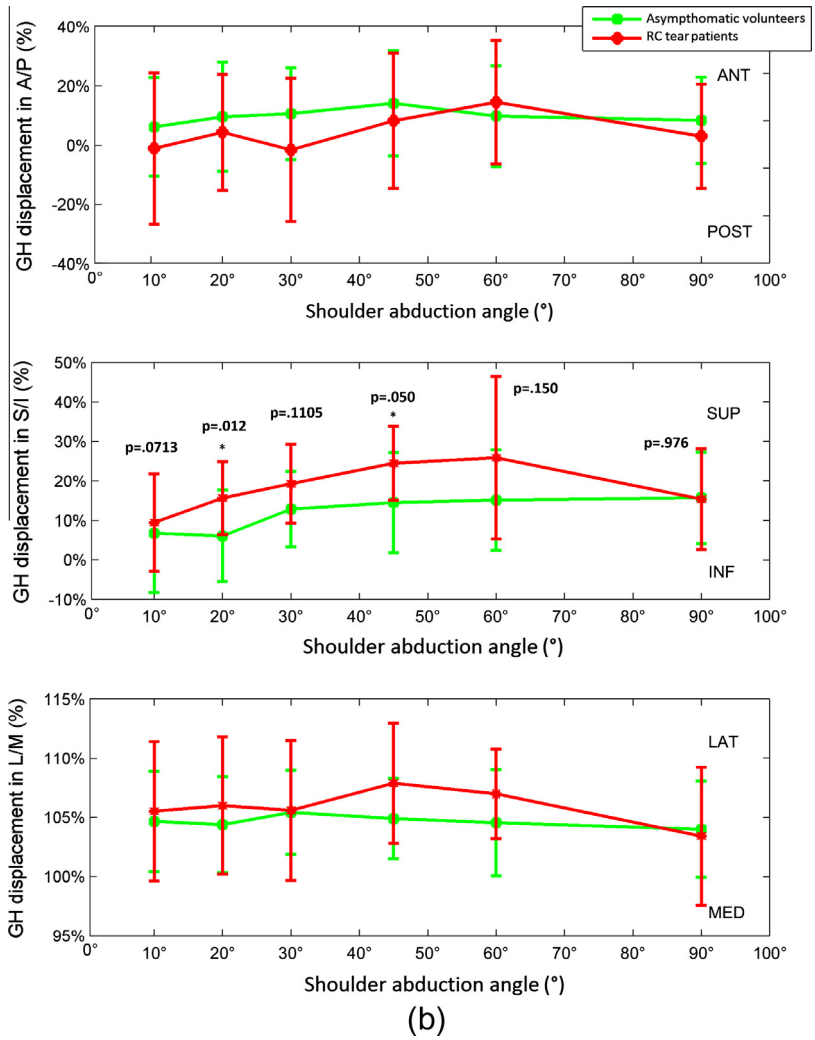

Fig. 3 (*continued*)

Table 5
Comparison of the average amplitudes of glenohumeral displacements in three directions between RC tear patients and asymptomatic volunteers. The results were presented as mean ± standard deviation, and with the minimum and maximum glenohumeral displacements among individuals between brackets.

	Anteroposterior (mm)	Superoinferior (mm)	Mediolateral (mm)
RC tear patient	4.8 ± 1.3 [2.5–6.4]	4.7 ± 2.7 [1.3–10.3]	2.2 ± 0.8 [1.3–3.8]
Asymptomatic volunteers	4.1 ± 1.6 [1.5–8.2]	3.4 ± 2.0 [1.1–8.4]	1.6 ± 0.8 [0.3–4.3]

4.2. Part 2: preliminary study

The preliminary application presented in the study showed a trend of anterior displacement of humeral head according to the glenoid in asymptomatic volunteers, which is consistent with the results of Graichen and colleges who demonstrated that for both passive and active shoulder abductions, the humeral head stayed anteriorly until 150° (Graichen et al., 2000). However, the present study showed that RC tear patients presented a trajectory of humeral head across both anterior and posterior sides of the glenoid. In the superoinferior direction, RC tear patients tended to exhibit higher superior migration of the humeral head compared to asymptomatic volunteers, which was significant at 20° and 45° of shoulder abduction. The result was in accordance with previous researches in patients with RC tears (Keener et al., 2009; Paletta et al., 1997; Poppen and Walker, 1976), patients that underwent RC repair surgery (Bey et al., 2011) and patient with impingement symptoms (Ludewig and Cook, 2002). The superoinferior displacement trajectory in previous researches was various. Some researches found almost continuous humeral head displacement with respect to the glenoid from inferior to the glenoid center (Nishinaka et al., 2008), superior part of the glenoid (Teyhen et al., 2010) during shoulder abduction until 120–135°, while Graichen and colleges found a humeral head decrease from 60° to 90° of shoulder abduction (Graichen et al., 2000). In the present study, a return to original superoinferior location was observed from 60° to 90° of abduction in the patients and from 45° to 90° in asymptomatic volunteers. This can be explained by the requirement of static poses that may underestimate the amount of superior glenohumeral migration compared to continuous movements (Teyhen et al., 2010). However, this difference should be under 1 mm (Graichen et al., 2000; Teyhen et al., 2010).

Considering individual variations throughout the evaluated range of motion, the average amplitudes were higher in RC tear

patients than in asymptomatic volunteers, in particular in the superoinferior direction. However, the amplitude observed in asymptomatic volonteers in the superoinferior direction (4.1 mm) was higher than that was previously reported in the literature where it was less than 2 mm (Bey et al., 2008; Graichen et al., 2005, 2000) or 2.5 mm (Massimini et al., 2011) in healthy subjects. However, the amplitude of anteroposterior displacements were lower than results in the literature for both groups (less than 4.8 mm *versus* 6 mm) (Massimini et al., 2011). Individual results in both groups showed large variations, which tended to be higher in the asymptomatic volunteers group than for the group of RC tear patients, excepted in the superoinferior direction. Indeed, in both groups, some subjects tended to have limited glenohumeral displacements whereas some others exhibited displacements higher than 10 mm. The lack of significant results for certain abduction positions may be due to the high variation among different individuals and the shoulder abduction angle errors during acquisition.

In this preliminary study, asymptomatic volunteers were chosen to be in the similar age range as RC tear patients. However, in spite of their pain absence, this cohort finally included nine subjects that presented either intermediate fat infiltration or partial RC tears, or both. This could explain the difficulty to obtain significant differences in our study. However, these subjects did not exhibited different humeral head behavior than other asymptomatic volunteers. As a results, removing these subjects from the asymptomatic group did not changed the results of the present study. This also demonstrated that the other asymptomatic volunteers, even without partial RC tears or fat infiltration, may under risks of RC tears because of the increased superoinferior glenohumeral displacements. However, in anteroposterior directions, asymptomatic volunteers mainly kept the humeral head in the anterior part of the scapula, which is different compare to RC tear patients. Thus, except for the well accepted measurements in superoinferior direction in clinical researches, humeral head trajectory in the anteroposterior direction seems also an interesting parameter to predict the shoulder RC pathology risks. Nevertheless, further researches, in particular longitudinal studies, are needed to demonstrate this assumption.

A limitation of the current acquisition protocol is that accurate control of shoulder abduction motions was difficult. Ongoing research aims at standardizing the position in a more reproducible manner. Moreover, each acquisition required the subject to hold the position for 10 s which may cause both muscular fatigue and passive motions. After all, the preliminary analysis can help to simplify the protocol by choosing fewer acquisitions with shoulder abduction angles ranging from 20° to 60°, which may present significant result and avoid muscle fatigue.

5. Conclusion

The biplane X-ray image reconstruction and registration technique provided low-dose acquisitions in multiple functional positions. *In vitro* accuracy and *in vivo* reproducibility evaluation demonstrated the potential of using such a method for biomechanical and clinical investigations. Preliminary application reported statistically significant differences of superior humeral head displacement between RC tear patients and asymptomatic volunteers. Besides, large variations of humeral head migration amplitudes were found in both asymptomatic volunteers and RC tear patients. Compared to the results in healthy subjects from the literature, the asymptomatic volunteers seemed to present different glenohumeral displacements, however further researches are required to fully understand the mechanics. Further research will also focus on adapting the 3D reconstruction and registration technique to clinical applications with improved reliability and simplified protocol.

Conflict of interest

The authors have no conflicts of interest to declare.

Acknowledgements

The project was supported by Institut de Recherche Robert-Sauvé en Santé et Sécurité du Travail du Québec, Fondation ParisTech Programme BIOMECAM Chaire ParisTech in France, Natural Science and Engineering Research Council of Canada, Fonds de Recherche sur la Nature et les Technologies du Québec, Fonds de Recherche en Santé du Québec, EOS Imaging, and French pôle de compétitivité MEDICEN (STEREOS + program).

References

Aubert B, Vergari C, Ilharreborde B, Courvoisier A, Skalli W. 3D reconstruction of rib cage geometry from biplanar radiographs using a statistical parametric model approach. Comput Methods Biomech Biomed Eng Imag Vis 2014:1–15. http://dx.doi.org/10.1080/21681163.2014.913990.

Beaulieu CF, Hodge DK, Bergman AG, Butts K, Daniel BL, Napper CL, et al. Glenohumeral relationships during physiologic shoulder motion and stress testing: initial experience with open MR imaging and active imaging-plane registration. Radiology 1999;212:699–705. http://dx.doi.org/10.1148/radiology.212.3.r99se31699.

Bey MJ, Kline SK, Zauel R, Lock TR, Kolowich PA. Measuring dynamic in-vivo glenohumeral joint kinematics: technique and preliminary results. J Biomech 2008;41:711–4. http://dx.doi.org/10.1016/j.jbiomech.2007.09.029.

Bey MJ, Peltz CD, Ciarelli K, Kline SK, Divine GW, van Holsbeeck M, et al. In vivo shoulder function after surgical repair of a torn rotator cuff: glenohumeral joint mechanics, shoulder strength, clinical outcomes, and their interaction. Am J Sports Med 2011;39:2117–29. http://dx.doi.org/10.1177/0363546511412164.

Bey MJ, Zauel R, Brock SK, Tashman S. Validation of a new model-based tracking technique for measuring three-dimensional, in vivo glenohumeral joint kinematics. J Biomech Eng 2006;128:604–9. http://dx.doi.org/10.1115/1.2206199.

Boyer PJ, Massimini DF, Gill TJ, Papannagari R, Stewart SL, Warner JP, et al. In vivo articular cartilage contact at the glenohumeral joint: preliminary report. J Orthop Sci 2008;13:359–65. http://dx.doi.org/10.1007/s00776-008-1237-3.

Chaibi Y, Cresson T, Aubert B, Hausselle J, Neyret P, Hauger O, et al. Fast 3D reconstruction of the lower limb using a parametric model and statistical inferences and clinical measurements calculation from biplanar X-rays. Comput Methods Biomech Biomed Eng 2012;15:457–66. http://dx.doi.org/10.1080/10255842.2010.540758.

Chopp JN, O'Neill JM, Hurley K, Dickerson CR. Superior humeral head migration occurs after a protocol designed to fatigue the rotator cuff: a radiographic analysis. J Shoulder Elbow Surg 2010;19:1137–44. http://dx.doi.org/10.1016/j.jse.2010.03.017.

Constant CR, Murley AH. A clinical method of functional assessment of the shoulder. Clin Orthop Relat Res 1987:160–4.

Cresson T, Godbout B, Branchaud D, Chav R, Gravel P, De Guise JA. 2008. Surface reconstruction from planar X-ray images using moving least squares. In: Conf. proc. annu. int. conf. IEEE eng. med. biol. soc. IEEE eng. med. biol. soc. annu. conf.; 2008, p. 3967–70. http://dx.doi.org/10.1109/IEMBS.2008.4650078.

Cuno A, Esperança C, Oliveira A, Cavalcanti PR. 3D as-rigid-as-possible deformations using MLS. In: Proceedings of the 27th computer graphics international conference; 2007. p. 115–22.

Dal Maso F, Raison M, Lundberg A, Arndt A, Allard P, Begon M. Glenohumeral translations during range-of-motion movements, activities of daily living, and sports activities in healthy participants. Clin Biomech (Bristol, Avon) 2015. http://dx.doi.org/10.1016/j.clinbiomech.2015.06.016.

Goutallier D, Postel JM, Bernageau J, Lavau L, Voisin MC. Fatty muscle degeneration in cuff ruptures. Pre- and postoperative evaluation by CT scan. Clin Orthop Relat Res 1994:78–83.

Graichen H, Hinterwimmer S, von Eisenhart-Rothe R, Vogl T, Englmeier K-H, Eckstein F. Effect of abducting and adducting muscle activity on glenohumeral translation, scapular kinematics and subacromial space width in vivo. J Biomech 2005;38:755–60. http://dx.doi.org/10.1016/j.jbiomech.2004.05.020.

Graichen H, Stammberger T, Bonel H, Englmeier Karl-Hans, Reiser M, Eckstein F. Glenohumeral translation during active and passive elevation of the shoulder – a 3D open-MRI study. J Biomech 2000;33:609–13.

Keener JD, Wei AS, Kim HM, Steger-May K, Yamaguchi K. Proximal humeral migration in shoulders with symptomatic and asymptomatic rotator cuff tears. J Bone Joint Surg Am 2009;91:1405–13. http://dx.doi.org/10.2106/JBJS.H.00854.

Lagacé P-Y, Billuart F, Ohl X, Skalli W, Tétreault P, de Guise J, et al. Analysis of humeral head displacements from sequences of biplanar X-rays: repeatability study and preliminary results in healthy subjects. Comput Methods Biomech Biomed Eng 2010;15:221–9. http://dx.doi.org/10.1080/10255842.2010.522185.

Lagacé P-Y, Cresson T, Hagemeister N, Billuart F, Ohl X, de Guise JA, et al. 3D reconstruction of the scapula from biplanar radiographs. In: Proc. SPIE 8314; 2012. p. 8314L. http://dx.doi.org/10.1117/12.911527.

Lawrence RL, Braman JP, Laprade RF, Ludewig PM. Comparison of 3-dimensional shoulder complex kinematics in individuals with and without shoulder pain, part 1: sternoclavicular, acromioclavicular, and scapulothoracic joints. J Orthop Sports Phys Ther 2014;44(636–45):A1–8. http://dx.doi.org/10.2519/jospt.2014.5339.

Lebailly F, Lima LVPC, Clairemidi A, Aubert B, Guerard S, Chaibi Y, de Guise J, Fontaine C, Skalli W. Semi-automated stereoradiographic upper limb 3D reconstructions using a combined parametric and statistical model: a preliminary study. Surg Radiol Anat 2012;34:757–65. http://dx.doi.org/10.1007/s00276-011-0884-9.

Ludewig PM, Cook TM. Translations of the humerus in persons with shoulder impingement symptoms. J Orthop Sports Phys Ther 2002;32:248–59. http://dx.doi.org/10.2519/jospt.2002.32.6.248.

Massimini DF, Boyer PJ, Papannagari R, Gill TJ, Warner JP, Li G. In-vivo glenohumeral translation and ligament elongation during abduction and abduction with internal and external rotation. J Orthop Surg Res 2012;7:29. http://dx.doi.org/10.1186/1749-799X-7-29.

Massimini DF, Warner JJP, Li G. Non-invasive determination of coupled motion of the scapula and humerus – an in-vitro validation. J Biomech 2011;44:408–12. http://dx.doi.org/10.1016/j.jbiomech.2010.10.003.

Nishinaka N, Tsutsui H, Mihara K, Suzuki K, Makiuchi D, Kon Y, et al. Determination of in vivo glenohumeral translation using fluoroscopy and shape-matching techniques. J Shoulder Elbow Surg 2008;17:319–22. http://dx.doi.org/10.1016/j.jse.2007.05.018.

Ohl X, Billuart F, Lagacé P-Y, Gagey O, Hagemeister N, Skalli W. 3D morphometric analysis of 43 scapulae. Surg Radiol Anat 2012;34:447–53. http://dx.doi.org/10.1007/s00276-012-0933-z.

Ohl X, Lagacé PY, Billuart F, Gagey O, Skalli W, Hagemeister N. Robustness and reproducibility of a glenoid-centered scapular coordinate system derived from low-dose stereoradiography analysis. J Appl Biomech 2015;31:56–61. http://dx.doi.org/10.1123/jab.2013-0310.

Paletta GA, Warner JJP, Warren RF, Deutsch A, Altchek DW. Shoulder kinematics with two-plane x-ray evaluation in patients with anterior instability or rotator cuff tearing. J Shoulder Elb Surg 1997;6:516–27. http://dx.doi.org/10.1016/S1058-2746(97)90084-7.

Pomero V, Mitton D, Laporte S, de Guise JA, Skalli W. Fast accurate stereoradiographic 3D-reconstruction of the spine using a combined geometric and statistic model. Clin Biomech (Bristol, Avon) 2004;19:240–7. http://dx.doi.org/10.1016/j.clinbiomech.2003.11.014.

Poppen NK, Walker PS. Normal and abnormal motion of the shoulder. J Bone Joint Surg Am 1976;58:195–201.

Quijano S, Serrurier A, Aubert B, Laporte S, Thoreux P, Skalli W. Medical engineering & physics three-dimensional reconstruction of the lower limb from biplanar calibrated radiographs. Med Eng Phys 2013;35:1703–12.

Sahara W, Sugamoto K, Murai M, Tanaka H, Yoshikawa H. The three-dimensional motions of glenohumeral joint under semi-loaded condition during arm abduction using vertically open MRI. Clin Biomech (Bristol, Avon) 2007;22:304–12. http://dx.doi.org/10.1016/j.clinbiomech.2006.04.012.

Teyhen DS, Christ TR, Ballas ER, Hoppes CW, Walters JD, Christie DS, et al. Digital fluoroscopic video assessment of glenohumeral migration: static vs. dynamic conditions. J Biomech 2010;43:1380–5. http://dx.doi.org/10.1016/j.jbiomech.2010.01.026.

Yamaguchi K, Sher JS, Andersen WK, Garretson R, Uribe JW, Hechtman K, et al. Glenohumeral motion in patients with rotator cuff tears: a comparison of asymptomatic and symptomatic shoulders. J Shoulder Elbow Surg 2000;9:6–11.

Zhu Z, Massimini DF, Wang G, Warner JJP, Li G. The accuracy and repeatability of an automatic 2D–3D fluoroscopic image-model registration technique for determining shoulder joint kinematics. Med Eng Phys 2012;34:1303–9. http://dx.doi.org/10.1016/j.medengphy.2011.12.021.

Cheng Zhang received her master degree in biomedical engineering in 2013, France. She is currently a joint Ph.D. student at École de technologie supérieure, Canada and Arts et Métiers ParisTech, France. Her research interests include 3D modeling of the glenohumeral joint based on biplane X-ray images and rotator cuff tears.



Prof. Wafa Skalli is a Mechanical Engineer (1980) and a PhD in Biomechanics (1983) from Arts et Métiers ParisTech. She is founder and scientific director of the Institut de Biomécanique Humaine Georges Charpak, and holder of the BiomecAM ParisTech chair on subject specific musculoskeletal modeling. She is particularly involved in biomechanics and modeling for clinical innovation, with a strong link to experimental and clinical approach. She is co-inventor of the innovative EOS low dose biplanar XRay system.

Pierre-Yves Lagacé received his Engineering degree from McGill University, Canada in 2006. He obtained an international joint Ph.D. in Biomedical Engineering from the École de technologie supérieure, Canada and Arts et Métiers ParisTech, France in 2013. He is currently a lecturer of engineering at the University College of the Cayman Islands. His research interests include joint imaging, modelling and motion analysis.

Dr. Fabien Billuart got his Ph.D in 2008. He is member of the laboratoire d'exploration fonctionnelles et d'analyse du mouvement and his research interests are about muscular function and movement analysis. He also teaches at the Institut de Formation en Kinésithérapie at Saint-Michel Paris.

Dr. Xavier Ohl received his MD from the University of Reims, France in 2008. He finished his Ph.D. in 2014 in the Institut de Biomécanique Humaine Georges Charpak of Paris (Arts et Métiers ParisTech). He is an orthopaedic surgeon with a particular interest in shoulder and elbow surgery and scapulothoracic biomechanics.

Thierry Cresson received the Ph.D. degree in signal processing and communications from the University of Rennes 1, Rennes, France, in 2005. He is currently a research associate at the Laboratoire de recherche en Imagerie et Orthopédie (LIO), Montreal, QC, Canada. His current research interests include medical image processing, registration algorithms, 3D medical imaging, and 3D modeling.



Dr. Nathalie J. Bureau MD M.Sc FRCPC is a musculoskeletal radiologist at the Centre hospitalier de l'Université de Montréal and a Professor of Radiology at the Université de Montréal. She earned an M.D. degree at the University of Montreal before completing her residency at the same institution. She then pursued a fellowship in musculoskeletal radiology and intervention at the University of Virginia in 1993–94. In 2014, she completed a Master's degree in Biomedical Sciences at the University of Montreal. Dr Bureau is a Researcher at the Centre de Recherche du Centre Hospitalier de l'Université de Montréal. Her research focuses on an imaging-based strategy for knee biomechanics evaluation and for tendon biomechanical properties quantification to assist treatment and monitoring of articular and tendon disorders.

Dr. Dominique M. Rouleau is an orthopedic surgeon at the Hôpital du Sacré-Coeur de Montréal. She received her medical degree in 2006 at Université de Montréal with best student mention of the Edouard Samson program. She did a fellowship in trauma at the Hôpital du Sacré-Coeur de Montréal in 2006–2007. In 2007–2008, she did another fellowship in shoulder surgery at University of Western Ontario. Since 2008, she is the secretary-treasurer for the orthopaedic program of Université de Montréal (FREOM). In 2009, became assistant professor in the surgery program of Université de Montréal. She is currently a member of the orthopaedic team at Hôpital du Sacré-Coeur de Montréal as well as associated researcher at the Research Center of Hôpital du Sacré-Coeur in upper limb trauma. Her research interests include upper limb surgery and trauma, as well as trauma epidemiology.

Dr. André Roy MD, FRCPC, Msc, Bsc, is a physiatrist working at the Centre hospitalier de l'Université de Montréal (CHUM), at the sports Medicine Clinic of Montreal University and at the Clinique de Physiatrie et de Médecine du Sport de Montréal. He is an adjunct professor at the Montreal University faculty of Medicine. He earned an M.D. degree at the University of Montreal before completing his physiatry residency at the same institution in 1998. He then pursued a fellowship in Sports Medicine and interventional pain medicine at McGill University in 1998–1999. Previously, he completed a Bsc and Msc in Kinesiology at Laval University. He is the Chief of staff of the Physiatry service of the CHUM, the medical director and founder of the Sports Medicine Clinic of Montreal University. His interest his sports medicine, biomechanics, and interventional pain medicine.

Dr. Patrice Tétreault received his degree in medicine from McGill University, Canada in 1995. He then completed his training in orthopedic surgery at the University of Montreal, from 1995 to 2000. He also did a fellowship in shoulder surgery in Zurich, Switzerland and Boston, USA in 2000–01. His special interests are in shoulder biomechanics.

Christophe Sauret received his Ph.D in Biomechanics in 2010 at Clermont Université (France). He is assistant professor at Arts et Métiers ParisTech (France) since 2012 and performed his research at the Institut de Biomécanique Humaine Georges Charpak. His research focuses on musculoskeletal modeling applied to sports and disabilities.

Prof. Jacques A. de Guise is Full Professor at the Department of Automated Production Engineering of École de technologie supérieure (ETS). After completing his studies in Electrical Engineering at École Polytechnique Montreal in 1977, he did his graduate studies at the Biomedical Engineering Institute of École Polytechnique and the University of Montreal, where he obtained his PhD in 1984. He is also Associate Professor at the Department of Surgery, Faculty of Medicine, University of Montreal and an active member of the Centre Hospitalier de l'Université de Montéral Research Center (CRCHUM). He is the Director of the Imaging and Orthopaedics Research Laboratory (LIO) of ÉTS and CRCHUM. He holds the Canada Research Chair in 3D Imaging and Biomedical Engineering and the Marie-Lou and Yves Cotrel Research Chair in Orthopaedics at the Department of Surgery, Faculty of Medicine, University of Montreal. He his Fellow of the Canadian Academy of Engineering since 2011.

Prof. Nicola Hagemeister graduated her PhD in biomedical engineering at École Polytechnique de Montréal in 2001. She is full professor at École de technologie supérieure since 2009 and member of the laboratoire de recherche en imagerie et orthopédie (LIO – Centre de recherche du CHUM). Her research interests are about functional analysis of joints (knee and shoulder).