



Science Arts & Métiers (SAM)

is an open access repository that collects the work of Arts et Métiers Institute of Technology researchers and makes it freely available over the web where possible.

This is an author-deposited version published in: <https://sam.ensam.eu>
Handle ID: <http://hdl.handle.net/10985/18119>

To cite this version :

Jean-Yves LAZENNEC, Youngwoo KIM, Aidin Eslam POUR - Total Hip Arthroplasty in Patients With Parkinson Disease: Improved Outcomes With Dual Mobility Implants and Cementless Fixation - Journal of Arthroplasty - Vol. 33, n°5, p.1455-1461 - 2017

Any correspondence concerning this service should be sent to the repository

Administrator : scienceouverte@ensam.eu





Science Arts & Métiers (SAM)

is an open access repository that collects the work of Arts et Métiers ParisTech researchers and makes it freely available over the web where possible.

This is an author-deposited version published in: <https://sam.ensam.eu>
Handle ID: <http://hdl.handle.net/null>

To cite this version :

Jean-Yves LAZENNEC, Youngwoo KIM, Aidin Eslam POUR - Total Hip Arthroplasty in Patients With Parkinson Disease: Improved Outcomes With Dual Mobility Implants and Cementless Fixation - The Journal of Arthroplasty - Vol. 33, n°5, p.1455-1461. - 2017

Any correspondence concerning this service should be sent to the repository

Administrator : archiveouverte@ensam.eu



Primary Arthroplasty

Total Hip Arthroplasty in Patients With Parkinson Disease: Improved Outcomes With Dual Mobility Implants and Cementless Fixation

Jean Y. Lazennec, MD, PhD ^{a, b}, Youngwoo Kim, MD, PhD ^{a, c, d}, Aidin Eslam Pour, MD ^{e, *}

^a Department of Orthopaedic and Trauma Surgery, Pitié-Salpêtrière Hospital, Assistance Publique—Hôpitaux de Paris, France

^b Anatomy Department Faculté Pitié Salpêtrière UPMC, Paris, France

^c Institut de Biomécanique Humaine Georges Charpak, Arts et Métiers Paris Tech, Paris, France

^d Department of Orthopaedic Surgery, Graduate School of Medicine, Kyoto University, Kyoto, Japan

^e Department of Orthopaedic Surgery, University of Michigan, Ann Arbor, Michigan

ARTICLE INFO

Article history:

Received 26 October 2017

Received in revised form

25 November 2017

Accepted 27 November 2017

Available online 5 December 2017

Keywords:

primary total hip arthroplasty

revision total hip arthroplasty

Parkinson disease

dual mobility bearing

postoperative rehabilitation

long term functional outcome

ABSTRACT

Background: Parkinson disease (PD) results in severe limitation in ambulation caused by abnormality of gait and posture. The rate of complications, including fractures and dislocation after total hip arthroplasty (THA), can be higher among these patients. The goal of this study was to investigate the long-term outcomes of primary and revision THAs with cementless dual mobility implants.

Methods: This retrospective study examines 59 PD patients who had surgery between 2002 and 2012. All the primary cases were performed for osteoarthritis and all patients received cementless acetabular implants with dual mobility bearing surface. The femoral stem was cemented in 4 patients who underwent revision surgery. The mean follow-up time was 8.3 years (4–14 years).

Results: Good to excellent pain relief was achieved in 53 of 57 patients at the 2-year follow-up and in 40 of 47 patients at their latest follow-up. The most common medical complication was cognitive impairment (12 of 57 patients). One patient sustained an intraprosthetic hip dislocation 9 years after surgery, which required revision. Four patients sustained periprosthetic femoral fractures with well-fixed stem, requiring open reduction and internal fixation. The disability had increased in 68% of the patients in the latest follow-up visit.

Discussion: Our study shows that elective primary or revision THA using cementless implants with dual mobility bearing surface in patients with PD provides satisfactory long-term outcomes, although many of these patients may see a general worsening of their activities over time due to PD.

© 2017 Elsevier Inc. All rights reserved.

Parkinson disease (PD) is a geriatric problem, which causes severe limitation in the patients' ambulation, including abnormality of gait and posture, and limited exercise capability. It affects approximately 1% of the US population over 60 years old [1]. Many of these patients experience hip pain due to degenerative joint disease that results in even more limitation of their mobility and may require a total hip arthroplasty (THA). Postoperatively, these patients may have higher rates of dislocation or

periprosthetic fractures due to PD-associated falls [2–4]. As a result, orthopedic surgeons may hesitate to offer THA as a treatment to these patients. Because of advances in arthroplasty technology and the medical management of the PD, increasing numbers of PD patients undergo THA.

Researchers have investigated outcomes of knee [5–10], shoulder [11–15], and hip arthroplasties for hip fractures [16–18] in this group of patients and reported high rates of complications and dissatisfaction. Few studies are published about long-term outcomes of THAs in PD patients [2–4,6].

The aim of this study was to report the long-term outcome of THA using cementless dual mobility implants for primary and revision surgeries in this group of patients.

Materials and Methods

This was a retrospective longitudinal study of patients who were diagnosed with PD and underwent THA in our hospital. Patients

underwent surgery in the Department of Orthopaedic and Trauma Surgery, Pitié-Salpêtrière Hospital, between 2002 and 2012. We obtained approval from our institutional review board for this study.

Our study population included 59 patients (34 men and 25 women). The average age at the time of surgery was 72.5 years (range 55–79 years). The surgeries included 42 primary THAs for osteoarthritis and 21 revision hip arthroplasties. The indication for revision surgery included recurrent hip dislocation (11 hips), severe acetabular polyethylene wear (6 hips), and femoral implant loosening (4 hips). All surgeries were performed using an anterolateral approach. In all primary surgeries, patients received a cementless acetabular implant with dual mobility bearing surface (Concept DM, Ceramconcept, Newark, DE). The highly cross-linked polyethylene was not used in any of these patients. For primary THA cases, patients received hydroxyapatite-coated, double-tapered titanium stem (Monoblock Global stem [38 cases], Modular global stem [4 cases], Ceramconcept, Newark, DE). A dual mobility bearing surface was used in all revision cases. In 7 cases with recurrent hip dislocation (7 of 11 hips), only the acetabular implant was changed, whereas in the other 4 cases (4 of 11 hips), both the acetabular and femoral implants were revised. In those hips that underwent revision of the femoral implant (4 hips), the loose implant was removed and the new femoral stem was cemented in place (Optimum stem, Ceramconcept, Newark, DE). All patients were followed up closely by neurology team and physical therapists perioperatively. All patients had normal physical therapy, which included balance therapy. Patients were followed up for a mean of 8.3 years (range 4–14 years). Two patients were lost to follow-up before their 2-year follow-up. Ten patients had passed away at the end of the study because of unrelated medical reasons. This left 57 patients at 2-year follow-up and 47 patients at the latest follow-up.

The preoperative and postoperative PD-related disability was defined based on the Hoehn and Yahr classification system [19]. This system was defined in 1967 and is presented in Table 1.

Statistical Analysis

This was a retrospective case series study. We used Kaplan-Meier methods to report the survival of the patients free of revision and reoperation. The preoperative and postoperative disability status (based on Hoehn and Yahr classification) was compared using chi-square tests [19]. The statistical analysis was performed with Stata 14.1 (StataCorp LP, College Station, TX).

Results

Good to excellent pain relief was achieved in 53 of 57 patients at the 2-year follow-up and in 40 of 47 patients at their latest follow-up. At the most recent follow-up, there was no clinical or radiographic periprosthetic loosening of the cementless acetabular or

Table 1
Hoehn and Yahr Classification System for Disability.

Stage	
1	Unilateral involvement only, usually with minimal or no functional impairment.
2	Bilateral or midline involvement, without impairment of balance.
3	First sign of impaired righting reflexes. The patient is unsteady on turning or when pushed from a standing position with the feet together and eyes closed. Function is somewhat restricted, but some work may be possible. Patients can lead independent lives with mild-to-moderate disability.
4	Fully developed, severely disabling disease. The patient is able to walk and stand unassisted, but is markedly incapacitated.
5	Confinement to bed or wheelchair, unless aided.

femoral implants or significant polyethylene wear. Figure 1 shows a patient who underwent primary THA and Figure 2 shows a patient who underwent revision hip arthroplasty. Postoperative medical complications included pneumonia (3 patients), urinary tract infections (7 patients), cognitive impairment (12 patients), and sacral pressure ulcers (2 patients). Postoperative surgical complications included wound infection with *Escherichia coli* in 2 patients who subsequently underwent irrigation and debridement with intravenous antibiotics (7 years and 9 years after index surgery). One patient sustained intraprostatic hip dislocation 9 years after surgery, requiring revision surgery to exchange the dual mobility head (Fig. 3). This patient had developed pelvic retroversion, which resulted in posterior impingement, superoanterior polyethylene wear, and as a result intraprostatic dislocation. This patient underwent revision of the modular stem to a new stem with less anteversion. The acetabular implant was well fixed and was not revised. Four patients sustained periprosthetic femoral fractures between 2 and 5 years from index surgery. None of the femoral stems were loose. The fractures in 2 patients were Vancouver type A_C fracture and were treated with cables only. The fractures in the other 2 cases were Vancouver type B1 fracture and were treated with plates, screws, and cables. In survival analysis using Kaplan-Meier method with revision, reoperation and dislocation as end points, survival was 91.5% at the 2-year follow-up and 79.7% at the 5-year follow-up (Fig. 4).

According to the Hoehn and Yahr classification [19], the preoperative disability was classified to be stage 1 in 19 patients (of 59, 32.2%), stage 2 in 24 patients (of 59, 40.7%), and stage 3 in 16 patients (of 59, 27.1%). The postoperative disability was classified to be stage 1 in 7 patients (of 47, 14.9%), stage 2 in 13 patients (of 47, 27.7%), stage 3 in 18 patients (of 47, 38.3%), and stage 4 in 9 patients (of 47, 19.1%) ($P < .001$). In 16 patients (of 47, 34%), the disability classification had not changed. Twenty-four patients had worsening in disability by 1 stage (of 47, 51.1%) and 7 patients had worsening of their disability by 2 stages (of 47, 14.9%).

Discussion

Our results indicate that elective primary or revision THA using dual mobility cementless cup and cementless femoral stem in patients with PD showed satisfactory outcomes in midterm to long-term results. This study is one of the first reports on the clinical and radiographic assessment of elective primary or revision THA with dual mobility cementless cup and cementless femoral stem in patients with PD. The few studies that have been published on this topic deal with primary and revision THAs in PD patients performed for femoral neck fractures or for failed implants after femoral neck fracture [1,2] and were not included in our work. In our study, all patients experienced improvement in their pain in the early follow-up and maintained the improvement of their pain at the latest follow-up, even though, as expected, the disease progression of PD occurred in the long-term. Our results indicate that successful primary and revision THA improves the pain and the quality of life of patients with PD, even in those with significant disability and ultimate PD-associated death.

THA in patients with PD is a challenging surgery because of associated comorbidity and complications. Previous studies reported the high general and local complication rates in these patients (2, 4). Our results indicate that 11 patients with primary THA (29.7%) and 8 patients with revision THA (40.0%) had general complications, consistent with previously published works. Queally et al [20] reported that aggressive medical management of patients with PD in the early post-operative period helped to avoid complications. Their results suggest that rehabilitation should be

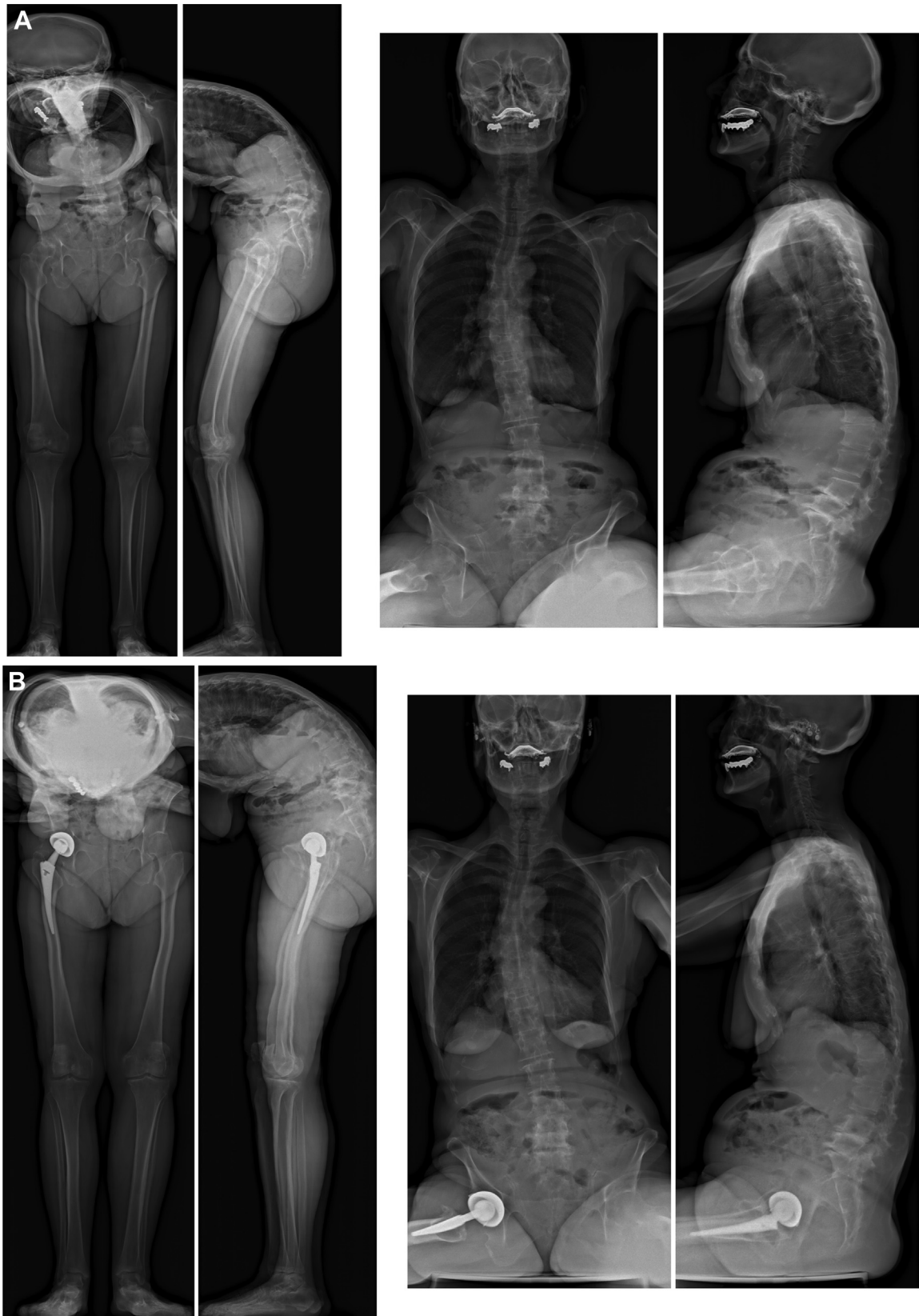

Fig. 1. Preoperative (A) and postoperative (B) EOS imaging (standing and sitting) in a patient with Parkinson disease and spinal deformity who underwent primary total hip arthroplasty without complication.

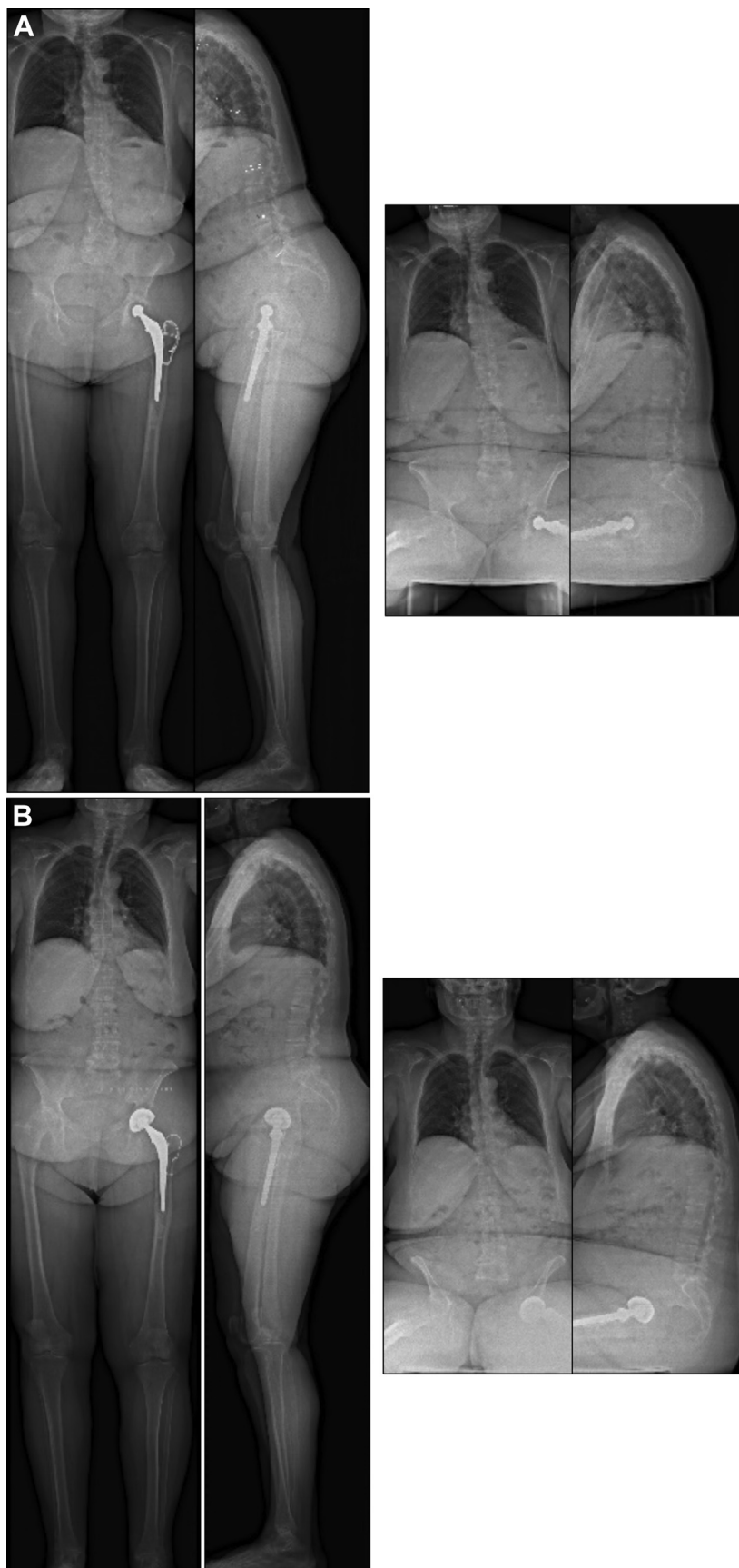


Fig. 2. Preoperative (A) and postoperative (B) EOS imaging (standing and sitting) in a patient with Parkinson disease who underwent revision total hip arthroplasty without complication.

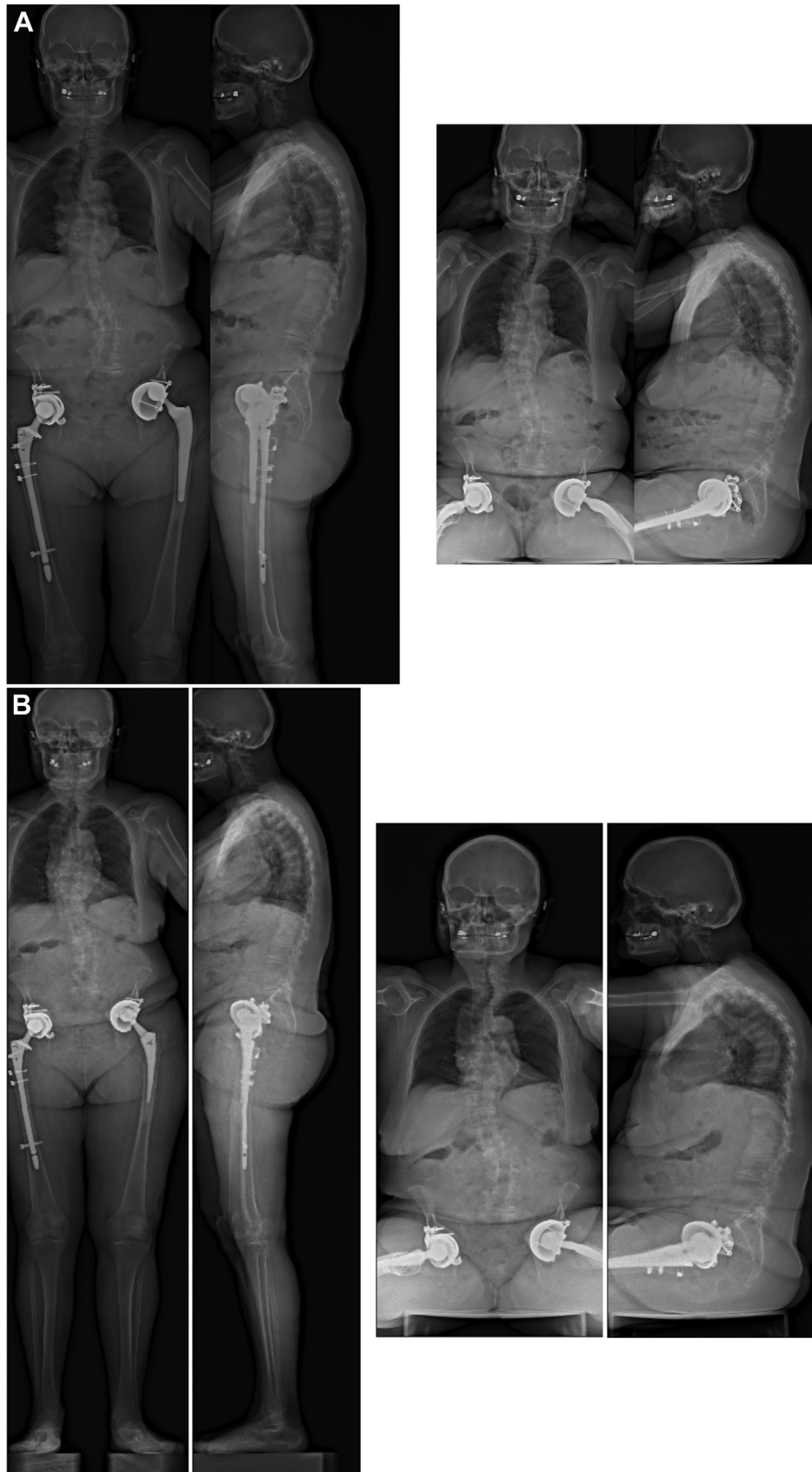


Fig. 3. Preoperative (A) and postoperative (B) EOS imaging (standing and sitting) of a patient who sustained intraprosthetic dislocation of the femoral head after surgery. This patient developed pelvic retroversion after total hip arthroplasty, which resulted in posterior impingement and superoanterior polyethylene wear. This patient underwent revision surgery for a new dual mobility bearing surface and a femoral stem with less anteversion.

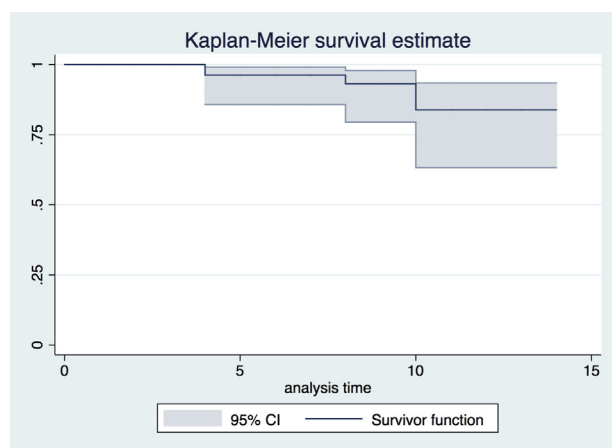


Fig. 4. Kaplan-Meier survival analysis with dislocation, revision, and reoperation for any reason other than infection as end point. CI, confidence interval.

started early to minimize complication and achieve the maximum degree of physical activity.

According to the literature, the rate of dislocation after THA in patients with PD is 0%–37% [2,21–23]. The neurological conditions such as neuromuscular weakness can predispose patients to gait disturbance, fall, functional disturbance, and dislocation after THA [24]. PD patients are a high-risk group for dislocation after primary and revision THAs because of increased muscle tone and rigidity [23]. Using comprehensive nationwide Finnish health registry data, Jansen et al [6] reported recently that the rate of early hip dislocation after primary THA increased significantly (hazard ratio 2.33). Strategies for managing dislocation after THA in high-risk patients include the constrained liner, the large femoral head, large-diameter metal-on-metal total hip prosthesis, and dual mobility [3,21,25–31]. Therefore, since 2003, we have been using the dual mobility implant in all patients with PD. In the present study of 57 PD patients, after elective primary and revision THAs, there were no dislocations at mean 8.3 years follow-up. Mohammed et al [26] reported that there were no dislocations after primary and revision THAs using dual mobility implants in the patients with central nervous system problems. Our findings in agreement with the published results from these studies indicate that THA in the patients with PD using dual mobility implants is one form of treatment for achieving satisfactory outcomes. Our study shows that cementless cups and femoral stems can be used with a very low rate of mechanical complication. We did find one asymptomatic patient with intraprostatic dislocation who needs further revision. This complication has been reported by others [32,33]. The reason for this is not known. This patient had dislocation because of developing pelvic retroversion over time. As a result, patient sustained intraprostatic dislocation because of posterior impingement. We advise that the surgeon should be aware of the possibility of intraprostatic dislocation after dual mobility implant. Also, it is critical to assess the changes in pelvic version in standing and sitting positions and adjust the implant orientation accordingly.

Previous reports of the outcome of THA in PD patients indicate that acetabular and femoral component fixation in THA can be achieved using cemented devices [2,4,6]. A recent meta-analysis concluded that PD patients were at higher risk of osteoporosis than healthy control subjects (OR 2.61) [34]. In elderly patients with osteoporosis, cemented prostheses provide initial stability and immediate weight-bearing ambulation. A recent report indicated that short-term result of THA using cementless dual mobility implant in patients with PD reduced dislocation without increased

risk of loosening [26]. In our study, none of the patients had an intraoperative periprosthetic fracture and any subsequent instability or further revision because of loosening. However, there were 2 (5.4%) and 2 (10.0%) periprosthetic fracture after primary and revision THA, respectively. These patients were injured because of fall. Mathew et al [4] reported that the 2 patients (13.3%) of 15 PD patients had a periprosthetic fracture after THA. In PD patients, fragility fractures caused by poor bone quality and falls because of the disturbed postural reflex [35]. The treatment of periprosthetic femoral fracture after femoral revision is more complex and challenging [36]. These results suggested that elective primary or revision THA using dual mobility cementless cup and cementless femoral stem in patients with PD were satisfactory midterm to long-term results. Because of the nature of their medical condition, PD patients after THA should be managed with neurologist and continue the rehabilitation to prevent postoperative periprosthetic femoral fracture.

There were several limitations to this study. First, this study was retrospective without a patient control group for comparison. Second, our patient population is rather small, but it is more than some of the previously published studies. Third, our study did not include any patients who underwent THA due to femoral neck fracture. This, in addition to the fact that this group of patients is low demand with limited activity may explain rather good results on a mean follow-up in our study.

References

- [1] Tysnes OB, Storstein A. Epidemiology of Parkinson's disease. *J Neural Transm (Vienna)* 2017;124:901–5.
- [2] Weber M, Cabanela ME, Sim FH, Frassica FJ, Harmsen WS. Total hip replacement in patients with Parkinson's disease. *Int Orthop* 2002;26:66–8.
- [3] Harwin SF, Mistry JB, Chughtai M, Khlopas A, Gwam C, Newman JM, et al. Dual mobility acetabular cups in primary total hip arthroplasty in patients at high risk for dislocation. *Surg Technol Int* 2017;30:251–8.
- [4] Mathew PG, Sponer P, Kucera T, Grinac M, Knizek J. Total HIP arthroplasty in patients with Parkinson's disease. *Acta Med (Hradec Kralove)* 2013;56:110–6.
- [5] Fast A, Mendelsohn E, Sosner J. Total knee arthroplasty in Parkinson's disease. *Arch Phys Med Rehabil* 1994;75:1269–70.
- [6] Jansen E, Puolakka T, Peltola M, Eskelinen A, Lehto MU. Surgical outcomes of primary hip and knee replacements in patients with Parkinson's disease: a nationwide registry-based case-controlled study. *Bone Joint J* 2014;96-B:486–91.
- [7] Macaulay W, Geller JA, Brown AR, Cote LJ, Kiernan HA. Total knee arthroplasty and Parkinson disease: enhancing outcomes and avoiding complications. *J Am Acad Orthop Surg* 2010;18:687–94.
- [8] Mehta S, Vankleunen JP, Booth RE, Lotke PA, Lonner JH. Total knee arthroplasty in patients with Parkinson's disease: impact of early postoperative neurologic intervention. *Am J Orthop (Belle Mead NJ)* 2008;37:513–6.
- [9] Shah SN, Hornyak J, Urquhart AG. Flexion contracture after total knee arthroplasty in a patient with Parkinson's disease: successful treatment with botulinum toxin type A. *J Arthroplasty* 2005;20:1078–80.
- [10] Tinning CG, Cochrane LA, Singer BR. Primary total knee arthroplasty in patients with Parkinson's disease: analysis of outcomes. *Acta Orthop Belg* 2013;79:301–6.
- [11] Burrus MT, Werner BC, Cancienne JM, Gwathmey FW, Brockmeier SF. Shoulder arthroplasty in patients with Parkinson's disease is associated with increased complications. *J Shoulder Elbow Surg* 2015;24:1881–7.
- [12] Cusick MC, Otto RJ, Clark RE, Frankle MA. Outcome of reverse shoulder arthroplasty for patients with Parkinson's disease: a matched cohort study. *Orthopedics* 2017;40:e675–80.
- [13] Dunn J, Byrne AN, Higgins LD. Reverse total shoulder arthroplasty in patients with Parkinson disease: a case series and review of the literature. *Am J Orthop (Belle Mead NJ)* 2011;40:625–9.
- [14] Koch LD, Cofield RH, Ahlskog JE. Total shoulder arthroplasty in patients with Parkinson's disease. *J Shoulder Elbow Surg* 1997;6:24–8.
- [15] Kryzak TJ, Sperling JW, Schleck CD, Cofield RH. Total shoulder arthroplasty in patients with Parkinson's disease. *J Shoulder Elbow Surg* 2009;18:96–9.
- [16] Lodos E, Nilsson LT, Stromqvist B. Internal fixation of femoral neck fractures in Parkinson's disease. 32 patients followed for 2 years. *Acta Orthop Scand* 1989;60:682–5.
- [17] Pritchett JW, Bortel DT. Parkinson's disease and femoral neck fractures treated by hemiarthroplasty. *Clin Orthop Relat Res* 1992;279:310–1.
- [18] Turcotte R, Godin C, Duchesne R, Jodoin A. Hip fractures and Parkinson's disease. A clinical review of 94 fractures treated surgically. *Clin Orthop Relat Res* 1990;256:132–6.

- [19] Hoehn MM, Yahr MD. Parkinsonism: onset, progression and mortality. *Neurology* 1967;17:427–42.
- [20] Queally JM, Abdulkarim A, Mulhall KJ. Total hip replacement in patients with neurological conditions. *J Bone Joint Surg Br* 2009;91:1267–73.
- [21] Park KS, Seon JK, Lee KB, Yoon TR. Total hip arthroplasty using large-diameter metal-on-metal articulation in patients with neuromuscular weakness. *J Arthroplasty* 2014;29:797–801.
- [22] Sutter EG, McClellan TR, Attarian DE, Bolognesi MP, Lachiewicz PF, Wellman SS. Outcomes of modular dual mobility acetabular components in revision total hip arthroplasty. *J Arthroplasty* 2017;32:S220–4.
- [23] Cabanela ME, Weber M. Total hip arthroplasty in patients with neuromuscular disease. *Instr Course Lect* 2000;49:163–8.
- [24] Fackler CD, Poss R. Dislocation in total hip arthroplasties. *Clin Orthop Relat Res* 1980;151:169–78.
- [25] Li J, Zheng W, Zhao J, Liu D, Xu W. Large diameter metal on metal total hip replacement for femoral neck fractures with neurological conditions: a retrospective assessment. *Indian J Orthop* 2014;48:605–11.
- [26] Mohammed R, Hayward K, Mulay S, Bindi F, Wallace M. Outcomes of dual-mobility acetabular cup for instability in primary and revision total hip arthroplasty. *J Orthop Traumatol* 2015;16:9–13.
- [27] Luthra JS, Al Riyami A, Allami MK. Dual mobility total hip replacement in a high risk population. *SICOT J* 2016;2:43.
- [28] Plummer DR, Christy JM, Sporer SM, Paprosky WG, Della Valle CJ. Dual-mobility articulations for patients at high risk for dislocation. *J Arthroplasty* 2016;31(9 Suppl):131–5.
- [29] Hamadouche M, Ropars M, Rodaix C, Musset T, Gaucher F, Biau D, et al. Five to thirteen year results of a cemented dual mobility socket to treat recurrent dislocation. *Int Orthop* 2017;41:513–9.
- [30] Graversen AE, Jakobsen SS, Kristensen PK, Thillemann TM. No dislocations after primary hip arthroplasty with the dual mobility cup in displaced femoral neck fracture in patients with dementia. A one-year follow-up in 20 patients. *SICOT J* 2017;3:9.
- [31] Lange JK, Spiro SK, Westrich GH. Utilizing dual mobility components for first-time revision total hip arthroplasty for instability. *J Arthroplasty* 2017. <https://doi.org/10.1016/j.arth.2017.09.029>. [Epub ahead of print].
- [32] Kaiser D, Kamath AF, Zingg P, Dora C. Double mobility cup total hip arthroplasty in patients at high risk for dislocation: a single-center analysis. *Arch Orthop Trauma Surg* 2015;135:1755–62.
- [33] Philippot R, Camilleri JP, Boyer B, Adam P, Farizon F. The use of a dual-articulation acetabular cup system to prevent dislocation after primary total hip arthroplasty: analysis of 384 cases at a mean follow-up of 15 years. *Int Orthop* 2009;33:927–32.
- [34] Malochet-Guinamand S, Durif F, Thomas T. Parkinson's disease: a risk factor for osteoporosis. *Joint Bone Spine* 2015;82:406–10.
- [35] Boonstra TA, van der Kooij H, Munneke M, Bloem BR. Gait disorders and balance disturbances in Parkinson's disease: clinical update and pathophysiology. *Curr Opin Neurol* 2008;21:461–71.
- [36] Kim Y, Tanaka C, Tada H, Kanoe H, Shirai T. Treatment of periprosthetic femoral fractures after femoral revision using a long stem. *BMC Musculoskelet Disord* 2015;16:113.