



### Science Arts & Métiers (SAM)

is an open access repository that collects the work of Arts et Métiers Institute of Technology researchers and makes it freely available over the web where possible.

This is an author-deposited version published in: <https://sam.ensam.eu>  
Handle ID: <http://hdl.handle.net/10985/18207>

#### To cite this version :

Louis BOISSIERE, Bertrand MOAL, Olivier GILLE, Elise DE-ROQUEFEUIL, Muriel DURIEUX, Ibrahim OBEID, Vincent DOUSSET, Jean-Marc VITAL, Wafa SKALLI - Lumbar spinal muscles and spinal canal study by MRI three-dimensional reconstruction in adult lumbar spinal stenosis - Revue de Chirurgie Orthopédique et Traumatologique - Vol. 103, n°2, p.279–283 - 2017

Any correspondence concerning this service should be sent to the repository

Administrator : [scienceouverte@ensam.eu](mailto:scienceouverte@ensam.eu)



# Lumbar spinal muscles and spinal canal study by MRI three-dimensional reconstruction in adult lumbar spinal stenosis

L. Boissière<sup>a,b,\*</sup>, B. Moal<sup>a</sup>, O. Gille<sup>b</sup>, E. De-Roquefeuil<sup>c</sup>, M. Durieux<sup>c</sup>, I. Obeid<sup>b</sup>, V. Dousset<sup>c</sup>, J.-M. Vital<sup>b</sup>, W. Skalli<sup>a</sup>

<sup>a</sup> Laboratory of Biomechanics, Arts et Métiers ParisTech, ENSAM, boulevard de l'Hôpital, 75013 Paris, France

<sup>b</sup> Spine Unit 1, Bordeaux University Hospital, place Amélie-Raba-Léon, 33076 Bordeaux, France

<sup>c</sup> Neuro-radiology Department, Bordeaux University Hospital, place Amélie-Raba-Léon, 33076 Bordeaux, France

## A B S T R A C T

**Background:** Lumbar spinal stenosis is degenerative disc disease most common manifestation. If stenosis degree seems poorly related to symptom severity, lumbar muscles role is recognized. Many studies report imaging methods, to analyze muscle volumes and fat infiltration (FI), but remain limited due to the difficulty to represent entire muscle volume variability. Recently a 3D muscle reconstruction protocol (using the deformation of a parametric specific object method (DPSO) and three-point Dixon images) was reported. It offers the ability to evaluate, muscles volumes and muscle FI.

**Purpose:** To describe, in a lumbar spinal stenosis population, muscle volumes, muscle FI and lumbar spinal canal volume with 3D MRI images reconstructions.

**Materials and methods:** Ten adults presenting L4–L5 lumbar stenosis, were included. After specific MRI protocol, three-dimensional, muscle and spinal canal, reconstructions were performed. Muscle (psoas and paraspinal muscles) volumes and fat infiltration (FI), the spinal canal volume, age, and height were correlated one to each other with Spearman correlation factor. An ANOVA was performed to evaluate the intervertebral level influence ( $P \leq 0.05$ ).

**Results:** Muscle volumes correlated with height ( $r = 0.68$  for psoas). Muscles FI correlated with age ( $r = 0.66$  for psoas) and lumbar spinal canal volume ( $r = 0.91$ ). Psoas and paraspinal volumes were maximum at L3–L4 level whereas FI increased from L1–L2 to L5–S1 level.

**Discussion:** These first results illustrate the importance to consider muscles entirely and report correlations between muscles FI, lumbar spinal canal volume and age; and between muscle volumes and patients height. Muscle degeneration seems more related to muscle FI than muscle volume.

**Level of evidence:** 3.

### Keywords:

Lumbar spine

Spinal stenosis

MRI

Three-dimension

Muscle

## 1. Introduction

Lumbar spinal stenosis (LSS) is degenerative disc disease most common manifestation, and induces neurologic claudication. Stenosis degree seems poorly related to symptom severity or functional impairment [1]. If nerve root direct compression is involved in physiopathology [2], lumbar muscles role is also recognized in clinical manifestations [3].

Muscle morphology influences muscle performance [4], and muscle degeneration can be characterized by muscular atrophy and fatty tissue deposit [5,6]. Many studies report imaging methods,

such as MRI or CT-scan, to appreciate it. However most studies assessing muscle cross-sectional areas (CSA) [7–9], or measurement of muscle density [10] are limited due to the difficulty to represent entire muscle volume variability [11]. Moreover significant modifications have been reported, in CSA studies, when slice orientation was modified [12]. Three-dimensional muscle reconstruction methods, via CT-scan [13] or MRI [14], have been performed but CT-scan provides an important radiation exposure, and T1-MRI sequences provide an inhomogeneity in the magnetic field making accurate fat infiltration (FI) quantification impossible.

Recently, Moal et al. [15] reported a 3D muscle reconstruction protocol (using the deformation of a parametric specific object method [DPSO] and three-point Dixon images). It offers the ability to evaluate, muscles volumes and muscle FI, with MRI specific sequences.

The purpose of this study was to describe, in a lumbar spinal stenosis population, muscle volumes, muscle FI and lumbar spinal canal volume with 3D MRI images reconstructions.

## 2. Material and methods

### 2.1. Patient selection

Inclusion criteria were adults, over 30 years old, with a symptomatic L4–L5 LSS, lasting for at least 12 weeks, and resisting to conservative treatment including painkillers and physiotherapy. Preponderance of symptoms should be radicular pain in one or both legs and walking difficulties.

Exclusion criteria were spinal instability identified on radiographies (spondylolisthesis, scoliosis), MRI contraindication, prior spine surgery, neurologic and/or muscular disorders, and occlusive arterial disease.

Ten patients were included (5 men and 5 women) in the present study (age  $58.5 \pm 15$  years; range, 35–81 years; height  $167.2 \pm 8.8$  cm; range 155–179 cm; weight  $74.5 \pm 17$  kg; range 46–105 kg; BMI  $26.5 \pm 5$  kg·m<sup>-2</sup>; range 19–35 kg·m<sup>-2</sup>). All patients gave informed consent for their clinical details and MRI to be used in the study. Patients were referred for a preoperative magnetic resonance imaging (MRI) and these were subsequently studied and measured.

### 2.2. Measures and procedures [15]

#### 2.2.1. MRI acquisition

All lumbar spine imaging were performed on a whole body MR system operating at 3.0T (General Electric®, Discovery MR750w). The imaging protocol included a T1-weighted turbo spin-echo (T1 TSE) sequence (TR/TE = 1220/11 ms, acquisition matrix =  $512^\circ \times 84$ , in plane resolution =  $0.98^\circ \times 0.98$  mm<sup>2</sup>, slice thickness = 5 mm, slice gap = 5 mm, parallel imaging acceleration factor (iPat) = 2, 40 slices, flip angle = 150°, bandwidth = 219 Hz/pixel, turbo factor = 5, acquisition time = 2:15 min) and a T1-weighted TSE sequence for applying the three-point Dixon method [16–19] (TR/TE = 829/15.7 ms, acquisition matrix =  $512^\circ \times 384$ , in plane resolution =  $0.98^\circ \times 0.98$  mm<sup>2</sup>, slice thickness = 5 mm, slice gap = 5 mm, iPat = 2, 40 slices, flip angle = 150°, bandwidth = 315 Hz/pixel, turbo factor = 3, echo spacing = 15.7, acquisition time = 4:38 min). The scanner from the TSE images, for the three-point Dixon method, automatically generated water and fat images. Both sequences had exactly the same slice position and orientation. Image volume covered the coccyx to the lumbar spine (Th12 vertebra) and was acquired in two stages. Total acquisition time was 30 min.

#### 2.2.2. Muscles and lumbar spinal canal reconstructions (DPSO method) (Fig. 1)

Muscles of interest were psoas and spine extensor paraspinal muscles (multifidus, longissimus and ilio-costal-muscle). 3D muscle and spinal canal reconstructions were performed using Muscl'X software, custom software (Laboratory of Biomechanics, Arts et Métiers ParisTech, France) [13]. The reconstructions extended from the last slice before T12–L1 intervertebral disc to the union with iliac muscle for the psoas and to S2 for posterior paraspinal muscles and vertebral spinal canal. Using the axial MRI images, the software generated the 3D geometry of each muscle. The reconstruction technique was based on the DPSO algorithm as described in the literature [13]. For this method, Li et al. report an intraclass correlation factor greater than 0.83 indicating very good reliability for muscle reconstruction [20]. To our knowledge, lumbar spinal canal reconstruction has not been described. An inter- and intra-observer

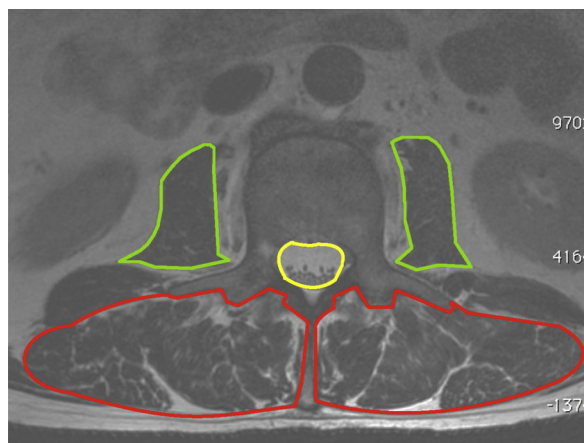


Fig. 1. Psoas, paraspinal muscles and spinal canal contouring with the DPSO method.

reliability analysis was performed for the lumbar canal reconstruction. Two trained ratters performed the measures. The first ratter performed the measures twice with a two weeks interval.

#### 2.2.3. MRI parameters

Muscle volume, spinal canal volume and muscle fat infiltration percentage, were calculated for psoas and posterior paraspinal muscles. The reconstructions were also segmented for an analysis level by level. Segmentation sections for each intervertebral level were in between each MRI pediculo-transverse slice.

#### 2.2.4. Statistical analysis

Wilcoxon test was used to compare muscle volumes, muscle FI and lumbar canal volume mean values. Spearman correlation coefficient was used to investigate the relationship between muscle volumes and FI percentage, lumbar spinal stenosis volume and morphometric parameters (age, height, weight, BMI). Friedman test was realized to evaluate the influence of intervertebral level. For lumbar canal reconstruction reliability analysis the intraclass correlation factor was calculated. For each statistical analysis, the level of significance was set at  $P \leq 0.05$ .

## 3. Results

### 3.1. Muscle volumes (Fig. 2)

Psoas muscle (mean  $\pm$  SD) volume was  $155 \pm 60$  cm<sup>3</sup> (range 48–253). Posterior paraspinal muscle volume was  $400 \pm 78$  cm<sup>3</sup> (244–494). The ratio between psoas and posterior paraspinal muscles was  $0.4 \pm 0.1$  (0.2–0.5). No significant differences were found between right and left muscles.

### 3.2. Muscular fat infiltration

Psoas muscle (mean  $\pm$  SD) FI was  $41 \pm 11\%$  (range 28–76). Posterior paraspinal muscles FI was  $44 \pm 12\%$  (26–69). The ratio between psoas and posterior paraspinal muscles was  $1 \pm 0.2$  (0.7–1.4). No significant differences were found between right and left muscles.

### 3.3. Lumbar canal volume

The mean lumbar spinal canal volume was  $31.3 \pm 5.5$  cm<sup>3</sup> (range 21.4–41.2). Intraclass correlation coefficient for inter- and intra-observer reliability was 0.92 (0.90–0.95).

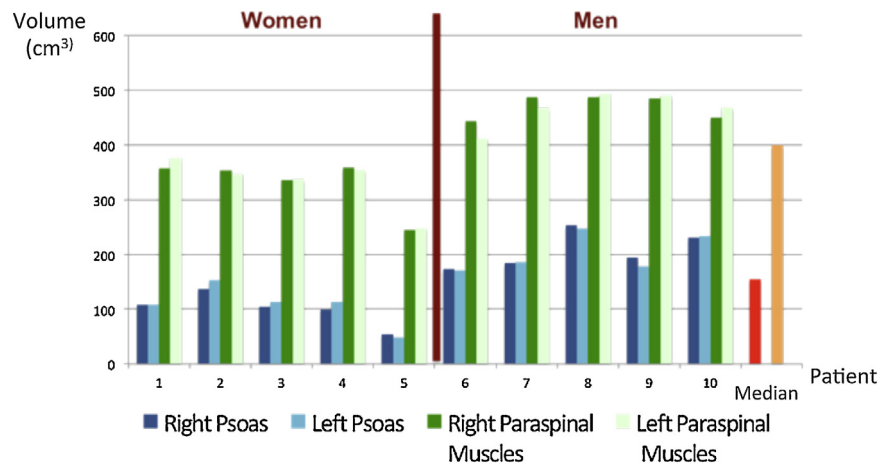


Fig. 2. Psoas and paraspinal muscles right and left volumes.

**Table 1**  
Statistical significant correlations for muscle volumes, fat infiltration and spinal canal volume.

Spearman correlation factor	Psoas volume	Psoas fat infiltration	Paraspinal muscle volume	Paraspinal muscle fat infiltration	Spinal canal volume
Age		0.66		0.68	0.7
Height	0.68		0.68		
Psoas volume			0.86		
Psoas fat infiltration				0.82	0.89
PSM volume	0.86				
PSM fat infiltration		0.82			0.91
Spinal canal volume		0.89		0.91	

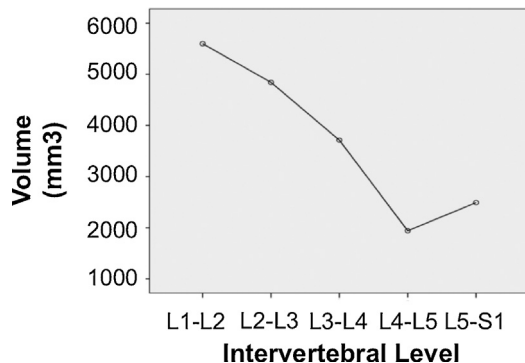


Fig. 3. Lumbar spinal canal volume according to intervertebral level.

### 3.4. Correlation analysis (Table 1)

Muscle volumes correlated with height ( $r=0.68$  for psoas and paraspinal muscles) and other muscle volumes ( $r=0.86$ ). Muscles FI correlated with age ( $r=0.66$  for psoas and  $0.68$  for paraspinal muscles), other muscles fat infiltration ( $r=0.82$ ) and Lumbar spinal canal volume ( $r=0.91$ ). All these correlations were statistically significant ( $P<0.05$ ). No significant correlations were found for weight and BMI.

### 3.5. Segmental analysis

#### 3.5.1. Spinal canal (Fig. 3)

The lumbar canal volume significantly ( $P<0.01$ ) decreased from L1–L2 to L5–S1 and was minimum at L4–L5 level.

#### 3.5.2. Psoas muscle

The psoas volume significantly ( $P<0.01$ ) increased from L1–L2 to L3–L4 and was maximum at L3–L4 level. The psoas fat infiltration

significantly ( $P<0.01$ ) increased at each intervertebral level from L1–L2 to L5–S1.

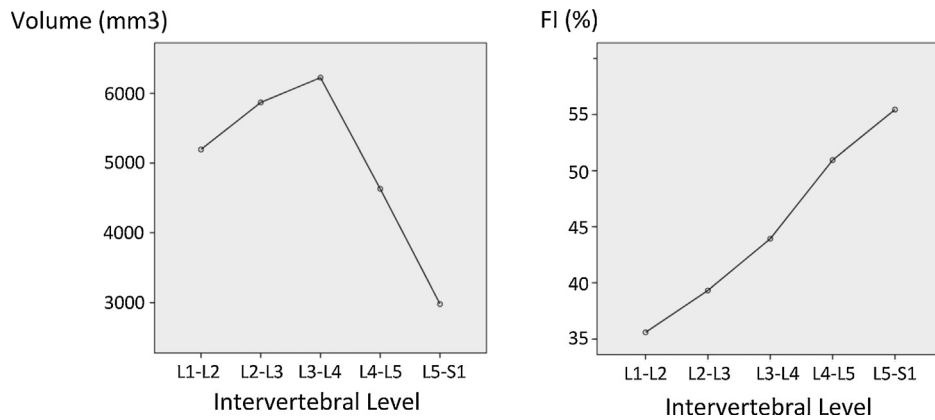
#### 3.5.3. Posterior paraspinal muscles (Fig. 4)

The paraspinal muscles volume was maximum at L3–L4 level. Fat infiltration percentage significantly ( $P<0.01$ ) increased progressively from 35% at L1–L2 level to 55% at L5–S1 level.

## 4. Discussion

Lumbar spine muscles imaging description has widely been described, but three-dimensional MRI studies remain limited. It offers the ability to study a muscle entirely without any radiation exposure. The protocol used in this study, with Dixon acquisitions, was previously reported and permits a quantitative and qualitative muscle characterization [15]. If muscle importance in degenerative lumbar spine seems admitted, its relationship with lumbar spinal stenosis remains controversial. To our knowledge, no three-dimensional studies evaluating lumbar spinal muscles and lumbar vertebral canal were reported. The main purpose of this study was to study together lumbar muscles and lumbar vertebral canal and investigate possible relationships. Despite some limits concerning the number of included patients, and control group absence, several conclusions can be drawn.

Muscle volumes correlated with height ( $r=0.68$ ) but not age, weight or BMI. This is in contrast with most CSA studies where correlation between muscle volumes and age were reported [21,22]. On the opposite Valentin et al., in a tridimensional reconstruction study, concluded that the effect of age cannot be generalized across all muscles [23]. These findings underline the interest of studying entire muscles as CSA studies only consider muscle surface. Muscle volume appears more as a morphologic parameter. In this cohort, height and sex are highly correlated ( $r=0.88$ ) introducing a potential bias. Indeed no multivariate analysis can be performed, but the relationship between muscle volume's and height is in accordance



**Fig. 4.** Paraspinal muscles volume and fat infiltration percentage according to intervertebral level.

with previous literature reports [15,24]. Further studies including a larger number of patients should be performed, to investigate the age-muscle volume relationship and the influence of sex and height on muscle volumes. Another limit that could be pointed out is the patient's physical activity that was not taken into account in this study.

If muscle volume did not correlate with age, muscle FI was significantly correlated with age ( $r=0.66$  for psoas and  $r=0.68$  for paraspinal muscles), underlining that muscle FI takes part, or is a consequence, of degenerative processes. Increased muscle FI has been associated with ageing and low back pain [25], but studies on muscle FI produced inconsistent results. Fortin et al. [26] reported a modest and inconsistent effect of age on muscle composition. These disparities could be explained by the different measuring methods used. Magnetic field inhomogeneity's making accurate FI quantification impossible was reported for MRI sequences [14]. MRI protocol using three-point Dixon images eliminates inhomogeneity to obtain reliable muscle FI quantification. Muscle FI and age highly correlate with lumbar spinal canal volume. To our knowledge, this is the first published study evaluating lumbar spinal canal volume and its relationship with muscle volumes and muscle FI. If lumbar canal volume correlated with age, it is mostly related with muscle FI ( $r=0.9$ ). These findings open a new field of investigations. Indeed muscle FI has been associated with clinical functional scores [27], and no correlation was found between the importance of LSS and functional scores [28]. These reports seem contradictory considering the relationship between muscle FI and LSS. Correlations between these two parameters agree with literature report. Indeed Chen et al. [27] reported differential muscle changes in unilateral chronic compressions. These preliminary results should be enhanced with a larger cohort to investigate more precisely the relationship between age, lumbar canal volume and muscle FI.

Studying the entire muscles made a proper segmental analysis possible to evaluate the intervertebral level influence. LSS severity was maximal at L4–L5 level, underlining the consistency with inclusion criteria. Lumbar canal volume and muscle volume appear as morphologic parameters depending on patient's anatomy. Muscle volume was maximal at L3–L4 level, and lumbar canal volume decreased with intervertebral level. Muscle FI also decreased with intervertebral level. These findings are similar with disc degeneration processes with a maximum at L5–S1 level and a minimum at L1–L2 level. D'Hooge et al. [29] reported similar findings with increased muscle degeneration at the lower levels.

## 5. Conclusion

This study, with an original three-dimensional reconstruction method, reports correlations between muscle volumes and height

and between muscle FI, age and lumbar spinal canal volume. Muscle FI was maximum at the lower spine levels and decreased progressively. Despite the small number of patients included, muscle FI seems more related to muscle degeneration than muscle volume.

## Disclosure of interest

The authors declare that they have no competing interest.

## References

- [1] Backstrom KM, Whitman JM, Flynn TW. Lumbar spinal stenosis-diagnosis and management of the aging spine. *Man Ther* 2011;16:308–17.
- [2] Brish A, Lerner MA, Braham J. Intermittent claudication from compression of cauda equina by a narrowed spinal canal. *J Neurosurg* 1964;21:207–11.
- [3] Sullivan MS. Back support mechanisms during manual lifting. *Phys Ther* 1989;69:38–45.
- [4] Gibbons LE, Latikka P, Videman T, Manninen H, Battie MC. The association of trunk muscle cross-sectional area and magnetic resonance image parameters with isokinetic and psychophysical lifting strength and static back muscle endurance in men. *J Spinal Disord* 1997;10:398–403.
- [5] Hicks GE, Simonsick EM, Harris TB, Newman AB, Weiner DK, Nevitt MA, et al. Cross-sectional associations between trunk muscle composition, back pain, and physical function in the health, aging and body composition study. *J Gerontol A Biol Sci Med Sci* 2005;60:882–7.
- [6] Kamath S, Venkatanarasimha N, Walsh MA, Hughes PM. MRI appearance of muscle denervation. *Skeletal Radiol* 2008;37:397–404.
- [7] Barker KL, Shamley DR, Jackson D. Changes in the cross-sectional area of multifidus and psoas in patients with unilateral back pain: the relationship to pain and disability. *Spine (Phila Pa 1976)* 2004;29:E515–9.
- [8] Dangaria TR, Naesh O. Changes in cross-sectional area of psoas major muscle in unilateral sciatica caused by disc herniation. *Spine (Phila Pa 1976)* 1998;23:928–31.
- [9] Gille O, de Seze MP, Guerin P, Jolivet E, Vital JM, Skalli W. Reliability of magnetic resonance imaging measurements of the cross-sectional area of the muscle contractile and non-contractile components. *Surg Radiol Anat* 2011;33:735–41.
- [10] Danneels LA, Vanderstraeten GG, Cambier DC, Witvrouw EE, De Cuyper HJ. CT imaging of trunk muscles in chronic low back pain patients and healthy control subjects. *Eur Spine J* 2000;9:266–72.
- [11] Tracy BL, Ivey FM, Jeffrey Metter E, Fleg JL, Siegel EL, Hurley BF. A more efficient magnetic resonance imaging-based strategy for measuring quadriceps muscle volume. *Med Sci Sports Exerc* 2003;35:425–33.
- [12] Henderson L, Kulik G, Richarme D, Theumann N, Schizas C. Is spinal stenosis assessment dependent on slice orientation? A magnetic resonance imaging study. *Eur Spine J* 2012;21(Suppl. 6):S760–4.
- [13] Jolivet E, Daguet E, Pomero V, Bonneau D, Laredo JD, Skalli W. Volumetric patient-specific reconstruction of muscular system based on a reduced dataset of medical images. *Comput Methods Biomech Biomed Engin* 2008;11:281–90.
- [14] Sudhoff I, de Guise JA, Nordez A, Jolivet E, Bonneau D, Khoury V, et al. 3D-patient-specific geometry of the muscles involved in knee motion from selected MRI images. *Med Biol Eng Comput* 2009;47:579–87.
- [15] Moal B, Bronsard N, Raya JG, Vital JM, Schwab F, Skalli W, et al. Volume and fat infiltration of spino-pelvic musculature in adults with spinal deformity. *World J Orthop* 2015;6:727–37.
- [16] Dixon WT. Simple proton spectroscopic imaging. *Radiology* 1984;153:189–94.
- [17] Glover GH, Schneider E. Three-point Dixon technique for true water/fat decomposition with B0 inhomogeneity correction. *Magn Reson Med* 1991;18:371–83.

- [18] Glover GH. Multipoint Dixon technique for water and fat proton and susceptibility imaging. *J Magn Reson Imaging* 1991;1:521–30.
- [19] Yeung HN, Kormos DW. Separation of true fat and water images by correcting magnetic field inhomogeneity in situ. *Radiology* 1986;159:783–6.
- [20] Li F, Laville A, Bonneau D, Laporte S, Skalli W. Study on cervical muscle volume by means of three-dimensional reconstruction. *J Magn Reson Imaging* 2014;39:1411–6.
- [21] Fortin M, Videman T, Gibbons LE, Battie MC. Paraspinal muscle morphology and composition: a 15-yr longitudinal magnetic resonance imaging study. *Med Sci Sports Exerc* 2014;46:893–901.
- [22] Takahashi K, Takahashi HE, Nakadaira H, Yamamoto M. Different changes of quantity due to aging in the psoas major and quadriceps femoris muscles in women. *J Musculoskelet Neuronal Interact* 2006;6:201–5.
- [23] Valentin S, Licka T, Elliott J. Age and side-related morphometric MRI evaluation of trunk muscles in people without back pain. *Man Ther* 2014.
- [24] Maden-Wilkinson TM, McPhee JS, Rittweger J, Jones DA, Degens H. Thigh muscle volume in relation to age, sex and femur volume. *Age (Dordr)* 2014;36:383–93.
- [25] Mengiardi B, Schmid MR, Boos N, Pfirrmann CW, Brunner F, Elfering A, et al. Fat content of lumbar paraspinal muscles in patients with chronic low back pain and in asymptomatic volunteers: quantification with MR spectroscopy. *Radiology* 2006;240:786–92.
- [26] Fortin M, Macedo LG. Multifidus and paraspinal muscle group cross-sectional areas of patients with low back pain and control patients: a systematic review with a focus on blinding. *Phys Ther* 2013;93:873–88.
- [27] Chen YY, Pao JL, Liaw CK, Hsu WL, Yang RS. Image changes of paraspinal muscles and clinical correlations in patients with unilateral lumbar spinal stenosis. *Eur Spine J* 2014;23:999–1006.
- [28] Yasar B, Simsek S, Er U, Yigitkanli K, Eksioğlu E, Altug T, et al. Functional and clinical evaluation for the surgical treatment of degenerative stenosis of the lumbar spinal canal. *J Neurosurg Spine* 2009;11:347–52.
- [29] D'Hooge R, Cagnie B, Crombez G, Vanderstraeten G, Dolphens M, Danneels L. Increased intramuscular fatty infiltration without differences in lumbar muscle cross-sectional area during remission of unilateral recurrent low back pain. *Man Ther* 2012;17:584–8.