



Science Arts & Métiers (SAM)

is an open access repository that collects the work of Arts et Métiers Institute of Technology researchers and makes it freely available over the web where possible.

This is an author-deposited version published in: <https://sam.ensam.eu>
Handle ID: <http://hdl.handle.net/10985/18316>

To cite this version :

Tamás S. ILLES, François LAVASTE, Jean-François DUBOUSSET - The third dimension of scoliosis: The forgotten axial plane - Revue de Chirurgie Orthopédique et Traumatologique - Vol. 105, n°2, p.351-359 - 2019

Any correspondence concerning this service should be sent to the repository

Administrator : scienceouverte@ensam.eu



The third dimension of scoliosis: The forgotten axial plane

Tamás S. Illés^{a,b,c,*}, Francois Lavaste^d, Jean F. Dubousset^c

^a Orthopaedic and Trauma Surgery, CHU–Brugmann, Université Libre de Bruxelles/Vrije Universiteit Brussel, Brussels, Belgium

^b Orthopaedic and Trauma Surgery, CHU–Odense and Clinical Research Institute, Denmark South University, Odense, Denmark

^c Académie Nationale de Médecine, 16, rue Bonaparte, 75006 Paris, France

^d Institute of Biomechanics Human Georges-Charpak, Arts et métiers ParisTech, 151, boulevard de l'Hôpital, 75013 Paris, France

A B S T R A C T

Idiopathic scoliosis is a three-dimensional (3D) deformity of the spine. In clinical practice, however, the diagnosis and treatment of scoliosis consider only two dimensions (2D) as they rely solely on postero-anterior (PA) and lateral radiographs. Thus, the projections of the deformity are evaluated in only the coronal and sagittal planes, whereas those in the axial plane are disregarded, precluding an accurate assessment of the 3D deformity. A universal dogma in engineering is that designing a 3D object requires drawing projections of the object in all three planes. Similarly, when dealing with a 3D deformity, knowledge of the abnormalities in all three planes is crucial, as each plane is as important as the other two planes. This article reviews the chronological development of axial plane imaging and spinal deformity measurement.

Keywords:
Scoliosis
Axial plane
Top view
Vertebral vector

1. Introduction

Idiopathic scoliosis is a three-dimensional (3D) deformity of the spine. However, the diagnosis and treatment of scoliosis currently rely solely on postero-anterior (PA) and lateral radiographs. In engineering, designing and creating a 3D object requires drawing projections of the object in all three planes. This approach is dogma in all fields of engineering including aeronautics, the automobile industry, and civil engineering. The two-dimensional (2D) diagnosis and treatment of scoliosis due to reliance on PA and lateral radiographs flies in the face of this dogma, as the projections of the deformity are evaluated in the coronal and sagittal planes but not in the axial plane. This 2D management strategy has its roots in historical factors but is not acceptable for assessing a 3D deformity. The abnormalities must be evaluated in all three planes, and each plane is as important as the other two.

This article reviews the development over time of imaging and measurement techniques for axial plane abnormalities then discusses the latest orientations and most promising new methods.

That scoliosis involves multiple dimensions was suggested centuries ago. In the late 18th century, Magny was the first to report that vertebral rotation was a component of scoliotic deformities (Fig. 1

[1]. In 1882, Adams gave an accurate description of vertebral axial plane rotation in scoliotic deformities based on a study of several cadaver specimens. He also gave detailed descriptions of other axial plane deformities, such as those affecting the ribs and rib cage, with formation of a gibbus deformity due to axial vertebral rotation or lateral vertebral displacement during scoliosis development (Fig. 2) [2]. These accurate anatomical descriptions led to a consensus that scoliosis was a 3D deformity in the late 19th century.

In the early 20th century, the advent of radiography provided the first opportunity for a direct evaluation of scoliotic deformities in living patients [3]. However, the widespread use of radiographic images, with a predominant focus on descriptions and measurements in the coronal plane, gradually led most surgeons to neglect the abnormalities in the other planes. Cobb's angle, measured in the coronal plane, is currently the reference standard for assessing the severity of scoliosis [4].

Despite widespread recognition that scoliosis is a 3D deformity, evaluation of the characteristics of the sagittal curve were also introduced only fairly recently, because the most striking component of the scoliotic deformity is in the coronal plane. Sagittal curve abnormalities are challenging to assess, as the normal sagittal curve variations are also difficult to describe accurately. Consequently, emphasis has been placed recently on characterising the normal sagittal alignment rather than on evaluating the sagittal components of scoliotic deformities. Sagittal alignment is fairly easy to visualise and analyse on lateral radiographs. Normal sagittal alignment and its alterations induced by scoliosis are currently among the most often studied characteristics of the spine [5,6].

* Corresponding author. Département de chirurgie orthopédique et de traumatologie, CHU–Brugmann, 4, place Van Gehuchten, 1020 Brussels, Belgium.

E-mail addresses: tamasilles58@yahoo.com, tamas.illes@chu-brugmann.be (T.S. Illés).

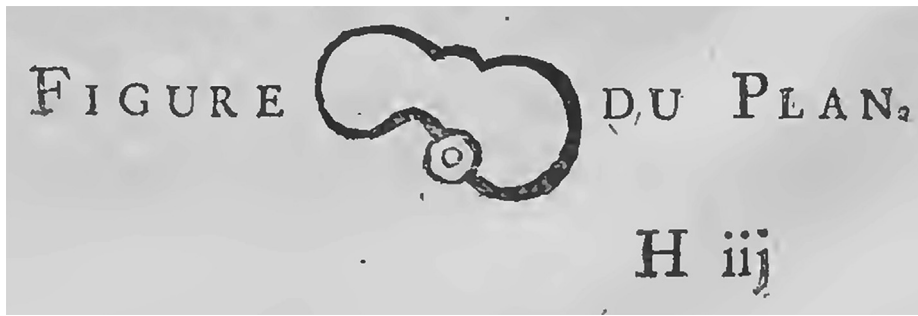

Fig. 1. M. Magny: Report on rakis, a disease of the spinal column [1]. This is probably the earliest representation of scoliosis projected onto the axial plane.

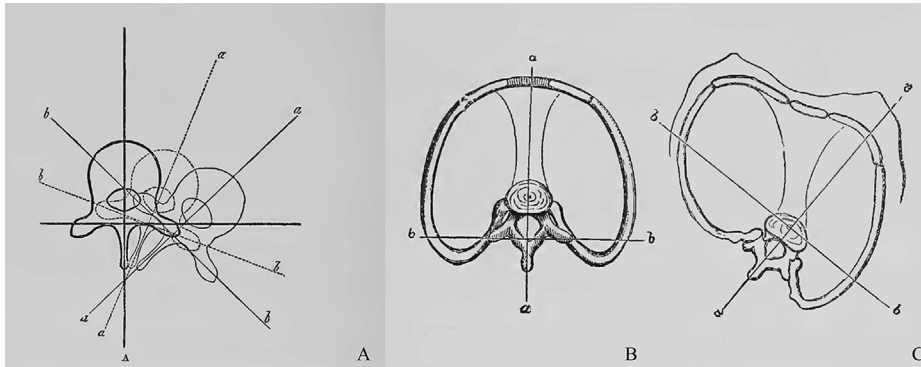


Fig. 2. Top view showing scoliosis in the axial plane, from Adams [2]. This is a surprisingly accurate representation of axial vertebral rotation (A), of the normal thoracic structure (B), and of the thoracic deformity that occurs during the development of a gibbus secondary to axial vertebral rotation (C).

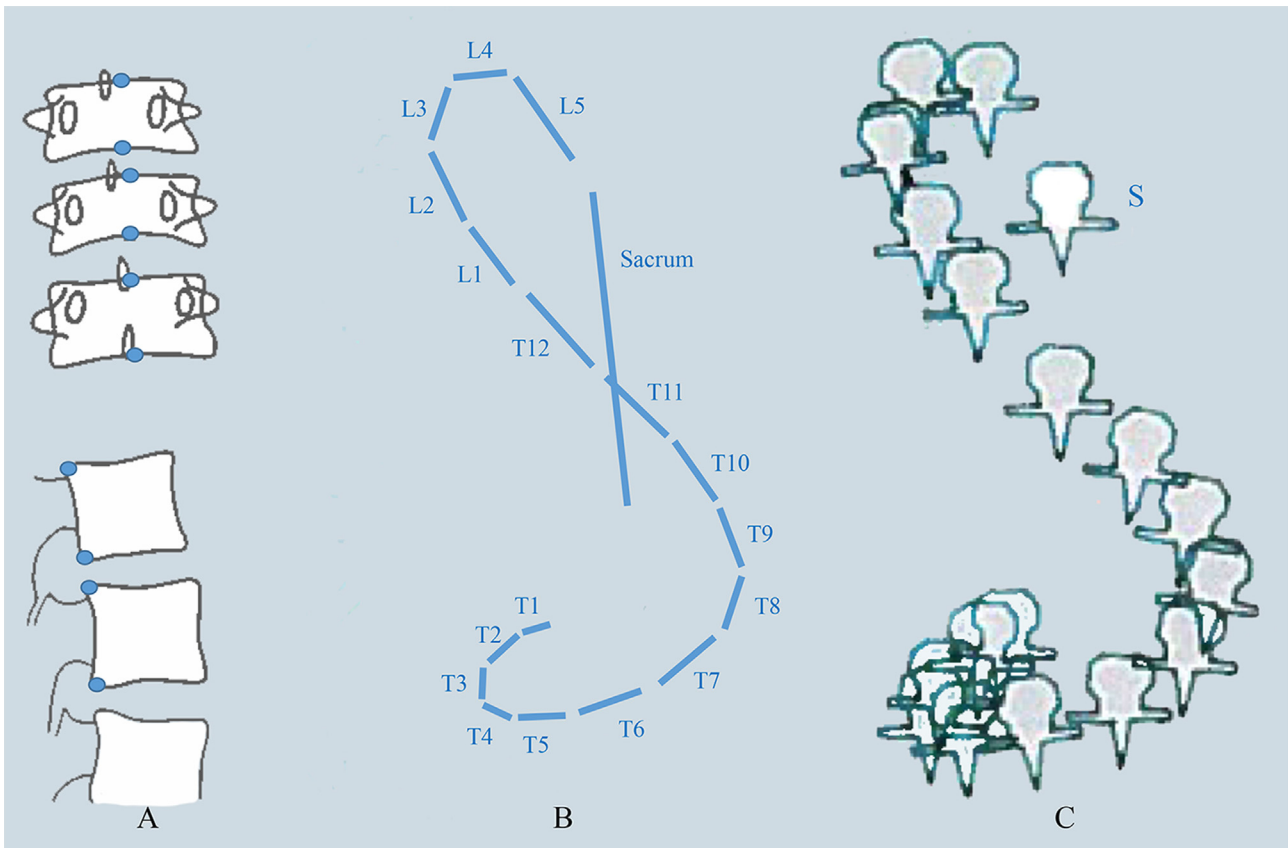


Fig. 3. The earliest spinal imaging technique based on informatics technology [8]. Standing postero-anterior and lateral radiographs were used. The posterior edge of the S1 endplate and centre of each vertebral endplate were marked on the postero-anterior view and the posterior edge of each vertebral endplate on the lateral view (blue dots on the diagram, A). Rotation of each vertebra was also measured on the postero-anterior view using Perdriolle's technique. Seven points were used for each vertebra. Based on these data, the software directly produced a three-dimensional reconstruction of the spine that visualised the curves in the coronal, sagittal, and axial planes. Each line represents a vertebra. The length of each line depends on the height of the vertebra and on its inclination on the horizontal plane (B). The software also provided an idealised display of the spine in the axial plane (C).

Measurements in the sagittal plane are included in a widely used classification system for scoliosis [7].

Unfortunately, no such attention has been directed at evaluating abnormalities in the axial plane, despite a study by the senior author of this article (JD) establishing the considerable importance of axial plane deformities [8]. In this study, a computer-assisted method was used to evaluate the 3D projection of the spinal deformity. A 3D reconstruction of the spine was obtained after marking the posterior edge of the S1 plateau and the centre of each of the other vertebral plateaus on the PA radiograph and the posterior edge of each vertebra on the lateral radiograph. In addition, Perdirolle's method was used to measure vertebral rotation at each level. Specially designed software produced a 3D reconstruction of the spine. A top view, i.e., a view in the axial plane, was also obtained, and seemed to be the most informative view (Fig. 3). This method was applied to 30 paediatric patients with scoliosis with the goal of separating progressive and non-progressive cases. Six prognostic types were defined. This study demonstrated that the prognosis of scoliosis cannot be predicted based only on PA and lateral radiographs.

Recognition of the importance of abnormalities in the axial plane led to the development of a surgical derotation technique. The introduction of Cotrel-Dubousset instrumentation (CDI) based on the concept that deformities in all three planes must be corrected was the main consequence of recognition that axial plane deformities constitute a major component of scoliosis [9].

In addition, the description and evaluation of axial plane abnormalities led to the identification of major postoperative changes such as the crankshaft phenomenon after posterior fusion [10]. In the crankshaft phenomenon, continued anterior spinal growth during the initial period following posterior fusion results in progressive vertebral rotation in the axial plane (Fig. 4). Understanding this phenomenon is difficult or perhaps impossible without top views [10]. Paradoxical kyphosis due to marked vertebral rotation is common in patients with severe scoliosis and also cannot be understood without analysing the axial plane [11].

Regrettably, these first conclusions about the importance of axial plane abnormalities were not well understood. However, the worldwide acceptance of CDI created a strong demand for evaluations of the projections of scoliotic deformities in all three planes [12]. In 1994, the 3D Terminology of Spinal Deformity Working Group of the Scoliosis Research Society (SRS) emphasised the need for a true 3D tool capable of diagnosing and accurately evaluating scoliotic deformities in all three planes [13].

Computed tomography (CT) (Fig. 5) and magnetic resonance imaging (MRI) seem to be the most accurate investigations for assessing alterations in the axial plane [14–19]. Both CT and MRI have been developed as diagnostic tools for scoliosis. However, their use in everyday practice is limited as both are costly and CT requires exposure to high radiation doses. Another limitation is that both methods are used with the patient in the supine position, which can significantly change the curves in all three planes [20]. Consequently, 2D imaging by PA and lateral radiographs remains the main diagnostic investigation in patients with scoliosis. Nevertheless, visualising and evaluating axial plane abnormalities is a major challenge, particularly in everyday clinical practice.

2. 2D Measurements

Given the central role of 2D X-ray images in the clinical evaluation of scoliosis, several mathematical approaches based on 2D measurements have been developed to estimate the amount of vertebral rotation in the axial plane. The measurements use anatomical vertebral landmarks such as the pedicles and spinous processes, which are visible on both the PA and lateral views.

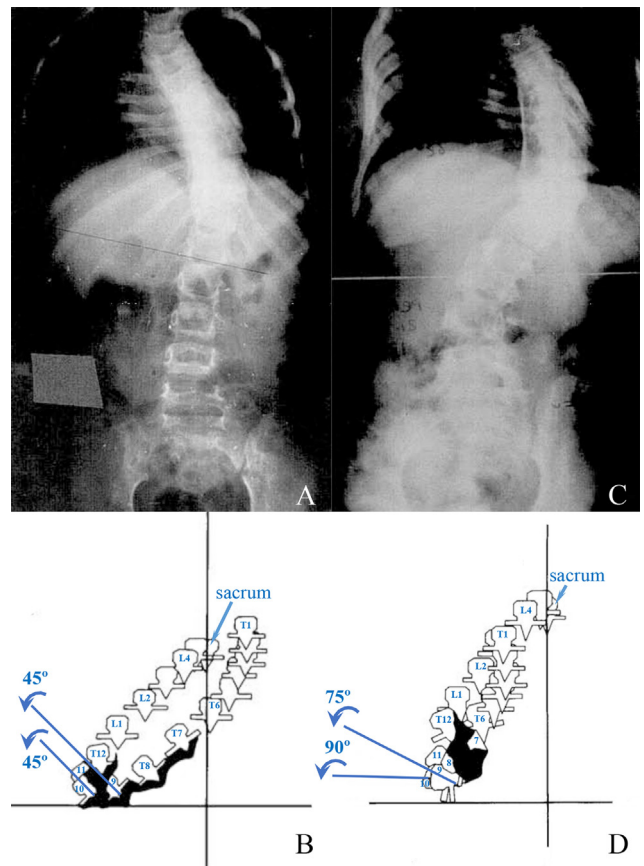


Fig. 4. The crankshaft phenomenon [10]. Postero-anterior radiographs obtained before surgery (A) and some time after surgery (C) in the same patient. Top views before surgery (B) and some time after surgery (D): due to the major rotation ($> 90^\circ$) of the apical vertebra (T10), the fusion mass (in black) gradually moved forwards towards the vertebral bodies. Consequently, growth of the vertebral bodies caused not only additional angulation and rotation of the spine, but also apparent progressive kyphosis.

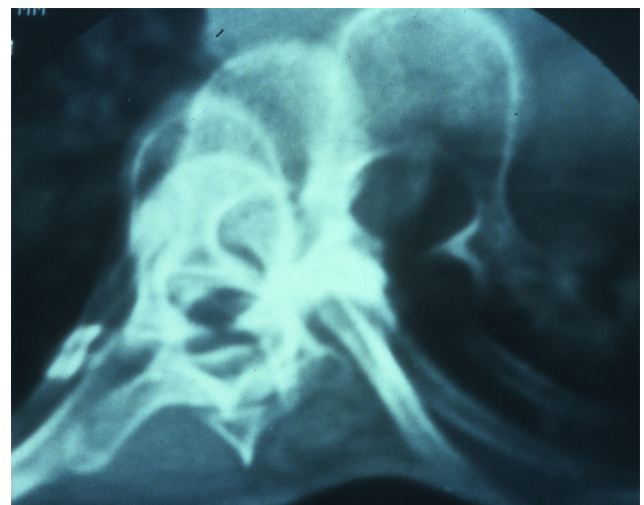


Fig. 5. Computed tomography scan showing rotation of several vertebrae in a patient with scoliosis.

Although radiographs can be obtained in 2D, axial vertebral rotation was long evaluated based solely on the relative positions of the neural arch components on the PA view. Thus, Cobb used the position of the spinal process relative to the lateral edges of the vertebra as the criterion for estimating vertebral rotation

(Fig. 6A) [4]. Nash and Moe improved the quantification of rotation by instead assessing the position of the vertebral pedicles relative to the vertebral body, also on PA radiographs [22]. The pedicles, which normally project onto the lateral part of the vertebral body, move toward the centre of the body as rotation increases (Fig. 6B). The method was further improved by Stokes et al., who

combined the position of the pedicles relative to the centre of the vertebral body with known vertebral parameters such as the interpedicular distance and the offset of the pedicles from the centre of the vertebral body (Fig. 6C) [23]. Perdrille and Vidal developed a torsionmeter to measure the angle of vertebral rotation directly from a life-size radiograph (Fig. 6D) [24]. The measurement tool

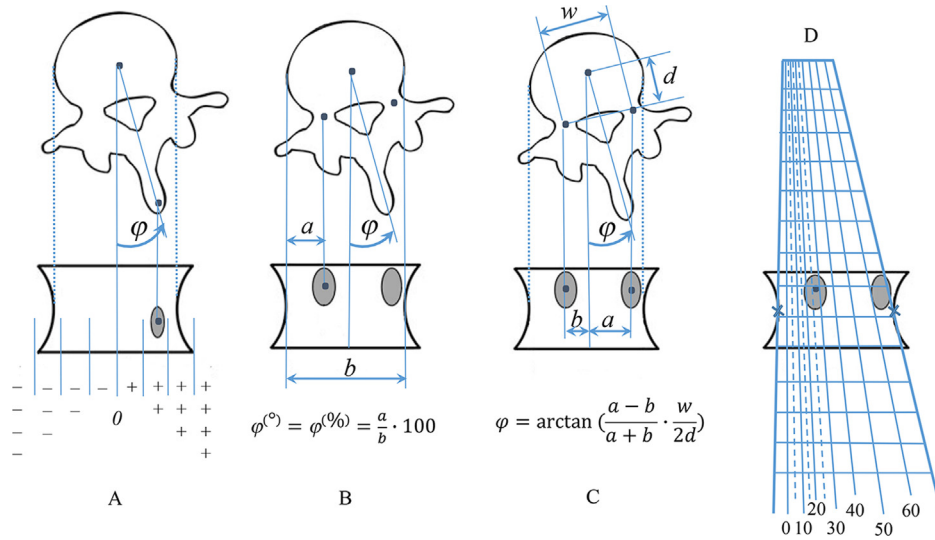


Fig. 6. Methods for quantitative evaluation of axial vertebral rotation [21]. Cobb (A), Nash and Moe (B), Stokes (C), and Perdrille (D).

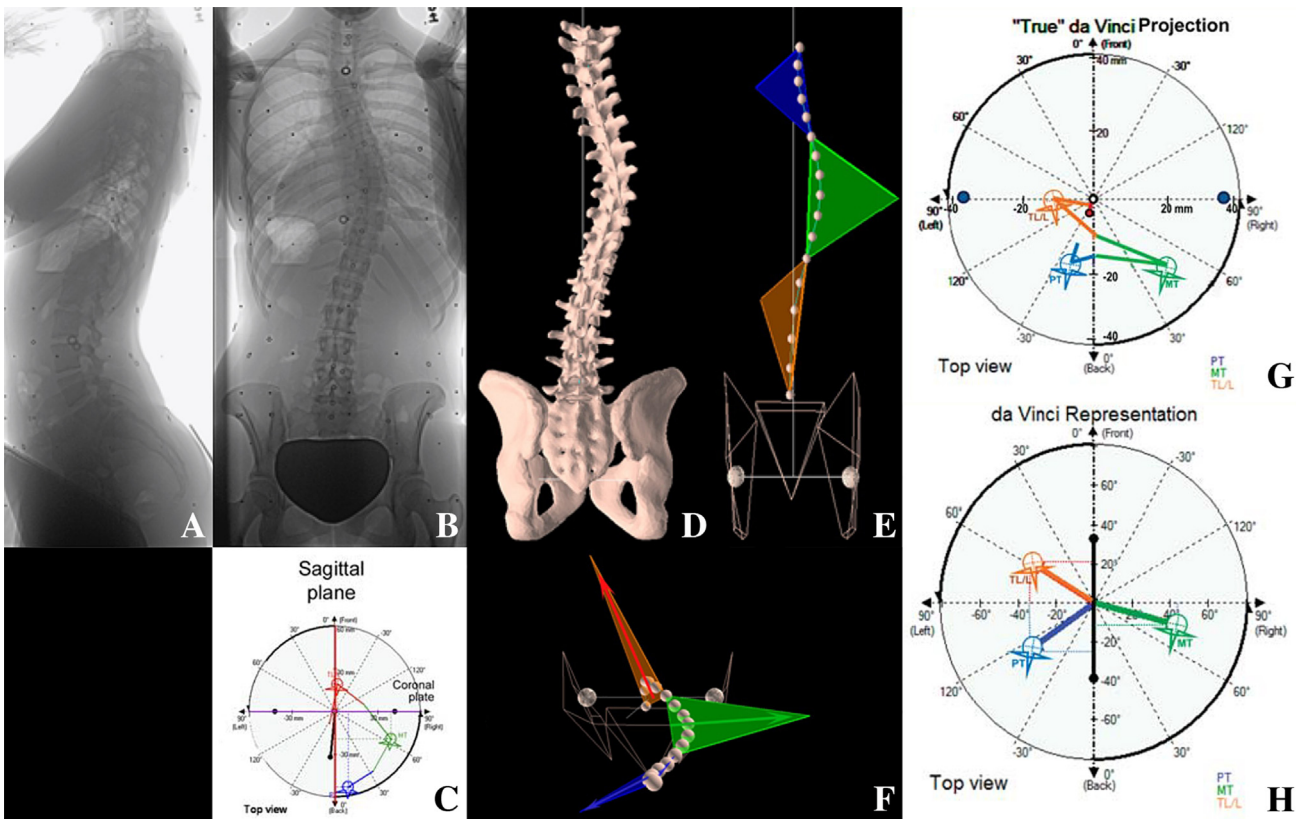


Fig. 7. Plane of maximum curvature (PMC): top-view display according to the da Vinci representation [36]. A and B. Lateral (A) and postero-anterior (B) radiographs in a patient with severe thoracic scoliosis. C. The top view of the apical vertebrae shown on a circular graph. D. 3D reconstruction of the scoliosis in the same patient. E and F. PMCs of the upper thoracic curve (blue), main thoracic curve (green), and thoraco-lumbar/lumbar curve (orange) in the coronal plane (E) and axial plane (F). G. The da Vinci projection is a schematic representation of the PMCs and of the severity of the curves at the various segments of the spine. H. da Vinci representation of the same curves in which the PMCs are replaced by arrows drawn from the centre to the apex of each PMC. The length of each arrow is proportional to the curve, its horizontal projection reflects the magnitude of the coronal deformity, and its vertical projection reflects the sagittal component of the deformity. In addition, vertebral body rotation is represented by a simplified graphic display of each apical vertebra with the spinal process indicating the direction and amount of rotation in the axial plane.

positioned on the radiograph and aligned with the lateral edges of the vertebral body under study indicates the angle of rotation in 5° increments based on a line drawn through the centre of the inner pedicle. Although widely used in clinical practice the Perdriolle torsionmeter offers only very limited reproducibility and precision [25]. Several other methods have been developed, but all of them derive from the principles underlying the four above-described methods [22].

Reliability is limited for all the methods used to estimate axial rotation based on PA radiographs, as these images do not provide sufficiently accurate qualitative and quantitative information on the anatomical structures needed to assess axial rotation. In addition, all the available studies focussed solely on axial rotation, disregarding lateral vertebral translation, which also contributes to the axial deformity [22].

3. 2.5D measurements

To improve the accuracy of axial rotation measurements, several methods have been developed using stereoradiography, lateral oblique and PA radiographs, or radiographs in two orthogonal planes [26,27]. In general, the principles and implementation of these methods are as suggested by the senior author of this article (JD). Axial rotation is measured after 3D vertebral reconstruction based on identification of the same anatomical vertebral landmarks on the PA and lateral views. To obtain good precision and reproducibility of 3D reconstructions, the vertebral landmarks must be accurately defined on orthogonal PA and lateral views. Careful attention to patient position is essential to ensure that the two views are at a 90° angle relative to each other.

Spinal 3D reconstructions provide the most accurate vertebral rotation measurements [28]. Nevertheless, many other methods for estimating axial vertebral rotation have been developed using various geometrical formulas or software tools and modern digital imaging systems [29–33].

4. Quasi-3D measurements–Plane of Maximum Curvature (PMC)

In 1994, the 3D Terminology of Spinal Deformity Working Group of the SRS recognised the need for a true 3D method for diagnosing scoliosis but also acknowledged that 3D imaging is a major challenge. Our approach seeks to take this human limitation under consideration by extensively using spinal projections onto accessory planes. The values thus obtained are quasi-3D rather than truly 3D measurements yet strike a reasonable compromise between mathematical doctrine on the one hand and conceptual and practical constraints on the other [13].

The plane of maximum curvature (PMC) was introduced based on the above-reported data to characterise spinal deformities in all three dimensions [34]. The PMC is defined as the plane passing through the centres of the two end vertebrae and of the apical vertebra. By definition, the PMC is similar to the preferred plane used by Stagnara et al. for radiologically assessing severe scoliotic curves [35]. The PMC, although fairly easy to identify, does not indicate the true anatomical coronal, sagittal, or axial plane. Consequently, the clinical impact and relevance of the PMC are difficult to define (Fig. 7) [37].

Despite the huge efforts and dogged work supplied by renowned spine surgeons, we believe that the PMC is an abstraction that attempts to delimit the 3D deformity without using sophisticated tools, although these can provide the true axial projection of the scoliosis. New techniques are continually suggested but their application to everyday clinical practice is difficult. The horizontal view

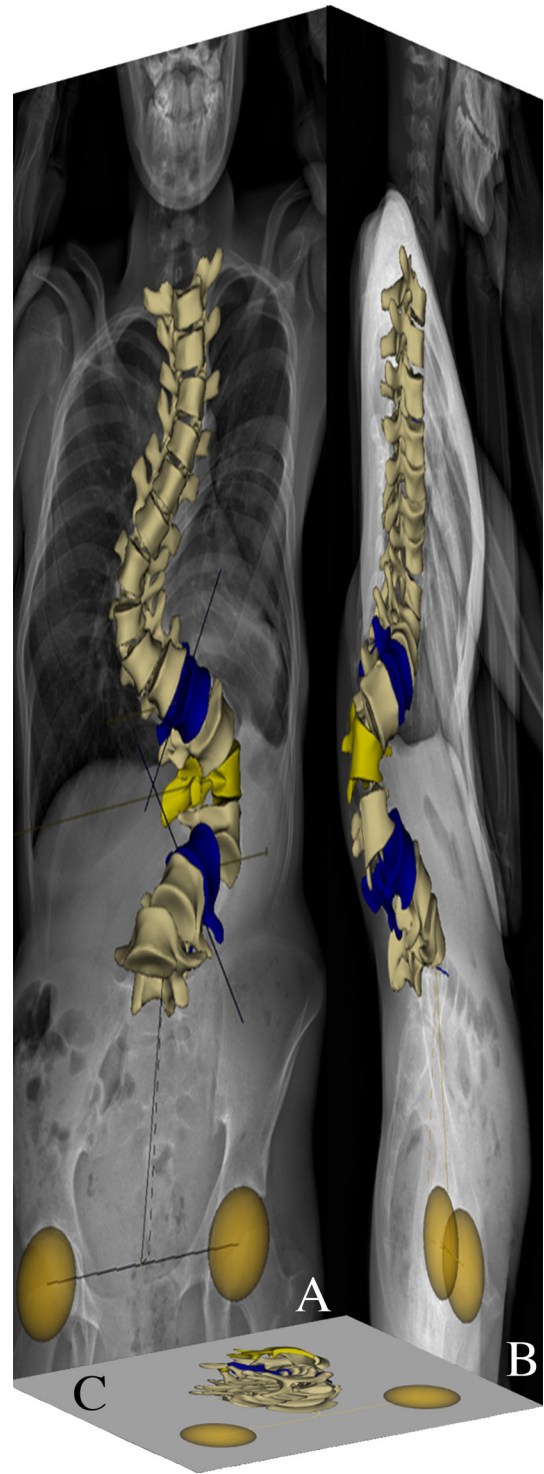


Fig. 8. 2D/3D EOS images in a patient with severe scoliosis. 3D reconstruction on the postero-anterior (A) and lateral (B) radiograph. 3D top view (C).

offered by the da Vinci representation has failed to facilitate the comprehension or the use of these techniques [38].

As stated by Stokes and the 3D Terminology of Spinal Deformity Working Group of the SRS, PMC visualisation provides, not a true 3D image, but only a quasi-3D image [13]. When studies of true 3D projections are feasible, mandating the use of non-real accessory planes (the PMC) is open to criticism.

5. 3D EOS imaging

An application of the 2D/3D stereoradiography EOS imaging technique (EOS Imaging, Paris, France) initiated by the senior author of this article (JD) has radically changed our ability to obtain 3D images of scoliosis [39]. EOS is a low-dose X-ray imaging method based on the gaseous particle detector technology that earned G Charpak the Nobel Prize in physics in 1992 [40,41]. EOS imaging has been developed for use in orthopaedics. The 2D/3D EOS machine simultaneously captures digital images of the standing patient in two perpendicular planes after digitisation of a whole-body scan [42]. The PA and lateral radiographs created by the EOS system are life-sized and free of distortion. They are used by dedicated software (sterEOS) to obtain an accurate 3D reconstruction of the surface of the vertebrae and spine (Fig. 8) [43,44]. Once the 3D reconstruction has been obtained, the projection of the spine in the three planes, including the axial plane, can be visualised.

In addition to the 3D reconstruction, 3D parameters are generated automatically by the vertebrae, pelvis, and spine. As is the case with conventional biomechanics, the sterEOS software determines the 3D angular positions of the vertebrae by computing the three angles using a sequence of rotations of mobile axes (cardanic or Bryant angles) [45]. Although this is a precise mathematical definition, the clinical meaning and relevance of the rotation values thus obtained are doubtful, as there is no international consensus about the vertebral coordinate systems or the order of the rotations

in the sequence. When using the axis displacement method, the computed value of the three angles depends on the order of the rotations. If the coordinate system is altered, the order of the rotations does not necessarily represent the same anatomical order. Consequently, the rotation values will differ and will not be comparable [45]. Another mistake often made by orthopaedic surgeons when using 3D Bryant angles for clinical purposes is designation of these angles as the coronal, sagittal, and axial angles, thus confusing the 3D Bryant angles with the angles projected on the three anatomical planes of reference. This semantic drift is misleading, because the 3D Tait-Bryan angle corresponds to the three angles projected onto a single plane. In clinical practice, only the angles projected onto the anatomical planes of reference, eg., corresponding to the angles visible on the PA and lateral radiographs, have clinical significance and are used by orthopaedic surgeons.

6. Vertebral vectors

The PA vertebral vector is a novel visualisation concept that was introduced to overcome the above-described problems; simplify 3D projection display in the coronal, sagittal, and axial planes; and allow mathematical characterisation of projected curves (Fig. 9) [46]. Generally speaking, a vector is a mathematical entity characterised by its starting and end points, its length, and its direction in space. A vector is usually represented by a line segment with an

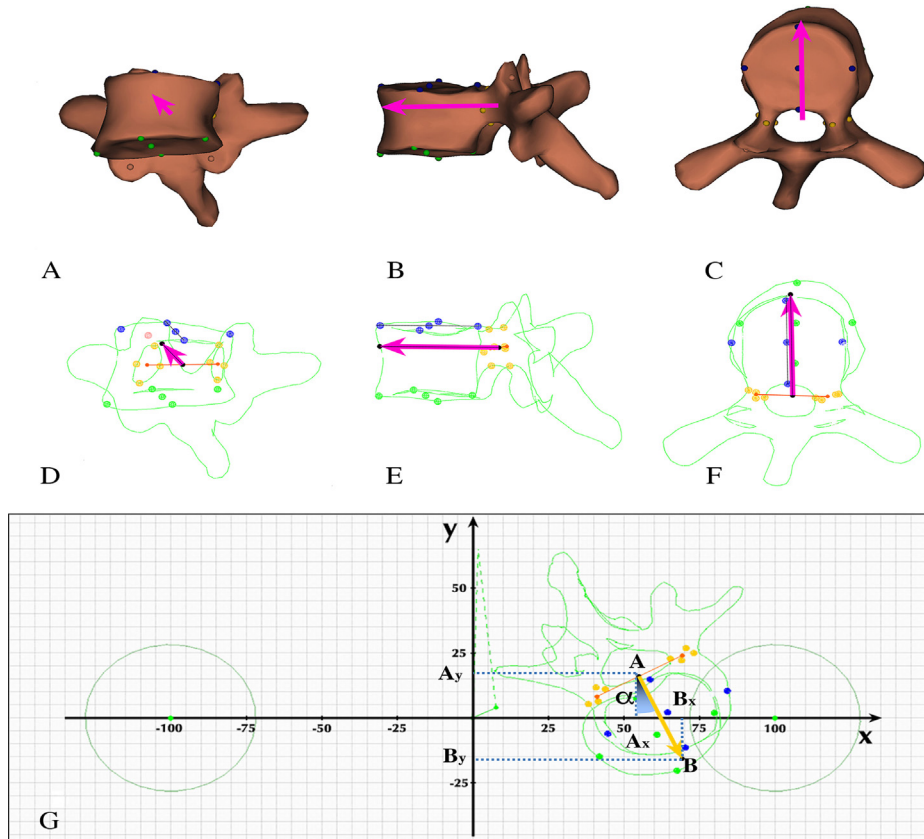


Fig. 9. Determination of the vertebral vector and coordinate system [45]. A, B, and C. Surface 3D reconstructions of the vertebrae in the coronal (A), sagittal (B), and axial (C) planes with the position of the vertebral vector (magenta arrow). D, E, and F. Coronal (D), sagittal (E), and axial (F) views of the vertebral contours; coloured reference points for the vertebral landmarks. G. Coordinate system in the axial plane with a vertebra (in contour mode) and its vector. The coordinates of each vectorial point can be determined using basic vectorial algebra. The coordinates of \vec{AB} are $(A_x; A_y)$ for the starting point A and $(B_x; B_y)$ for the end point B. Consequently, the coordinates are as follows: $\vec{AB}(B_x - A_x; B_y - A_y)$. The projected length (d) of \vec{AB} in the axial plane is as follows: $(@d)_i[\vec{AB}] \rightarrow \sqrt{((A_1y - B_1y)^2 + (A_1x - B_1x)^2)}$ Axial rotation (the vectorial angle-relative to the Y axis) is computed using the tangent function: $tga = \frac{(B_x - A_x)}{(B_y - A_y)}$.

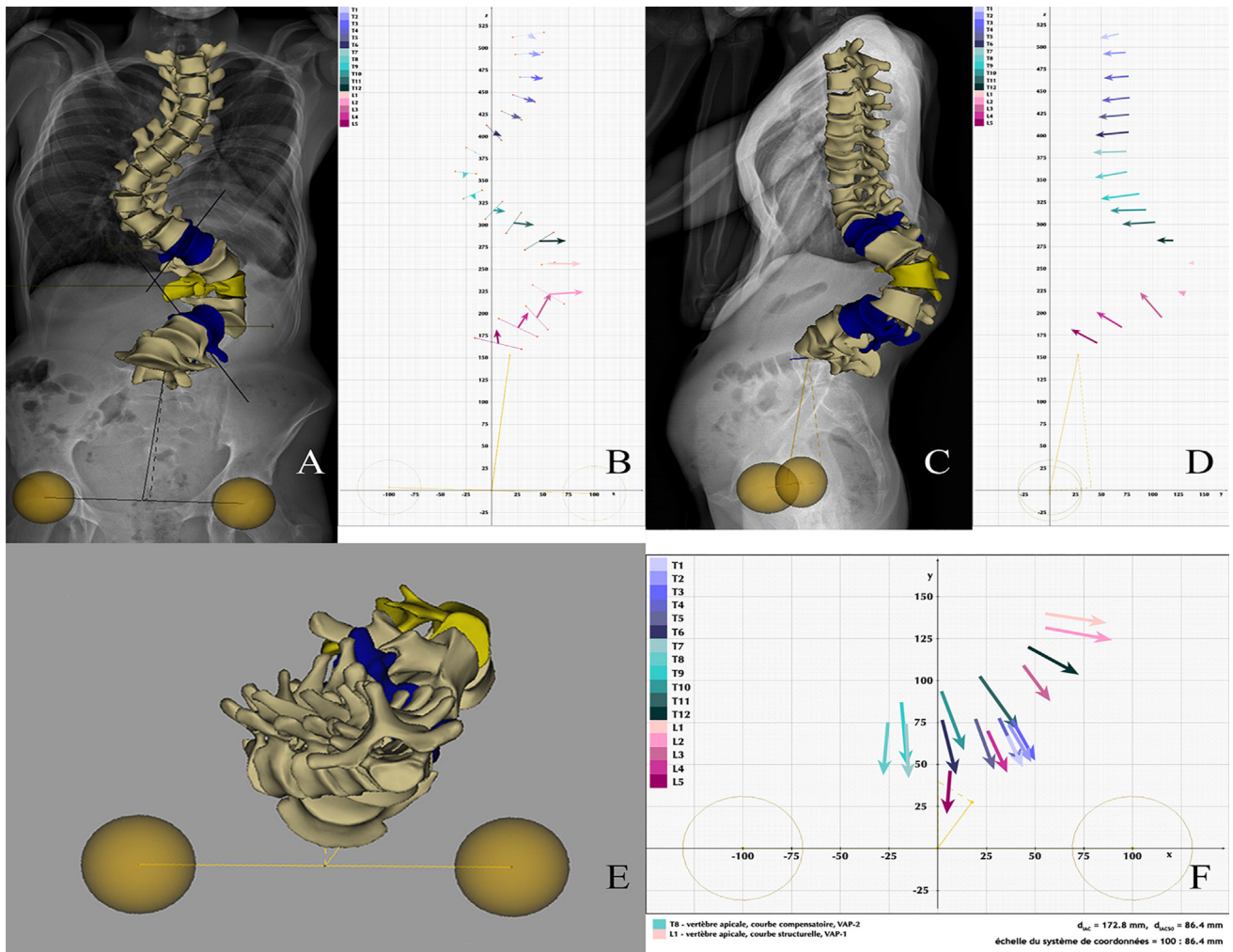


Fig. 10. 2D/3D EOS and the use of vertebral vectors to visualise severe scoliosis. A. 3D reconstruction on a postero-anterior radiograph. B. The vertebrae have been replaced by their vertebral vectors. With vertebral vector visualisation in the coronal plane, only the small arrows representing the terminal parts of the vectors are visible for the vertebrae that have no axial rotation (T7 and T8). With increasing vertebral rotation, the projection of the vectors becomes more visible, until the arrows seem to represent the full length of the vectors, indicating nearly 90° of rotation (L1 and L2). Decomensation of the upper part of the body can also be determined from the distance between T1 and the Z axis. The magnitude of the coronal curve is directly proportional to the X axis coordinates of the vertebral vector. C and D. Lateral radiograph with 3D reconstruction (C) and visualisation using vertebral vectors (D). In the sagittal plane, most of the vectors are visible along their full length, clearly delineating the sagittal spinal curves. As axial rotation increases, the projected vector lengths decrease continuously; when rotation reaches 90°, only the arrowheads are visible (L1 and L2). E and F. 3D reconstruction in the axial plane (E) and visualisation of the vertebral vector (F). In the axial plane, vertebral rotation does not affect the projected length of the vectors. Thus, the angle related to the Y axis shows the projected axial vertebral rotations. The X axis coordinates measured in the axial plane are directly proportional to the amount of lateral vertebral translation [42].

arrowhead to indicate its direction. The starting point of a vertebral vector (A) is the midpoint of the line connecting the two pedicular centroids and the end point (B) is located on the anterior surface of the vertebral body. By definition, the vertebral vector represents the PA axis of the vertebra and is parallel to the upper vertebral endplate. Thus, the length of the vector is proportional to the size of the vertebral body. By definition, the vertebral vector \vec{AB} replaces the real vertebra while preserving crucial information about its size, position, and 3D orientation [47].

The vertebral vectors representing the entire spine can be displayed within an individually calibrated system of coordinates that provides simple and well-established mathematical methods for quantitatively evaluating the 3D geometry of the spine (Fig. 9G). In this system of coordinates, the X axis is a line connecting the centres of the right and left acetabular cavities. The Y axis is perpendicular to the X axis in the coronal plane, travels through the midpoint of the inter-acetabular line, and is located within the median sagittal plane of the body. Finally, the Z axis travels through the same

point and is perpendicular to the X and Y axes. The scale of the coordinate system depends on each individual, as it is based on the actual distance between the two acetabular centroids. Dividing the distance between the two acetabular centroids into 200 equal segments produces a specific scale that allows comparisons, as there are always 100 units between the origin of the coordinate system and the acetabular centroid on either side. The units thus obtained serve as the basic units for each of the three axes in the coordinate system. Within this system and in each of the three planes, the projected coordinates of the \vec{AB} vector starting point (Ax; y; z;) and end point (Bx; y; z;) can be determined.

The different coordinates in the three planes have different meanings (Fig. 10A-D). In the axial plane, the x coordinates represent the distance from the Y axis, the y coordinates represent the distance from the X axis, and the direction of the vector represents the projected axial rotation of the vertebra. The value of the projected vertebral rotation can be computed based on the x and y coordinates of the vertebral vector starting and end points, by

using the trigonometric tangent function. Inter-vertebral rotation can also be computed, as the difference in axial rotation between the two adjacent vertebrae. In addition to vertebral rotation, lateral vertebral translation and sagittal curve projections can be assessed using this coordinate system (Fig. 10E-F) [48].

Vertebral vector display has considerably simplified the simultaneous representation of spinal deformities in all three planes. Vertebral vectors have already been proven relevant in the coronal and sagittal planes for both the normal and the scoliotic spine [49,50].

7. Conclusion

Vertebral vectors improve axial plane visualisation and axial rotation measurement. In clinical practice, vertebral vectors are a useful adjunct to current reference standard procedures for measuring the coronal and sagittal curves. Although the vertebral vector method uses projected images, surgeons have been using projections since the introduction of radiography and therefore have extensive experience with this technique. The use of projected images is unavoidable, although an extensive and accurate 3D display can also be achieved. An excellent analogy is with architectural design: even when highly accurate 3D visualisation is obtained, buildings are constructed based on their projections in the three planes. A building cannot be constructed solely on the basis of a 3D computer-generated image. The same is true of scoliosis: the projections in the three planes must be available. Images in two planes are not sufficient, since scoliosis is a 3D deformity.

The PA vertebral vector method allows surgeons to evaluate the third dimension of the scoliotic deformity without having to apply other virtual planes. This simple user-friendly graphic visualisation method considerably facilitates comprehension of the 3D nature of scoliosis and helps to monitor the effects of non-operative [51] and surgical [52] treatments. The information provided is sufficient to allow a visual evaluation and to supply significant clinical information in all three anatomical planes. In addition, the vertebral vector visualisation approach is a reasonable compromise between mathematical doctrine and practical implementation.

Disclosure of interest

J.F.D. Occasional consultant for Medtronic.

The other authors declare that they have no competing interest.

Funding

None.

Contributions

T.S.I.: Conceived and designed the work, drafted the manuscript.

F.L. Revised the article critically for important intellectual content.

J.F.D. Revised the article critically and gave final approval of the version to be published.

References

- [1] Magny M. Mémoire sur le Rakitis ou Maladie de la Colonne vertébrale. Paris: Chez Méquignon l'aîné, Libraire, rue des Cordeliers, vis-à-vis l'Eglise de Saint-Côme; 1780.
- [2] Adams W. Lectures pathology and treatment lateral and other forms curvature of the spine. 2nd ed London: J& A. Churchill New Burlington street; 1882.
- [3] Röntgen W. On a new kind of rays. Nature 1896;53:274–326.
- [4] Cobb JR. Outline for the study of scoliosis. The American Academy of Orthopedic Surgeons. Instructional Course Lectures. Ann Arbor: JW. Edwards, 5; 1948. p. 261–75.
- [5] Diebo BG, Varghese JJ, Lafage R, Schwab FJ, Lafage V. Sagittal alignment of the spine: What do you need to know? Clin Neurol Neurosurg 2015;139:295–301.
- [6] Roussouly P, Nnadi C. Sagittal plane deformity: an overview of interpretation and management. Eur Spine J 2010;19:1824–36.
- [7] Lenke LG, Betz RR, Harms J, et al. Adolescent idiopathic scoliosis: a new classification to determine extent of spinal arthrodesis. J Bone Joint Surg Am 2001;83-A:1169–81.
- [8] Graf H, Hecquet J, ubousset DJ. 3-dimensional approach to spinal deformities. Application to the study of the prognosis of pediatric scoliosis. Rev Chir Orthop 1983;69:407–16 [in French].
- [9] Cottrel Y, Dubousset J. Nouvelle technique d'ostéosynthèse rachidienne segmentaire par voie postérieure. Rev Chir Orthop 1984;70:489–94.
- [10] Dubousset J, Herring JA, Shuffelbarger H. The Crankshaft Phenomenon. J Pediatr Orthop 1989;9:541–50.
- [11] de Jonge T, Dubousset JF, Illés T. Hyperrotatory paradoxical kyphosis. Spine 2002;27:393–8.
- [12] Cottrel Y, Dubousset J, Guillaumat M. New universal instrumentation in spinal surgery. Clin Orthop Relat Res 1988;227:10–23.
- [13] Stokes IA. Three-dimensional terminology of spinal deformity. A report presented to the Scoliosis Research Society by the Scoliosis Research Society Working Group on 3-D terminology of spinal deformity. Spine 1994;19:236–48.
- [14] Aaro S, Dahlborn M. Estimation of vertebral rotation and the spinal and rib cage deformity in scoliosis by computer tomography. Spine 1981;6:460–7.
- [15] Ho E, Upadhyay S, Chan F, Hsu L, Leong J. New methods of measuring vertebral rotation from computed tomographic scans: an intraobserver and interobserver study on girls with scoliosis. Spine 1993;18:1173–7.
- [16] Krismer M, Sterzinger W, Christian H, Frischhut B, Bauer R. Axial rotation measurement of scoliotic vertebrae by means of computed tomography scans. Spine 1996;21:576–81.
- [17] Vrtovec T, Likar B, Pernus F. Automated curved planar reformation of 3D spine images. Phys Med Biol 2005;50:4527–40.
- [18] Birchall D, Hughes D, Hindle J, Robinson L, Williamson J. Measurement of vertebral rotation in adolescent idiopathic scoliosis using three-dimensional magnetic resonance imaging. Spine 1997;22:2403–7.
- [19] Vrtovec T, Ourselin S, Lavier G, Likar B, Pernus F. Automated generation of curved planar reformations from MR images of the spine. Phys Med Biol 2007;52:2865–78.
- [20] Yazici M, Acaroglu ER, Alanay A, Deviren V, Cila A, Surat A. Measurement of vertebral rotation in standing versus supine position in adolescent idiopathic scoliosis. J Pediatr Orthop 2001;21:252–6.
- [21] Vrtovec T, Franjo Pernus F, Likar B. A review of methods for quantitative evaluation of axial vertebral rotation. Eur Spine J 2009;18:1079–90.
- [22] Nash Jr CL, Moe JH. A study of vertebral rotation. J Bone Joint Surg Am 1969;51-A:223–9.
- [23] Stokes IA, Bigalow LC, Moreland MS. Measurement of axial rotation of vertebrae in scoliosis. Spine 1986;11:213–8.
- [24] Perdriolle R, Vidal J. A study of scoliotic curve. The importance of extension and vertebral rotation [in French]. Rev Chir Orthop Reparatrice Appar Mot 1981;67:25–34.
- [25] Omeroglu H, Ozekin O, Bicimoglu A. Measurement of vertebral rotation in idiopathic scoliosis using the Perdriolle torsionmeter: a clinical study on intraobserver and interobserver error. Eur Spine J 1996;5:167–71.
- [26] Pearcy M, Tibrewal S. Axial rotation and lateral bending in the normal lumbar spine measured by three-dimensional radiography. Spine 1984;9:582–7.
- [27] Labelle H, Dansereau J, Bellefleur C, Jéquier J. Variability of geometric measurements from three-dimensional reconstructions of scoliotic spines and rib cages. Eur Spine J 1995;4:88–94.
- [28] Gille O, Champain N, Benchikh-El-Fegoun A, Vital JM, Skalli W. Reliability of 3D reconstruction of the spine of mild scoliotic patients. Spine 2007;32:568–73.
- [29] Chi WM, Cheng CW, Yeh WC, et al. Vertebral axial rotation measurement method. Comput Methods Programs Biomed 2006;81:8–17.
- [30] Eijgcraam SM, Boselie TF, Sieben JM, et al. Development and assessment of a digital x-ray software tool to determine vertebral rotation in adolescent idiopathic scoliosis. Spine J 2017;17:260–5.
- [31] Hecquet J, Legaye J, Duval-Beaupère G. Access to a three-dimensional measure of vertebral axial rotation. Eur Spine J 1998;7:206–11.
- [32] Pinheiro AP, Tanure MC, Oliveira AS. Validity and reliability of a computer method to estimate vertebral axial rotation from digital radiographs. Eur Spine J 2010;19:415–20.
- [33] Sullivan TB, Bastrom T, Reighard J, Jeffords M, Newton PO. A novel method for estimating three-dimensional apical vertebral rotation using two-dimensional coronal Cobb angle and thoracic kyphosis. Spine Deformity 2017;5:244–9.
- [34] Aubin C-E, Lobeau D, Labelle H, Maquinghen-Godillon AP, LeBlanc R, Dansereau J. Planes of maximum deformity in the scoliotic spine. In: IAF Stokes (ed) Research into spinal deformities 2. Amsterdam: IOS Press; 1999. p. 45–8.
- [35] Stagnara P, Queneau P. Scolioses évolutives en période de croissance: aspects cliniques, radiologiques, propositions thérapeutiques. Rev Chir Orthop 1953;39:378–449.
- [36] Labelle H, Aubin C-E, Jackson R, Lenke L, Newton P, Parent S. Seeing the spine in 3D: How will it change what we do? J Pediatr Orthop 2011;31:S37–45.
- [37] Villemure I, Aubin C-E, Grimard G, Dansereau J, Labelle H. Progression of vertebral and spinal three-dimensional deformities in adolescent idiopathic scoliosis: A longitudinal study. Spine 2001;26:2244–50.
- [38] Sangole AP, Aubin CE, Labelle H, Stokes IA, Lenke LG, Jackson R, Newton P. Three-dimensional classification of thoracic scoliotic curves. Spine 2009;34:91–9.

- [39] Dubousset J, Charpak G, Dorion I, et al. Le system EOS. Nouvelle imagerie osteo-articulaire basse dose en position debout. E-memoire Acad Nat Chir 2005;4:22-7.
- [40] Kalifa G, Charpak G, Maccia C, et al. Evaluation of a new low-dose digital x-ray device: first dosimetric and clinical result in children. *Pediatr Radiol* 1998;28:557-61.
- [41] <http://nobelprize.org/nobel.prizes/physics/laureates/1992/index.html>.
- [42] Dubousset J, Charpak G, Dorion I, et al. A new 2D and 3D imaging approach to musculoskeletal physiology and pathology with low-dose radiation and the standing position: the EOS system. *Bull Acad Natl Med* 2005;189:287-97.
- [43] Mitulescu A, Skalli W, Mitton D, De Guise J. Three-dimensional surface rendering reconstruction of scoliotic vertebrae using a non stereo-corresponding points technique *Eur Spine J* 2002;11:344-52.
- [44] Le Bras A, Laporte S, Mitton D, de Guise JA, Skalli W. 3 D detailed reconstruction of vertebrae with low dose digital stereoradiography. *Stud Health Technol Inform* 2002;91:286-90.
- [45] Skalli W, Lavaste F, Descrimes JL. Quantification of three-dimensional vertebral rotations in scoliosis: what are the true values? *Spine* 1995;20:546-53.
- [46] Illés T, Tunyogi-Csapó M, Somoskeőy Sz. Breakthrough in three-dimensional scoliosis diagnosis—significance of horizontal plane view and vertebra vectors. *Eur Spine J* 2011;20:135-43.
- [47] Illés T. Comparaison entre la mesure classique bidimensionnelle de la scoliose et sa mesure tridimensionnelle par les vecteurs vertébraux. Avantages dans le pronostic et l'appréciation des résultats. *Bull Acad Nat Medecine* 2011;195:629-43.
- [48] Illés TS, Burkus M, Somoskeőy S, Lauer F, Lavaste F, Dubousset JF. The horizontal plane appearances of scoliosis: what information can be obtained from top-view images? *Int Orthop* 2017;41:2303-11.
- [49] Somoskeőy S, Tunyogi-Csapó M, Bogyó C, Illés T. Clinical validation of coronal and sagittal spinal curve measurements based on three-dimensional vertebra vector parameters. *Spine J* 2012;12:960-8.
- [50] Illés T, Somoskeőy S. Comparison of scoliosis measurements based on three-dimensional vertebra vectors and conventional two-dimensional measurements: advantages in evaluation of prognosis and surgical results. *Eur Spine J* 2013;22:1255-63.
- [51] Ilharborde B, Sbag G, Skalli W, Mazda K. Adolescent idiopathic scoliosis treated with posteromedial translation: radiologic evaluation with a 3D low-dose system. *Eur Spine J* 2013;22:2382-91.
- [52] de Mauroy JC, Journe A, Gagaliano F, Lecante C, Barral F, Pourret S. The new Lyon ARTbrace versus the historical Lyon brace: a prospective case series of 148 consecutive scoliosis with short time results after 1 year compared with a historical retrospective case series of 100 consecutive scoliosis; SOSORT award 2015 winner. *Scoliosis* 2015;10:26, <http://dx.doi.org/10.1186/s13013-015-0047-6>.