



Science Arts & Métiers (SAM)

is an open access repository that collects the work of Arts et Métiers Institute of Technology researchers and makes it freely available over the web where possible.

This is an author-deposited version published in: <https://sam.ensam.eu>
Handle ID: <http://hdl.handle.net/10985/18318>

To cite this version :

François GIRINON, Serge KETOFF, Quentin HENNOCQ, Nicolas KOGANE, Nicolas ULLMANN, Natacha KADLUB, Eva GALLIANI, Cécilia NEIVA-VAZ, Marie-Paule VASQUEZ, Arnaud PICARD, Roman Hossein KHONSARI - Maxillary shape after primary cleft closure and before alveolar bone graft in two different management protocols: A comparative morphometric study - Journal of Stomatology, Oral and Maxillofacial Surgery - Vol. 120, n°5, p.406-409 - 2019

Any correspondence concerning this service should be sent to the repository

Administrator : scienceouverte@ensam.eu



Maxillary shape after primary cleft closure and before alveolar bone graft in two different management protocols: A comparative morphometric study

F. Girinon^a, S. Ketoff^{a,b}, Q. Hennocq^b, N. Kogane^b, N. Ullman^b, N. Kadlub^b, E. Galliani^b, C. Neiva-Vaz^b, M.P. Vazquez^b, A. Picard^b, R.H. Khonsari^{b,*}

^a Arts et métiers ParisTech, LBM, Paris, France

^b Assistance publique Hôpitaux de Paris, Hôpital Universitaire Necker - Enfants Malades, Service de Chirurgie Maxillofaciale et Chirurgie Plastique, Centre de Référence des Malformations de la Face et de la Cavité Buccale (MAFACE), Filière Maladies Rares TêteCou, Université Paris Descartes, Université Sorbonne Paris Cité, Paris, France

ABSTRACT

Aim and scope: Result assessment in cleft surgery is a technical challenge and requires the development of dedicated morphometric tools. Two cohorts of patients managed according to two different protocols were assessed at similar ages and their palatal shape was compared using geometric morphometrics.

Material and methods: Ten patients (protocol No. 1) benefited from early lip closure (1–3 months) and secondary combined soft and hard palate closure (6–9 months); 11 patients (protocol No. 2) benefited from later combined lip and soft palate closure (6 months) followed by hard palate closure (18 months). Cone-Beam Computed Tomography (CBCT) images were acquired at 5 years of age and palatal shapes were compared between protocols No. 1 and No. 2 using geometric morphometrics.

Results: Protocols No. 1 and No. 2 had a significantly different timing in their surgical steps but were assessed at a similar age (5 years). The inter-canine distance was significantly narrower in protocol No. 1. Geometric morphometrics showed that the premaxillary region was located more inferiorly in protocol No. 1.

Conclusion: Functional approaches to cleft surgery (protocol No. 2) allow obtaining larger inter-canine distances and more anatomical premaxillary positions at 5 years of age when compared to protocols involving early lip closure (protocol No. 1). This is the first study comparing the intermediate results of two cleft management protocols using 3D CBCT data and geometric morphometrics. Similar assessments at the end of puberty are required in order to compare the long-term benefits of functional protocols.

Keywords:

Cleft lip and palate
Geometric morphometrics
Cone-Beam
Maxillary growth
Functional protocol

1. Introduction

The scientific assessment of management protocols for cleft lip and palate raises numerous methodological issues. These protocols cover long periods of time – from birth to the end of pubertal growth – and many controllable and non-controllable factors influence the surgical outcomes, such as, among many others, the choice of the surgical techniques, the timing of the different procedures, the skills of the various surgeons involved, details in

the post-operative care, the quality of the orthodontic management and speech therapy techniques [1–3].

The maxillofacial and plastic surgery department at Necker - Enfants Malades University Hospital is a very active national cleft center managing 200 new primary cases every year. In 2012, the department changed its surgical team and management protocol for children with cleft lip and palate. Until 2012, protocol No. 1 involved an early closure of the lip at the age of 1–3 months followed by a combined closure of the soft and hard palate at the age of 6–9 months. Bone graft for alveolar cleft reconstruction was not part of protocol No. 1. From 2012, protocol No. 2 was applied: the soft palate and the lip were closed at 6 months of age, the hard palate was closed at 18 months of age and the alveolar bone graft was performed between ages 4 and 6, using an iliac donor site. Alveolar cleft reconstruction was preceded by the placement of an

* Corresponding author at: Service de Chirurgie Maxillofaciale et Chirurgie Plastique, Hôpital Universitaire Necker-Enfants Malades, 149, rue de Sèvres, 75015 Paris, France.

E-mail address: roman.khonsari@aphp.fr (R.H. Khonsari).

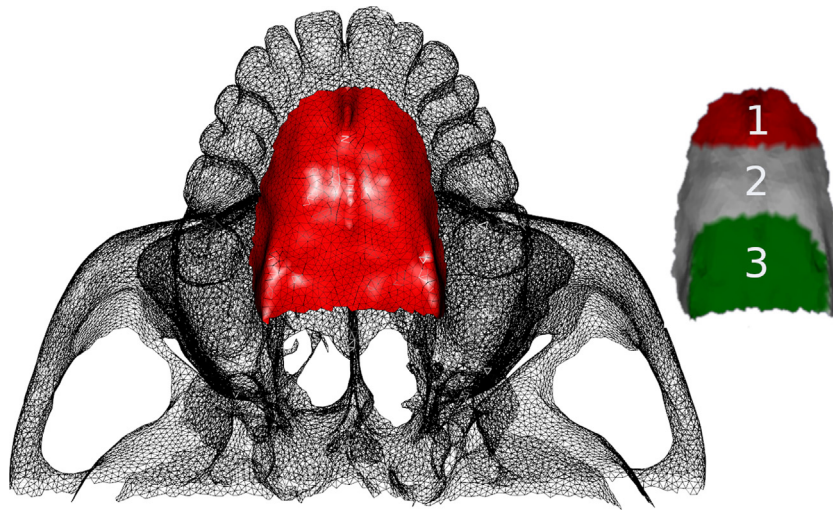


Fig. 1. Definition of the total region of interest on the surface of the palate (in red), and of the three different zones used in the morphometric analyses: (1) palatal tip (red), (2) median palatal region (white) and (3) posterior palate (green).

intra-oral orthopedic expansion device (Quad-Helix) and the graft was performed when the inter-canine distance was over 32 mm, before the eruption of the permanent incisors and canines [3].

In order to compare the outcome of cleft lip and palate closure between protocols No. 1 and No. 2, we retrospectively included the last series of patients initially managed according to protocol No. 1 and included into protocol No. 2 at the age of 4 (in 2012), when eligible for alveolar cleft reconstruction. We compared the 3D structure of their maxilla based on Cone-Beam Computed Tomography (CBCT) images with a series of patients fully managed according to protocol No. 2 since birth. Using morphometric geometrics [4,5], we assessed the differences in maxillary structures between the two groups.

2. Material and methods

We included 10 patients managed according to protocol No. 1 and included into protocol No. 2 at 4 years of age (group No. 1), and 11 patients initially managed according to protocol No. 2 (group No. 2), without agenesis of the lateral incisors. We considered CBCTs performed before orthopedic maxillary expansion. We recorded the following parameters: age at primary surgery, age at secondary surgery, age at CBCT and inter-canine distance (measured on 3D reconstructions obtained from the CBCTs).

We defined three anatomical regions on the surface of the palate:

1. palatal tip (in red), extending to a horizontal line distal to the canines;
2. median palatal region (in white), covering the rest of the hard palate down to the maxillo-palatine sutures and;
3. posterior palate (in green), covering the surface between the maxillo-palatine sutures and the posterior choana (Fig. 1).

Table 1

Clinical characteristics of groups No. 1 and No. 2.

	Sex ratio (m/f)	Cleft side (L/R)	Mean age at CBCT (y)	Age at primary surgery (mo)	Age at secondary surgery (mo)
Group No. 1	7/3	8/2	5.95 ± 1.01	1.92 ± 0.9	8.4 ± 1.22
Group No. 2	7/4	10/1	5.09 ± 0.97	5.09 ± 1.16	15.64 ± 4.59

m: male; f: female; L: left; R: right; CBCT: cone-beam computer tomography; y: years; mo: months.

A palatal plane was computed in order to fit the palatal surface using the least-square method. The z-axis was defined as normal to this palatal plane. The barycentre of the palatal tip was computed and projected on the palatal plane. The barycentre of the posterior palate was computed and similarly projected on the palatal plane. The x-axis was defined using these two projections. The displacement vectors between the two groups were projected into these axes. We considered the first 5 principal components, accounting for 80% of the variance, after having tested the multi-normality of the dataset using a Henze-Zirkler test from the MVN package [6] in R (R Development Core Team (2008). R: a language and environment for statistical computing. R Foundation for Statistical Computing, Vienna, Austria. ISBN 3-900051-07-0, URL <http://www.R-project.org>). A multivariate analysis of variance (MANOVA test) for each individual in the space of the first 5 principal components was performed.

3. Results

Group No. 1 consisted in 7 boys (6 left-sided clefts and 1 right sided cleft) and 3 girls (2 left-sided clefts and 1 right sided cleft). Group No. 2 consisted in 7 boys (6 left-sided clefts and 1 right sided cleft) and 4 girls with left-sided clefts. The mean ages at CBCT were not different between the two groups: 5.95 ± 1.01 years for group No. 1 and 5.09 ± 0.97 for group No. 2 ($P = 0.06$). The ages at primary surgery were different between the two groups: 1.92 ± 0.96 months for group No. 1 and 5.09 ± 1.16 months for group No. 2 ($P < 0.001$). The ages at secondary surgery were also different between the two groups: 8.4 ± 1.22 months for group No. 1 and 15.64 ± 4.59 months for group No. 2 ($P < 0.001$) (Table 1). The inter-canine distance for group No. 1 was 2.56 ± 0.32, and was significantly shorter than the inter-canine distance for group No. 2, which was 2.90 ± 0.28 ($P = 0.026$).

Table 2
Displacements between groups No. 1 and No. 2 (in centimeters).

	Whole palate			Palatal tip			Posterior palate		
	x	y	z	x	y	z	x	y	z
Mean displacement	-0.25	-0.03	0.09	-0.36	-0.13	1.03	-0.14	-0.05	-0.22
Minimal absolute displacement	0	0	0	0	0	0	0	0	0
Maximal absolute displacement	1.01	0.82	1.73	0.73	0.74	1.73	0.5	0.77	0.65
Mean of the displacement norm \pm standard deviation	0.56 \pm 0.34			1.15 \pm 0.29			0.40 \pm 0.18		

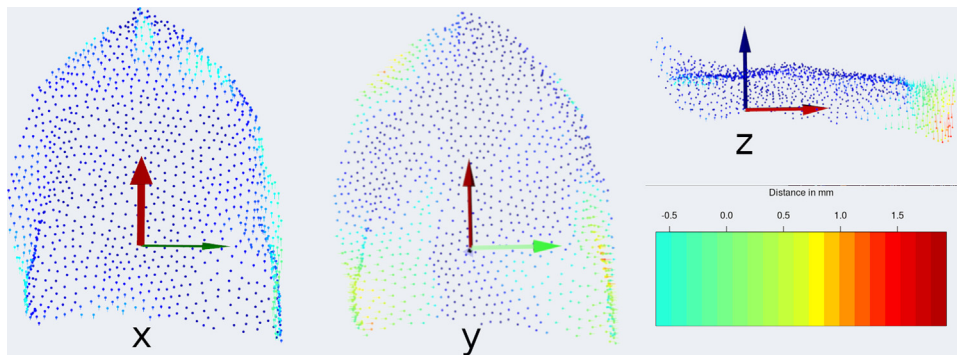


Fig. 2. Displacements between groups No. 1 and No. 2 according to the x -, y - and z -axes, showing that the differences in shape predominated at the tip of the palate, in the premaxillary region. For each displaced point, the round end represented group No. 2: the significant downward displacement of the palatal tip in group No. 2 was thus figured by a positive (in red and yellow color codes) downward shift of the round ends of each individual displacement along the z -axis. Protocol No. 2 furthermore induced a trend for posterior transversal narrowing (y -axis, not significant); the sagittal dimension (x -axis) was not significantly affected at 5 years of age.

Distances between palatal surfaces from groups No. 1 and No. 2 were computed for the whole palate, the palatal tip and the posterior palate (Table 2). The MANOVA test in the space of the first 5 principal components showed that the 2 groups were significantly different for the position of the palatal tip, while the rest of the palatal surface was superimposable (Table 3). Graphical rendering of these results showed that the different between groups No. 1 and No. 2 was predominantly located in the tip of the hard palate, in the premaxillary region.

4. Discussion

Various morphometric methods have been used to assess cleft anatomy [7–13] and the outcomes of cleft repair [14,15], based on 2D radiographic data [7,8], 3D radiographic data [9,10] and digitized dental casts [11,15]. Our study is nevertheless the first, to our knowledge, to use 3D CBCT data in order to compare the outcomes of two different management protocols based on geometric morphometrics.

Protocol No. 1 involved early lip closure (at 1.92 ± 0.96 months) and secondary combined soft and hard palate closure (at 8.4 ± 1.22 months); protocol No. 2 was based on functional considerations [3,16,17,18] and favored later lip closure associated with soft palate closure using intra-velar veloplasty (at 5.09 ± 1.16 months) followed by hard palate closure (at 15.64 ± 4.59 months). Protocol No. 2 allowed minimizing palatal scars and could potentially favor transversal and sagittal palatal growth [3,19,20]. Here, we showed that the inter-canine distance at 5 years of age was significantly smaller in protocol No. 1, thus suggesting that the functional approach to cleft surgery could favor transversal maxillary growth [20]. This transversal effect was nevertheless not confirmed by geometric morphometrics (Table 3 and Fig. 2) and most probably requires assessments beyond 5 years of age. Interestingly, we showed that, at 5 years of age, the main differences between the palatal shapes in protocols No. 1 and No. 2 were located at the palatal tip, in the premaxillary region. This finding was in line with previous results from the literature, which reported an inferior displacement of the premaxilla in cleft patients [12,13];

Table 3
MANOVA tests showing that the position of the palatal tip region is significantly different in groups No. 1 and No. 2 in the principal component space.

	<i>df</i>	<i>P</i>	<i>F</i>	<i>df1</i>	<i>df2</i>	<i>p</i>
Whole palate	1	0.29	2.09	5	26	0.09
Palatal tip	1	0.34	2.68	5	26	0.04
Posterior palate	1	0.09	0.52	5	26	0.75

Df: degree of freedom; P: Pillai's trace; F: Fisher F-test; df1, df2: degrees of freedom used in determining the F statistics; significant results in red.

based on these previously published results, we support the fact that functional protocol No. 2 allows obtaining a palatal shape closer to normal than protocol No. 1.

5. Conclusion

Comparing the results of two cleft management protocols as a whole is an impossible task. By considering discrete steps within these protocols, and by focusing on specific 3D objects and limited morphometric parameters (here: 3D palatal shape), we could demonstrate a significantly different palatal structure resulting from two approaches to cleft surgery:

- early lip closure;
- functional approach involving lip and soft palate closure at 6 months of age [3,19].

The causes of these differences cannot be deduced from our results; it is nevertheless generally hypothesized that lip surgery at 6 months of age allows a better anatomical reconstruction than in early surgery, and that a two-step palatal closure minimizes scarring [20]. These two factors most probably influence palatal growth, and more precisely premaxillary growth; interestingly, the premaxillary region is the only significantly modified region between protocols No. 1 and No. 2 according to our results. Our findings are obtained at an intermediate age. Longer follow-up assessments would provide more definitive arguments in favor of the use of a functional approach in cleft lip and palate management.

Disclosure of interest

The authors declare that they have no competing interest.

Acknowledgments

Thanks to Pr. Gérard Couly and Dr. Benoît Michel for sharing data from their patients.

References

- [1] Greives MR, Camison L, Losee JE. Evidence-based medicine: Unilateral cleft lip and nose repair. *Plast Reconstr Surg* 2014;134:1372–80.
- [2] Khonsari RH, Korolenkova MA, Ivanov AL. Treatment plans for cleft lip and palate in Russia. *Rev Stomatol Chir Maxillofac* 2012;113:191–6.

- [3] Talmant JC, Talmant JC, Lumineau JP. Primary treatment of cleft lip and palate. Its fundamental principles. *Ann Chir Plast Esthet* 2016;61:348–59.
- [4] Lele SR, Richtsmeier JT. An invariant approach to statistical analysis of shapes. In: Keidling N, Morgan B, van der Heijden P, editors. *Interdisciplinary Statistics Series*. Boca Raton, Florida, U.S.A.: Chapman & Hall/CRC; 2001. p. 308.
- [5] Zelditch ML, Swiderski DL, Sheets HD. *Geometric morphometrics for biologists: a primer* (2nd ed.). Amsterdam, Netherlands: Academic Press; 2012. p. 478.
- [6] Korkmarz S, Goksuluk D, Zararsiz G. MVN: a R package for assessing multivariate normality. *R J* 2014;6(2):151–62.
- [7] Ward RE, Moore ES, Hartsfield JK. Morphometric characteristics of subjects with oral facial clefts and their relatives. In: Wyszynski DE, editor. *Cleft lip and palate: from origin to treatment*. Hong-Kong: Oxford University Press; 2002. p. 66–86.
- [8] Kreiborg S, Hermann NV. Craniofacial morphology and growth in infants and young children with cleft lip and palate. In: Wyszynski DE, editor. *Cleft lip and palate: from origin to treatment*. Hong-Kong: Oxford University Press; 2002. p. 87–97.
- [9] Kane AA, DeLeon VB, Valeri C, Becker DB, Richtsmeier JT, Lo LJ. Preoperative osseous dys-morphology in unilateral complete cleft lip and palate: a quantitative analysis of computed tomography data. *Plast Reconstr Surg* 2007;119:1295–301.
- [10] Starbuck JM, Ghoneima A, Kula K. Bilateral cleft lip and palate: a morphometric analysis of facial skeletal form using cone beam computed tomography. *Clin Anat* 2015;28:584–92.
- [11] Smahel Z, Trefný P, Formánek P, Müllerová Z, Peterka M. Three-dimensional morphology of the palate in subjects with unilateral complete cleft lip and palate at the stage of permanent dentition. *Cleft Palate Craniofac J* 2004;41:416–23.
- [12] Bejdová Š, Krajíček V, Peterka M, Trefný P, Velemínská J. Variability in palatal shape and size in patients with bilateral complete cleft lip and palate assessed using dense surface model construction and 3D geometric morphometrics. *J Craniomaxillofac Surg* 2012;40:201–8.
- [13] Rusková H, Bejdová Š, Peterka M, Krajíček V, Velemínská J. 3-D shape of palatal surface in patients with unilateral complete cleft lip and palate. *J Craniomaxillofac Surg* 2014;42:140–7.
- [14] Hoffmanova E, Bejdová Š, Borský J, Dupej J, Caganova V, Velemínská J. Palatal growth in complete unilateral cleft lip and palate patients following neonatal cheiloplasty: classic and geometric morphometric assessment. *Int J Pediatr Otorhinolaryngol* 2016;90:71–6.
- [15] Hoffmanova E, Moslerová V, Dupej J, Borský J, Bejdová Š, Velemínská J. Three-dimensional development of the upper dental arch in unilateral cleft lip and palate patients after early neonatal cheiloplasty. *Int J Pediatr Otorhinolaryngol* 2018;109:1–6.
- [16] Hotz-Jenny M, Perko MA. Coordinated orthodontic and surgical treatment of cleft lip, jaw and palate. A contribution on the prevention of delayed adverse effects. *Schweiz Med Wochenschr* 1974;104:718–23.
- [17] Perko MA. Two-stage closure of cleft palate (progress report). *J Maxillofac Surg* 1979;7:46–80.
- [18] Peri G, Biehler G, Gamarra M, Dordain M, Gamarra A, el Sissy A, et al. The concept of global treatment of labiopalatine clefts before the age of orthodontics. *Orthod Fr* 1983;54:509–12.
- [19] Markus AF, Smith WP, Delaire J. Primary closure of cleft palate: a functional approach. *Br J Oral Maxillofac Surg* 1993;31:71–7.
- [20] Delaire J, Mercier J, Gordeeff A, Bedhet N. The 3 palatine fibromucous membranes. Their role in maxillary growth. Therapeutic role in surgery of the palatine shelves. *Rev Stomatol Chir Maxillo-fac* 1989;90:379–90.