



### Science Arts & Métiers (SAM)

is an open access repository that collects the work of Arts et Métiers Institute of Technology researchers and makes it freely available over the web where possible.

This is an author-deposited version published in: <https://sam.ensam.eu>  
Handle ID: <http://hdl.handle.net/10985/20227>

#### To cite this version :

O. BARBIER, Wafa SKALLI, L. MAINARD, D. MAINARD - The reliability of the anterior pelvic plane for computer navigated acetabular component placement during total hip arthroplasty: Prospective study with the EOS imaging system - Orthopaedics & Traumatology: Surgery & Research - Vol. 100, n°6, p.S287-S291 - 2014

Any correspondence concerning this service should be sent to the repository

Administrator : [scienceouverte@ensam.eu](mailto:scienceouverte@ensam.eu)



# The reliability of the anterior pelvic plane for computer navigated acetabular component placement during total hip arthroplasty: Prospective study with the EOS imaging system

O. Barbier<sup>a,b,c,\*</sup>, W. Skalli<sup>b</sup>, L. Mainard<sup>d</sup>, D. Mainard<sup>a</sup>,  
Computer Assisted Orthopedic Surgery–France (CAOS–France)

<sup>a</sup> Service de chirurgie orthopédique, hôpital central, 29, avenue de Lattre-de-Tassigny, 54000 Nancy, France

<sup>b</sup> Laboratoire de biomécanique, école nationale supérieure des arts et métiers Paris tech, boulevard de l'Hôpital, 75013 Paris, France

<sup>c</sup> Service de chirurgie orthopédique, hôpital d'instruction des Armées-Bégin, 69, avenue de Paris, 94160 Saint-Mandé, France

<sup>d</sup> Service de radiologie, hôpital Brabois, rue du Morvan, 54511 Vandœuvre-lès-Nancy, France

## A B S T R A C T

**Keywords:**  
Total hip arthroplasty  
EOS  
Navigation  
Anterior pelvic plane

**Introduction:** Computer navigated total hip arthroplasty is mostly based on the use of the anterior pelvic plane (APP) as a reference. EOS is a new imaging system that provides three-dimensional analysis of the pelvis in a functional position with a low dose of radiation. The aim of this study was to evaluate the reliability of the APP for placement of the cup during computer navigated THA using EOS.

**Hypothesis:** The reliability of the APP is limited for the placement of the acetabular cup during computer navigated THA.

**Materials and methods:** This was a prospective monocentric study using the EOS imaging system evaluating 44 patients in the standing position three months after computer navigated THA (Orthopilot™). Reproducibility of EOS measurements were analyzed using SterEOS software and the reliability of the navigation data for the position of the cup were assessed.

**Results:** Intra and interobserver reproducibility of the measurements of the orientation of the cup by EOS were good with correlation coefficients above 93% and 95% and confidence intervals of less than  $\pm 5^\circ$ . Mean cup inclination and anteversion were  $41.3^\circ$  and  $20.9^\circ$  and  $44.3^\circ$  and  $29.5^\circ$  respectively in operative and post-operatively. The differences between measurements of operative cup inclination using computer assisted navigation and the post-operative EOS measurements were significant ( $P < 0.05$ ) with a correlation coefficient of less than 40%.

**Discussion:** Our study confirms the lack of precision of the APP as a reference for positioning of the acetabular component, especially in relation to anteversion. Although for many years the APP was considered to be a global reference, in fact, it is subject to significant inter-individual variations and variations during changes in position. These factors, associated with the difficulty of determining the preoperative APP, explain the lack of reliability of this reference. Preoperative evaluation of the orientation of APP by EOS and its integration into the navigation system could help the operator position these components.

**Level of evidence:** Level III Prospective diagnostic case controlled study.

## 1. Introduction

The use of computer navigation optimises the position of the cup during total hip arthroplasty (THA) to improve biomechanics, reduce the risk of dislocation and early component wear. The anterior pelvic plane (APP), used as a plane of reference for navigation, is an anatomical reference that cannot be superimposed

on the vertical plane in clinical practice [1–6] and has significant inter-individual variations and variations, depending on the patient's position [5,6]. EOS is a recent imaging technique, based on the work of Georges Charpak, Nobel Prize in physics in 1992 [7,8], which provides a static and/or functional 3-D image of the skeleton. A reconstruction of the entire body in a functional position is obtained from two digital orthogonal 2-D images obtained simultaneously, with a low level of radiation [7–10]. Our hypothesis was that the reliability of the APP was limited for positioning the cup during computer navigated THA.

\* Corresponding author.

E-mail address: olive.barbier@gmail.com (O. Barbier).

The aims of this study were: (1) to validate the reproducibility of the EOS imaging system for measuring cup orientation and (2) to use the EOS system to analyze the reliability of the APP for operative cup placement.

## 2. Materials and methods

### 2.1. Patients

This was a prospective, non-randomized study of a cohort of patients who underwent computer assisted THA for primary hip arthritis during the 12-months inclusion period. Patients with a history of hip surgery or presenting with hip dysplasia were excluded. All patients were operated on by the same surgeon. The intervention was performed by a Hardinge-type mini-invasive anterolateral approach [1] in lateral decubitus position at 45°, with the Orthopilot™ (B Braun, Melsungen, Germany) navigation system. The APP was used as the plane of reference for navigation. A press-fit cup (Plasmacup™, B Braun, Melsungen, Germany) and a cementless straight stem (Excia™, B Braun, Melsungen, Germany) were used for each patient. The goal for acetabular component positioning during the intervention was 15° ± 10° anteversion and 40° ± 10° inclination. The final position of navigated cup placement was noted. All patients underwent the same post-operative rehabilitation protocol.

### 2.2. Method of assessment

All patients underwent follow-up by EOS imaging at 3 months post-operative. The protocol described by Lazennec et al. [6] and Chaibi et al. [10] was used: standing with the feet apart. Quality criteria described by Lazennec et al. [6] and Chaibi et al. [10] were used to validate the tests. Cup orientation measurements were obtained from clinically validated sterEOS (EOS imaging, Paris, France) software [6,10]. Cup inclination on the frontal plane was defined as the angle between the cup axis and the horizontal reference line on the AP view [6,10] and cup anteversion on the sagittal plane as the angle between the cup axis and the reference horizontal line on the lateral view [6,10].

### 2.3. Statistical analysis

The statistical analysis was performed with Numbers 09™ Version 4.3 (Apple Inc, Cupertino, CA USA) software. Repeatability (intraobserver reliability) and reproducibility (interobserver reliability) of the EOS™ system were calculated for the first 10 cases. Two measurements were performed by two independent observers (a surgeon and a radiologist) and two successive measurements were performed at 1-month interval by the same observer for the 10 first patients. The mean differences (d), the standard deviation (SD) and the 95% confidence interval (CI 95%) (equivalent to 2 × SD) were calculated to analyze the data. The correlations between measurements and between observers were evaluated by linear regression for paired samples and the Pearson's interclass correlation coefficient (ICC) between the different series. An ICC of more than 0.8 was considered to be good and confirmed reliability of measurements. Reliability between measurements was evaluated according to the Bland and Altman [11] method by graphically representing the difference between the 2 measurements (performed by the same observer or 2 independent observers) in relation to the mean measurement.

Quantitative data were analyzed by determining the mean (M), the mean differences and the standard deviation (SD). A lack of statistically significant variation in cup orientation angles was confirmed by a paired *t*-test and by calculating the Pearson ICC

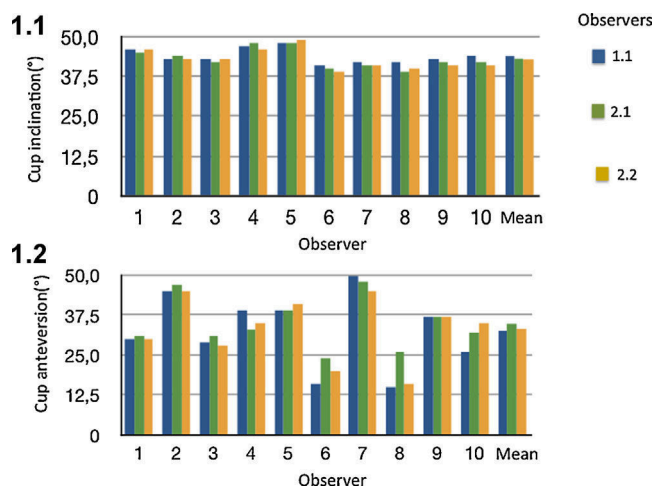


Fig. 1. Overall results of the inter- and intra observer study of EOS measurements of cup inclination (1.1) and anteversion (1.2).

between the different series of operative and post-operative measurements to evaluate cup inclination and anteversion variation for all patients. An individual analysis of variations in operative and post-operative data was also performed using the Bland and Altman method by graphically representing the difference between the two values in relation to the mean value [11].

The study protocol was validated by the local ethics committee and patients were informed of the study protocol.

## 3. Results

Forty-four patients with primary hip arthritis were included in the study. There were 11 men and 33 women, mean age 64 years old (range = 40–83, SD ± 14.6) mean body mass index 27 kg/m<sup>2</sup> (range = 18–41, SD ± 6).

Intra- and interobserver variability for post-operative cup orientation evaluated by the EOS system are summarized in Table 1 and Fig. 1. The differences in successive measurements to determine intra- and interobserver variability were not significantly different from zero, showing that there were no systematic measurement errors. There was good agreement for anteversion values and inclination obtained by each operator and the same operator, with correlation coefficients of more than 93%. Using a CI of 95%, random errors for each of the parameters was less than ± 5°, with a wide distribution of anteversion as shown by the Bland and Altman graphic analysis (Fig. 2).

The results of the direct paired comparison of operative and post-operative angles obtained by computer navigation and EOS respectively are summarized in Fig. 3 and Table 2. Agreement between the two measurements was poor with a correlation coefficient of less than 40%. The direct paired *t*-test showed a significant difference in operative and post-operative values (Table 2). The Bland and Altman graphic analysis showed significant dispersion in relation to the mean measurement, especially for anteversion (Fig. 4).

## 4. Discussion

This is the first study using the EOS system to assess the reliability of the APP as a reference for cup placement during computer assisted THA. Although certain authors have analyzed cup position after THA using X-rays or CT-scan, these measurements are imprecise or inexact because pelvic tilt varies depending on the patient and his/her position [4,6,10–16].

**Table 1**  
Intra- and interobserver study of variability with EOS.

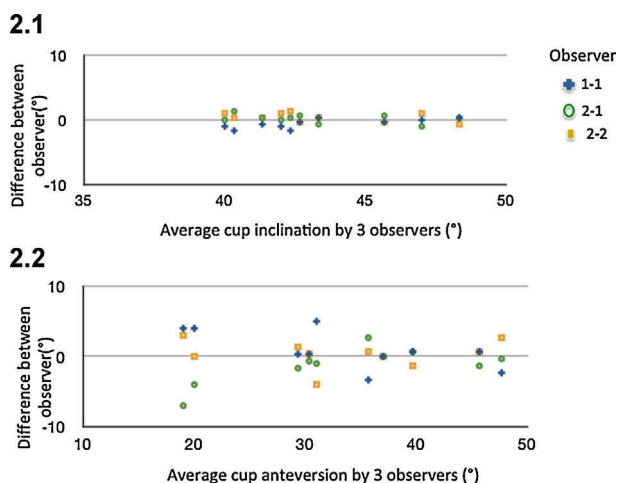
	Repeatability				Reproducibility			
	d	2SD	ICC	P-value	d	2 SD	ICC	P-value
Inclination	0.29	1.34	0.93	0.44	-0.19	1.60	0.94	0.26
Anteversión	-0.47	4.84	0.93	0.35	-0.16	5.08	0.94	0.31

d: mean differences; 2DS: two standard deviations (c95% confidence interval of differences); P-value of the Student *t*-test (observer effect for repeatability and repetition effect of the measurements for reproducibility); ICC: Pearson's interclass correlation coefficient.

**Table 2**  
Direct paired comparisons of measurements of cup angles obtained operatively during computer navigated THA and post-operatively by EOS.

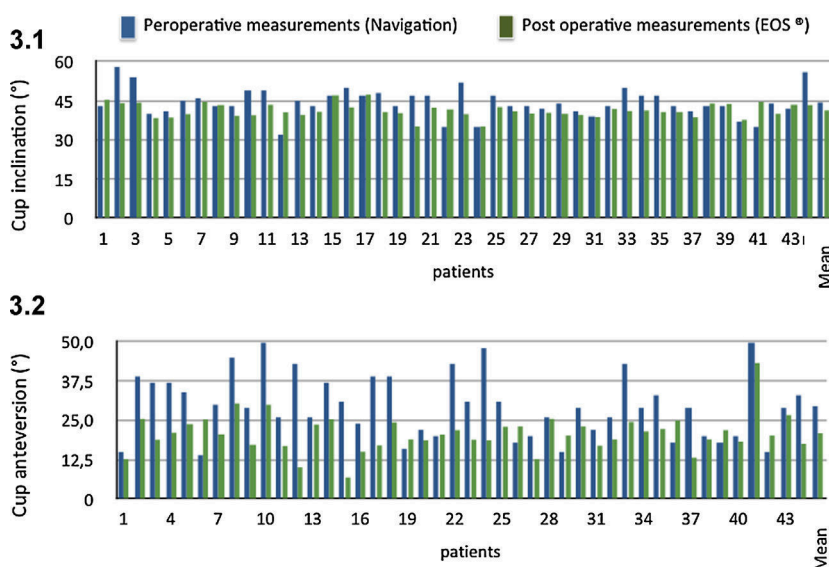
	Inclination			Anteversión		
	Navigation	EOS	Difference	Navigation	EOS	Difference
M	41.32	44.36	-3.0	20.91	29.52	-8.6
DS	2.66	5.34	5.1	6.7	10.19	9.8
P-value	0.0013			0.000004		
ICC	0.38			0.36		

M: mean, DS: standard deviation; P-value: student *t*-test of paired series; ICC: Pearson interclass correlation coefficient.

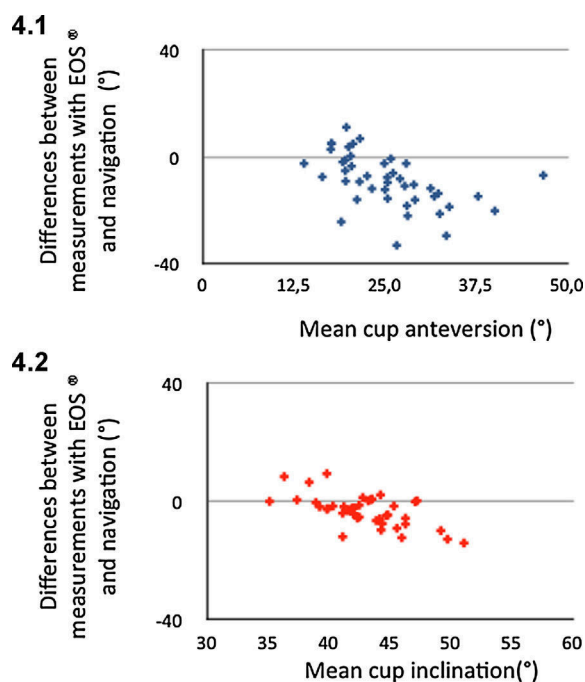


**Fig. 2.** Graphic representation of the difference between the measurements and the mean measurements according to Bland and Altman for cup inclination (2.1) and anteversion (2.2).

The first step was to confirm that the EOS system reliably measured cup orientation. Our results confirmed those in the literature and showed good inter- and intraobserver reproducibility of EOS measurements. Journé et al. [12] measured acetabular cup inclination and anteversion on dry bone with EOS and found a repeatability of  $\pm 1.4^\circ$  and  $\pm 2.3^\circ$  respectively and a reproducibility of  $\pm 1.6^\circ$  and  $\pm 2.5^\circ$  respectively with a CI of 95%. Billaud et al. [16], evaluated a metal back cup and found a difference of  $1.7^\circ \pm 1.4^\circ$  for inclination and  $1.5^\circ \pm 2.9^\circ$  for anteversion between EOS and CT-scan results respectively, and an interobserver error of  $2.6^\circ \pm 1.4^\circ$  for inclination and  $2.5^\circ \pm 1.4^\circ$  for anteversion respectively. Kalteis et al. [5] showed that the precision of acetabular cup inclination and anteversion measured on plain X-rays was  $\pm 3^\circ$  and  $\pm 10^\circ$ , respectively, while it was approximately  $2^\circ$  with CT-scan. Lazennec et al. [6] confirmed these results and did not find any systematic intra- and interobserver errors in the standing or sitting positions with a 95% CI between  $\pm 3.83^\circ$  and  $\pm 6.27^\circ$  for acetabular parameters respectively. Thus, although CT-scan is still considered to be the “gold standard” for the measurement of cup orientation, radiation limits its use. EOS is therefore an interesting and reliable alternative, which is more precise than conventional X-ray and with less radiation.



**Fig. 3.** Overall results of the comparative study of operative computer navigated measurements and post-operative EOS results of cup inclination (3.1) and anteversion (3.2).



**Fig. 4.** Graphic representation of the difference between operative computer navigated measurements and post-operative EOS results compared to mean measurements according to Bland and Altman for cup anteversion (4.1) and inclination (4.2).

Second, this study showed that the reliability of the APP was limited as a reference for operative cup orientation especially in relation to anteversion. This lack of precision has already been reported in the literature [17–20]. There are three possible explanations for this. First, the operative determination of APP orientation is difficult because the percutaneous palpation of bone anatomy landmarks (pubis and iliac spine) is imprecise. Wolf et al. [17] used a kinematic model to show that an error of 4 mm when identifying these landmarks would result in a 2° error in inclination and 7° in anteversion in the final cup position, while the minimum thickness of the soft tissues between the surface of the skin and the bone was approximately 8 mm at the iliac spine and 13 mm at the pubis, for a mean underestimation of anteversion of 4.4°. Second, computer navigation uses the APP as a local pelvic reference. This reference, which was considered to be exact for many years and to be globally horizontal in the supine position and vertical in the standing position, was also considered to be superimposable upon the Galilean reference frame used to perform THA. Indeed, initially, the APP was considered to be independent of gender and age [18,19] and stable between the seated and standing position and after THA [19]. However, studies have now shown that the APP is, in fact, not vertical but has a posterior tilt of approximately 4°, more than 5° in 38% of cases and even 10° in 13% of cases, and these are significant inter-individual variations [17–20]. Finally the position of the pelvis is dynamic, not static, during changes in position and daily activities and this variation, which is not predictable, is between –2° and –5.4° of pelvic extension [4,20–25]. The APP used as a reference could be weighted in relation to the pelvic tilt in the standing position, as suggested by Wolf et al. [17]. Although this author added the estimated 4° to determine APP orientation during surgery, the variation of the position of the pelvis between the preoperative standing (X-ray or EOS) or supine (CT-scan) positions and the operative lateral decubitus position makes this estimation random. The final possible explanation is that the variation in cup orientation compared to the APP may be the result of a modification in pelvic parameters before and after THA, as shown by

Nishihara et al. [21] and Babisch et al. [4], and this variation in pelvic tilt during cup insertion must be taken into consideration so that the orientation is not the same for all patients. McCollum et al. [24] also suggested adjusting cup position to anteroposterior pelvic tilt to reduce the risk of dislocation after THA because of the wide range (–37°–44°) of preoperative values of pelvic tilt in patients in the supine position. Lembeck et al. [26] measured variations in functional anteversion of the cup in relation to variations in pelvic tilt and defined the notion of functional acetabular anteversion to obtain a balance between stability and mobility. According to Lazennec et al. [6] and Lembeck et al. [26], a variation in posterior pelvic tilt of 1° results in an increase in functional anteversion of the cup of 0.7°. Philippot et al. [25], emphasized the necessity of taking into account sagittal balance of the spine and the pelvis during THA and defined a new reference, the pelvi-Lewinnek angle which is approximately 12°, constant whatever the position, and which they included in the navigation protocol.

## 5. Conclusion

Pelvic tilt, functional anteversion and the lack of precision in identifying the APP are the cause of poor reliability of this reference for acetabular cup position. Preoperative evaluation of these parameters must be improved to improve accuracy in cup positioning. Further research using EOS should help provide specific individual data for preoperative planning of component placement as well as achieve operative goals by integrating this information into computer navigated THA.

## Disclosure of interest

The authors have not supplied their declaration of conflict of interest.

## References

- [1] Mainard D. Navigated and non navigated total hip arthroplasty: results of two consecutive series using a cementless straight hip stem. *Orthopedics* 2008;31(10 suppl. 1):21–6.
- [2] Mainard D, Valentin S, Gasnier J, Galois L, Mollard B. Mesure du plan pelvien antérieur par ultrasons : comparaison aux mesures radiologiques et par logiciel de navigation. *Rev Chir Orthop* 2007;93:131–2.
- [3] Wan Z, Malik A, Jaramaz B, Chao L, Dorr LD. Imaging and navigation measurement of acetabular component position in THA. *Clin Orthop Relat Res* 2009;467:32–42.
- [4] Babisch JW, Layher F, Amiot LP. The rationale for tilt adjusted acetabular cup navigation. *J Bone Joint Surg Am* 2008;90:357–65.
- [5] Kalteis TA, Handel M, Herbst B, Grifka J, Renkawitz T. In vitro investigation of the influence of pelvic tilt on acetabular cup alignment. *J Arthroplasty* 2009;24:152–7.
- [6] Lazennec JY, Rousseau MA, Rangel A, et al. Pelvis and total hip arthroplasty acetabular component orientations in sitting and standing positions: measurements reproducibility with EOS imaging system versus conventional radiographies. *Orthop Traumatol Surg Res* 2011;97:373–80.
- [7] Duboussset J, Charpak G, Skalli W, Kalifa G, Lazennec JY. EOS stereo-radiography system: whole-body simultaneous anteroposterior and lateral radiographs with very low radiation dose. *Rev Chir Orthop* 2007;93:141–3.
- [8] Kalifa G, Charpak Y, Maccia C, et al. Evaluation of a new low-dose digital X-ray device: first dosimetric and clinical results in children. *Pediatr Radiol* 1998;28:557–61.
- [9] Deschenes S, Charron G, Beaudoin G, et al. Diagnostic imaging of spinal deformities: reducing patients radiation dose with a new slot-scanning X-ray imager. *Spine* 2010;35:989–94.
- [10] Chaïbi Y, cressonb T, Aubert B, et al. Fast 3D reconstruction of the lower limb using a parametric model and statistical interference and clinical measurements calculation from bi planar X-rays. *Comput Method Biomech Biomed Engin* 2012;15:457–66.
- [11] Bland JM, Altman DG. Statistical methods for assessing agreement between two methods of clinical measurement. *Lancet* 1986;8476:307–10.
- [12] Journé A, Sadaka J, Bélicour C, Sautet A. New method for measuring acetabular component positioning with EOS imaging: feasibility study on dry bone. *Int Orthop* 2012;36:2205–9.
- [13] Lazennec JY, Brusson A, Rousseau MA, Gomes C, Foulinais D. La rotation axiale du bassin dans le plan horizontal: étude expérimentale par le système

- EOS, résultats cliniques d'une série de 98 patients. *Rev Chir Orthop Traumatol* 2012;98(Suppl. 7):S320.
- [14] Guenon B, Zadegan F, Ami F, Hanche D, Nizard R. Reliability of a new method for lower-extremity measurement based on stereoradiographic three dimensional reconstruction. *Orthop Traumatol Surg Res* 2012;98:444-5.
- [15] Kosiyatrakul A, Lena S, Chotanaphuti T. Measurement of acetabular cup anteversion with the circle theorem. *J Med Assoc Thai* 2009;92(Suppl. 6): S128-33.
- [16] Billaud A, Lavoine N, Tournier C. Mesure EOS 3D de l'antéversion et de l'inclinaison d'un cotyle metal-back. *Rev Chir Orthop Traumatol* 2011;97(Suppl. 7):S298.
- [17] Wolf A, Digioia 3rd AM, Mor AB, Jaramaz B. Cup alignment error model for total hip arthroplasty. *Clin Orthop Relat Res* 2005;437:132-7.
- [18] Taki N, Mitsugi N, Mochida Y, Akamatsu Y, Saito T. Change in pelvic tilt angle 2 to 4 years after total hip arthroplasty. *J Arthroplasty* 2012;27: 940-4.
- [19] Pinoit Y, May O, Girard J, Laffargue P, Ala Eddine T, Migaud H. Low accuracy of the anterior pelvic plane to guide the position of the cup with imageless computer assistance: variation of position in 106 patients. *Rev Chir Orthop* 2007;93:455-60.
- [20] Blondel B, Parratte S, Tropiano P, Pauly V, Aubaniac JM, Argenson JN. Pelvic tilt measurement before and after total hip arthroplasty. *Orthop Traumatol Surg Res* 2009;95:568-72.
- [21] Nishihara S, Sugano N, Nishii T, Ohzono K, Yoshikawa H. Measurements of pelvic flexion angle using three-dimensional computed tomography. *Clin Orthop Relat Res* 2003;411:140-51.
- [22] Ala Eddine T, Migaud H, Chantelot C, et al. Variations of pelvic anteversion in the lying and standing positions analysis of 24 control subjects and implications for CT measurement of position of a prosthetic cup. *Surg Radiol Anat* 2001;23:105-10.
- [23] Beckmann J, Lüring C, Tingart M, Anders S, Grifka J, Köck FX. Cup positioning in THA: current status and pitfalls. A systematic evaluation of the literature. *Arch Orthop Trauma Surg* 2009;129:863-72.
- [24] McCollum DE, Gray WJ. Dislocation after total hip arthroplasty. Causes and prevention. *Clin Orthop Relat Res* 1990;261:159-70.
- [25] Philippot R, Wegrzyn J, Farizon F, Fessy MH. Pelvic balance in sagittal and Lewinnek reference planes in the standing, supine and sitting positions. *Orthop Traumatol Surg Res* 2009;95:70-6.
- [26] Lembeck B, Mueller O, Reize P, Wuelker N. Pelvic tilt makes acetabular cup navigation inaccurate. *Acta Orthop* 2005;76:517-23.