



Science Arts & Métiers (SAM)

is an open access repository that collects the work of Arts et Métiers Institute of Technology researchers and makes it freely available over the web where possible.

This is an author-deposited version published in: <https://sam.ensam.eu>
Handle ID: <http://hdl.handle.net/10985/21561>

To cite this version :

Cécile ROSCOP, Paul MATHIO, Pascal KOUYOUMDJIAN, Wafa SKALLI, Olivier GILLE, Laurent GAJNY - Analysis of apex and transitional vertebra of the spine according to pelvic incidence using orientation and position parameters - European Spine Journal - Vol. 30, n°9, p.2514-2519 - 2021

Any correspondence concerning this service should be sent to the repository

Administrator : scienceouverte@ensam.eu



Analysis of apex and transitional vertebra of the spine according to pelvic incidence using orientation and position parameters.

Cécile Roscop¹, Paul Mathio¹, Laurent Gajny², Pascal Kouyoumdjian³, Wafa Skalli², Olivier Gille¹

¹ Spine Surgery Department, University Hospital, Bordeaux, France

² Institut de Biomécanique Humaine Georges Charpak, Arts et Métiers, Institute of Technology, Paris, France.

³ Spine Surgery Department, University Hospital, Nîmes, France

ABSTRACT:

Objective: To identify the different apex and transitional vertebra according to the shape of the pelvis of individuals despite their difference in sagittal alignment using our measurement system.

Methods: Full spine X-rays using EOS in standard stand-position of 99 volunteers were selected (47 women, 52 men, mean age 31years old). Validated 3D reconstruction technique allowing extraction of spinopelvic parameters, and position and rotation of each vertebra and lumbar discs. Subjects were divided in three groups: low PI (*low PI*, $n=37$), moderate PI (*mid PI*, $n=52$), high PI (*high PI*, $n=10$), with respectively a PI below 45 °, between 45 °-60 ° and above 60 °. Occurrence of specific position and rotation values of apex and transitional vertebra were assessed in each groups.

Results: Frequency curves tend to move cranially when the incidence increases except in cervicothoracic where T1 is a constant for all shape of spine with occurrence approaching 90%. Angulation value of relevant vertebra and lumbar lordosis are significantly positively correlated for the whole population.

Conclusions: Our study allowed the assessment of the distribution of spine curvatures according to the pelvic incidence. It describes the occurrence of localization of the apex and transitional vertebrae according to pelvic incidence. These results should be taken into account during the analysis of the sagittal balance, especially when planning deformity surgery in adults.

Keywords: postural balance, spinal alignment, EOS™ 2D/3D, vertebral rotation, pelvic incidence.

INTRODUCTION

Deterioration of the sagittal balance due to degenerative pathology is correlated with an alteration in the quality of life and a worsening of lower back pain, most often leading to surgery [1]. Surgery is deleterious when the fusion is performed in an incorrect position, not respecting the sagittal balance criteria [2, 3]. Knowledge and restoration of sagittal balance is essential to obtain good postoperative outcomes [4, 5]. However, estimating the sagittal profile is sometimes difficult when it has already deteriorated.

Sagittal alignment is assessed by spinopelvic parameters and spine curvature. Lumbar lordosis is strongly correlated with pelvic incidence, which has enabled many authors to establish formulas estimating theoretical lumbar lordosis according to pelvic incidence [6, 7]. However, for an identical lumbar lordosis, sagittal balance of people can be very different [8, 9]. Lumbar lordosis can no longer be considered as a single concentric curvature. Indeed, 67% of lumbar lordosis is found on the lower L4S1 levels [9, 10]. Additionally, lumbar lordosis can no longer be limited to the upper end-plate of L1 and upper end-plate of S1. Berthonnaud et al. [11] showed that the inflection point of lumbar and thoracic curvatures could be moved depending on pelvic incidence. For high pelvic incidence, the inflection point may be beyond T12. In this case, the curvature measured between L1 and S1 may underestimate the true lumbar lordosis.

Otherwise, Roussouly describes in his classification different apex according to the different types of spine [9]. Indeed, the more the sacral slope increases, the more the apex tends to move cranially. The same is true for the inflection point. Tono et al [12] have shown that pelvic incidence is strongly correlated with lumbar lordosis according to different lumbar apex. However, there is no correlation when the lumbar apex is beyond L3, suggesting that in this shape of spine, lumbar lordosis is underestimated when measured between L1 and S1.

To our knowledge, there are no radiological parameters to assess apex and transitional vertebrae. In addition, the description of apex and inflection point at the lumbar level is well described in several articles, however thoracic apex and inflection point of cervicothoracic are still unrecognized. The objective of this study is to identify the different apex and transitional vertebra according to the shape of the pelvis of individuals despite their difference in sagittal alignment using our measurement system.

METHODS

Population and study design

99 asymptomatic volunteers (52 men and 47 women) were retrospectively included for the study. The asymptomatic character of the volunteers was assessed using two parameters: the Oswestry score, which must be

less than 20, [1] and a visual analog scale which separately assesses low back pain and radiculalgia, which must be less than 2/10. X-rays were obtained using the EOS system in the standardized free-standing position adapted from Faro: fists on clavicles [13]. This position is more representative of a subject's functional balance while still allowing adequate lateral radiographic visualization of the spine. A 3D reconstruction including the spine and the pelvis were obtained using a validated software developed at Institut de Biomécanique Humaine Georges Charpak (ENSAM Paris) [14–16]. Inclusion criteria of the EOS radiographs in the study were to have total visibility from pelvis to head on both views. Exclusion criteria were: previous spine surgery, surgery or accessories preventing the visibility of the upper part of the cervical spine, and an abnormality in number of vertebrae such as a lumbosacral transitional vertebra or a supernumerary lumbar vertebra.

Studied radiographic parameters

We measured: pelvic incidence (PI), pelvic tilt (PT), sacral slope (SS), thoracic kyphosis (T4T12 KT) lumbar lordosis (L1S1 LL), and global postural parameters like the sagittal vertical axis (SVA) [17], the global tilt (GT) [18], and ODHA [19].

Apex and transitional vertebra

We use two parameters to define these relevant vertebrae as described in Figure 1. The position parameter corresponds to the offset between the center of the vertebral body and the gravity line through the femoral heads named *Ax*. The orientation parameter corresponds to the angulation of the vertebra with respect to the horizontal called *VSA (Vertebral Sagittal Angulation)*. The lumbar apex is defined as the vertebra closest to the gravity line with an angulation close to the horizontal, ie an *Ax* and a *VSA* closest to 0. Conversely, the thoracic apex is furthest from the axis and close to the horizontal with the largest *Axis* and a *VSA* close to 0. The cervicothoracic and thoracolumbar transitional vertebra correspond respectively to the most oriented downwards with the most negative *VSA* and the most upward-oriented with the most positive *VSA*.

Subjects were then divided into three groups according to their pelvic incidence [20]: low PI (*low PI*), moderate PI (*mid PI*), high PI (*high PI*), with respectively a PI <45 °, between 45 ° -60 ° and > 60 °.

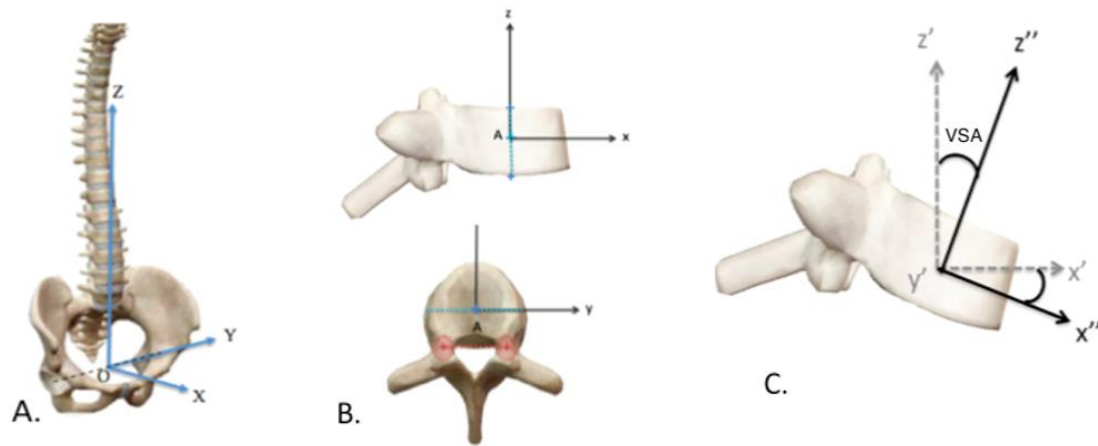


Figure 1 : A: Anatomogravital frame: The frontal plane is the vertical plane going through both acetabulum centers', the sagittal and transverse plan are orthogonal to each other and to the frontal plane. The origin of the frame is from the center of the two acetabulum segment. B: Position parameter: x coordinates of the point A center of the vertebral body in the anatomogravital frame, noted Ax. C: Orientation parameter: VSA corresponding to angular values of rotations quantified by method using rotation matrices in sagittal plane.

Statistical analysis

A descriptive analysis of the radiological criteria was made using the online software EasyMedStat (www.easymedstat.com; Neuilly-Sur-Seine; France). The normality of the parameters was evaluated by the Shapiro-Wilk test with an alpha risk of 5% ($\alpha = 0.05$). Correlations between parameters were evaluated using a correlation calculation (Pearson test) with an alpha significance threshold equal to 0.05.

RESULTS

Description of the sample

99 of 119 subjects were included. 11 subjects had an abnormality in the number of vertebrae: transitional lumbosacral anomaly or by additional lumbar vertebra. 9 subjects weren't reconstructed because they didn't respect the standardized free-standing position adapted from Faro: hands to ears or head obscuring visibility of the upper cervical spine. Out of 99 subjects, there were 47 women and 52 men. The average age was 31 (range, 18-47). Subjects were asymptomatic: the mean of the clinical questionnaires was respectively 9,0% for Oswestry scale (0-16%, SD 3.23) and 0.08 for VAS (0-2, SD 0.24). Subjects' characteristics are described in Table 1.

Table 1: Demographical and radiological sagittal parameters of the sample

	Mean	Min	Max	SD
Age (years)	31	18	47	7,3
Oswestry (%)	9,0	0	16	3,23
EVA (n)	0,08	0	2	0,24
PI (°)	48,9	29.9	80.1	9,9
PT (°)	9,4	-11.0	26.5	6,9
SS (°)	39,5	24.6	59.7	7,6
T4T12 TK (°)	33,5	8.4	5.6	8,9
L1S1 LL (°)	57,5	29.9	85.2	9,3
SVA (°)	27,3	2.8	64.2	15,5
GT (°)	15,6	1.5	30.3	6,5
ODHA (°)	3,1	-7.7	3.2	2,1

Apex and transitional vertebra according to PI

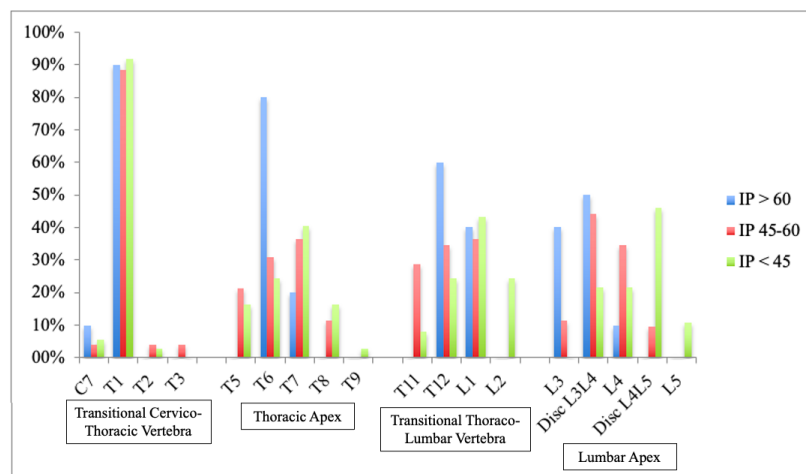
37 subjects were classified in the group *lowPI*, 52 in the group *midPI*, et 10 in the group *highPI* (table 2).

Table 2 : Sagittal parameters (mean ± SD)

	LowPI (=37)	MidPI (=52)	HighPI (=10)
PI	39,3 ± 4,6	52,1 ± 4,6	68,0 ± 6,0
PT	5,1 ± 6,9	11,1 ± 5,2	17,0 ± 4,7
SS	34,2 ± 6,2	41,0 ± 5,5	51,0 ± 6,3
T4T12 TK	34,0 ± 9,1	33,0 ± 9,1	34,1 ± 8,3
L1S1 LL	52,9 ± 8,7	58,6 ± 7,5	68,0 ± 6,0
SVA	30,6 ± 17,1	25,7 ± 15,0	24,0 ± 9,2
ODHA	3,25 ± 2,0	3,1 ± 2,4	3,0 ± 1,3

T1 is the transitional cervicothoracic vertebra for the three groups with values approaching 90% (Graph 2).

The thoracic apex is found at T7 in 41% in the group *lowPI*, 37% in the group *midPI*, at T6 in 80% in the group *highPI*. The thoracolumbar transitional vertebra is at L1 in 43% in the group *lowPI*, 37% in the group *midPI*, and at T12 in 60% in the group *highPI*. The lumbar apex is found in L4L5 in 46% in the group *lowPI*, and L3L4 in 44% in the group *midPI*, 50% in the group *highPI*.



Graph 1: Relevant vertebra according to rotation parameter and pelvic incidence

Correlation study according to orientation parameter and sagittal parameter

VSA of relevant vertebra and LL are significantly positively correlated for the whole population (table 3). Low lumbar VSA and PI are significantly positively correlated (L5 $r=0.68$, $p < 10^{-4}$, L4 $r=0.63$, $p < 10^{-4}$). T1 VSA is not significantly correlated with LL and PI ($r=0.06$, $p > 0.05$, $r=0.02$, $p > 0.05$).

Table 3: Correlation coefficients (Pearson) between vertebral orientations and pelvic parameters in asymptomatic subjects.

	L5 VSA	L4 VSA	T12 VSA	T7 VSA	T1 VSA
Pelvic Incidence	0,68* $p < 10^{-4}$	0,63* $p < 10^{-4}$	0,09 <i>NS</i>	0,18 <i>NS</i>	0,06 <i>NS</i>
Pelvic Tilt	0,10 <i>NS</i>	0,13 <i>NS</i>	0,26 $p=0,01$	0,10 <i>NS</i>	0,23 $p=0,019$
Lumbar Lordosis L5S1	0,69* $p < 10^{-4}$	0,58* $p < 10^{-4}$	0,66* $p < 10^{-4}$	0,25 $p=0,012$	0,02 <i>NS</i>

* Reports to a very strong significant correlation

NS: Not significant

DISCUSSION

The erected position is unique to Humans, stable and economical. Duval-Beaupère et al have shown the tendency to maintain an economic posture in terms of muscle fatigue and spinal stresses [6]. This is allowed thanks to the appearance of an enlargement and verticalization of the pelvis, with formation of harmonious spinal curvatures, in particular a lumbar lordosis [21, 22]. There is significant variability in these curvatures in the general population. Roussouly and al. described different shape of spine depending on the degree of SS and the location of the lumbar apex [9]. The Roussouly classification highlights that with a high sacral slope, the lumbar apex is higher. Additionally, in their work they described the lumbar lordosis as divided into two arcs with the majority of lordosis at the lower arch, with the apex located at the top of the lower arch. The inflection point of lumbar and thoracic curves is also more cranial as the SS increases. However, there is no description of the thoracic apex and cervico-thoracic inflection point depending on the shape of the pelvis. Tono and al. [12] investigated the relationship between PI and LL according to different apex. Their results show a correlation between PI and LL when apex are located in L4 and below. However, there is no longer a correlation between PI and LL when the apex is located at L3 and above. It suggested that theoretical formulas of LL versus PI are not applicable in this case [8, 20, 23, 24].

In this study, we assessed thoracic and lumbar apex, cervicothoracic and thoracolumbar transitional vertebra, and their occurrence according to the pelvic incidence. Indeed, pelvic incidence is a shape parameter of the pelvis, fixed and constant for an individual after the end of growth [25], we have proposed to describe these different relevant vertebrae according to the pelvic incidence. If we consider the most frequent trio of vertebrae, the frequency curves tend to move cranially when the incidence increases except in cervico-thoracic where T1 is a constant for all shapes of spine (graph 1). Concerning lumbar apex, in *lowPI* group the apex is located at L4L5 disc (46%,) for PI beyond 45 °, the apex is at L3L4 disc (44% in *midPI*, 50% in *highPI*). The apex is therefore low, which confirms that the majority of lordosis is considered between L4L5 disc and S1 for low incidences and between L3L4 and S1 for larger incidences. Regarding thoracolumbar inflection point, it is located at L1 for pelvic incidences of less than 45 ° (43% *lowPI*, 37% *midPI*), in T12 for incidences above 60 ° (60% *highPI*). For large PI, L1S1 lumbar lordosis underestimates true lumbar lordosis. It is better to measure the lordosis between S1 and the vertebra most tilted down than to select L1. In addition, for these large PI it will be necessary to restore a long lumbar lordosis to respect the physiology and to obtain an “ideal” apex regarding L3L4 discs. Finally for thoracic apex, it is located in T7 for pelvic incidences of less than 45 ° (41% *lowPI*, 37% *midPI*) and in T6 for incidences above 60 ° (80% *highPI*). This notion is important in long instrumented fusion, the choice and orientation of the last instrumented thoracic vertebra must take into account the value of the pelvic incidence and the location of the physiological apex [26, 27].

We deliberately did not analyze the cervical spine because there is significant inter-individual variability in cervical curvature in the global population. The literature describes the possibility of having a cervical spine in kyphosis even in healthy subjects [28]. This variability does not allow us to highlight any relevant vertebra.

A spine arthrodesis in inappropriate position is correlated with deterioration in quality of life [2, 3]. In this sense, the SRS-Schwab classification proposed goals to reduce this risk concerning pelvic tilt, PI minus LL, and VAS [29]. However, despite compliance with its targets, there is 30% postoperative mechanical complication in several series [26, 30]. This particularly concerns patients with a high PI for whom its targets do not seem to be adapted. Indeed, a PT at 20 ° is not necessarily pathological for these patients as in our *highPI* group ($17.0^{\circ} \pm 4.7$). Otherwise, the distribution of lordosis, proven to be important, is not considered in the Schwab classification [10, 29]. The European Spine Study Group (ESSG) proposes a proportional PI based method that predicts the appearance of mechanical complications after deformity surgery in adults [31]. The GAP score takes into account the proportion of L4S1 lordosis in particular and allows a more global morphological assessment that does not exclude high pelvic views [18, 31]. Knowing the distribution of curvatures, in particular in lumbar lordosis, and

the location of apex, is therefore essential to limit post-operative mechanical complications and improved outcomes.

These values do not take into account compensation phenomena, in particular an augmented pelvic tilt and knee flexion. For the purpose of surgical planning, the pelvic tilt must first be corrected by software simulations, as it is already done routinely. These values should be applied to clinical studies to analyze and demonstrate the influence of the orientation and position of relevant vertebrae on the outcome of arthrodesis.

CONCLUSION

Sagittal alignment differs with pelvic incidence even when the LL values are the same. Our study allowed the assessment of the distribution of spine curvatures according to the pelvic incidence. It describes the occurrence of localization of the apex and transitional vertebrae according to pelvic incidence. These results should be taken into account during the analysis of the sagittal balance, especially when planning deformity surgery in adults.

REFERENCES

1. Glassman SD, Bridwell K, Dimar JR, et al (2005) The impact of positive sagittal balance in adult spinal deformity. *Spine* 30:2024–2029. <https://doi.org/10.1097/01.brs.0000179086.30449.96>
2. Lazennec JY, Ramaré S, Arafati N, et al (2000) Sagittal alignment in lumbosacral fusion: relations between radiological parameters and pain. *Eur Spine J Off Publ Eur Spine Soc Eur Spinal Deform Soc Eur Sect Cerv Spine Res Soc* 9:47–55. <https://doi.org/10.1007/s005860050008>
3. Tribus CB, Belanger TA, Zdeblick TA (1999) The effect of operative position and short-segment fusion on maintenance of sagittal alignment of the lumbar spine. *Spine* 24:58–61. <https://doi.org/10.1097/00007632-199901010-00014>
4. Bourghli A, Aunoble S, Reebye O, Le Huec JC (2011) Correlation of clinical outcome and spinopelvic sagittal alignment after surgical treatment of low-grade isthmic spondylolisthesis. *Eur Spine J* 20:663–668. <https://doi.org/10.1007/s00586-011-1934-z>
5. Kawakami M, Tamaki T, Ando M, et al (2002) Lumbar sagittal balance influences the clinical outcome after decompression and posterolateral spinal fusion for degenerative lumbar spondylolisthesis. *Spine* 27:59–64. <https://doi.org/10.1097/00007632-200201010-00014>
6. Duval-Beaupère G, Schmidt C, Cosson P (1992) A Barycentremetric study of the sagittal shape of spine and pelvis: the conditions required for an economic standing position. *Ann Biomed Eng* 20:451–462
7. Schwab F, Lafage V, Boyce R, et al (2006) Gravity line analysis in adult volunteers: age-related correlation with spinal parameters, pelvic parameters, and foot position. *Spine* 31:E959-967. <https://doi.org/10.1097/01.brs.0000248126.96737.0f>
8. Legaye J, Duval-Beaupère G (2005) Sagittal plane alignment of the spine and gravity: a radiological and clinical evaluation. *Acta Orthop Belg* 71:213–220
9. Roussouly P, Gollogly S, Berthonnaud E, Dimnet J (2005) Classification of the normal variation in the sagittal alignment of the human lumbar spine and pelvis in the standing position. *Spine* 30:346–353

10. Roussouly P, Pinheiro-Franco JL (2011) Sagittal parameters of the spine: biomechanical approach. *Eur Spine J Off Publ Eur Spine Soc Eur Spinal Deform Soc Eur Sect Cerv Spine Res Soc* 20 Suppl 5:578–585. <https://doi.org/10.1007/s00586-011-1924-1>
11. Berthonnaud E, Dimnet J, Roussouly P, Labelle H (2005) Analysis of the sagittal balance of the spine and pelvis using shape and orientation parameters. *J Spinal Disord Tech* 18:40–47
12. Tono O, Hasegawa K, Okamoto M, et al (2019) Lumbar lordosis does not correlate with pelvic incidence in the cases with the lordosis apex located at L3 or above. *Eur Spine J* 28:1948–1954. <https://doi.org/10.1007/s00586-018-5695-9>
13. Faro FD, Marks MC, Pawelek J, Newton PO (2004) Evaluation of a functional position for lateral radiograph acquisition in adolescent idiopathic scoliosis. *Spine* 29:2284–2289
14. Humbert L, De Guise JA, Aubert B, et al (2009) 3D reconstruction of the spine from biplanar X-rays using parametric models based on transversal and longitudinal inferences. *Med Eng Phys* 31:681–687. <https://doi.org/10.1016/j.medengphy.2009.01.003>
15. Ferrero E, Lafage R, Vira S, et al (2017) Three-dimensional reconstruction using stereoradiography for evaluating adult spinal deformity: a reproducibility study. *Eur Spine J Off Publ Eur Spine Soc Eur Spinal Deform Soc Eur Sect Cerv Spine Res Soc* 26:2112–2120. <https://doi.org/10.1007/s00586-016-4833-5>
16. Gajny L, Ebrahimi S, Vergari C, et al (2019) Quasi-automatic 3D reconstruction of the full spine from low-dose biplanar X-rays based on statistical inferences and image analysis. *Eur Spine J Off Publ Eur Spine Soc Eur Spinal Deform Soc Eur Sect Cerv Spine Res Soc* 28:658–664. <https://doi.org/10.1007/s00586-018-5807-6>
17. Jackson RP, Hales C (2000) Congruent spinopelvic alignment on standing lateral radiographs of adult volunteers. *Spine* 25:2808–2815
18. Boissière L, Takemoto M, Bourghli A, et al (2017) Global tilt and lumbar lordosis index: two parameters correlating with health-related quality of life scores-but how do they truly impact disability? *Spine J Off J North Am Spine Soc* 17:480–488. <https://doi.org/10.1016/j.spinee.2016.10.013>
19. Amabile C, Pillet H, Lafage V, et al (2016) A new quasi-invariant parameter characterizing the postural alignment of young asymptomatic adults. *Eur Spine J Off Publ Eur Spine Soc Eur Spinal Deform Soc Eur Sect Cerv Spine Res Soc* 25:3666–3674. <https://doi.org/10.1007/s00586-016-4552-y>
20. Le Huec JC, Hasegawa K (2016) Normative values for the spine shape parameters using 3D standing analysis from a database of 268 asymptomatic Caucasian and Japanese subjects. *Eur Spine J Off Publ Eur Spine Soc Eur Spinal Deform Soc Eur Sect Cerv Spine Res Soc* 25:3630–3637. <https://doi.org/10.1007/s00586-016-4485-5>
21. Le Huec JC, Saddiki R, Franke J, et al (2011) Equilibrium of the human body and the gravity line: the basics. *Eur Spine J Off Publ Eur Spine Soc Eur Spinal Deform Soc Eur Sect Cerv Spine Res Soc* 20 Suppl 5:558–563. <https://doi.org/10.1007/s00586-011-1939-7>
22. Le Huec JC, Aunoble S, Philippe L, Nicolas P (2011) Pelvic parameters: origin and significance. *Eur Spine J Off Publ Eur Spine Soc Eur Spinal Deform Soc Eur Sect Cerv Spine Res Soc* 20 Suppl 5:564–571. <https://doi.org/10.1007/s00586-011-1940-1>
23. Schwab F, Lafage V, Patel A, Farcy J-P (2009) Sagittal plane considerations and the pelvis in the adult patient. *Spine* 34:1828–1833. <https://doi.org/10.1097/BRS.0b013e3181a13c08>
24. Hasegawa K, Okamoto M, Hatsushikano S, et al (2016) Normative values of spino-pelvic sagittal alignment, balance, age, and health-related quality of life in a cohort of healthy adult subjects. *Eur Spine J Off Publ Eur Spine Soc Eur Spinal Deform Soc Eur Sect Cerv Spine Res Soc* 25:3675–3686. <https://doi.org/10.1007/s00586-016-4702-2>

25. Legaye J, Duval-Beaupère G, Hecquet J, Marty C (1998) Pelvic incidence: a fundamental pelvic parameter for three-dimensional regulation of spinal sagittal curves. *Eur Spine J Off Publ Eur Spine Soc Eur Spinal Deform Soc Eur Sect Cerv Spine Res Soc* 7:99–103
26. Lafage R, Line BG, Gupta S, et al (2017) Orientation of the Upper-most Instrumented Segment Influences Proximal Junctional Disease Following Adult Spinal Deformity Surgery. *Spine* 42:1570–1577. <https://doi.org/10.1097/BRS.0000000000002191>
27. Sebaaly A, Riouallon G, Obeid I, et al (2018) Proximal junctional kyphosis in adult scoliosis: comparison of four radiological predictor models. *Eur Spine J Off Publ Eur Spine Soc Eur Spinal Deform Soc Eur Sect Cerv Spine Res Soc* 27:613–621. <https://doi.org/10.1007/s00586-017-5172-x>
28. Kim SW, Kim T-H, Bok DH, et al (2017) Analysis of cervical spine alignment in currently asymptomatic individuals: prevalence of kyphotic posture and its relationship with other spinopelvic parameters. *Spine J Off J North Am Spine Soc*. <https://doi.org/10.1016/j.spinee.2017.09.008>
29. Schwab F, Ungar B, Blondel B, et al (2012) Scoliosis Research Society-Schwab adult spinal deformity classification: a validation study. *Spine* 37:1077–1082. <https://doi.org/10.1097/BRS.0b013e31823e15e2>
30. Soroceanu A, Diebo BG, Burton D, et al (2015) Radiographical and Implant-Related Complications in Adult Spinal Deformity Surgery: Incidence, Patient Risk Factors, and Impact on Health-Related Quality of Life. *Spine* 40:1414–1421. <https://doi.org/10.1097/BRS.0000000000001020>
31. Yilgor C, Sogunmez N, Boissiere L, et al (2017) Global Alignment and Proportion (GAP) Score: Development and Validation of a New Method of Analyzing Spinopelvic Alignment to Predict Mechanical Complications After Adult Spinal Deformity Surgery. *J Bone Joint Surg Am* 99:1661–1672. <https://doi.org/10.2106/JBJS.16.01594>