



Science Arts & Métiers (SAM)

is an open access repository that collects the work of Arts et Métiers Institute of Technology researchers and makes it freely available over the web where possible.

This is an author-deposited version published in: <https://sam.ensam.eu>
Handle ID: <http://hdl.handle.net/10985/21902>

To cite this version :

Marc KHALIFÉ, Claudio VERGARI, Emmanuelle FERRERO, Valérie ATTALI, Cécile HEIDSIECK, Aymen ASSI, Wafa SKALLI - The rib cage: a new element in the spinopelvic chain - European Spine Journal - 2022

Any correspondence concerning this service should be sent to the repository

Administrator : scienceouverte@ensam.eu



The rib cage: a new element in the spinopelvic chain

Marc Khalife^{1,2,3,4}  · Claudio Vergari^{3,4} · Emmanuelle Ferrero^{1,2} · Valérie Attali^{5,6} · Cécile Heidsieck^{3,4} · Ayman Assi⁷ · Wafa Skalli^{3,4}

Abstract

Introduction This study analyzes anatomical variations of the thoracic cage (TC) according to spinopelvic alignment, age and gender using stereoradiography in erect position.

Methods This retrospective multicentric study analyzed computed parameters collected from free-standing position bi-planar radiographs, among healthy subjects. Collected data were: age, gender, pelvic parameters (Pelvic Incidence, Pelvic Tilt (PT) and Sacral Slope), T1-T12 Kyphosis (TK), L1-S1 Lordosis (LL), curvilinear spinal length, global TC parameters (maximum thickness and width, rib cage volume, mean Spinal Penetration Index (SPI)), 1st–10th rib parameters (absolute and relative (to the corresponding vertebra) sagittal angles).

Results Totally, 256 subjects were included (140 females). Mean age was 34 (range: 8–83). Significant correlations were found between TK and TC thickness (0.3, $p < 0.001$) and with TC Volume (0.3, $p = 0.04$), as well as rib absolute sagittal angle for upper and middle ribs (0.2, $p = 0.02$). Conversely, a -0.3 correlation has been exhibited between SPI and TK. Similar correlations were found with LL. PT significantly correlated with TC thickness (0.4, $p = 0.003$), SPI (-0.3 , $p = 0.03$), and all rib relative sagittal angles. Among global TC parameters, only thickness and SPI significantly changed after 20 years (respectively, 0.39 and -0.52 , $p < 0.001$). Ribs relative sagittal angle showed negative correlation with age in skeletally mature subjects ($p < 0.001$).

Conclusion This study demonstrates the correlation between TC anatomy and spinopelvic parameters, confirming its part of the spinopelvic chain of balance. Indeed, higher spinal curvatures were associated with lower SPI and higher TC thickness, TC volume and rib absolute sagittal angles.

Keywords Thoracic cage · Rib cage anatomy · Aging variations · Sagittal alignment · Pelvic incidence

✉ Marc Khalifé
marc.khalife@aphp.fr

¹ Orthopaedic Surgery Unit, Hôpital Européen Georges Pompidou, 20, rue Leblanc, 75015 Paris, France

² Université Paris Cité, Paris, France

³ Arts Et Métiers Institute of Technology, Université Sorbonne Paris Nord, Villetaneuse, France

⁴ IBHGC - Institut de Biomécanique Humaine Georges Charpak, HESAM Université, 75013 Paris, France

⁵ INSERM, UMRS1158 Neurophysiologie Respiratoire Expérimentale Et Clinique, Sorbonne Université, Paris, France

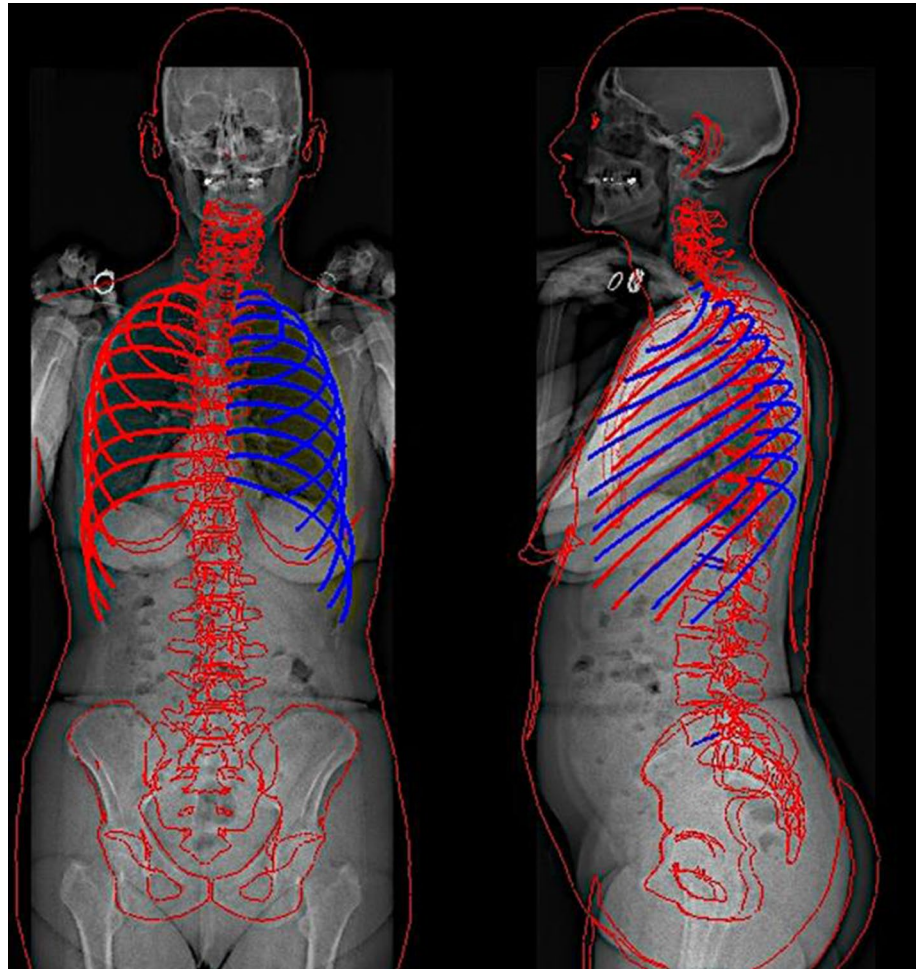
⁶ Service Des Pathologies du Sommeil (Département “R3S”), Assistance Publique Hôpitaux de Paris (APHP), Hôpitaux Universitaires Pitié Salpêtrière – Charles Foix, Paris, France

⁷ Faculty of Medicine, Saint-Joseph University, Beirut, Lebanon

Introduction

The spine and pelvis form a biomechanical chain of balance that allows to maintain an erect posture and a horizontal gaze. This results in a sagittal spinopelvic profile that can largely vary in different subjects: it depends on the morphology of the subject’s pelvis, and in particular on his pelvic incidence, but also on other factors such as age, gender, pain, and spine deformity [1, 2]. Alterations of the sagittal balance can be compensated by postural adjustments aiming at keeping the erect posture with a minimal energy expenditure [3]. Hence, thoracic kyphosis and lumbar lordosis can increase or decrease, and pelvic tilt can change within a physiological range in order to compensate [4]. In this sagittal chain of balance, the rib cage is often overlooked. However, ribs help stabilize the thoracic spine while also significantly reducing its range of motion [5, 6]. Therefore, the rib cage geometry

Fig. 1 Anteroposterior and lateral views after pelvis, spine and thoracic cage reconstruction



and kinematics can play a role in the compensating mechanisms which are deployed to keep the balance.

Alterations of balance can be permanent or semi-permanent, such as in spinal deformity, or dynamic, such as in breathing. While quiet breathing can be accompanied by a minor postural sway [7, 8], it has been shown that attaining maximal or minimal lung volume requires significant changes of the spinopelvic alignment [9, 10]. Thus, breathing function is correlated to thoracic cage anatomy and on its dynamic behavior, but also on the spinopelvic alignment and its dynamic changes. Furthermore, age and gender can have an impact on sagittal alignment [2, 11], as well as respiratory or musculoskeletal pathology [12]. Breathing is a basic vital function, and its study is therefore of interest for a wide range of physicians from pneumologists to spine surgeons, to understand more precisely the aging phenomena as well as gender variations of the rib cage. For instance, thoracic cage should be taken into account when addressing spinal malalignment. It has been demonstrated that restoring kyphosis in spinal deformity corrections helps avoiding respiratory repercussion [13], but the impact of this surgery on the rib cage is not well studied.

Indeed, little literature is available about thoracic cage anatomical variations, or its relationship with spinopelvic alignment. There are a few studies that analyzed rib cage anatomy variations using CT-scanner, however, to our knowledge, there are no articles in the literature describing age-, gender- and spinopelvic-related variations in upright position [14, 15]. Bi-planar radiography allows skeletal 3D reconstructions in erect position, allowing a more accurate sagittal alignment analysis than supine position [16]. In addition, radiation exposure is decreased for the subject, up to 30 times lower compared to CT-scan [17]. The 3D thoracic cage reconstruction method from bi-planar radiographs was validated in several articles analyzing rib cage deformities, brace treatment impact and predict pulmonary function in scoliotic adolescents [13, 18, 19].

The hypothesis of this study is that rib cage geometry is related to spinopelvic alignment. Hence, the aim of this study was to analyze the anatomical variations of the thoracic cage (TC) according to spinopelvic parameters using bi-planar X-Rays in erect position. Secondary objectives were to determine age- and gender-related variations of the TC.

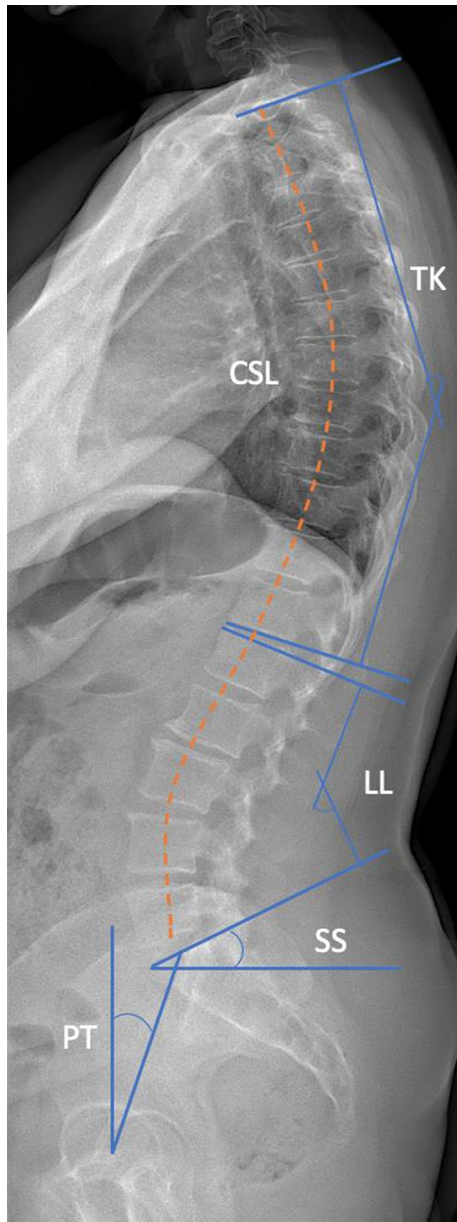


Fig. 2 Spinal and pelvic parameters representation on lateral view
TK: T1-T12 kyphosis, CSL: Curvilinear T1-L5 spinal length, LL: L1-S1 lordosis, SS: sacral slope, PT: pelvic tilt. Pelvic incidence = PT + SS.

Material and methods

Population

This multicentric study retrospectively included, apart from any medical consultation, healthy volunteer subjects from previous retrospective studies, with no reported pain. All subjects had free-standing position EOS® bi-planar radiographs (upright position, fingertips on the zygomatic bones,

one foot slightly forward) [20]. Subjects were excluded if they presented thoracic scoliosis (with Cobb angle greater than 10°) or any musculoskeletal deformity, and history of respiratory disease. This study was approved by the regional ethics committee (approval N° 6001, C.P.P Ile-de France VI) and FM 312 ethical committee at the Saint-Joseph University, Beirut. All subjects provided their informed written consent (or parents' if minor subject).

Parameters

Spinal and thoracic cage three-dimension reconstructions were performed according to previously validated methods [21, 22], by two specifically trained doctors (Fig. 1). Briefly, the user digitized the spinal line in the frontal and lateral X-rays, from T1 to L5. The method then proposed a first 3D reconstruction of the spine, and retro-projected the 3D models of the vertebra on the radiographs. The user could modify the models to make them fit the contours visible on the radiographs. In a second phase, the user digitized the sternum, the midlines of ribs 2, 5, 8 and 10 in the frontal radiograph, as well as the most posterior points of the ribs in the lateral view. Again, a 3D model was retro-projected on the radiographs for the user to adjust.

Apart from age and sex, all data were collected from 3D reconstructions:

- Pelvic parameters (Fig. 2): Pelvic incidence (PI), pelvic tilt (PT) and sacral slope (SS)
- Type of sagittal profile according to updated Roussouly's classification [23]
- Spinal parameters (Fig. 2): T1-T12 kyphosis (TK), T4-T12 kyphosis, L1-S1 lordosis (LL), curvilinear spinal length was measured from T1 to L5
- Global thoracic cage parameters (Fig. 3a):
 - maximum thickness (anteroposterior diameter—*mm*)
 - maximum width (lateral diameter—*mm*)
 - T1-T10 rib cage volume (cm^3)
 - mean Spinal Penetration Index (SPI: ratio between rib cage volume and volume occupied by the spine—%)
- Rib parameters, computed for each rib from 1 to 10 (Fig. 3b):
 - absolute sagittal angle: measured between horizontal line and rib sagittal axis.
 - relative sagittal angle: measured between the upper endplate of the corresponding vertebra and sagittal rib axis.
 - "umbrella angle": the coronal angle between two ribs.

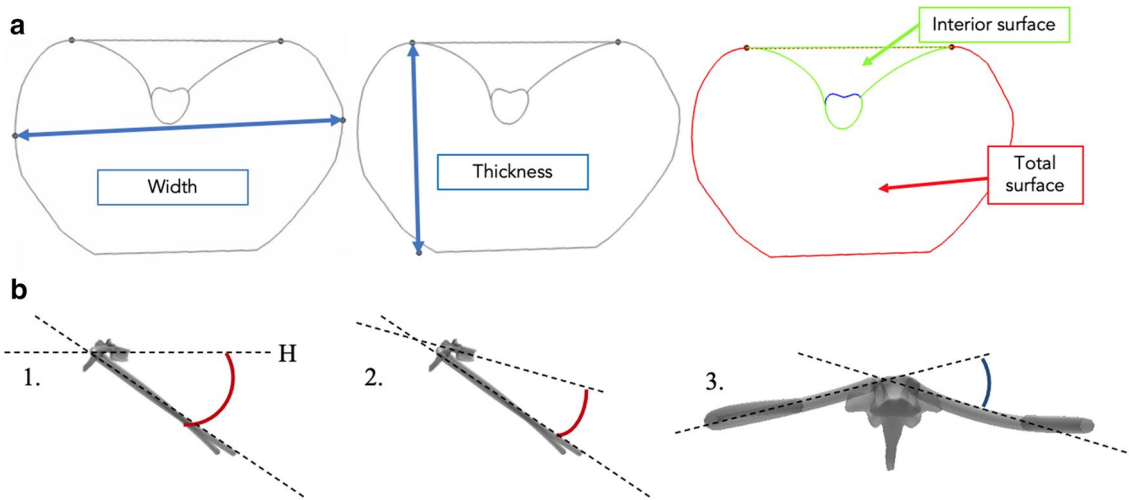


Fig. 3 a Thoracic cage width and thickness measure. Spinal Penetration Index (on the right) is obtained as follows: Interior surface \times 100 / Total surface. b Rib parameters. 1.: Absolute sagittal angle / 2.: Relative sagittal angle / 3.: Umbrella angle. H: Horizontal line

Table 1 Cohort demographic data

	Females	Males	Total	%
Children	28	10	38	15%
Adolescents	18	17	35	14%
Young	41	41	82	32%
Middle-aged	34	30	64	25%
Senior	19	18	37	14%
Growing	46	27	73	29%
Mature	94	89	183	71%
Total cohort	140	116	256	100%

Bold values correspond to totals (by gender or age categories)

Statistical analysis

All variables were tested for normality using Shapiro–Wilk's. Left and right ribs parameters were averaged, after statistically checking for symmetry. Rib groups have then been constituted: upper (ribs 2 to 5), middle (ribs 6 and 7) and lower (ribs 8 to 10). Correlations were searched between spinopelvic and thoracic parameters, using Pearson's coefficients. Using ANOVAs, rib and thoracic cage parameters have been compared according to sagittal profile as described in updated Roussouly's classification [23].

In order to distinguish more accurately variations between age intervals, and to separate growing from aging phenomena, the cohort has been divided in two subgroups for gender analysis (growing (8–19) versus mature skeleton (20+)) and into five groups for age analysis: Children (8–12 years),

Adolescents (13–19), Young (20–39), Middle-aged (40–59) and Seniors (60+).

Comparisons between gender or age categories were conducted using t-tests and ANOVAs for normally distributed variables, whereas Wilcoxon and Kruskal–Wallis tests were used for non-normally distributed ones. Correlations have then been tested between age and all the other numeric variables. A multivariate linear model was built to assess the relative effects of gender and subject height on rib cage volume. The model thus included sex, T1–L5 curvilinear spinal length and rib cage volume as variables, as well as their linear interactions. The statistical analyses have been carried out using RStudio, with p values lower than 0.05 considered significant.

Results

Population

A total of 256 healthy subjects were included for analysis, with 140 females (55%) and 116 males (Table 1). Mean age was 34 years (SD = 20.1, range: 8–83) with no significant difference between genders. Mean pelvic incidence was 50° (SD = 11, range: 24–87).

Relationship between rib cage and spinopelvic parameters

There were significant correlations between rib cage and spinopelvic parameters (Table 2, Fig. 4). Pelvic tilt and spinal length were correlated both to global rib cage parameters (volume, thickness, width, SPI) and to rib orientations

Table 2 Correlation coefficients between spinopelvic and rib cage parameters. Only significant p values and variables presenting correlations are reported (*: $p < 0.05$. †: $p < 0.001$). TC—Thoracic cage. SPI—Spinal penetration index

	T1-12 kyphosis	T4-T12 kyphosis	L1-S1 Lordosis	Pelvic Incidence	Sacral slope	Pelvic Tilt	Spinal length
TC volume	0.3†	0.2†	0.2*	0.1	0.1	0.3†	0.8†
TC thickness	0.3†	0.3†	0.1	0.1	0.1*	0.4†	0.5†
TC width	0.2†	0	0.1*	0.1	0	0.2†	0.8†
SPI	-0.3†	-0.2†	-0.2*	-0.1	-0.2†	-0.3†	-0.2†
Upper ribs absolute sagittal angle	0.1	0.2†	0.1	-0.1	0	-0.1	0.1
Middle ribs absolute sagittal angle	0.1	0.1*	0.1	-0.1	0	-0.1	0.1
Lower ribs absolute sagittal angle	-0.1	-0.1	0.3†	-0.2†	0.1*	-0.1	0.04
Upper ribs relative sagittal angle	-0.4†	-0.5†	0	-0.1	-0.1	-0.3†	-0.2†
Middle ribs relative sagittal angle	-0.2†	-0.4†	0	-0.1	-0.1	-0.2†	-0.2†
Lower ribs relative sagittal angle	0	-0.1	-0.2†	0	-0.2†	-0.3†	-0.2†
Upper ribs umbrella angle	0	0.1	0	-0.1	0.1	-0.1	-0.1*
Middle ribs umbrella angle	-0.1	0.1	-0.1	-0.1	0	-0.1*	-0.2†
Lower ribs umbrella angle	-0.1*	0	-0.1	-0.1	-0.1	-0.1*	-0.3†

Bold values correspond to significant correlations

(sagittal relative and absolute angles, umbrella angles, Table 2). T1-T12 and T4-T12 kyphosis were mostly correlated to global rib cage parameters (thickness and volume), but also to upper and middle ribs sagittal relative angles (Table 2). A higher thoracic kyphosis was associated to a lower SPI. Lumbar lordosis showed correlations with lower rib sagittal angles (Table 2). Figure 4 shows the relationships between pelvic incidence, T4-T12 kyphosis, SPI and rib cage volume. The association between PI and TC volume varied in opposite manners before and after skeletal maturation, with a -0.2 correlation among growing group and 0.5 in the mature group.

Analysis according to Roussouly's classification revealed significantly larger rib cage volume and thickness for types 1 and 3, along with lower SPI (Table 3). Relative sagittal angle of lower ribs was significantly greater in type 4 compared to type 1 ($p = 0.02$).

Analysis according to age

Cohort characteristics by age are reported in Table 1. Age was significantly correlated to pelvic tilt, sacral slope, LL, TK and spinal length (Table 4). PI, PT and spinal length increased with age among growing subjects while SS, LL and spinal length decreased in mature group, along with PT and TK augmentation. No significant differences were exhibited between Young, Middle-aged and Senior groups regarding TC volume and width, whereas children and adolescents had significantly lower volume and width values than older

subjects ($p < 0.02$, not shown). Thickness increased significantly with age between all subgroups except for young compared to adolescents ($p = 0.12$) and middle-aged compared to seniors ($p = 0.26$, not shown). SPI significantly decreased after 20 years old ($p < 0.001$) with no variation between children and adolescents. During growth, TC thickness, volume and width correlated with age (respectively, 0.47, 0.73, 0.73, $p < 0.001$). However, only thickness and SPI significantly changed after skeletal maturity (respectively, 0.39 and -0.52, $p < 0.001$). None of these parameters significantly varied between middle-aged and seniors (Fig. 5).

Absolute sagittal angles did not vary with age; however, relative sagittal angle showed negative correlation with age in skeletally mature subjects, with coefficients at, respectively, -0.52, -0.35, and -0.23 for upper, middle and lower ribs ($p < 0.001$). A negative correlation was found between TC Thickness and relative sagittal angles (-0.71, $p < 0.001$). Umbrella angles showed no correlation to age in the whole cohort, whereas children had significantly higher angles than the three older groups considering middle and lower ribs (not shown). All rib parameters are represented in Fig. 6.

Analysis according to gender

Male subjects presented larger TC in terms of thickness, width and volume ($p < 0.001$, Table 5). Female subjects had higher SPI than males ($p < 0.001$). In accordance, they had lower T1-T12 kyphosis than males with $45.3 \pm 10.7^\circ$ versus $49.9 \pm 10.5^\circ$ ($p = 0.0002$). Relative sagittal angles at all

Fig. 4 Relationship between pelvic incidence, rib cage volume, T4-T12 kyphosis and spinal penetration index. Colors indicate subject age. Correlations are shown separately for growing subjects (age ≤ 19 years, red dashed lines) and mature subjects (age > 19 , black dashed lines)

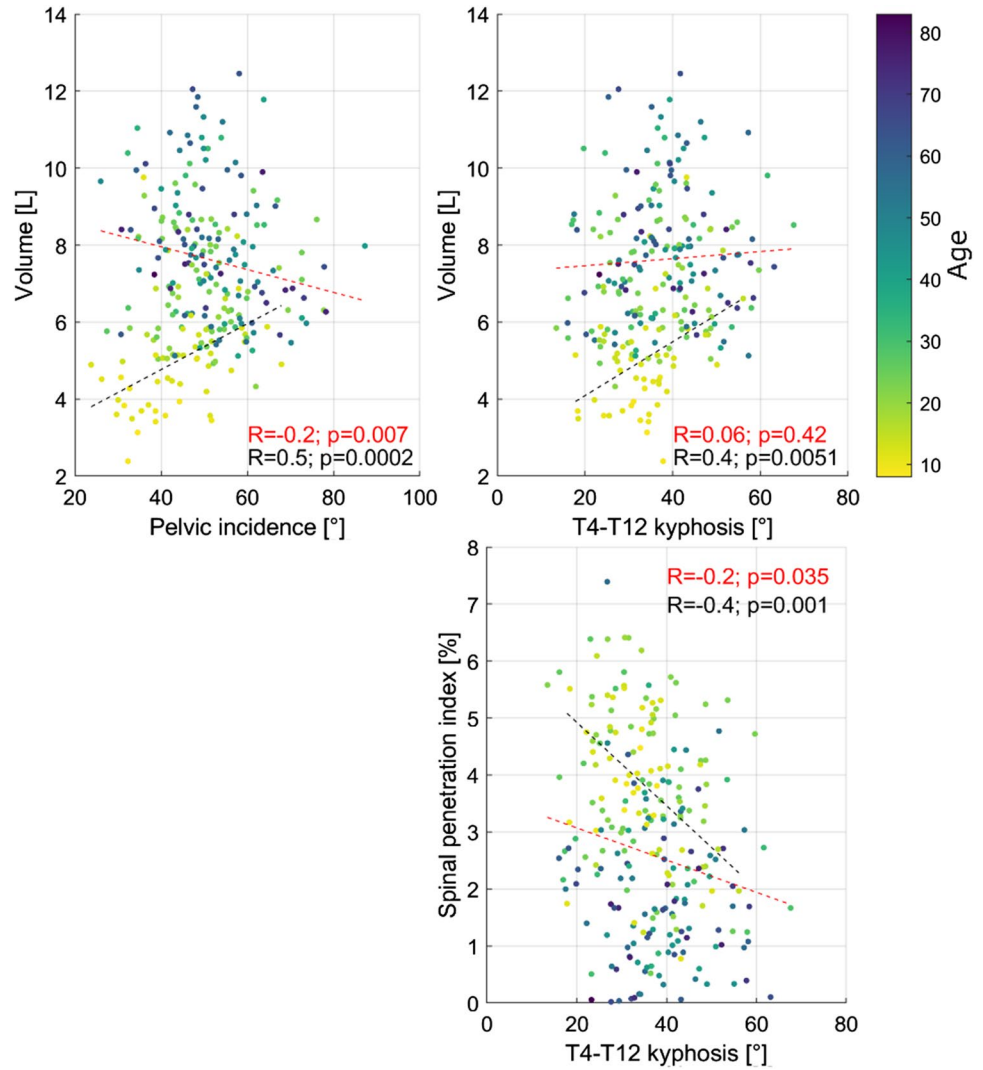


Table 3 Quantitative results of rib and thoracic cage parameters according to the five types of Roussouly's classification. *P* values resulting from ANOVA are given, marked with a "*" if significant. Abs.—Absolute. Rel.—Relative. 3A—Type 3 anteverted. SPI—Spinal penetration index

Roussouly type	1 (n=73)	2 (n=13)	3 (n=91)	3A (n=26)	4 (n=53)	<i>p</i>
Upper ribs	37 ± 6	35 ± 7	37 ± 6	37 ± 8	36 ± 7	0.70
Abs. sagittal angle						
Middle ribs	38 ± 6	37 ± 8	38 ± 6	38 ± 7	37 ± 6	0.65
Abs. sagittal angle						
Lower ribs	46 ± 5	45 ± 7	45 ± 5	46 ± 6	44 ± 5	0.30
Abs. sagittal angle						
Upper ribs	17 ± 8	22 ± 9	19 ± 8	21 ± 7	20 ± 9	0.08
Rel. sagittal angle						
Middle ribs	35 ± 8	37 ± 10	36 ± 8	38 ± 9	38 ± 8	0.20
Rel. sagittal angle						
Lower ribs	56 ± 7	56 ± 8	58 ± 7	59 ± 7	60 ± 7	0.02*
Rel. sagittal angle						
SPI	2.2 ± 1.8	3.2 ± 2.2	3.0 ± 1.8	3.7 ± 1.8	3.3 ± 1.5	< 0.001*
Volume	7569 ± 2144	5960 ± 2316	7141 ± 1718	5808 ± 2216	6717 ± 1565	< 0.001*
Thickness	169 ± 27	152 ± 26	165 ± 21	148 ± 26	158 ± 24	0.001*

Italics was used to describe *p*-values

Table 4 Correlation table between spinopelvic parameters and age. Pearson coefficients for the growing (age 8–19 years) and mature skeleton (age > 19) groups are reported, with corresponding p values (marked with a "*" if significant)

Correlation with Age	Growing	<i>p</i> -value	Mature	<i>p</i> value
Pelvic incidence	0.25	0.03*	0.06	0.40
Pelvic tilt	0.26	0.02*	0.41	<0.001*
Sacral slope	0.06	0.61	-0.24	<0.001*
L1-S1 Lordosis	-0.04	0.73	-0.27	<0.001*
T1-T12 Kyphosis	0.12	0.31	0.29	<0.001*
Curvilinear spinal length	0.78	<0.001*	-0.18	0.02*

Italics was used to describe *p*-values

rib levels were also higher in female subjects ($p < 0.001$, Table 5). There were no significant differences between genders regarding absolute sagittal angles and umbrella angles, except for lower ribs in terms of umbrella angles ($p = 0.0002$). Multivariate analysis showed that spinal length was a determinant of rib cage volume, rather than gender. More specifically, a change of gender induced a change of 1000 cm^3 [700; 1350 CI] in rib cage volume while a change of T1-T5 spinal length from 290 to 490 mm induced a change of 7300 cm^3 [6740; 8230 CI].

Discussion

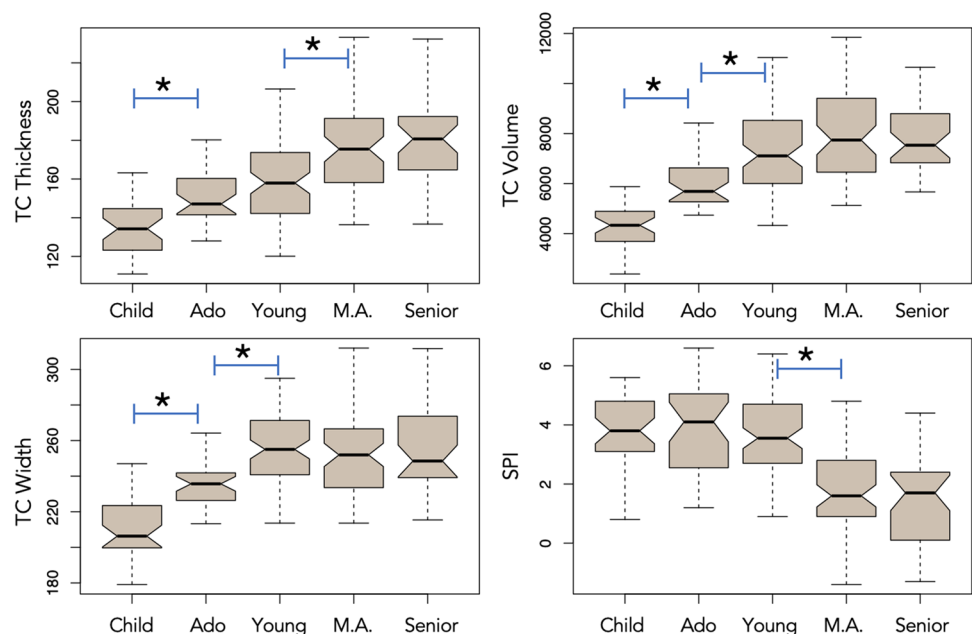
This study gives an insight on the correlation between rib cage anatomy and spinal and pelvic parameters. For instance, higher thoracic kyphosis and lumbar lordosis were both associated with lower SPI and higher TC thickness,

TC volume and rib absolute sagittal angles. TK was correlated with upper and middle ribs while lumbar lordosis presented correlations with lower ribs. Pelvic tilt showed correlations with several thoracic parameters: a higher pelvic tilt was correlated with higher TC thickness, higher rib relative sagittal angles and lower SPI. Pelvic incidence and sacral slope were negatively correlated with TC volume. This confirms the hypothesis of the study that the thoracic cage and spine anatomy are linked to each other, but also that the rib cage is an integral part of the spinopelvic chain of balance. Hence, spine, pelvis and rib cage should not be considered separately.

Expectedly, thoracic kyphosis showed stronger relationships with rib cage anatomy than lumbar lordosis. Indeed, thoracic spine presents anatomical joints with the ribs, and an increase in the first, leads to rising TC thickness and rib sagittal angles, particularly in the upper cage. Thoracic kyphosis was more strongly correlated to rib cage than to pelvic parameters. Lumbar lordosis was correlated with lower ribs, probably as it is directly influencing lower thoracic spine. Its correlations were stronger with pelvic parameters than rib cage ones. Pelvic incidence and sacral slope showed weak correlations with rib cage anatomy parameters. Among pelvic parameters, pelvic tilt was the most strongly associated with rib cage anatomy, especially TC thickness. This could be a compensation mechanism to compensate the forward shift of the gravity line due to an increase in TC thickness, with a posterior displacement driven by the increase in pelvic tilt.

This study describes for the first time the correlation between rib cage and spinopelvic anatomy in upright position, with respect to age and gender. Bi-planar radiography

Fig. 5 Boxplot representations of spinal penetration index (SPI), thoracic cage Volume, Width and Thickness according to age. Each subscript letter denotes a subset of subjects whose values do not differ significantly from each other at the 0.05 level. Age brackets: Children (8–12 years), Adolescents (13–19), Young (20–39), Middle-aged (M.A.: 40–59) and Seniors (60+)



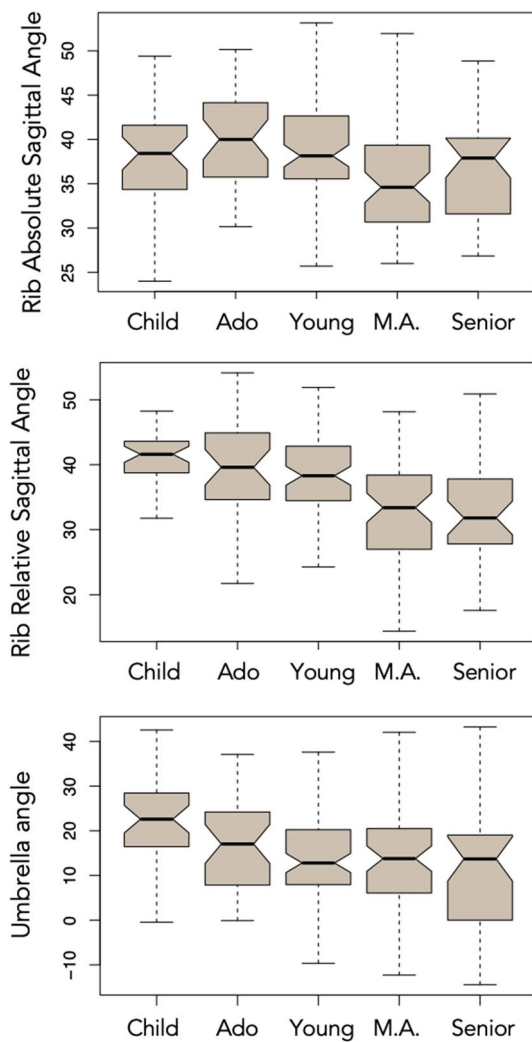


Fig. 6 Boxplot representations of absolute and relative sagittal angles and umbrella angles according to age. Age brackets: Children (8–12 years), Adolescents (13–19), Young (20–39), Middle-aged (M.A.: 40–59) and Seniors (60+)

has been more largely used to analyze rib cage in adolescent idiopathic scoliosis patients [24]. This technique offers several advantages such as radiation reduction for the subject—compared to CT-scan—and analysis in standing position [25]. Indeed, it has been proven in spine care that prone position can significantly alter spine morphology compared to standing position, thus bias sagittal alignment assessment [16]. More, in lying position, lung volumes—functional residual capacity and forced vital capacity—are smaller due to cephalic displacement of the diaphragm, a consequence of increased abdominal pressure, as well as increased pulmonary blood volume. This reduction in the lung volume in the recumbent position is correlated to a reduction in elastic recoil of the lungs and the chest wall and a modification of ribs orientations, which could both modify the forces applied to the thoracic cage and spinal curvatures [26]. Corroborating

further the association between rib cage and spine, Bouloussa et al. exhibited correlations between rib cage volume measured using bi-planar radiography and all pulmonary capacities (total lung, slow and forced vital capacities) in an adolescent idiopathic scoliosis population [19].

Adult spinal deformity patients present spine and thoracic cage deformity. However, surgical treatment of these patients usually focuses on the spine, including the restoration of thoracic kyphosis. This has an indirect effect on pelvic tilt through compensatory mechanism to maintain sagittal balance [3]. Given the significant anatomical relationships between pelvis, spine and rib cage, the latter should not be overlooked. However, the potential changes induced by spinal surgery on the rib cage are not well studied. Correction-fusion surgeries, through spinal deformity and kyphosis correction might have consequences on TC anatomy and pulmonary function. Therefore, a failure in restoring spinal physiological curvatures could lead to pulmonary dysfunction as it is known that respiratory function and spinal anatomy are linked.

Aging has been proven to modify spinal alignment [27], increase rib fracture risk [28], and alter respiratory function. One CT-scan-based study have analyzed changes in aging rib cage morphology. In that study, Weaver et al. reported significant changes in aging thoracic cage [15], which appear consistent with the present results. Both studies observed an increase in ribs sagittal angle during growth, then a decrease until adulthood and a further increase during aging (Fig. 6). However, relative rib orientations in the previous study were computed in supine position, according to the rib itself, whereas angles were computed relative to the vertebra in the present study. Hence, this relative angle represents the orientation of the costovertebral junction. This relative angle in the sagittal plane decreased with age, with a sharp decrease during adulthood (Fig. 6). Thoracic kyphosis increases with age, due to degenerative phenomena of the spine: bone remodeling, degenerating disks and facet joints along with sarcopenia. It appears that thoracic vertebrae tend to rotate forward while the ribs rotate upwards. This phenomenon may be explained, through a contribution of the costovertebral joints, as a prevention of TC subsidence into the abdomen, in order to maintain sufficient TC volume for respiratory function. The results of the present study corroborate Weaver et al. conclusions [15]. Indeed, it was found that the thoracic cage ages mainly through increasing its anteroposterior diameter (thickness) which is logically correlated with increasing thoracic kyphosis; hence augmenting TC osseous volume. Thickness grows constantly, whereas width increased only during skeletal maturation. Conversely, SPI seemed to be more specific of aging as it starts decreasing after adolescence. This phenomenon increases as well TC volume as thoracic spine occupies less space within the rib cage. These variations may be explained

Table 5 Quantitative results of thoracic cage morphology and spinopelvic parameters according to gender. Results are expressed by mean \pm standard deviation

	Females	Males	<i>p</i> value
Age	32.8 \pm 20.3	35.6 \pm 19.8	0.27
<i>Rib cage parameters</i>			
TC Volume	5967.3 \pm 1332.1	8202.8 \pm 1930.1	< 0.001*
TC Thickness	153.5 \pm 22.1	172.3 \pm 23.7	< 0.001*
TC Width	232.6 \pm 19.4	261.4 \pm 23.4	< 0.001*
SPI	3.43 \pm 1.67	2.24 \pm 1.72	< 0.001*
Upper ribs relative sagittal angle	21.6 \pm 7.7	16.3 \pm 7.6	< 0.001*
Middle ribs relative sagittal angle	38.4 \pm 7.7	34.4 \pm 8.1	< 0.001*
Lower ribs relative sagittal angle	58.8 \pm 7.4	56.2 \pm 7.1	< 0.001*
Upper ribs absolute sagittal angle	36.9 \pm 6.1	36.4 \pm 6.7	0.50
Middle ribs absolute sagittal angle	37.2 \pm 6.0	37.6 \pm 6.0	0.62
Lower ribs absolute sagittal angle	67.3 \pm 8.1	68.6 \pm 8.2	0.22
Upper ribs umbrella angle	24.5 \pm 10.0	23.4 \pm 10.8	0.40
Middle ribs umbrella angle	16.1 \pm 12.3	13.4 \pm 11.9	0.07
Lower ribs umbrella angle	28.1 \pm 9.8	23.5 \pm 9.6	0.0002*
<i>Spinopelvic parameters</i>			
Pelvic Incidence	50.3 \pm 11.6	48.5 \pm 10.2	0.17
Pelvic Tilt	10.6 \pm 7.7	11.0 \pm 7.2	0.71
Sacral Slope	39.7 \pm 8.8	37.5 \pm 8.2	0.04*
L1-S1 Lordosis	59.4 \pm 11.2	54.6 \pm 11.5	0.0008*
T1-T12 Kyphosis	45.3 \pm 10.7	49.9 \pm 10.5	0.0002*
T1-L5 curvilinear length	401.3 \pm 31	437.6 \pm 31	< 0.001*

Italics was used to describe *p*-values

by aging phenomena of lungs with diminution of reserve volumes which impact rib cage anatomy as well as weakened inspiratory muscles, leading to decreased vital capacity [12]. Indeed, in healthy subjects, aging is associated with changes in thoraco-pulmonary mechanical properties [29, 30]. Whether this may explain the noticeable differences observed on thoracic parameters in the senior group remains to be studied.

Differences between gender specifics were also observed. Females had more penetrating spines into the rib cage (higher SPI), ribs sloping more downward (higher rib relative sagittal angles), associated with smaller TK than male subjects. Males presented larger thoracic cages in terms of width, thickness and volume. These differences between genders mainly lie in the size difference between males and females as demonstrated by multivariate analysis, with a body size effect seven times higher than gender effect.

Limitations

This study analyzed transversally a cohort of healthy subjects. A longitudinal study would overrule the risk of selection bias and may allow more accurate description of aging phenomena. Another limitation of this study is the absence of anthropometric data and pulmonary function tests, such as functional

residual volume, to be correlated with radiological anatomy. New inter-disciplinary longitudinal studies would be interesting to further analyze relationships between rib cage and spine, and correlate anatomical features with functional data.

Conclusion

The results of this study demonstrate the correlation between thoracic cage anatomy and spinopelvic parameters, confirming that rib cage can be considered as a part of the spinopelvic chain of balance. Indeed, higher spinal curvatures were associated with lower SPI and higher TC thickness, TC volume and rib absolute sagittal angles. Furthermore, rib cage anatomy is also related to age and gender. Males have larger thoracic cages in terms of width, thickness, and volume while females have higher SPI and ribs relative sagittal angles. TC mainly ages through an increase in anteroposterior diameter and decrease in SPI. These results suggest that thoracic cage could be taken into account when addressing sagittal alignment issue as trunk anteroposterior diameter evolves. Further studies including pulmonary function tests in adult spinal deformity patients could help spine surgeons improve surgical management.

Funding No funding.

Availability of data and material Data will not be deposited.

Declarations

Conflicts of interest No conflicts to declare by any of the authors.

References

1. LegayeDuval-BeaupreHecquetMarty JGJC (1998) Pelvic incidence: A fundamental pelvic parameter for three-dimensional regulation of spinal sagittal curves. *Eur Spine J* 7:99–103. <https://doi.org/10.1007/s005860050038>
2. Iyer S, Lenke LG, Nemani VM, et al (2016) Variations in sagittal alignment parameters based on age: a prospective study of asymptomatic volunteers using full-body radiographs. *Spine (Phila Pa 1976)* 41: 1826–1836. <https://doi.org/10.1097/BRS.00000000000001642>
3. Barrey C, Roussouly P, Le Huec J-C et al (2013) Compensatory mechanisms contributing to keep the sagittal balance of the spine. *Eur Spine J* 22(Suppl 6):S834–S841. <https://doi.org/10.1007/s00586-013-3030-z>
4. Beyer G, Khalifé M, Lafage R, et al (2020) Pelvic compensation in sagittal malalignment: how much retroversion can the pelvis accommodate? *Spine (Phila Pa 1976)* 45:E203–E209. <https://doi.org/10.1097/BRS.0000000000003228>
5. Liebsch C, Graf N, Appelt K, Wilke H-J (2017) The rib cage stabilizes the human thoracic spine: an in vitro study using stepwise reduction of rib cage structures. *PLoS ONE* 12:e0178733. <https://doi.org/10.1371/journal.pone.0178733>
6. Ignasiak D, Dendorfer S, Ferguson SJ (2016) Thoracolumbar spine model with articulated ribcage for the prediction of dynamic spinal loading. *J Biomech* 49:959–966. <https://doi.org/10.1016/j.jbiomech.2015.10.010>
7. Clavel L, Attali V, Rivals I et al (2020) Decreased respiratory-related postural perturbations at the cervical level under cognitive load. *Eur J Appl Physiol* 120:1063–1074. <https://doi.org/10.1007/s00421-020-04345-1>
8. Hodges PW, Gurfinkel VS, Brumagne S et al (2002) Coexistence of stability and mobility in postural control: evidence from postural compensation for respiration. *Exp Brain Res* 144:293–302. <https://doi.org/10.1007/s00221-002-1040-x>
9. Dally JF (1908) An inquiry into the physiological mechanism of respiration, with especial reference to the movements of the vertebral column and diaphragm. *J Anat Physiol* 43:93–114
10. Attali V, Clavel L, Rouch P et al (2019) Compensation of respiratory-related postural perturbation is achieved by maintenance of head-to-pelvis alignment in healthy humans. *Front Physiol* 10:1–10. <https://doi.org/10.3389/fphys.2019.00441>
11. Mac-Thiong J-M, Roussouly P, Berthonnaud E, Guigui P (2011) Age- and sex-related variations in sagittal sacropelvic morphology and balance in asymptomatic adults. *Eur Spine J* 20(Suppl 5):572–577. <https://doi.org/10.1007/s00586-011-1923-2>
12. Turner JM, Mead J, Wohl ME (1968) Elasticity of human lungs in relation to age. *J Appl Physiol* 25:664–671. <https://doi.org/10.1152/jappl.1968.25.6.664>
13. Assi A, Karam M, Skalli W et al (2021) A Novel Classification of 3D Rib Cage Deformity in Subjects With Adolescent Idiopathic Scoliosis. *Clin spine Surg*. <https://doi.org/10.1097/BSD.0000000000001139>
14. Holcombe SA, Wang SC, Grotberg JB (2017) The effect of age and demographics on rib shape. *J Anat* 231:229–247. <https://doi.org/10.1111/joa.12632>
15. Weaver AA, Schoell SL, Stitzel JD (2014) Morphometric analysis of variation in the ribs with age and sex. *J Anat* 225:246–261. <https://doi.org/10.1111/joa.12203>
16. Yeung KH, Man GCW, Lam TP et al (2020) Accuracy on the preoperative assessment of patients with adolescent idiopathic scoliosis using biplanar low-dose stereoradiography: a comparison with computed tomography. *BMC Musculoskelet Disord* 21:558. <https://doi.org/10.1186/s12891-020-03561-2>
17. Delin C, Silvera S, Bassinet C et al (2014) Ionizing radiation doses during lower limb torsion and anteversion measurements by EOS stereoradiography and computed tomography. *Eur J Radiol* 83:371–377. <https://doi.org/10.1016/j.ejrad.2013.10.026>
18. Courvoisier A, Vialle R, Skalli W (2014) EOS 3D imaging: assessing the impact of brace treatment in adolescent idiopathic scoliosis. *Expert Rev Med Devices* 11:1–3. <https://doi.org/10.1586/17434440.2014.848166>
19. Bouloussa H, Pietton R, Vergari C et al (2019) Biplanar stereoradiography predicts pulmonary function tests in adolescent idiopathic scoliosis: a cross-sectional study. *Eur Spine J* 28:1962–1969. <https://doi.org/10.1007/s00586-019-05940-3>
20. Janssen MMA, Drevelle X, Humbert L, et al (2009) Differences in male and female spino-pelvic alignment in asymptomatic young adults: a three-dimensional analysis using upright low-dose digital biplanar X-rays. *Spine (Phila Pa 1976)* 34: E826–32. <https://doi.org/10.1097/BRS.0b013e3181a9fd85>
21. Humbert L, De Guise JA, Aubert B et al (2009) 3D reconstruction of the spine from biplanar X-rays using parametric models based on transversal and longitudinal inferences. *Med Eng Phys* 31:681–687. <https://doi.org/10.1016/j.medengphy.2009.01.003>
22. Vergari C, Aubert B, Lallemand-Dudek P et al (2020) A novel method of anatomical landmark selection for rib cage 3D reconstruction from biplanar radiography. *Comput Methods Biomech Biomed Eng Imaging Vis* 8:15
23. Laouissat F, Sebaaly A, Gehrchen M, Roussouly P (2018) Classification of normal sagittal spine alignment: refounding the Roussouly classification. *Eur Spine J* 27:2002–2011. <https://doi.org/10.1007/s00586-017-5111-x>
24. Ilharreborde B, Dubouset J, Le Huec J-C (2014) Use of EOS imaging for the assessment of scoliosis deformities: application to postoperative 3D quantitative analysis of the trunk. *Eur Spine J* 23(Suppl 4):S397–405. <https://doi.org/10.1007/s00586-014-3334-7>
25. Melhem E, Assi A, El Rachkidi R, Ghanem I (2016) EOS(®) biplanar X-ray imaging: concept, developments, benefits, and limitations. *J Child Orthop* 10:1–14. <https://doi.org/10.1007/s11832-016-0713-0>
26. Katz S, Arish N, Rokach A et al (2018) The effect of body position on pulmonary function: a systematic review. *BMC Pulm Med* 18:159. <https://doi.org/10.1186/s12890-018-0723-4>
27. Diebo BG, Ferrero E, Lafage R, et al (2015) Recruitment of compensatory mechanisms in sagittal spinal malalignment is age and regional deformity dependent: a full-standing axis analysis of key radiographical parameters. *Spine (Phila Pa 1976)* 40: 642–9. <https://doi.org/10.1097/BRS.0000000000000844>
28. Kent R, Woods W, Bostrom O (2008) Fatality risk and the presence of rib fractures. *Ann Adv Automot Med Assoc Adv Automot Med Annu Sci Conf* 52:73–82
29. Verbeken EK, Cauberghe M, Mertens I et al (1992) The senile lung. Comparison with normal and emphysematous lungs. 2. *Funct Asp Chest* 101:800–809. <https://doi.org/10.1378/chest.101.3.800>

30. Galetke W, Feier C, Muth T et al (2007) Reference values for dynamic and static pulmonary compliance in men. *Respir Med* 101:1783–1789. <https://doi.org/10.1016/j.rmed.2007.02.015>