



### **Science Arts & Métiers (SAM)**

is an open access repository that collects the work of Arts et Métiers Institute of Technology researchers and makes it freely available over the web where possible.

This is an author-deposited version published in: <https://sam.ensam.eu>  
Handle ID: [.http://hdl.handle.net/10985/24024](http://hdl.handle.net/10985/24024)

#### **To cite this version :**


Mathilde GAUME, Tristan LANGLAIS, Klervie LOISELET, S. PANNIER, Wafa SKALLI, Claudio VERGARI, Lotfi MILADI - Spontaneous induced bone fusion in minimally invasive fusionless bipolar fixation in neuromuscular scoliosis: a computed tomography analysis - European Spine Journal - Vol. 32, p.2550-2557 - 2023

Any correspondence concerning this service should be sent to the repository

Administrator : [scienceouverte@ensam.eu](mailto:scienceouverte@ensam.eu)



# Spontaneous induced bone fusion in minimally invasive fusionless bipolar fixation in neuromuscular scoliosis: a computed tomography analysis

M. Gaume<sup>1,2</sup>  · T. Langlais<sup>1,2</sup> · K. Loiselet<sup>3</sup> · S. Pannier<sup>1</sup> · W. Skalli<sup>2</sup> · C. Vergari<sup>2</sup> · L. Miladi<sup>1</sup>

## Abstract

**Purpose** Posterior spinal fusion (PSF) at skeletal maturity is still the gold standard in children with neuromuscular scoliosis (NMS) who underwent fusionless surgery. The aim of this computed tomography (CT) study was to quantify the spontaneous bone fusion at the end of a lengthening program by minimally invasive fusionless bipolar fixation (MIFBF), that could avoid PSF.

**Methods** NMS operated on with MIFBF from T1 to the pelvis and at final lengthening program were included. CT was performed at least five years postoperatively. The autofusion was classified as completely or not fused at the facets joint (on both coronal and sagittal plane, right and left side, from T1 to L5), and around the rods (axial plane, right and left side, from T5 to L5). Vertebral body heights were assessed.

**Results** Ten patients were included ( $10.7y \pm 2$  at initial surgery). Mean Cobb angle was  $82 \pm 20$  preoperatively and  $37 \pm 13$  at last follow-up. CT were performed on average  $6.7y \pm 1.7$  after initial surgery. Mean preoperative and last follow-up thoracic vertebrae height were respectively  $13.5 \text{ mm} \pm 1.7$  and  $17.4 \text{ mm} \pm 1.7$  ( $p < 0.001$ ). 93% facets joints were fused (out of 320 analyzed joints), corresponding to 15/16 vertebral levels. Ossification around the rods was observed in  $6.5 \pm 2.4$  levels out of 13 in the convex side, and  $4.2 \pm 2.2$  in the concave side ( $p = 0.04$ ).

**Conclusions** This first computed quantitative study showed MIFBF in NMS preserved spinal growth, while it induced 93% of facet joints fusion. This could be is an additional argument when questioning the real need for PSF at skeletal maturity.

**Keywords** Neuromuscular scoliosis · Fusionless bipolar technique · Spinal stiffness · Autofusion · Posterior spinal fusion

## Introduction

Neuromuscular spinal deformities are related to abnormality in muscle tone and trunk imbalance, which can cause a loss of sitting ability. They often start in the first years of life [1, 2]. When conservative treatment is no more effective,

various surgical strategies are proposed for the treatment of children with neuromuscular scoliosis (NMS) [3].

Early posterior spinal fusion (PSF) can cause growth inhibition and has negative effect on pulmonary function in young children, with decreased vital capacity and restricted pulmonary disease [4, 5]. Moreover, it does not arrest progression of the spine deformity even after anterior and posterior fusion [6, 7]. Difficulty in curve control after early fusion may be explained by crankshaft phenomenon defined as worsening of rotational deformity in young patients with solid posterior fusions resulting from persistent anterior growth of the vertebral bodies [8]. Zhang et al. [9] also suggested the role of neurocentral synchondroses that creates a scoliotic deformity in growing-animal model correlated with the degree of closure of the synchondrosis.

Another treatment option is fusionless surgery which is considered more physiologic as it preserves the growth and motion of the spine and chest. Innovative fusionless

---

✉ M. Gaume  
mathilde.gaume@aphp.fr

<sup>1</sup> Pediatric Orthopedic Surgery Department, Necker University Hospital, APHP, University of Paris-Cité, 149 rue de Sevres, 75015 Paris, France

<sup>2</sup> Arts et Métiers Institute of Technology, Institut de Biomécanique Humaine Georges Charpak, Université Sorbonne Paris Nord, Paris, France

<sup>3</sup> Pediatric Radiology Department, Necker University Hospital, APHP, University of Paris-Cité, Paris, France

techniques have been developed over the past decades (traditional and magnetically controlled growing rods, vertebral body tethers ...) with satisfactory results [10, 11]. However, the management at the end of the lengthening program is still controversial. Balsano et al. [12] recommend PSF at skeletal maturity even in case of good and satisfying final correction. The complication rate after such final fusion following traditional growing rods program is nevertheless high, reaching 20% in Poe-Kochert et al. [13] series. Moreover, PSF has a low effect on spinal deformity improvement and usually achieved < 50% additional correction of the deformity remaining at the end of the growing rod management [14]. Risk factors for reoperation following final fusion after GR program have been studied by Du et al. [15]. On the contrary, Jain et al. [16] avoided PSF in patients who have satisfactory final alignment and trunk height, a minimal gain in length at the last distraction and no clinical or radiographic evidence of implant-related problems. Bouthors et al. [17] considered retaining dual GR instead of PSF in patients at skeletal maturity with satisfactory deformity correction.

Recently, Gaume et al. [18] reported their results and complications of 100 neuromuscular patients with a mean follow-up of  $6.5 \pm 0.7$  years after minimally invasive fusionless bipolar fixation. PSF was not performed for any patient due to the stability of the construct and of the results over time and the hypothesis of a progressive ankylosis of the spine.

However, there are presently no objective imaging data supporting the quantity of auto fusion of the spine to guide in the decision of final PSF. The aim of this study was to evaluate growth and bone fusion on computed tomography at the final lengthening program.

## Patients and methods

### Patients

A total of 13 neuromuscular children who underwent a typical MIFBF and reached the end of their lengthening program were included. They all had a preoperative thoracic CT scan, and a thoraco-lumbo-pelvic computed tomography scans (TAP-CT) that was indicated for other health diseases excluding spinal disorder. The TAP-CT was performed after a minimum of 5 years follow-up after MIFBF. TAP-CT scan was not performed as a routine for the follow-up of NMS patients because of the risk of irradiation [19].

### Operative technique

The minimally invasive FBF technique was described in a previous paper [20]. Briefly, this construct has a proximal

foundation with two pairs of hook claws [21] and caudally a foundation with a rigid fixation with two ilio-sacral screws [22–24]. The longitudinal members consist of four Titanium rods overlapping caudally where the rods are coupled with connectors and here, the repetitive distractions are performed (Fig. 1).

The study was approved by the appropriate ethics committee (CPP, ID-EUDRACT #2014 A019043 44). Informed consent was obtained from parents/guardians of all participants.

### Methods of assessment

Collected clinical data included age at first surgery, sex, diagnosis, number of lengthening procedures, duration of follow-up, and complications. Patients underwent helical TAP-CT with 1.25 mm slice thickness. Facet joints between T1 and L5 were classified as completely or not fused by analyzing them on coronal and sagittal plane at all vertebral levels. A fusion score was defined as the percentage of number of fused facet joint/number of facet joints  $\times 100$ .

The rod induced ossification was assessed on axial plane at each spinal level below the proximal fixation, from T5 to L5, on the concave and convex sides.

Thoracic and lumbar vertebral height, from T1 to L5, as well as discal height, before and at latest follow-up were calculated as the mean of maximal anterior, posterior, left and right height in sagittal and coronal plane [25]. These measurements were compared to values obtained from the literature for healthy subjects [26].

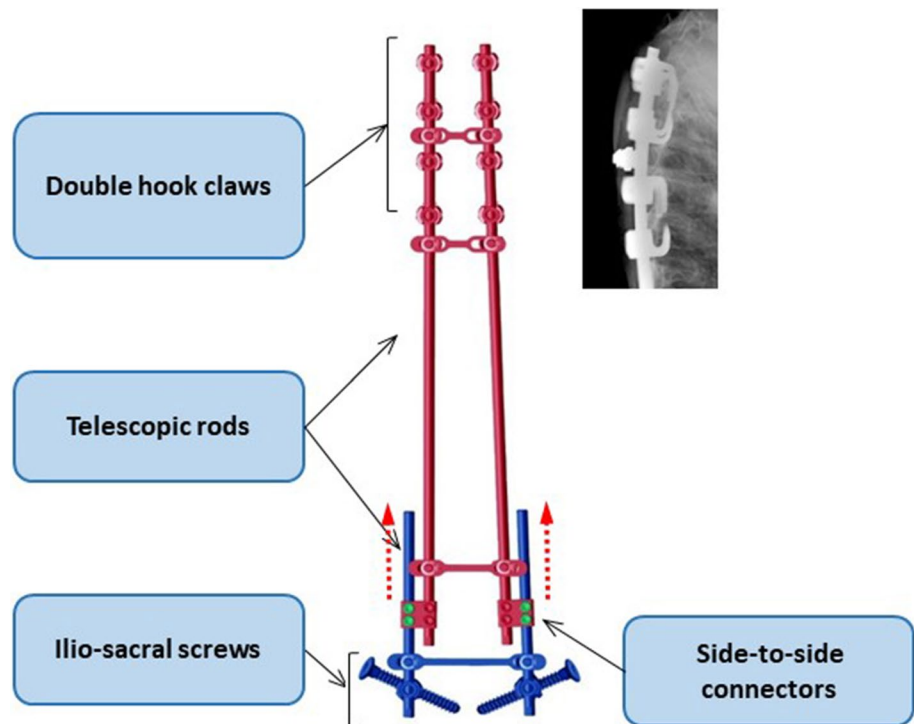
All measurements were repeated by two experienced orthopedic surgeons using Carestream Vue PACS software (Carestream Health). Blind comparison between the two observers was performed to assess the reliability of the method. Discrepancies were resolved by consensus.

Additional analyses were reviewed before surgery and at last follow-up: major curve angle according to the Cobb method on the coronal plane [27], pelvic obliquity, thoracic kyphosis (T4-T12) and lumbar lordosis (L1-S1) on sagittal plane.

### Statistical analysis

Continuous variables were presented as mean (Standard Deviation). The normality was verified with the Shapiro–Wilk test, and differences were analyzed by the student's paired t test or Wilcoxon signed-rank test if the normality condition was not verified. Alpha risk was set to 5% ( $\alpha=0.05$ ). Statistical analysis was performed with EasyMed-Stat (version 3.19; [www.easymedstat.com](http://www.easymedstat.com)).

**Fig. 1** Bipolar construct is anchored proximally with two pairs of hooks claws and caudally with two ilio-sacral screws



**Table 1** Pre- and postoperative radiographic parameters

Parameters	Preoperative	Last follow-up	<i>p</i> value
Cobb angle (°)	82 (SD=20)	37 (SD=12)	<0.001
Thoracic kyphosis (°)	48.4(SD=27.2)	32.6 (SD=6.8)	0.09
Lumbar lordosis (°)	40.2 (SD=18.3)	37.4 (SD=10.1)	0.6
Pelvic obliquity (°)	19 (SD=17.5)	0.5 (SD=2.7)	0.002

## Results

### Population

Thirteen patients (seven boys and six girls; six cerebral palsy, three spinal muscular atrophy type 2 and four syndromic) were included with a mean age at surgery of 10.7 years (y) (SD=2y; ranging from 6 to 14.5 y). All patients were Risser 0 at initial surgery. The average follow-up was 9.2y (SD=1.1; ranging from 8 to 11y). Five thoracolumbar scoliosis, three double curve and two thoracic scoliosis were recorded with a mean preoperative Cobb angle of  $82 \pm 19^\circ$  (ranging from 50 to  $118^\circ$ ). Mean pelvic obliquity was  $20 \pm 11^\circ$  preoperatively and  $2 \pm 2^\circ$  at latest follow-up. The preoperative and last follow-up radiographic parameters are reported in Table 1. The number of rod lengthening was on average three per patient (ranging from 1 to 4) with an average interval between procedures of  $1.9 \pm 0.8$  y. The global complication rate was 23% (3 patients). One upper hook

pullout, one hook migration and one deep infection were reported.

### Computed tomography outcomes

Computed tomography was performed on average 6.7 years (SD=1.7y; ranging from 4.5 to 10y) after the first surgical procedure. Patients were  $17.4 \pm 2$ y when the CT scan was performed, and all reached skeletal maturity (Risser 5).

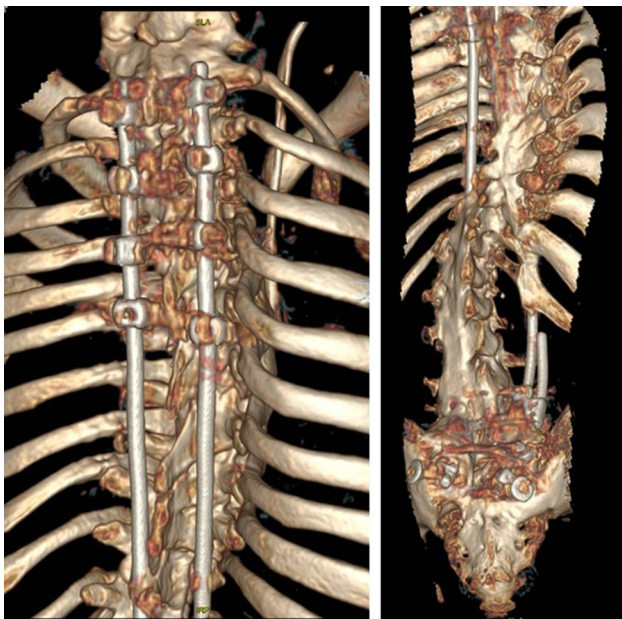
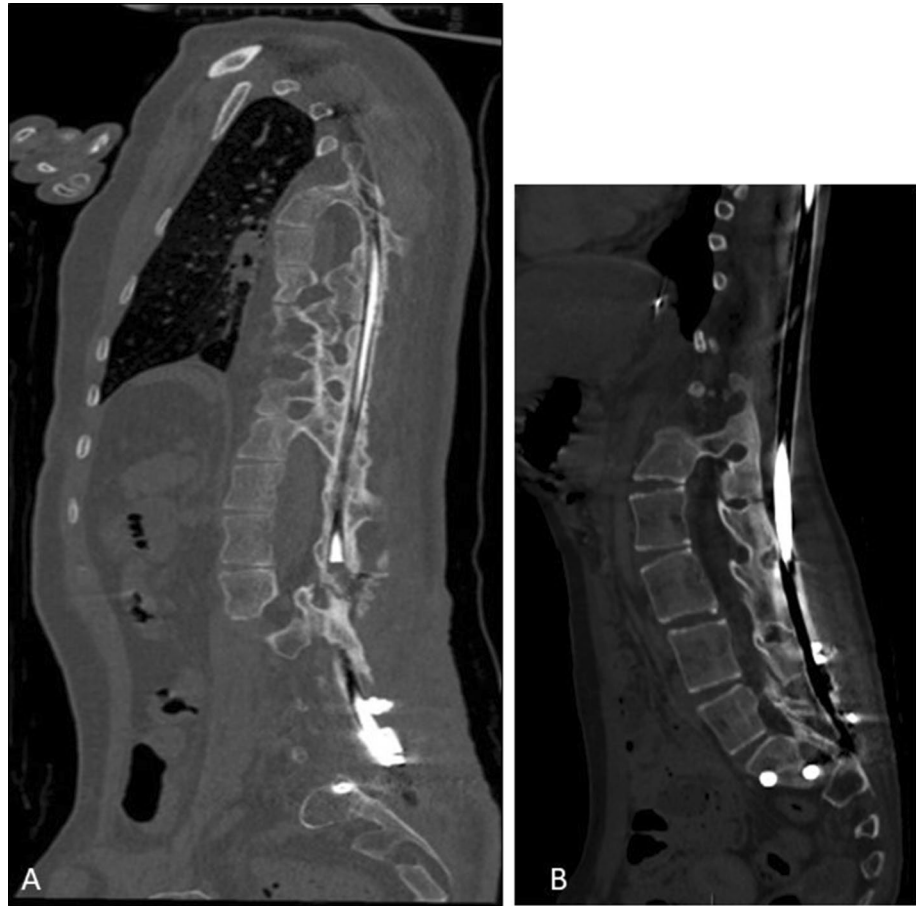The number of levels of facet joints fused was similar on right and left side ( $p=0.7$ ), averaging 15 levels out of 16 (94% of assessed facet joints, ranging 84.3 to 100%).

Mean number of levels with ossification induced by the rod on the convex side and concave side were, respectively, 6.5 (SD=2.4) and 4.2 (SD=2.2) with a mean difference of 2.3 (SD=3.1 CI95%=[0.2; 4.4];  $p=0.04$ ). Ossification around the rods was qualitatively confirmed by CT scan (Fig. 2) and 3D reconstruction of the bone by CT-scan thresholding (Figs. 3, 4).

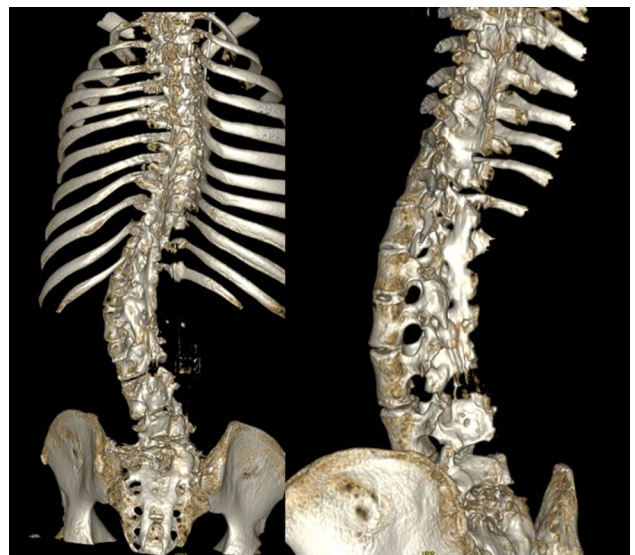
Blind operators agreed on 98% cases of facet joints fusion and 96% of ossifications around the rods.

Mean preoperative and last follow-up thoracic vertebrae height were, respectively, 13.4 mm (SD=1.7) and 17.4 mm (SD=1.7) with a mean difference of  $-4.0$  (SD=1.8; CI95%=[-5.2; -2.7];  $p<0.001$ ). Mean preoperative and last follow-up thoracic intervertebral disk height were, respectively, 3.6 mm (SD=0.2) and 2.0 mm (SD=0.5) with a mean difference of  $-1.5$  (SD=0.6; CI95%=[1.1; 2];  $p<0.001$ ). Mean last follow-up of lumbar vertebrae height

**Fig. 2** A/Sagittal CT scan view with rod induced ossification  
B/Sagittal CT scan view with lumbar joint fusion



**Fig. 3** 3D reconstruction with rod induced ossification and articular joint fusion



**Fig. 4** 3D reconstruction. The rods have been removed to allow a better view of the ossifications

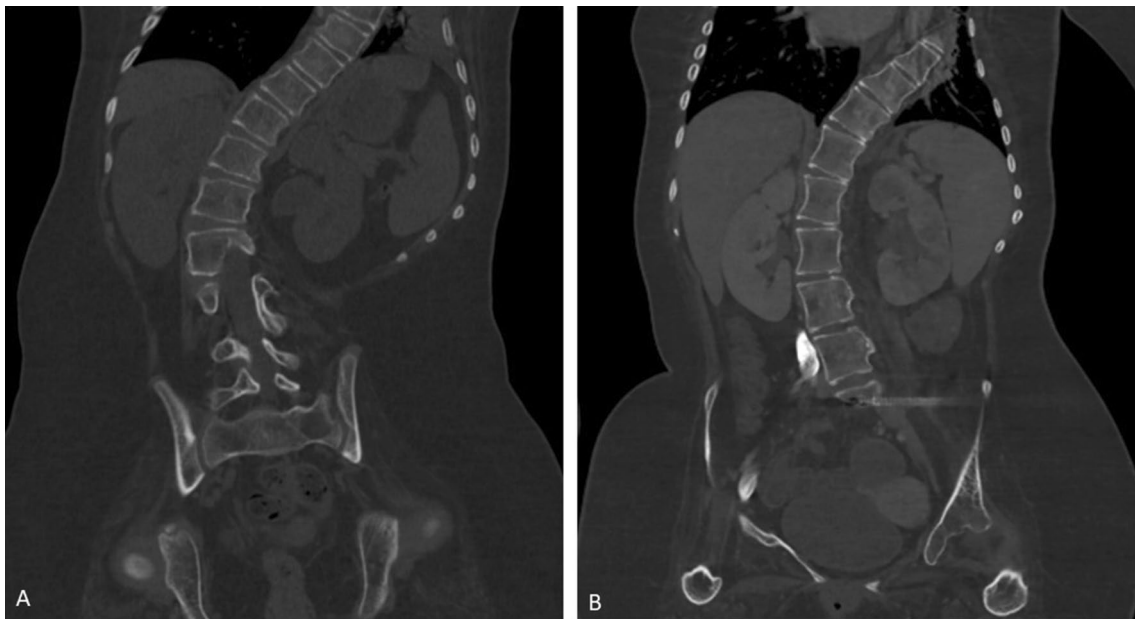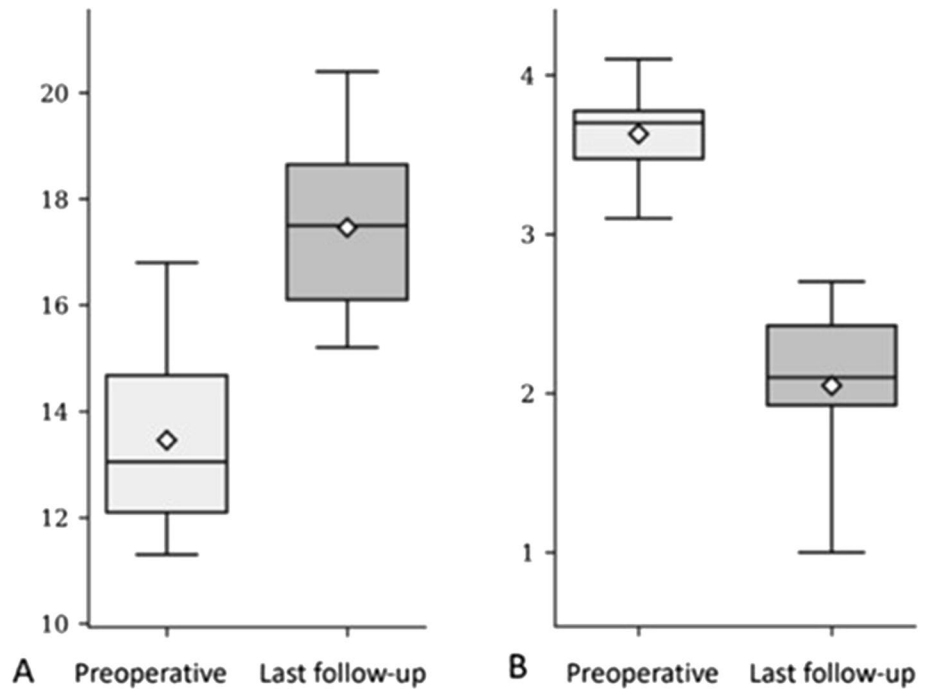
was  $26.0 \pm 2$  mm. (Fig. 5). Vertebral growth can be evaluated when comparing the postoperative and preoperative CT scans. Preoperatively, only thoracic CT scan was available

apart from one patient to whom a TAP-CT scan was performed. Thus, postoperative lumbar height was not available (Fig. 6).

## Discussion

The present computed tomography study is the first to describe and quantify the rate of fusion at the end of MIFBF surgery program. The fusion of facet joints and the induced bone around the rod suggest that the level of

**Fig. 5** **A** Thoracic vertebral height, **B** Thoracic intervertebral disk height



**Fig. 6** **A**/Preoperative and **B**/after 8 years follow-up CT scan of an SMA type 2 patient showing an increase in the thoracic and lumbar vertebral height and a decrease in discal height

---

autofusion which was spontaneously obtained could justify the avoidance of PSF. The analysis of complication rates at medium long-term (6.5 years [18]) corroborates this interpretation. These results may radically change our surgical guidelines for patients with neuromuscular scoliosis.

MIFBF was initially used as an alternative to traditional growing rods to reduce mechanical and infectious complications while waiting for PSF, which was initially planned at skeletal maturity for all patients. However, stable clinical and radiological correction was observed with a reduced rate of mechanical complications [18, 20]. Fibrosis and spontaneous fusion around the implants and along the rods were observed during revision surgeries performed in some patients and had confirmed the absence of the need to perform PSF as initially planned (Fig. 2).

The literature on the physiopathology of such progressive autofusion of the spine is poor. Autofusion was first described in 1984, by Moe et al. [28] who reported spontaneous fusion at the curve extremities and/or at the curve apex in young children treated for severe deformities with subcutaneous Harrington rod without fusion. Mardjetko et al. [29] observed extensive fibrosis and laminar spontaneous fusions under the instrumented regions with Luqué rods, frequently involving the entire thoracic spine but also extending across the thoracolumbar spine. Cahill et al. [30] reported that early autofusion of the spine can be caused by a combination of repeated surgical procedures and spontaneous bone bridging in the immobilized spinal span and occurs in as many as 89% of children treated with growing rods. Early autofusion may also result in diminishing amounts of lengthening, also called 'law of diminishing returns' achieved after rod lengthening as well as the reduced ability to gain deformity correction at the final definitive fusion surgery [31, 32].

In the present study, the autofusion after MIFBF could be related to the increased rigidity of the spine allowed by the strong and stable bipolar construct, anchored proximally by a double hooks' claws and distally by ilio-sacral screws. However, thanks to the minimally invasive approach, the preservation of the intermediate area between the proximal and distal fixation avoided too early autofusion that could have led to cessation of growth like in traditional growing rods techniques. Thus, thoracic and lumbar vertebral height at skeletal maturity achieved the corridor of normal height [26].

In opposition with traditional growing rod techniques, where the lengthening connector is generally inserted in the intermediate area leading to early fibrosis and autofusion due to repeated surgical lengthening procedures at this area, the bipolar fixation provides delayed autofusion that happens progressively many years later. This delayed autofusion in the bipolar technique allows to improve the correction of the residual deformity thanks to repetitive

rod lengthening or to the use of expandable devices in the first years after index surgery.

That may explain why in many cases the amount of spinal and pelvic deformity correction obtained by the bipolar technique was higher than with other growing rod techniques and even with arthrodesis in this population of patients [33, 34].

In the bipolar technique, the early autofusion may exist proximally in the instrumented thoracic vertebrae and distally in the lumbosacral junction secondary to the surgical approach and the insertion of the implants. The presence of metal close to the bone at the lumbosacral junction induces a progressive autofusion that cover the implants and stabilize them.

However, the amount of autofusion and its time to onset may vary from patient to patient. This study is limited by the small number of patients who underwent a full spine CT scan. The answer how to act after the end of growth in this patient group is far from solved: to remove or to leave the implants in situ [35], to make a rod lengthening or to make a reoperation with supplementary correction and instrumented fusion [36, 37]. However, in view of the results of this study, and the low frequency of neuromuscular scoliosis, we may recommend performing a low dose CT scan before any clinical decision at final lengthening program to confirm the no need of final PSF [38]. Additional studies will be necessary to better understand the progressive stiffening of the spine on surrounding tissues.

## Conclusion

The present study suggests that final fusion after minimally invasive fusionless bipolar fixation might be unnecessary. This hypothesis is supported by the evidence of a high rate of spontaneous fusion on CT scan at the end of the lengthening program in this series of neuromuscular patients. Further investigation on a larger cohort should confirm these findings. Furthermore, the impact of this less invasive surgical technique and of the stability obtained should be analyzed in view of long-term complications and quality of life of the patients.

**Funding** The authors state that this work has not received any funding.

## Declarations

**Conflict of interest** The authors of this manuscript: Mathilde Gaume, Klervie Loiselet, Hedi Chekir, Tristan Langlais, Nathalie Boddaert, Stéphanie Pannier, Wafa Skalli and Claudio Vergari declare no relationships with any companies, whose products or services may be related to the subject matter of the article. Lotfi Miladi is a consultant from EUROS company.

**Informed consent** Written informed consent was obtained from all subjects (patients) in this study.

**Ethical approval** Institutional Review Board approval was obtained.

## References

1. Thometz JG, Simon SR (1988) Progression of scoliosis after skeletal maturity in institutionalized adults who have cerebral palsy. *J Bone Joint Surg Am* 70A:1290–1296
2. Saito N, Ebara S, Ohotsuka K et al (1998) Natural history of scoliosis in spastic cerebral palsy. *Lancet* 351:1687–1692. [https://doi.org/10.1016/S0140-6736\(98\)01302-6](https://doi.org/10.1016/S0140-6736(98)01302-6)
3. Fernandes P, Weinstein SL (2007) Natural history of early onset scoliosis. *J Bone Joint Surg Am* 89(Suppl 1):21–33. <https://doi.org/10.2106/JBJS.F.00754>
4. Bowen RE, Scaduto AA, Banuelos S (2008) Does early thoracic fusion exacerbate preexisting restrictive lung disease in congenital scoliosis patients? *J Pediatr Orthop* 28:506–511. <https://doi.org/10.1097/BPO.0b013e31817b931c>
5. Campbell RM, Smith MD, Mayes TC, Mangos JA, Willey Courand DB, Kose N, Pintero RF, Adler ME, Duong HL, Surber JL (2003) The characteristics of thoracic insufficiency syndrome associated with fused ribs and congenital scoliosis. *J Bone Joint Surg Am* 85:399–408. <https://doi.org/10.2106/00004623-200303000-00001>
6. Goldberg CJ, Moore DP, Fogarty EE, Dowling FE (2002) Long-term results from in situ fusion for congenital vertebral deformity. *Spine* 27:619–628. <https://doi.org/10.1097/00007632-200203150-00011>
7. Karol LA, Johnston C, Mladenov K, Schochet P, Walters P, Browne RH (2008) Pulmonary function following early thoracic fusion in non-neuromuscular scoliosis. *J Bone Joint Surg Am* 90:1272–1281. <https://doi.org/10.2106/JBJS.G.00184>
8. Dubousset J, Herring JA, Shufflebarger H (1989) The crankshaft phenomenon. *J Pediatr Orthop* 9:541–550. <https://doi.org/10.1097/01241398-198909010-00008>
9. Zhang H, Sucato DJ (2008) Unilateral pedicle screw epiphysiodesis of the neurocentral synchondrosis. Production of idiopathic-like scoliosis in an immature animal model. *J Bone Joint Surg Am* 90:2460–2469. <https://doi.org/10.2106/JBJS.G.01493>
10. Chest Wall and Spine Deformity Study Group, Growing Spine Study Group, Pediatric Orthopaedic Society of North America, Scoliosis Research Society Growing Spine Study Committee, Skaggs DL, Akbarnia BA, Flynn JM, Myung KS, Sponseller PD, Vitale MG (2014) A classification of growth friendly spine implants. *J Pediatr Orthop* 34(3):260–274. <https://doi.org/10.1097/BPO.0000000000000073>
11. Akbarnia BA, Marks DS, Boachie-Adjei O, Thompson AG, Asher MA (2005) Dual growing rod technique for the treatment of progressive early-onset scoliosis: a multicenter study. *Spine* 30:S46–S57. <https://doi.org/10.1097/01.brs.0000175190.08134.73>
12. Balsano M, Spina M (2020) Idiopathic early-onset scoliosis treated with Magec rods: what to do after the lengthening period is over? *Int J Spine Surg* 14(5):847–851. <https://doi.org/10.14444/7094>. (Epub 2020 Aug 25)
13. Poe-Kochert C, Shannon C, Pawelek JB, Thompson GH, Hardesty CK, Marks DS, Akbarnia BA, McCarthy RE, Emans JB (2016) Final fusion after growing-rod treatment for early onset scoliosis: is it final? *J Bone Joint Surg Am* 98(22):1913–1917. <https://doi.org/10.2106/JBJS.15.01334>
14. Growing Spine Study Group, Flynn JM, Tomlinson LA, Pawelek J, Thompson GH, McCarthy R, Akbarnia BA (2013) Growing-rod graduates: lessons learned from ninety-nine patients who completed lengthening. *J Bone Joint Surg Am* 95(19):1745–1750. <https://doi.org/10.2106/JBJS.L.01386>
15. Pediatric Spine Study Group, Du JY, Poe-Kochert C, Thompson GH, Hardesty CK, Pawelek JB, Flynn JM, Emans JB (2020) Risk factors for reoperation following final fusion after the treatment of early-onset scoliosis with traditional growing rods. *J Bone Joint Surg Am* 102(19):1672–1678. <https://doi.org/10.2106/JBJS.20.00312>
16. Growing Spine Study Group, Jain A, Sponseller PD, Flynn JM, Shah SA, Thompson GH, Means JB, Pawelek JB, Akbarnia BA (2016) Avoidance of “Final” surgical fusion after growing-rod treatment for early-onset scoliosis. *J Bone Joint Surg Am* 98(13):1073–1078. <https://doi.org/10.2106/JBJS.15.01241>
17. Bouthors C, Gaume M, Glorion C, Miladi L (2019) Outcomes at skeletal maturity of 34 children with scoliosis treated with a traditional single growing rod. *Spine* 44(23):1630–1637. <https://doi.org/10.1097/BRS.00000000000003148>
18. Gaume M, Vergari C, Khouri N, Skalli W, Glorion C, Miladi L (2021) Minimally invasive surgery for neuromuscular scoliosis: results and complications at a minimal follow-up of 5 years. *Spine* 46(24):1696–1704. <https://doi.org/10.1097/BRS.00000000000004082>
19. Shao Y-H, Tsai K, Kim S, Yu-Jen Wu Y-J, Demissie K (2019) Exposure to tomographic scans and cancer risks. *JNCI Cancer Spectr* 4(1):pkz072. <https://doi.org/10.1093/jncics/pkz072>
20. Miladi L, Gaume M, Khouri N et al (2018) Minimally invasive surgery for neuromuscular scoliosis: results and complications in a series of one hundred patients. *Spine* 43:E968–E975. <https://doi.org/10.1097/BRS.00000000000002588>
21. Gaume M, Persohn S, Vergari C et al (2020) Biomechanical cadaver study of proximal fixation in a minimally invasive bipolar construct. *Spine Deform* 8:33–38. <https://doi.org/10.1007/s43390-019-00014-2>
22. Dubousset J, Gaume M, Miladi L (2021) Ilio-sacral screw pelvic fixation when correcting spinal deformities with or without pelvic obliquity: our experience over 40 years. *Spine Deform* 9:665–670. <https://doi.org/10.1007/s43390-020-00263-6>
23. Miladi LT, Ghanem IB, Draoui MM et al (1997) Ilio-sacral screw fixation for pelvic obliquity in neuromuscular scoliosis. Long-term Followup study *Spine* 22:1722–1729. <https://doi.org/10.1007/s00402-021-04332-x>
24. Gaume M, Gerard P, Khouri N, Glorion C, Dubousset J, Miladi L (2022) Long-term outcomes of ilio-sacral screws in minimally invasive bipolar fusionless technique for neuromuscular scoliosis: a retrospective study in 167 patients. *Arch Orthop Trauma Surg* 143(4):1761–1767. <https://doi.org/10.1007/s00402-021-04332-x>
25. Frobin W, Brinckmann P, Biggemann M, Tillotson M, Burton K (1997) Precision measurement of disc height, vertebral height, and sagittal plane displacement from lateral radiographic views of the lumbar spine. *Clin Biomech (Bristol, Avon)* 12(Suppl 1):S1–S63. [https://doi.org/10.1016/s0268-0033\(96\)00067-8](https://doi.org/10.1016/s0268-0033(96)00067-8)
26. de Reuver S, Costa L, Van Rheeën H, Tabeling CS, Lemans JVC, Schlösser TPC, Kruijff MC, Van Stralen M, Castelein RM (2022) Disc and vertebral body morphology from birth to adulthood. *Spine* 47(7):E312–E318. <https://doi.org/10.1097/BRS.00000000000004278>
27. Cobb JR (ed) (1948) Outline for the study of scoliosis. *Instructional course lectures* 5:261–275
28. Moe JH, Kharrat K, Winter RB et al (1984) Harrington instrumentation without fusion plus external orthotic support for the treatment of difficult curvature problems in young children. *Clin Orthop Relat Res* 185:35–45
29. Mardjetko SM, Hammerberg KW, Lubicky JP et al (1992) The Luque trolley revisited, review of nine cases requiring revision.



- 
- Spine 17:582–589. <https://doi.org/10.1097/00007632-199205000-00018>
30. Cahill PJ, Marvil S, Cuddihy L, Schutt C, Idema J, Clements DH, Antonacci MD, Asghar J, Samdani AF, Betz RR (2010) Auto-fusion in the immature spine treated with growing rods. *Spine* 35(22):E1199–1203. <https://doi.org/10.1097/BRS.0b013e3181e21b50>
  31. Sankar WN, Skaggs DL, Yazici M et al (2011) Lengthening of dual growing rods and the law of diminishing returns. *Spine* 36:806–809. <https://doi.org/10.1097/BRS.0b013e318214d78f>
  32. Noordeen HM, Shah SA, Elsebaie HB et al (2011) In vivo distraction force and length measurements of growing rods: which factors influence the ability to lengthen? *Spine* 36:2299–2303. <https://doi.org/10.1097/BRS.0b013e31821b8e16>
  33. Tsirikos AI, Lipton G, Chang WN et al (2008) Surgical correction of scoliosis in pediatric patients with cerebral palsy using the unit rod instrumentation. *Spine* 33:1133–1140. <https://doi.org/10.1097/BRS.0b013e31816f63cf>
  34. Tsirikos AI, Mains E (2012) Surgical correction of spinal deformity in patients with cerebral palsy using pedicle screws instrumentation. *J Spinal Disord Tech* 25:404–408. <https://doi.org/10.1097/BSD.0b013e318227728c>
  35. Kocyigit IA, Olgun ZD, Demirkiran HG, Ayvaz M, Yazici M (2017) Graduation protocol after growing-rod treatment: removal of implants without new instrumentation is not a realistic approach. *J Bone Joint Surg Am* 99(18):1554–1564. <https://doi.org/10.2106/JBJS.17.00031>
  36. Murphy RF, Barfield WR, Emans JB, Akbarnia B et al (2020) Minimum 5-year follow-up on graduates of growing spine surgery for early onset scoliosis. *J Pediatr Orthop* 40(10):e942–e946. <https://doi.org/10.1097/BPO.0000000000001646>
  37. Pediatric Spine Study Group, Akbarnia BA, Pawelek JB, Hosseini P, Salari P, Kabirian N, Marks D, Shah SA, Skaggs DL, Emans JB, Elsebaie H, Thompson GH, Sponseller PD (2022) Treatment of early-onset scoliosis: similar outcomes despite different etiologic subtypes in traditional growing rod graduates. *J Pediatr Orthop*. 42(1):10–16. <https://doi.org/10.1097/BPO.0000000000001985>
  38. Abul-Kasim K et al (2009) Low-dose helical computed helical tomography (CT) in the perioperative work-up of adolescent idiopathic scoliosis. *Eur Radiol* 19(3):610–618. <https://doi.org/10.1007/s00330-008-1178-4>

**Publisher's Note** Springer Nature remains neutral with regard to jurisdictional claims in published maps and institutional affiliations.

Springer Nature or its licensor (e.g. a society or other partner) holds exclusive rights to this article under a publishing agreement with the author(s) or other rightsholder(s); author self-archiving of the accepted manuscript version of this article is solely governed by the terms of such publishing agreement and applicable law.