Science Arts & Métiers (SAM)
is an open access repository that collects the work of Arts et Métiers Institute of Technology researchers and makes it freely available over the web where possible.

This is an author-deposited version published in: https://sam.ensam.eu
Handle ID: .http://hdl.handle.net/10985/8795

To cite this version :

Guillaume DUBOIS, Dominique BONNEAU, Jean DUBOUSSET, Mickael TANTER, Jean-Luc GENNISSON, Philippe ROUCH, Claudio VERGARI - Non-invasive biomechanical characterization of intervertebral discs by shear wave ultrasound elastography: a feasibility study - European Journal of Radiology p.1-7 - 2014

Any correspondence concerning this service should be sent to the repository Administrator : scienceouverte@ensam.eu

NON-INVASIVE BIOMECHANICAL CHARACTERIZATION OF INTERVERTEBRAL DISC BY SHEARWAVE ULTRASOUND ELASTOGRAPHY: A FEASIBILITY STUDY

Claudio Vergari*†, Philippe Rouch†, Guillaume Dubois†, Dominique Bonneau†,

Jean Dubousset†, Mickael Tanter‡, Jean-Luc Gennisson‡ and Wafa Skalli†

Abstract

Objectives: Although magnetic resonance is widely spread to qualitatively assess disc morphology, a simple method to reliably determine intervertebral disc status is still lacking. Shear wave elastography is a recent technique that allows quantitative evaluation of soft-tissues mechanical properties; the aim of this study was to preliminary assess the feasibility and reliability of cervical intervertebral disc mechanical characterization by elastography and to provide first reference values for asymptomatic subjects.

Methods: Elastographic measurements were performed to determine shear wave speed (SWS) in C6-C7 or C7-T1 disc of forty-seven subjects; repeatability and inter-operator reproducibility were assessed.

Results: Global average shear wave speed (SWS) was 3.0 ± 0.4 m/s; measurement repeatability and inter-user reproducibility were 7 and 10 %, respectively. SWS was correlated with both subject's age ($p = 1.3e-5$) and body mass index ($p = 0.008$).

Conclusions: Shear wave elastography in intervertebral disc proved reliable and allowed stratification of subjects according to age and BMI. Applications could be relevant, for instance, in early detection of disc degeneration or in follow-up after trauma; these results open the way to larger cohort studies to define the place of this technique in routine intervertebral disc assessment.

Keywords: Spine; Spinal diseases, Fibrocartilage; Tissue; Elasticity Imaging; Biomechanics

* Corresponding Author. Email : c.vergari[at]gmail.com

†Arts et Metiers ParisTech, LBM, 151 bd de l'Hopital, 75013 Paris, France

‡ Institut Langevin, Ondes et Images, ESPCI ParisTech, CNRS UMR7587, INSERM U979, Paris, France

Introduction

Nearly all adults, at some point in life, experience back pain, neck pain or low back pain (Andersson, 1999; Ehrlich, 2003). The latter, in particular, was recently ranked the sixth leading contributor to overall disease burden and the leading cause of disability in both developed and developing countries (Murray et al., 2012). Few cases are due to specific causes with a clearly demonstrable underlying pathology, but a common denominator, although not necessarily the primary cause, is often the intervertebral disc (Cheung et al., 2009; Endean et al., 2011). Indeed, some degree of intervertebral disc degeneration, even if asymptomatic, is widespread with aging (Jacobs et al., 1990; Matsumoto et al., 2013), with a prevalence of 70 % of the population under 50 years old, and over 90 % of the population 50 years old and over (Teraguchi et al., 2014).

Intervertebral disc plays a major role in the biomechanical behaviour of the spine: it resists compressive loadings and absorbs shocks while allowing movements between vertebrae, thus facilitating flexibility of the column (Humzah and Soames, 1988). An alteration of the disc stiffness could be a sign, or the cause, of a disease of the disc itself or of the spine. A non-invasive direct method to determine disc mechanical properties could complement the tools at the clinician's disposal for the early diagnose of disc diseases (Kurowski and Kubo, 1986; Rohlmann et al., 2006; Ruberté et al., 2009; Tanaka et al., 2001) or in planning of surgical procedures (Aubin et al., 2008; Lafage et al., 2004; Lafon et al., 2009).

Magnetic resonance is a well-established technique to assess intervertebral disc morphology, water content and collagen structure (Benneker et al., 2005; Schneiderman et al., 1987; Thompson et al., 1990; Watanabe et al., 2007). Preliminary in-vitro work has shown correlations between magnetic resonance images and disc mechanical properties (Campana et al., 2011; Cortes et al., 2014; Mwale et al., 2008; Périé et al., 2006; Recuerda et al., 2012), but *in-vivo* applications are still lacking. Moreover, cost and accessibility of magnetic resonance imaging represent an issue when considering large scale routine clinical use.

Ultrasound-based methods are of much easier access; shear wave elastography, in particular, is a recent technique that allows quantitative evaluation of soft-tissue elastic modulus, which is an important mechanical parameter defining the resistance of the tissue to deformation. This technique is rapidly gaining its place in clinical routine for the evaluation of breast (Athanasiou et al., 2010; Cosgrove et al., 2012; Tanter et al., 2008), liver (Bavu et al., 2011; Ferraioli et al., 2012) and prostate lesions (Correas et al., 2013). It is non-invasive, fast and portable; therefore, it seems a good candidate to assess intervertebral disc mechanical properties.

An *in vitro* feasibility study on shear wave measurement was recently performed in oxtail intervertebral discs (Vergari et al., 2014), showing correlations between elastographic measurements and disc mechanical properties in compression. The present study aimed at determining the feasibility and reliability of SWS measurements in cervical intervertebral disc *in vivo*, and to provide first reference values for asymptomatic adults.

Methods

Subjects

Forty-seven subjects volunteered in this study (36.5 ± 12.6 years old, range 22-73; 23.7 ± 4.0 kg/m² body mass index, range 18.7-35.1; Table 1). All subjects declared to be free of spinal or disc pathologies and of neck back pain. Each subject gave informed consent after the nature of the procedure had been fully

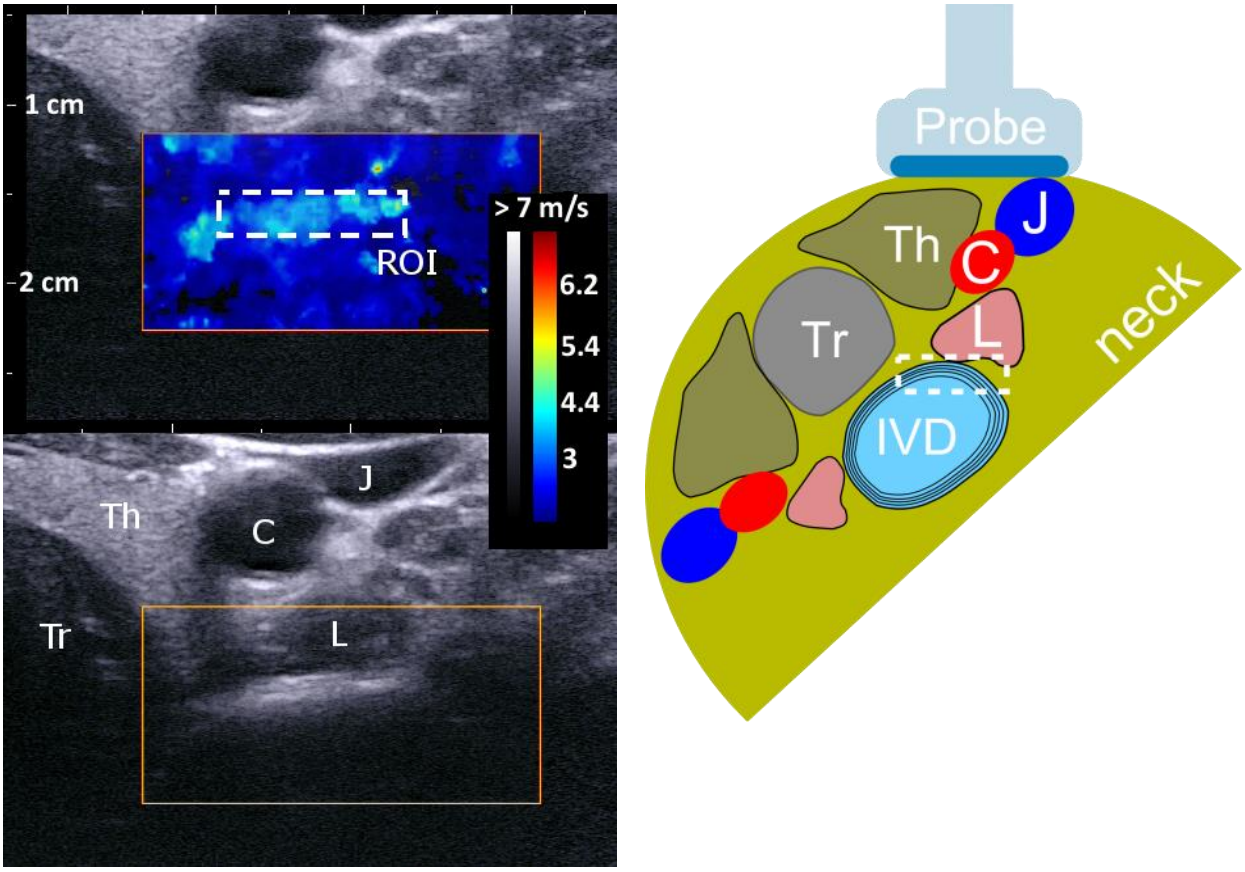

Fig. 1 Example of a mediolateral transverse elastographic image of cervical disc in a 35 years old female and schematic view. The region of interest (ROI) in the annulus fibrosus is indicated by a dashed rectangle both in the shear wave speed chart (top) and in the standard B-mode image (bottom). Several anatomical landmarks are visible, such as the thyroid gland (Th), trachea (Tr), carotid artery (C), jugular vein (J) and *longus colli* muscle (L). The nucleus is not visible since ultrasound does not penetrate that deep in the disc.

explained (ethical committee approval *CPP Ile-de-France VI* 6036).

Principles of elastographic measurement

Shear wave elastographic images were acquired using a commercial device (Aixplorer, SuperSonic Imagine, France) with a linear ultrasonic probe of 8 MHz central frequency (SuperLinear SL 15-4). This non-invasive measurement technique is based on two principles: acoustic radiation force and ultrasound ultrafast imaging (Bercoff et al., 2004; Sarvazyan et al., 1998). Briefly, the device generates quasi-plane shear waves deep in the tissue through the radiation force of ultrasound focused beams. Resulting shear waves propagate relatively slowly in biological tissues (~1-50 m/s), allowing their real-time observation with ultrafast ultrasound imaging (> 1000 frames per second). The actual speed of these shear waves depends on the tissue's mechanical properties: the stiffer the tissue, the faster the waves. The device outputs bitmap images or movies with color-charted local shear wave speeds (Figure 1), which are directly related to the tissue mechanical properties.

In general, studies on elastography report values of the tissue's elastic modulus. Intervertebral disc, however, is a complex biological structure; its outer region, the *annulus fibrosus*, where shear wave speed was measured, is a composite material consisting of concentric fibrocartilaginous *lamellae* that progressively transform into a gel-like core, the *nucleus pulposus*, towards the centre (Iatridis et al., 1996; Keyes and

Compere, 1932; Marchand and Ahmed, 1990). The inherent heterogeneity and anisotropy of intervertebral disc does not allow the mathematical simplifications usually adopted to directly obtain an elastic modulus from shear wave speed measurements (Royer et al., 2011). Therefore, only speed values were reported in this study.

Fig. 2 Setup for shear wave speed measurements in cervical disc (b).

Data acquisition and processing

The subject lied down in supine position; elastographic images of the intervertebral disc were acquired with the ultrasonic probe placed transversally at the level of C6-C7 or C7-T1 disc (Figure 2). The vertebral level was determined using the thyroid as anatomical landmark, while the disc was recognized from vertebral bone since the latter appears thin and very echogenic in B-mode images, and shear waves do not propagate in it (i.e., no elastographic signal was visible).

The elastographic machine was set to acquire raw images with no filtering. Three series of six seconds movies were acquired by one operator; data acquisition lasted about 10 minutes for each subject.

After data acquisition, a rectangular region of interest (ROI) was defined in the B-mode panel of the first frame of the movie, in the *annulus fibrosus* (the outer layer of the intervertebral disc, Figure 1). The average size of the ROI was 33 x 80 pixels (height x width, the corresponding size in mm varying with the image zoom; a typical ROI would be about 3.5 x 8 mm). A corresponding ROI was automatically generated in the elastographic panel (Figure 1), where SWS was calculated using custom software which was developed in Matlab (Mathworks, Natick, MA, USA). The average SWS was calculated in each image and then averaged to obtain a single mean SWS value for each movie. Some images were discarded because clearly affected by artefacts. All elastographic movies were processed by

Table 1 Characteristics of the subjects participating in this study and average shear wave speed in intervertebral discs.

	All subjects	**Age 22-30**	**Age 30-50**	**Age > 50**	**BMI < 25**	**BMI > 25**
N	47	20	19	8	33	14
Age	36.5 ± 12.6	26.1 ± 2.2	37.9 ± 5.9	59.3 ± 6.4	33.3 ± 11.0	44.2 ± 13.4
BMI (kg/m²)	23.7 ± 4.0	21.9 ± 2.6	24.2 ± 4.4	27.0 ± 3.4	21.7 ± 2.0	28.5 ± 3.1
SWS (m/s)	3.0 ± 0.4	3.3 ± 0.3	2.9 ± 0.3	2.7 ± 0.3	3.1 ± 0.4	2.8 ± 0.4

N = number of subjects, BMI = body mass index, SWS = shear wave speed. Mean values ± standard deviation.

the same operator.

Reliability assessment

Six series of ten-second movies (about ten elastographic images each) were acquired by three operators on a subset of five subjects (24.4 ± 1.8 years, range 22-27), in order to assess measurement reproducibility; the probe was replaced after each movie. Measurements in one subject (28 years old, 63 kg body mass) were also performed in three adjacent discs (C6-C7, C7-T1 and T1-T2) to confirm that the structure being measured was indeed the disc and to determine if the shear wave speed in those three discs was the same.

Statistical analysis

Patients were separated in three groups according to their age (Table 1): between 22 and 30 years, between 30 and 50 years old and over 50 years old. Patients were also separated in two groups according to their body mass index (BMI): lower and higher than 25 kg/m² (normal range and overweight/obese). Forty-seven subjects were sufficient to detect an effect size of 0.7 SD in three groups with over 95 % power at an α-level of 0.05 (Cohen, 1988).

Correlations were quantified with Pearson's correlation coefficient while differences were assessed with Student's t-test; statistical significance was set at 0.05. Repeatability (intra-operator) and reproducibility (inter-operator) of SWS measurements were determined according to ISO 5725 standard. Intraclass correlation coefficient (ICC) was determined both intra and inter-operator; an ICC greater than 0.75 was considered to signify good agreement (Lee et al., 1989). Bland-Altman plot was used to present the limits of agreement. Measurements in three adjacent discs were analysed with one-way ANOVA.

Results

Global average SWS was 3.0 ± 0.4 m/s (ranging from 2.2 to 3.9 m/s, Table 1); measurement repeatability and inter-user reproducibility were 0.2 and 0.3 m/s, respectively, corresponding to 7 and 10 % of average SWS. Intra-operator ICC was higher than 0.9 for each operator (0.98, 0.94 and 0.95, respectively) while inter-operator ICC was 0.97. Bland-Altman plot of the reproducibility protocol is shown in Figure 3.

A correlation was observed between age and SWS (Fig. 4, r = -0.6, p = 1.3e-5). Shear wave speed in the 22-30 years old group was significantly higher than that of the 30-50 years old group (p = 0.9e-5), while the latter was higher but not significantly than the over 50 group (p = 0.1, Fig. 5). A correlation was also observed between shear wave speed and BMI (Fig. 6, r = -0.38, p = 0.008), with significant differences between the normal and overweight populations (p = 0.004, Fig. 7). Finally, age and BMI were also correlated to each other (r = 0.38, p = 0.009).

Shear wave speed in three adjacent discs of one 28 years old subject was 2.96 ± 0.39 m/s (T1-T2), 2.96 ± 0.21 m/s (C7-T1) and 3.13 ± 0.44 m/s (C6-C7), respectively. No significant difference was observed between levels (p = 0.18, ANOVA test).

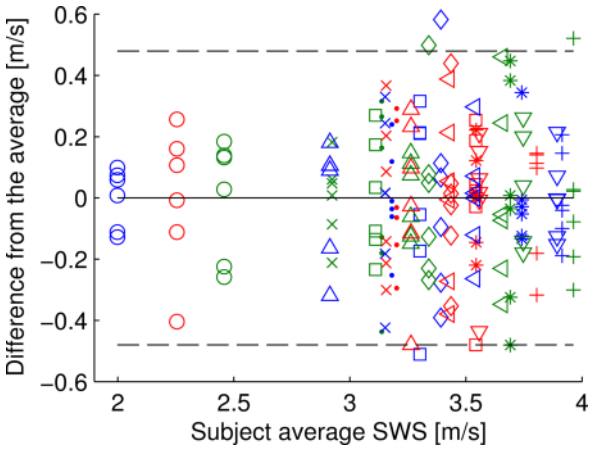

Fig. 3 Bland-Altmann plot of shear wave speed measurements in cervical intervertebral disc. Each colour identifies an operator (n = 3) while each symbol identifies a subject (n = 5). Dashed lines are twice the measurement repeatability.

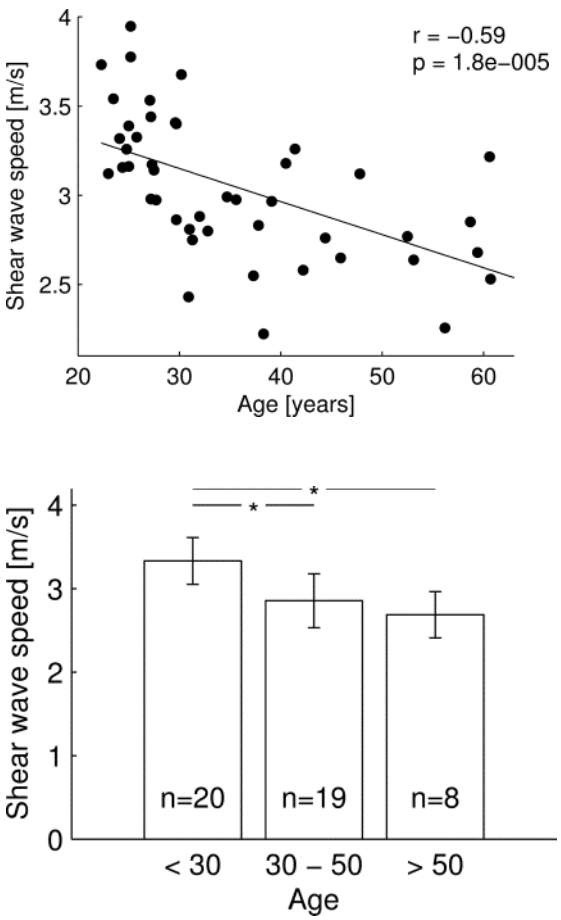

Fig. 4 (a) Correlation between shear wave speed in cervical intervertebral disc and subjects' age and (b) differences between age groups.

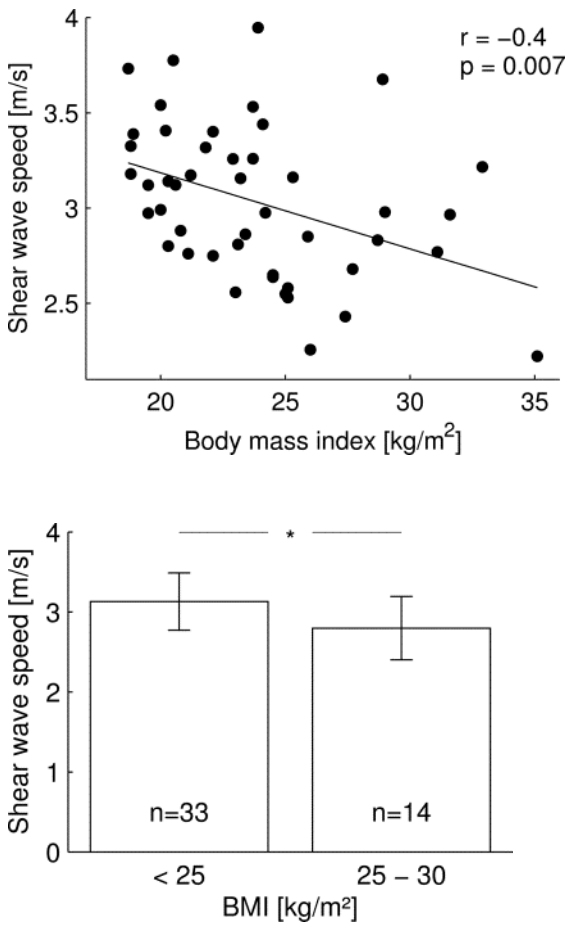

Fig. 5 (a) Correlation between shear wave speed in cervical intervertebral disc and subjects' body mass index and (b) differences between body mass index groups

Discussion

This study explored, for the first time, the feasibility of *in vivo* quantitative assessment of mechanical properties of cervical discs. Shear wave elastography measurements revealed highly repeatable, not operator-dependent and relatively easy to perform; this opens the way to a number of applications, both in clinic and in research to provide new insight on disc disease. Ultrasonic biomechanical characterization of the disc can complement the morphologic exam by magnetic resonance imaging and thus overcome certain limitations of magnetic resonance in patient managing.

Non-invasive biomechanical characterization of the disc could represent a novel biomarker for disc assessment, as was previously suggested by Cortes et al. (Cortes et al., 2014): the relationship between pain and biochemical or structural characteristics of the disc is complex (Freemont, 2009), but mechanical properties could be affected by both these aspects. For instance, mechanical traumas such as whiplash can cause disc pathologies which are difficult to diagnose because of the high prevalence of physiological disc degeneration with age (Pettersson et al., 1997). Disc mechanical properties could thus intervene as a fast screening technique to detect disc alteration.

Elastographic measurements could also play a role in surgical planning. For instance, adjacent segment disease, a symptomatic degeneration of the intervertebral discs adjacent to a spinal

segment that was fused by arthrodesis, is a widespread issue, as shown by the over 100 articles published in the last three years (PubMed search for “adjacent disc disease” between 2011 and 2013). The presence of a rigid segment in the column seems to accelerate the natural aging of adjacent intervertebral discs, but in particular if those discs had asymptomatic disc degeneration prior to surgery (Ishihara et al., 2004). Elastography could help detect these discs, especially since it is not affected by artefacts induced by the presence of metal-like implants, as is the case with computerized tomography and magnetic resonance (Stradiotti et al., 2009).

Two main limitations affect this study; first, subjects were included after they declared being free of spinal or disc disorders, but their status was not clinically checked. The lack of symptoms do not necessarily imply that intervertebral discs were healthy, because it is not unusual to find disc disorders in asymptomatic subjects (Jensen et al., 1994). Therefore, the average values reported in the present paper (and the correlations) could be affected by asymptomatic diseased discs. While the aim of the present work was not the comparison of elastography in healthy and diseased disc, future studies should include control groups where the status of the disc has been ascertained by other means.

The second main limitation is that all data was processed by only one operator, although elastographic images were acquired by three operators. In particular, the initial placement of the ROI and its semi-automatic tracking could affect measurement repeatability. The ROI size could be modified to avoid noisy regions; still, about one image in ten showed too much noise in the ROI and was therefore discarded.

The ROI was systematically placed in the annulus fibrosus, where the average SWS was calculated. It is likely that a significant portion of the annulus thickness, in the radial direction, was included in the ROI: Skrzypiec et al. (Skrzypiec et al., 2007) reported an average frontal thickness of about 7 mm for the annulus, which is similar to the thicknesses observed in b-mode image (Figure 1).

Applications of elastography to superficial organs, breast or muscles, showed that great care is needed to avoid high operator-dependent discrepancies in the measurements. One of the main reasons for this potential error is that tissue elasticity changes when applying pressure to it; therefore the shear wave speed can change when pushing over the tissue with the ultrasound probe itself (Kot et al., 2012). Intervertebral discs are deep structures, protected from the compressing force of the probe by overlying tissues and by the adjacent vertebral bodies; therefore, the operator-dependent force of application of the probe does not alter the SWS measurement. This is reflected in the very good inter-operator reproducibility.

Precision values were similar to those obtained *in vitro* in animal specimens (Vergari et al., 2014) (7 % repeatability in unloaded discs) and *in vivo* in muscles (Lacourpaille et al., 2012). Measurements in breast phantom have been previously performed with a slightly higher precision error of 0.5 m/s (corresponding to 0.82 kPa in Young’s modulus) (Mun et al., 2013).

A correlation was observed between SWS and subject age (Figure 4). Variation of intervertebral disc characteristics were previously demonstrated in similar ages range (Lehto et al., 1994), therefore such correlation was expected. A drift from these standard changes might be interpreted as an early sign of disc degeneration, especially in populations at risk (Jager et al., 1997; Scher, 1990). While a significant difference was observed between the groups of 22-30

years old and 30-50 years old subjects ($p < 0.05$), the difference between the latter and the 50-73 group was not significant ($p \approx 0.1$, Figure 5). This could be due to small number of subjects included in this preliminary study, and by the fact that the data variability could have been increased by the presence of asymptomatic diseased discs in the cohort. Previous *in-vitro* tests showed that age only marginally affects the mechanical properties of the annulus (Acaroglu et al., 1995; Ebara et al., 1996), while degeneration and regional variations are more important.

Figure 1 shows the transverse plane of the disc; aligning the probe with this particular plane is relatively straightforward because elastographic images are not generated (or they significantly fluctuate) if the probe is not aligned with the disc. Extreme pathological thinning of the disc could negatively affect the measurement by preventing the penetration of shear waves.

Wave propagation is affected by the anisotropic character of the disc, and in particular by the arrangement of lamellae; measurements in the longitudinal direction would therefore yield different results, which could be used to investigate disc mechanical properties in different directions (i.e., to study its anisotropic character). Work is in progress for researching a reliable protocol for measurements in the longitudinal direction and in lumbar discs; the latters are deeper than cervical discs and ultrasound propagation may be affected by the intestines and their contents. A correlation was also observed between shear wave speed and BMI (Figure 6). This correlation could be indirect since age and BMI were correlated as well. However, associations between overweight (body mass index ≥ 25 kg/m^2) and disc degeneration have been previously reported (Liuke et al., 2005; Weiler et al., 2011), suggesting that a degree of degeneration was detected in the discs of this study's cohort. This should be further investigated on a large cohort of subject with similar age and different BMI in order to exclude the influence of the age-effect.

More in-depth characterization of disc's mechanical properties could be obtained by performing *ex vivo* tests where all relevant variables and possible sources of artefact can be controlled (e.g., disc thickness, degree of degradation, etc.). For instance, a direct relationship between shear wave speed and disc's mechanical properties in compression was previously demonstrated *in vitro* in oxtail intervertebral discs (Vergari et al., 2014). At the same time, comparison with magnetic resonance evaluation would help clarify the physiological and clinical meaning of shear wave speed measurements and their sensitivity to disc degeneration. However, direct measurement of intervertebral discs already allows the stratification of the subjects according to age or body mass index, as shown in the present study. This finding justifies studies on larger cohorts aiming at defining the place of shear wave elastography in intervertebral disc routine examinations.

The aim of the present work was to assess the feasibility of intervertebral disc characterization by elastography *in vivo*. Shear wave speed measurements revealed repeatable and did not depend on the operator. The disc mechanical parameters that can be retrieved by these measurements must now be determined, for instance through cadaveric and *in-vitro* studies. This study opens the way to the exploration of diseased intervertebral disc and spine deformities.

Acknowledgements

The authors are grateful to the ParisTech BiomecAM chair program on subject-specific musculoskeletal modelling for funding (with the support of ParisTech

and Yves Cotrel Foundations, *Société Générale*, Proteor and Covea).

Conflict of interest statement

Jean-Luc Gennisson is a scientific consultant for SuperSonic Imagine, and Mickael Tanter is cofounder and shareholder of SuperSonic Imagine (Aix-en-Provence, France). The other authors do not have any conflicting financial interests.

References

Acaroglu, E. R., Iatridis, J. C., Setton, L. A., Foster, R. J., Mow, V. C., Weidenbaum, M., 1995. Degeneration and aging affect the tensile behavior of human lumbar anulus fibrosus. Spine (Phila Pa 1976) 20, 2690-2701.

Andersson, G. B., 1999. Epidemiological features of chronic low-back pain. Lancet 354, 581-585.

Athanasiou, A., Tardivon, A., Tanter, M., Sigal-Zafrani, B., Bercoff, J., Deffieux, T., Gennisson, J. L., et al., 2010. Breast lesions: quantitative elastography with supersonic shear imaging--preliminary results. Radiology 256, 297-303.

Aubin, C. E., Labelle, H., Chevrefils, C., Desroches, G., Clin, J., Eng, A. B., 2008. Preoperative planning simulator for spinal deformity surgeries. Spine (Phila Pa 1976) 33, 2143-2152.

Bavu, É., Gennisson, J.-L., Couade, M., Bercoff, J., Mallet, V., Fink, M., Badel, A., et al., 2011. Noninvasive In Vivo Liver Fibrosis Evaluation Using Supersonic Shear Imaging: A Clinical Study on 113 Hepatitis C Virus Patients. Ultrasound in Medicine & Biology 37, 1361-1373.

Benneker, L., Heini, P., Anderson, S., Alini, M., Ito, K., 2005. Correlation of radiographic and MRI parameters to morphological and biochemical assessment of intervertebral disc degeneration. European Spine Journal 14, 27-35.

Bercoff, J., Tanter, M., Fink, M., 2004. Supersonic shear imaging: a new technique for soft tissue elasticity mapping. IEEE Trans Ultrason Ferroelectr Freq Control 51, 396-409.

Campana, S., Charpail, E., De Guise, J. A., Rillardon, L., Skalli, W., Mitton, D., 2011. Relationships between viscoelastic properties of lumbar intervertebral disc and degeneration grade assessed by MRI. Journal of the Mechanical Behavior of Biomedical Materials 4, 593-599.

Cheung, K. M., Karppinen, J., Chan, D., Ho, D. W., Song, Y. Q., Sham, P., Cheah, K. S., et al., 2009. Prevalence and pattern of lumbar magnetic resonance imaging changes in a population study of one thousand forty-three individuals. Spine (Phila Pa 1976) 34, 934-940.

Cohen, J. 1988. Statistical power analysis for the behavioral science, Lawrence Erlbaum Associates, Hillsdale, New Jersey (USA).

Correas, J. M., Tissier, A. M., Khairoune, A., Khoury, G., Eiss, D., Helenon, O., 2013. Ultrasound elastography of the prostate: state of the art. Diagn Interv Imaging 94, 551-560.

Cortes, D. H., Magland, J. F., Wright, A. C., Elliott, D. M., 2014. The shear modulus of the nucleus pulposus measured using magnetic resonance elastography: A potential biomarker for intervertebral disc degeneration. Magnetic Resonance in Medicine 72, 211-219.

Cosgrove, D., Berg, W., Doré, C., Skyba, D., Henry, J.-P., Gay, J., Cohen-Bacrie, C., 2012. Shear wave elastography for breast masses is highly reproducible. European Radiology 22, 1023-1032.

Ebara, S., Iatridis, J. C., Setton, L. A., Foster, R. J., Mow, V. C., Weidenbaum, M., 1996. Tensile properties of nondegenerate human lumbar anulus fibrosus. Spine (Phila Pa 1976) 21, 452-461.

Ehrlich, G. E., 2003. Low back pain. Bull World Health Organ 81, 671-676.

Endean, A., Palmer, K. T., Coggon, D., 2011. Potential of magnetic resonance imaging findings to refine case definition for mechanical low back pain in epidemiological studies: a systematic review. Spine (Phila Pa 1976) 36, 160-169.

Ferraioli, G., Tinelli, C., Dal Bello, B., Zicchetti, M., Filice, G., Filice, C., 2012. Accuracy of real-time shear wave elastography for assessing liver fibrosis in chronic hepatitis C: a pilot study. Hepatology 56, 2125-2133.

Freemont, A. J., 2009. The cellular pathobiology of the degenerate intervertebral disc and discogenic back pain. Rheumatology (Oxford) 48, 5-10.

Humzah, M. D., Soames, R. W., 1988. Human intervertebral disc: Structure and function. The Anatomical Record 220, 337-356.

Iatridis, J. C., Weidenbaum, M., Setton, L. A., Mow, V. C., 1996. Is the nucleus pulposus a solid or a fluid? Mechanical behaviors of the nucleus pulposus of the human intervertebral disc. Spine (Phila Pa 1976) 21, 1174-1184.

Ishihara, H., Kanamori, M., Kawaguchi, Y., Nakamura, H., Kimura, T., 2004. Adjacent segment disease after anterior cervical interbody fusion. Spine J 4, 624-628.

Jacobs, B., Ghelman, B., Marchisello, P., 1990. Coexistence of cervical and lumbar disc disease. Spine (Phila Pa 1976) 15, 1261-1264.

Jager, H. J., Gordon-Harris, L., Mehring, U. M., Goetz, G. F., Mathias, K. D., 1997. Degenerative change in the cervical spine and load-carrying on the head. Skeletal Radiol 26, 475-481.

Jensen, M. C., Brant-Zawadzki, M. N., Obuchowski, N., Modic, M. T., Malkasian, D., Ross, J. S., 1994. Magnetic Resonance Imaging of the Lumbar Spine in People without Back Pain. New England Journal of Medicine 331, 69-73.

Keyes, D. C., Compere, E. L., 1932. The normal and pathological physiology of the nucleus pulposus of the intervertebral disc. An Anatomical, Clinical, and Experimental Study. The Journal of Bone & Joint Surgery 14, 897-938.

Kot, B. C., Zhang, Z. J., Lee, A. W., Leung, V. Y., Fu, S. N., 2012. Elastic modulus of muscle and tendon with shear wave ultrasound elastography: variations with different technical settings. PLoS One 7, e44348.

Kurowski, P., Kubo, A., 1986. The Relationship of Degeneration of the Intervertebral Disc to Mechanical Loading Conditions on Lumbar Vertebrae. Spine (Phila Pa 1976) 11, 726-731.

Lacourpaille, L., Hug, F., Bouillard, K., Hogrel, J.-Y., Nordez, A., 2012. Supersonic shear imaging provides a reliable measurement of resting muscle shear elastic modulus. Physiological Measurement 33, N19.

Lafage, V., Dubousset, J., Lavaste, F., Skalli, W., 2004. 3D finite element simulation of Cotrel-Dubousset correction. Comput Aided Surg 9, 17-25.

Lafon, Y., Lafage, V., Dubousset, J., Skalli, W., 2009. Intraoperative three-dimensional correction during rod rotation technique. Spine (Phila Pa 1976) 34, 512-519.

Lee, J., Koh, D., Ong, C. N., 1989. Statistical evaluation of agreement between two methods for measuring a quantitative variable. Computers in Biology and Medicine 19, 61-70.

Lehto, I. J., Tertti, M. O., Komu, M. E., Paajanen, H. E. K., Tuominen, J., Kormano, M. J., 1994. Age-related MRI changes at 0.1 T in cervical discs in asymptomatic subjects. Neuroradiology 36, 49-53.

Liuke, M., Solovieva, S., Lamminen, A., Luoma, K., Leino-Arjas, P., Luukkonen, R., Riihimaki, H., 2005. Disc degeneration of the lumbar spine in relation to overweight. Int J Obes (Lond) 29, 903-908.

Marchand, F., Ahmed, A. M., 1990. Investigation of the laminate structure of lumbar disc anulus fibrosus. Spine (Phila Pa 1976) 15, 402-410.

Matsumoto, M., Okada, E., Toyama, Y., Fujiwara, H., Momoshima, S., Takahata, T., 2013. Tandem age-related lumbar and cervical intervertebral disc changes in asymptomatic subjects. European Spine Journal 22, 708-713.

Mun, H. S., Choi, S. H., Kook, S. H., Choi, Y., Jeong, W. K., Kim, Y., 2013. Validation of intra- and interobserver reproducibility of shearwave elastography: Phantom study. Ultrasonics 53, 1039-1043.

Murray, C. J., Vos, T., Lozano, R., Naghavi, M., Flaxman, A. D., Michaud, C., Ezzati, M., et al., 2012. Disability-adjusted life years (DALYs) for 291 diseases and injuries in 21 regions, 1990-2010: a systematic analysis for the Global Burden of Disease Study 2010. Lancet 380, 2197-2223.

Mwale, F., Demers, C. N., Michalek, A. J., Beaudoin, G., Goswami, T., Beckman, L., Iatridis, J. C., et al., 2008. Evaluation of quantitative magnetic resonance imaging, biochemical and mechanical properties of trypsin-treated intervertebral discs under physiological compression loading. J Magn Reson Imaging 27, 563-573.

Périé, D., Iatridis, J. C., Demers, C. N., Goswami, T., Beaudoin, G., Mwale, F., Antoniou, J., 2006. Assessment of compressive modulus, hydraulic permeability and matrix content of trypsin-treated nucleus pulposus using quantitative MRI. Journal of Biomechanics 39, 1392-1400.

Pettersson, K., Hildingsson, C., Toolanen, G., Fagerlund, M., Bjornebrink, J., 1997. Disc pathology after whiplash injury. A prospective magnetic resonance imaging and clinical investigation. Spine (Phila Pa 1976) 22, 283-287; discussion 288.

Recuerda, M., Perie, D., Gilbert, G., Beaudoin, G., 2012. Assessment of mechanical properties of isolated bovine intervertebral discs from multi-parametric magnetic resonance imaging. BMC Musculoskeletal Disorders 13, 195.

Rohlmann, A., Zander, T., Schmidt, H., Wilke, H.-J., Bergmann, G., 2006. Analysis of the influence of disc degeneration on the mechanical behaviour of a lumbar motion segment using the finite element method. Journal of Biomechanics 39, 2484-2490.

Royer, D., Gennisson, J. L., Deffieux, T., Tanter, M., 2011. On the elasticity of transverse isotropic soft tissues (L). Journal of the Acoustical Society of America 129, 2757-2760.

Ruberté, L. M., Natarajan, R. N., Andersson, G. B. J., 2009. Influence of single-level lumbar degenerative disc disease on the behavior of the adjacent segments—A finite element model study. Journal of Biomechanics 42, 341-348.

Sarvazyan, A. P., Rudenko, O. V., Swanson, S. D., Fowlkes, J. B., Emelianov, S. Y., 1998. Shear wave elasticity imaging: a new ultrasonic technology of medical diagnostics. Ultrasound in Medicine & Biology 24, 1419-1435.

Scher, A. T., 1990. Premature onset of degenerative disease of the cervical spine in rugby players. S Afr Med J 77, 557-558.

Schneiderman, G., Flannigan, B., Kingston, S., Thomas, J., Dillin, W. H., Watkins, R. G., 1987. Magnetic Resonance Imaging in the Diagnosis of Disc Degeneration: Correlation with Discography. Spine (Phila Pa 1976) 12, 276-281.

Skrzypiec, D., Pollintine, P., Przybyla, A., Dolan, P., Adams, M., 2007. The internal mechanical properties of cervical intervertebral discs as revealed by stress profilometry. European Spine Journal 16, 1701-1709.

Stradiotti, P., Curti, A., Castellazzi, G., Zerbi, A., 2009. Metal-related artifacts in instrumented spine. Techniques for reducing artifacts in CT and MRI: state of the art. European Spine Journal 18, 102-108.

Tanaka, N., An, H. S., Lim, T.-H., Fujiwara, A., Jeon, C.-H., Haughton, V. M., 2001. The relationship between disc degeneration and flexibility of the lumbar spine. The Spine Journal 1, 47-56.

Tanter, M., Bercoff, J., Athanasiou, A., Deffieux, T., Gennisson, J.-L., Montaldo, G., Muller, M., et al., 2008. Quantitative Assessment of Breast Lesion Viscoelasticity: Initial Clinical Results Using Supersonic Shear Imaging. Ultrasound in Medicine & Biology 34, 1373-1386.

Teraguchi, M., Yoshimura, N., Hashizume, H., Muraki, S., Yamada, H., Minamide, A., Oka, H., et al., 2014. Prevalence and distribution of intervertebral disc degeneration over the entire spine in a population-based cohort: the Wakayama Spine Study. Osteoarthritis and Cartilage 22, 104-110.

Thompson, J. P., Pearce, R. H., Schechter, M. T., Adams, M. E., Tsang, I. K. Y., Bishop, P. B., 1990. Preliminary Evaluation of a Scheme for Grading the Gross Morphology of the Human Intervertebral Disc. Spine (Phila Pa 1976) 15, 411-415.

Vergari, C., Rouch, P., Dubois, G., Bonneau, D., Dubousset, J., Tanter, M., Gennisson, J. L., et al., 2014. Intervertebral disc characterization by shear wave elastography: an in-vitro preliminary study. Proceedings of the Institution of Mechanical Engineers, Part H: Journal of Engineering in Medicine 228, 607-615.

Watanabe, A., Benneker, L. M., Boesch, C., Watanabe, T., Obata, T., S.E., A., 2007. Classification of Intervertebral Disk Degeneration with Axial T2 Mapping. American Journal of Roentgenology 189, 936-942.

Weiler, C., Lopez-Ramos, M., Mayer, H. M., Korge, A., Siepe, C. J., Wuertz, K., Weiler, V., et al., 2011. Histological analysis of surgical lumbar intervertebral disc tissue provides evidence for an association between disc degeneration and increased body mass index. BMC Res Notes 4, 497.